COLUMBIA LIBRARIES OFFSITE
HEALTH SCIENCES STANDARD
HX00057762

RD31 B51

Columbia University 3
in the City of New York

College of Physicians and Surgeons

Reference Library

Digitized by the Internet Archive
in 2010 with funding from
Open Knowledge Commons

http://www.archive.org/details/treatiseonregion03binn

A TREATISE

ON

REGIONAL SURGERY

VOLUME III

BINNIE

VOLUME I

The Head — Branchial System — The Thorax—The Breast . . . .

VOLUME II

The Abdomen — The Genito-Urinary System—The Spine. . . . . .

VOLUME III

The Upper Extremity—The Lower Extremity . . . . . .

A TREATISE
ON
REGIONAL SURGERY

BY VARIOUS AUTHORS

EDITED BY
JOHN FAIRBAIRN BINNIE, A. M., C. M., F. A. C. S.
KANSAS CITY, MISSOURI.

VOLUME III

WITH 521 ILLUSTRATIONS

PHILADELPHIA
P. BLAKISTON'S SON & CO.
1012 WALNUT STREET

Copyright, 1917, by P. Blakiston's Son & Co.

THE MAPLE PRESS YORK PA

LIST OF CONTENTS

SECTION I

PAGE

Traumata of the Upper Extremity (Exclusive of Fractures and Dislocations). JAMES F. MITCHELL, A.B., M.D., F.A.C.S. 1

SECTION II

Fractures of the Upper Extremity, J. W. PERKINS, M.D., F.A.C.S. 27

SECTION III

Dislocations of the Upper Extremity, A. F. JONAS, M.D., F.A.C.S. 97

SECTION IV

Diseases of the Upper Extremity, DEAN LEWIS, A.B., M.D., F.A.C.S. 149

SECTION V

Deformities and Paralyses of the Upper Extremity, E. H. BRADFORD, M.D., F.A.C.S. and ROBERT SOUTTER, A.B., M.D., F.A.C.S. 291

SECTION VI

Operations upon the Upper Extremity, J. F. BINNIE, A.M., C.M., F.A.C.S. 319

SECTION VII

Traumata of the Lower Extremity (Exclusive of Fractures and Dislocations), W. J. FRICK, M.D., F.A.C.S. 333

SECTION VIII

Fractures of the Lower Extremity, SIR W. ARBUTHNOT LANE, BT., M.D., B.S., F.R.C.S. 345

SECTION IX

Dislocations of the Joints of the Lower Extremity, CHARLES HERBERT FAGGE, M.B., B.S., F.R.C.S. 387

SECTION X

PAGE

Tumors of the Lower Extremities, EMMET RIXFORD, B. SC., M.D., F.A.C.S. . . . 439

SECTION XI

Non-Traumatic Affections of the Lower Extremity, STANLEY STILLMAN, M.D., F.A.C.S. 471

SECTION XII

Deformities of Lower Limbs, SIR ROBERT JONES, C.B. CH.M., F.R.C.S., (Ed.) HON. F.R.C.S.I., and DAVID MCCRAE AITKEN, A.M., M.B., CH.B., F.R.C.S. (Ed. and Eng.). 577

SECTION XIII

Congenital Dislocation of the Hip, SIR ROBERT JONES, C.B. CH.M., F.R.C.S., (Ed.) HON. F.R.C.S.I., and DAVID MCCRAE AITKEN, A.M., M.B., CH.B., F.R.C.S. (Ed. and Eng.) 647

SECTION XIV

Infantile Paralysis, SIR ROBERT JONES, C. B. CH.M., F.R.C.S., (Ed.) HON. F.R.C.S.I., and DAVID MCCRAE AITKEN, A.M., M.D., CH.B., F.R.C.S. (Ed. and Eng.) 657

SECTION XV

Amputations (Lower Extremity), J. F. BINNIE, A.M., C.M., F.A.C.S. 681

SECTION XVI

Operations upon the Joints of the Lower Extremity, J. F. BINNIE, A.M., C.M., F.A.C.S. 691

SECTION XVII

Thoracic Surgery, HOWARD LILIENTHAL, A.B., M.D., F.A.C.S., and JOHN C. A. GERSTER, A.B., M.D., F.A.C.S. 703

INDEX 805

REGIONAL SURGERY

THE EXTREMITIES

SECTION I

TRAUMATA OF THE UPPER EXTREMITY

By

JAMES F. MITCHELL, A.B., M.D., F.A.C.S.

WOUNDS AND INJURIES OF THE ARM

Injuries of the arm in general assume an especial importance because of the necessity of good function of this member in relation to the earning capacity of a large proportion of individuals. Naturally exposed to injury in the ordinary walks of life, the possibilities are vastly multiplied in those engaged in trades and manufacturing industries involving the use of machinery, steam and electricity.

Bruises or *contusions* of moderate degree accompanied by slight extravasation of blood in the tissues call for no further treatment than rest or the application of an ice-bag to relieve pain. Larger subcutaneous collections of blood require a long time for absorption and are liable to suppuration. It is advisable, therefore, to incise, remove the blood, wash out the pocket with salt solution, close the incision and put the part at rest. Contusions of special structures will be considered under their proper headings.

Open wounds vary in significance according to the parts involved and the liability to infection. The two chief dangers are hemorrhage and infection. The importance of the first dressing cannot be overestimated. No dressing at all is better than a dirty one. The value of non-interference and the danger of a tightly applied tourniquet are especially important. Extensive hemorrhage demands immediate attention; but, until the surgeon is reached, pressure applied over a clean dressing is recommended. The surgeon's duty should be to ascertain whether important structures are injured and to institute

proper measures for their repair, to check hemorrhage and to provide against shock and infection. The primary infection in many accidental wounds is slight, as in *superficial* or *clean cuts*. These may be cleansed with alcohol or iodine, treated as operative wounds and immediately closed. For such closure through-and-through sutures of silk placed by means of fine straight needles will be found most serviceable. These needles may be kept ready threaded, half a dozen basted in a piece of flannel and boiled when needed (Fig. 1). They can be passed with a minimum amount of pain, but the advantages of local anæsthesia are evident. It is well for one in the way of treating accidental wounds to familiarize himself with the various local methods which are especially applicable in surgery of the extremities, for the injury is exceptional which cannot be satisfactorily treated by their aid.



Fig. 1.—Reduced three-fifths. To show method of basting the threaded needles. Silk No C. Needle No. 7. We usually employ silk two sizes finer than this. (*Progressive Medicine.*)

Extensive lacerated or *crushed wounds* involving large areas of skin or deeper structures demand further consideration in view of the possibility of infection and shock. The danger of tetanus should be always in mind and in many cases a prophylactic injection of tetanus antitoxin should be given. Naturally the first question which arises is whether the arm can be preserved or is amputation necessary. Amputation should not be too hastily decided upon, for limbs which at first sight seem hopeless may be saved as useful members. Bones, muscles, nerves or vessels may be sutured and regain their function.

It may be wise to delay operative measures and carry out only those details which are immediately necessary. This is particularly true in accidents from machinery, explosions, or crushing of any sort where grease or foreign material is ground into the tissues. In these doubtful cases the first treatment should be limited to the cleansing of the wound and its surrounding skin, the ligation of bleeding vessels, and the removal of foreign material or torn and soiled tissues whose circulation has been evidently destroyed. The skin may be freed of grease or dirt by means of gasoline, turpentine or ether. The treatment of such wounds and the surrounding skin solely with iodine for cleansing and dressing is rapidly gaining in favor. Another popular method is the irrigation of the wound with sterile water and the application of a moist, mildly antiseptic dressing. Gauze saturated with a weak solution of bichloride of mercury (1–5000) may be used. Carbolic acid solutions should be avoided as a continued application, and bichloride should not be used after iodine because of the irritation produced. Pockets and cavities are drained with wicks of gauze covered with rubber tissue. In no case should sutures be tightly placed, and it is better to close the skin loosely with few stitches far apart. Conservatism is the rule at first until the viability of the tissues is determined, and the temptation to accomplish classical operations must be strictly avoided. Gangrene or extensive infection may demand amputation.

Avulsion of the arm is accompanied by great shock and calls for most conservative treatment. Bleeding is often slight because of the curling up of the intima of the torn artery; nevertheless the vessel should be caught and ligated. Projecting nerves should be injected with cocain or novocain and then divided high up so as to avoid the resulting scar; the protruding ends of bone should be excised. The skin is only loosely sutured and drainage provided.

Gunshot injuries of the arm demand immediate operation only for the control of severe hemorrhage or the removal of superficial splinters. Otherwise the small wound of entrance and the large one of exit may both be treated conservatively and repair of injured deeper structures made under favorable conditions. If infection occurs, drainage and open treatment will be necessary as in any infected wound.

Wounds of the forearm are concerned chiefly with the injury of nerves and tendons which will be considered later.

Wounds of the Hand and Fingers.—*Incised or stab wounds* which do not involve important structures need nothing more than cleansing

with soap, water and alcohol with a few minutes' soaking in bichloride followed by immediate suture. As few sutures as possible are used and caution is again urged against tying them tightly. A wet bichloride dressing is applied for 24 or 48 hours, after which it is replaced by collodion. The danger of grave infection following apparently trivial wounds of the hand and fingers should be ever in mind; hence the importance of the first dressing. Particularly dangerous are the wounds of nails, splinters or toy pistols, where infection is carried to the depths and the surface heals quickly. These should always be treated with pure carbolic acid or iodine and drainage provided. In most instances a prophylactic dose of tetanus antitoxin is indicated.

Lacerated and crushed wounds are most common among those working with machinery. Inasmuch as the working efficiency of the individual depends upon the result obtained, judgment and caution are demanded of the surgeon. Avoid the temptation to do typical operations and save as much as possible. Except in rare cases, open treatment is best. Where there is great laceration or crushing and the circulation in large areas is uncertain, preliminary treatment in a continuous bath of salt solution will often result in the preservation of tissues which appear hopelessly injured. In the *mangle hand*, a combined crush and burn seen in laundry workers, this is particularly useful.

The following technique for the treatment of finger injuries is recommended by M. B. Swift (Bost. Med. and Surg. Jour., 1912, CLXVII, 115) after an extensive experience with emergency surgery in a large industrial center. Fresh wounds are cleansed with turpentine on gauze, no scrubbing brush being permitted, no matter how dirty the wound or its surrounding parts. The wound is then washed with 95 per cent. alcohol. Protruding bone is removed to the level of the flesh. A single stitch is taken in the center to insure the bone being covered. The sides are left open for drainage. A 95 per cent. alcohol dressing is applied and over this oiled paper and a bandage. There were no infections in wounds treated in this way and useful and painless stumps resulted. Wounds already infected beyond the injury are treated by free incision (avoiding the tendon sheaths), bichloride soaking and wet bichloride dressings. In other clinics the routine employment of wet bichloride dressings have given equally good results. The important facts to bear in mind are that these should be as carefully treated as are wounds made on the operating table; that, as a rule, they should not be tightly closed; that infection, when possible, should be averted, and that amputation is the treatment of last resort and conservatism will be rewarded

by the saving of many useful limbs and the preservation of working efficiency. Portions of fingers completely severed may be replaced and regain their vitality. Finney reports an instance in which two finger tips were replaced seven hours after being severed with perfect result (J. H. H. Bull., 1892, III, 122).

Burns.—Burns of the hand are of common occurrence and like other wounds and injuries of these parts are of significance in that their results may determine the working efficiency of the individual. The signs, symptoms and degrees correspond to those in other regions. The fact that the region of joints is so often involved with resulting contracture or ankylosis renders their proper treatment important.

Treatment consists in combating shock in extensive lesions, the immediate relief of severe pain by morphia, and local applications to relieve pain, prevent infection and promote healing.

Superficial burns or scalds, where there is only reddening of the skin or bleb formation, are best treated by washing thoroughly with alcohol, opening and evacuating the blebs and applying sterile silver foil over which a dry sterile dressing is placed. This will be found to be a most comfortable and efficient treatment. Infection is prevented and healing rapid.

More extensive burns involving the whole thickness of the skin can be treated in various ways; but in general it may be stated that grease and oils (as the long used Carron oil) and dusting powders should be avoided. Treatment with no dressing at all, the parts being exposed to warm air, seems to be gaining in favor. For many cases in which dressings are painful or a line of demarcation slow in forming, the continuous bath is most comfortable and effective. Picric acid and bicarbonate of soda are perhaps the most popular applications. The consensus of opinion, according to Desfosses (Presse Medicale, 1912, No. 24, 248), is that the outcome of a burn depends on the first dressing. He recommends painting the burned surface and its surrounding skin immediately with tincture of iodine. Whatever application is used it is most essential to guard against adhesions and contractures about the joints and flexures during the healing process, by the placing of pads and the use of apparatus to maintain proper position, *i.e.*, abduction for burns about the shoulder, extension at the elbow, wrist and fingers. Sloughs are removed and granulating surfaces covered by skin grafts at the earliest possible moment, that motion in the joints may be encouraged, and massage instituted. The thin Thiersch grafts are most satisfactory for the arm and dorsum of the hand, but in the palm a flap

of full thickness gives a better result where the area is of any extent. Resulting contractures demand plastic operations which are at times most unsatisfactory. Destruction of the whole substance of any part of the arm naturally demands immediate amputation and extensive gangrene, through the dangers of toxemia, may do likewise.

Electrical Burns.—An individual coming into contact with an electrically charged wire may receive no other injury than apparently small burns of the hands and feet, the ordinary points of entrance and exit. A current of several thousand volts may thus pass through his body. These burns are of sufficiently common occurrence to deserve special consideration. The damage is usually much greater than appears at first sight and there is more shock than in ordinary burns; gangrene extends beyond the limits of apparent injury; sloughs are slow in separating and healing is prolonged. There is evidently an impairment of circulation about the burn which retards repair. The continuous bath will be found of the greatest value in these cases until a line of demarcation has formed, when amputation or excision of the sloughing area followed by skin grafting may be done. In superficial burns the ordinary treatment suffices. Burns from lightning stroke have practically the same characteristics.

Burns Caused by the Röntgen Ray or Radium.—There are two varieties of X-ray injuries, the acute burn and chronic dermatitis. Radium apparently produces similar changes. The *acute burn* was common in the early days of long exposure, but is at present rarely seen except from repeated exposures at short intervals. There may be no evidence of injury for a long time, when there appears reddening of an area of skin accompanied by pain. This extends and goes on to sloughing. Progress is slow and repair tedious. The approved treatment in lesions of any extent is excision of the whole area with a surrounding zone of healthy tissue followed by immediate or later skin grafting. It is not wise to excise too early, before the limits of sloughing can be accurately determined.

Chronic X-ray dermatitis is fortunately of less frequent occurrence, as experience has shown its dangers and protective methods have been developed for its prevention. It is seen most often on the hands of those working constantly with X-rays. The skin becomes dry, eczematous and atrophic. Macerated areas appear which are not only exceedingly painful but may become the seat of epithelial cancer. Porter (Jour. of Med. Research, 1909, XXI, 357) has collected 47 cases of carcinoma with a mortality of 25 per cent. He states that little can be done for

the dermatitis, but urges early excision and skin grafting of the ulcerated areas. In many instances amputation of the fingers or of the whole hand becomes necessary. Robert Abbe has recently found that these X-ray ulcers seem to be greatly benefited by treatment with radium.

Nerves.—Because of their superficial position the nerves of the upper extremity are exposed to trauma in all sorts of accidents, or they may be injured in operative procedures or by pressure from splints, crutches, etc. The actual lesion may be simply a contusion or stretching, a single puncture with hemorrhage or partial or complete division of the nerve. In the process of repair of wounds the nerves may be subjected to pressure from scar tissue or callus.

Division of a nerve is characterized by immediate motor and sensory paralysis in the area which it supplies, followed later by distal degeneration of the nerve. A puncture amounts to an incomplete division and recovery is rapid. In a laceration the nerve sheath gives way first before the fibers yield, and the torn fibers are apt to be widely separated. The division here is complete or incomplete and the symptoms vary accordingly. In incomplete division there may be hyperæsthesia, while in complete division there are varying degrees of anæsthesia owing to overlapping fields of nerve supply. Later come muscular atrophy and degeneration and various forms of trophic disturbances, as the "velvety hand," changes in the nails, ankylosis of the joints and ulceration or loss of the finger tips. In partial section, trophic disturbances may be entirely absent. Whether regeneration of the nerve does actually take place from the central portion only or from both central and distal portions is still a disputed question, with the weight of evidence from most recent experimental work in favor of the former view. From the surgical standpoint, it can be safely said that regeneration occurs only when the divided ends are approximated and so retained, and the earlier this is accomplished the better the prognosis. Recovery may occur without suture of the nerve, but this is rare and usually the ends remain separated by scar tissue.

Nerve suture may be done at the time of the accident (primary) or after the wound has healed (secondary). Suture should never be attempted in the presence of infection, primary union being absolutely essential to success. The nerve should be freely exposed and its ends freshened. In the case of laceration, excise the shreds, or in secondary suture, remove all adhesions and scar tissue and with a sharp knife cut across well beyond the bulbous tips to expose the normal nerve

fasciculi. The ends are then approximated by stretching, if the separation is not more than 2 or 3 cm. If this cannot be done, the arm may be shortened by resecting bone or various methods of bridging the defect, or nerve anastomosis may be used. Nerve transplantation has not proven satisfactory. Neuroplasty has given better results. Other attempts at bridging have been made by connecting the ends with strands of catgut carried through a tube of rubber, bone, or best of all, according to Tubby, a section of a blood-vessel (Lancet, 1909, II, 706). Better chances are sometimes offered by nerve anastomosis, connecting the distal portion of the divided nerve with a healthy neighboring one, remembering always to obtain end-to-end contact. In suturing the prepared ends the method and material are unimportant, but that which inflicts least trauma is to be preferred. The method of choice is to use sutures of fine silk which include only the sheath. These may be reinforced with tension sutures of catgut which pass through the substance of the nerve. If there is much tension on the line of suture the nerve should be supported by securing it to neighboring structures. The line of suture is further protected from adhesions and invasion of scar tissue from the sides by wrapping around it some such substance as Cargile membrane or, according to Murphy (Surg., Gyn. and Obst., 1907, IV, 385), by covering it with fascia, muscle or fat. Various other materials have been used, such as paraffin, gelatin, peritoneum, eggshell membrane, decalcified bone tubes or sections of blood-vessels. Absolute fixation of the arm for two or three weeks should be followed by massage, passive motion and treatment with galvanic current continued through a period of many months to maintain or improve the nutrition of the muscles during the period of repair and regeneration of the nerve.

The *results* are usually excellent, almost as good in secondary as in primary suture, provided secondary changes in the muscles and joints have not progressed too far. Some nerves seem to offer better chances than others, suture of the musculo-spiral having apparently furnished the best results. According to Murphy, "the result of nerve suture without infection and without the interposition of connective tissue can be made as uniformly successful as bone union under similar conditions."

The period of regeneration varies, the order of return of function being, first, trophic; second, sensory; and lastly, motor. Return of sensation is not to be expected before six weeks and motion from 10 to 12 weeks. Complete recovery may take years. Failure at the first attempt should not deter one from undertaking a second suture of the

same nerve. Successful suture with regeneration has been accomplished many years after the original division of the nerve, but the earlier the union is reëstablished the more rapid and certain the restoration of function.

Contusions.—In slight contusions, as in the common one of striking the ulnar at the elbow, there is no gross lesion of the nerve and the sensations of tingling or numbness pass off in a few minutes.

In severe contusions many or all the fibers may be severed and the symptoms and results are the same as in partial or complete division of the nerve. The nerve sheath may remain intact, in which case regeneration is apt to take place. On the other hand, the sheath may become so thickened or contracted as to amount almost to non-union of the nerve. The electric reaction is useful in prognosis. If the reaction of degeneration is present and there is rapid muscle atrophy, a long time will be required for recovery. If after a week or more the muscles still respond to faradic stimulation, rapid recovery may be expected. Treatment should be primarily directed to lessening inflammation by means of rest, compresses, etc. Later the same means should be employed as after nerve suture—massage, passive motion and the galvanic current. After a reasonable length of time it may be advisable to expose and explore the nerve. The condition may then be relieved by stretching or the removal of surrounding adhesions or, if the nerve continuity is actually interrupted by scar tissue within the sheath, by resection and suture. Horsley (Practitioner, 1899, LXIII, 131) advises waiting 18 months before resorting to secondary suture after primary healing of the original wound with nerve division. The same rule might apply in failure of regeneration after contusion.

Stretching of the nerves of the arm as an accidental affair is apt to occur in the brachial plexus. It may result in more or less complete division of the cords. Mild cases subside rapidly with rest. The more severe injuries cause paralysis, which will be considered later.

Compression of the nerves of the arm is a very common occurrence and may result from numerous causes; the most frequent is pressure of a crutch in the axilla or of the arm against the edge of the operating table, or under the head during sleep. A narrow tourniquet may be responsible or a tight plaster cast or splints. The nerves may be subjected to pressure from a dislocated humeral head or in fracture of the shaft of the humerus, or they may be involved in scar tissue during the process of wound healing. In addition they may be pressed upon by tumors, enlarged glands, aneurisms or cervical ribs.

The *symptoms* vary from slight tingling or numbness, or hyperæsthesia and slight muscular twitchings, to painful cramps followed by anæsthesia and paralysis with resulting degeneration and muscular atrophy.

Treatment ordinarily consists in the removal of the cause with subsequent massage and electrical stimulation. In some instances it may be necessary to expose the nerve and free it from adhesions and stretch it.

Brachial Plexus.—Injuries of the elements of the brachial plexus are not unusual and may be of any variety. They result in paralysis of a part or all of the arm according to the roots involved. Brachial paralysis may be the result of stab or bullet wounds or of pressure from tumors, cervical ribs, callus, crutches, etc. The most common cause is stretching or laceration of the plexus either over the head of the humerus as in anæsthesia paralysis, or more commonly by some pressure or traction which forces the head away from the shoulder. This is seen in brachial birth palsies and occurs also in adults. The lesion produced is a giving way of the nerve sheaths and partial or complete rupture of the nerve fibers at different levels. There is also tearing of the cervical fascia and hemorrhage into and about the nerves, so that not only are the torn nerves prevented from uniting by scar tissue, but there is pressure on the remaining ones. It has been shown by Taylor and others that the injury involves the roots from above downward and that the maximum injury is to the upper roots (Taylor and Casamajor, Ann. of Surg., 1913, LVIII, 577, and Clark, Taylor and Prout, Am. J. Med. Sci., 1905, CXXX, 670).

Paralysis may involve the whole arm, the upper arm or the lower arm. The common form is the upper arm palsy, or *Erb's paralysis*, which involves the fifth and sixth cervical roots. The paralyzed muscles atrophy and trophic disturbances may occur. Sensation is less impaired. There may be pain due to neuritis of the undivided nerves. The position of the arm is striking. It hangs by the side in adduction and inward rotation. It cannot be abducted or rotated outward. The hand is pronated and the elbow extended. Treatment should at first be directed toward lessening inflammation, assisting repair and maintaining the nutrition of the muscles. Improvement occurs as the undivided nerves resume their function and the symptoms become limited to the supply of those nerves which have not regenerated. After waiting a year in birth palsies or a few months in adult cases operative interference is indicated, as without this the prognosis is distinctly bad. A palpable thickening above the clavicle marks the seat of the lesion.

Operative treatment consists in exploration of this region, with removal of the scar tissue and such repair of nerve structures as may be indicated in the individual case. The damaged nerves are resected and the roots and trunks sutured end to end. In cases where the ends cannot be approximated, Taylor advises resection of the clavicle as an aid. The incisions and operative field are shown in Figs. 2 and 3. An immobilizing dressing is maintained for two or three weeks approximating the head and shoulder, after which the ordinary post-operative treatment of massage, etc., is instituted. Improvement is

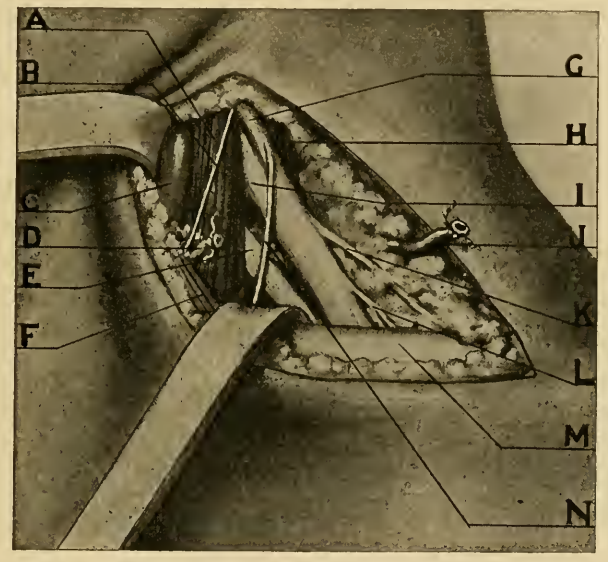

FIG. 2.—Dissection of the operative field in brachial birth palsy. A, Scalenus anticus muscle; B, phrenic nerve; C, internal jugular vein; D, transversalis colli artery, divided; E, VII cervical root; F, omohyoid muscle; G, V cervical root; H, scalenus medius muscle; I, VI cervical root; J, transversalis colli artery; K, suprascapular nerve; L, nerve to subclavian muscle; M, clavicle; N, nerve to scalenus anticus muscle. (*Clark, Taylor, and Prout.*)

slow but the results encouraging, although a perfect result is seldom to be expected.

Thomas (Ann. Surg., 1911, LIII, 77) believes that many of these palsies are due not to laceration of the brachial plexus in the neck, but to laceration of the axillary portion of the capsule of the shoulder. The extravasation of blood, lymph and synovial fluid gravitates about the nerves in the axilla giving rise to a non-infectious neuritis. He thinks, therefore, that the first therapeutic measures should be directed toward obtaining a return of normal motion in the shoulder-joint.

Brachial birth palsies are of the same type as the above with the same symptoms. The same operative treatment is advised and improvement may be expected, even after the paralysis has existed for many years.

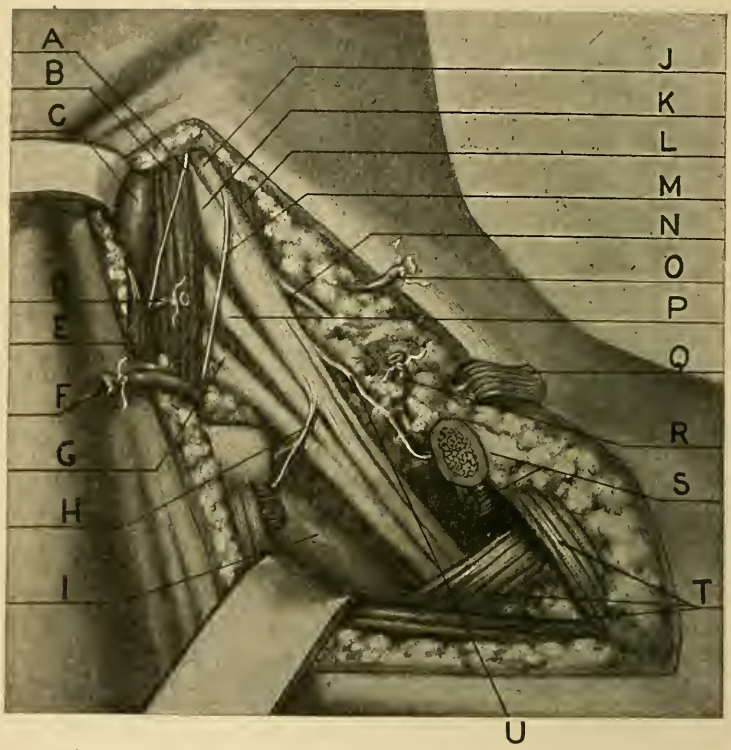

FIG. 3.—Dissection of the operative field in brachial birth palsy. A, Phrenic nerve; B, scalenus anticus muscle; C, internal jugular vein; D, transversalis colli artery; E, omohyoid muscle, divided; F, suprascapular artery, divided; G, VIII cervical and I dorsal roots; H, external anterior thoracic nerve; I, subclavian artery; J, V cervical root; K, VI cervical root; L, scalenus medius muscle; M, nerve to scalenus anticus muscle; N, suprascapular nerve; O, transversalis colli artery; P, VII cervical root; Q, omohyoid muscle, divided; R, suprascapular artery; S, clavicle and subclavius muscle, divided and retracted; T, deltoid, pectoralis minor, pectoralis major (muscles); U, nerve to subclavius muscle. (*Clark, Taylor and Prout.*)

Anæsthesia palsies are caused by forcible stretching of the brachial plexus over the head of the humerus as in the position in which the arm is often held in breast operations. One or all the nerves may be involved. As the lesion here is stretching rather than actual tearing, recovery is to be expected although it may be slow. No other treatment is required than massage, electricity, etc.

Circumflex Nerve.—This may be injured by a direct blow on the shoulder or in the reduction of a dislocation of the head of the humerus.

The characteristic paralysis of the deltoid muscle results. The lesion may be simply a stretching or a contusion without division, where recovery may be expected under rest, massage, etc. The nerve, however, may be completely divided when, after a reasonable time, operative treatment—incision and suture—may be attempted. On account of the small size of the nerve this is difficult and the outlook is not good.

Musculo-spiral Nerve.—This nerve is more frequently injured than any other nerve of the arm. Lying as it does in close proximity to the shaft of the humerus, it is especially liable to injury in fractures in the middle and lower thirds of this bone. It may be stretched or divided

FIG. 4.—Wrist-drop, due to pressure paralysis of the musculospiral nerve, either through being involved in a callus or caught between fragments in a fracture at the middle of the shaft of the humerus; in this case it followed too tight an application of an Esmarch constrictor. (*Eisendrath, Keen's Surg.*)

at the time of the fracture or it may be involved by callus in the process of repair. It may also be injured by pressure during sleep or upon the operating table during anæsthesia. A narrow tourniquet, a tight splint or the pressure of a crutch in the axilla may also be responsible, or it may be involved in wounds of the upper arm with other nerves.

The symptoms vary with the level of the injury, but as this is most often in the middle or lower third of the upper arm the deformity of wrist-drop is quite characteristic. The hand hangs in pronation and flexion and the fingers cannot be extended. Anæsthesia on the back of the hand varies and may be slight. Later, when the paralyzed muscles atrophy, the flexors prevail and a flexion contracture develops (Fig. 4).

Treatment.—In the ordinary crutch paralysis or other pressure forms, removal of the cause is, with the usual nutritional treatment, followed by recovery which may, however, be slow. In persistent paralysis from fracture or secondarily from scar tissue or callus, exploration is indicated.

The function of the musculo-spiral should always be tested in fractures of the shaft of the humerus, and in compound fractures without infection the nerve, if divided, should be immediately sutured. If infection is present this suture should be left till the wound is healed. The nerve is exposed well above and below the point of injury by a long incision between the external condyle and the deltoid insertion, and the necessary steps for its repair carried out—excision of scar tissue, or callus, or resection and suture as the case may be. After-treatment, as in all nerve sutures, is important.

FIG. 5.—"Ape hand." Deformity from paralysis of median nerve. (*v. Bergmann and Bull.*)

The results of suture are better in the musculo-spiral than in any other nerve of the arm—93 per cent. recoveries. Suture may be undertaken two or three years after the injury with a possibility of recovery. It must be remembered too that in the event of absolute failure of nerve regeneration the deformity can be improved by tendon-transplantation in the forearm.

Median Nerve.—Injuries of this nerve are particularly apt to occur in wounds near the wrist and in such cases its function should always be tested before suturing even an apparently superficial cut in this region, especially in wounds from glass. Injuries near the elbow or in the upper arm are less common, but may occur in dislocation of the elbow or in gunshot or lacerated wounds of the arm.

Symptoms.—The characteristic deformity is in the hand. Flexion of the second and third phalanges of the fingers is impaired and flexion, abduction and apposition of the thumb are lost. The thumb cannot be brought against the little finger but lies in extension and adduction. If the paralysis persists, there is atrophy of the ball of the thumb and

the flexor side of the forearm. The deformity is known as "ape hand" (Fig. 5). In division near the wrist, only the thumb muscles and the lumbricales are paralyzed. Anæsthesia of the lower part of the flexor surface of the forearm and the palm of the hand results from high division, while injury at the wrist is accompanied by the characteristic palmar anæsthesia of the first and second and half of the ring finger. The *treatment* of median nerve injuries is the same as that for musculo-spiral. The prognosis after suture, however, is not so good—about 80 per cent. recoveries. It has been successfully sutured by v. Bruns one year and nine months after injury.

Ulnar Nerve.—Next to the musculo-spiral the ulnar is most frequently the seat of injury, especially at the elbow in contusions or frac-

FIG. 5*a*.—Claw-hand. Griffin clutch of Duchenne. (*Fowler, Keen's Surg.*)

tures, or at the wrist in open wounds. Injury in the upper arm is rare. Paralysis is evidenced by loss of extension of the distal phalanges and flexion of the basal, by inability to adduct or abduct the fingers (interossei) and by loss of motion of the little finger. Persistence of the paralysis causes, by contracture, the "claw-hand" (Fig. 5*a*). There is variable anæsthesia of the palmar surface of the little and half the ring finger, and in long-standing cases trophic disturbance in the hand.

Treatment of these injuries is the same as with the median and ulnar. As to results, the ulnar gives the poorest outlook for recovery after suture and the little finger especially is likely to remain partly disabled.

Dislocation of the ulnar nerve from its groove at the elbow may occur as a congenital or habitual condition or may be the result of traumatism with or without fracture. The characteristic symptoms are severe darting pain in the region of the elbow into the distribution of the ulnar

nerve in the hand with numbness and tingling in the little and ring fingers. The pain is caused by both flexion and extension of the elbow by the nerve jumping over the tip of the internal condyle, so that there is entire disability for any kind of work necessitating the use of the arm. As a rule there is no anæsthesia or paralysis.

Treatment.—The idiopathic cases without pain require no treatment, but in the traumatic recurrent ones operative treatment alone will give relief. The operation consists simply in replacing the nerve in its groove and suturing over it a flap of fibrous tissue from the triceps fascia to hold it in place. Cobb (Ann. of Surg., 1908, XLVIII, 409) has collected 23 cases, including two of his own, in which operation has been done with excellent results.

Traumatic Neuritis.—Pain in the distribution of any of the nerves of the arm following trauma is very common and may be the result of a direct injury of the nerve at the time or may be due to the nerve being compressed by scar tissue. Trophic changes may follow and the process of degeneration extend toward the periphery from the point of injury. There is another form which often follows comparatively slight injury or infection of the hand or finger which assumes an ascending or centripetal form, and the resulting neuritis is far out of proportion to the original injury. It is, therefore, a progressive neuritis whose course is entirely incalculable from the onset.

The treatment of post-traumatic neuritis is at first palliative by rest, hot applications, etc., and later nutritional—massage, electricity and passive motion. If the condition persists, freeing and stretching the nerve will often bring relief. The treatment of the progressive form is often most unsatisfactory and the condition may assume the proportions of a chronic disease.

Vessels.—The blood-vessels of the upper extremity are frequently subjected to injury from contusion or bullet wounds or in open cuts and lacerations. The significance of these injuries naturally depends upon the importance of the particular vein or artery and treatment varies accordingly. If the vessel is of such size that its continuity is of importance in preserving the circulation of the limb, effort at repair should be instituted. If, however, collateral circulation is evidently sufficient, control of hemorrhage is all that is desired. Fortunately the collateral circulation in the upper extremity is so ample that the risk of gangrene is comparatively slight. Thus it is stated that ligation of the subclavian is followed by gangrene in the hand and arm in 2.01 per cent.; of the axillary in 6.6 per cent.; of the brachial in 18.75 per

cent., when applied immediately above the origin of the profunda. Below this point the arteries may be ligated without fear of gangrene.

One of the coats of an artery—usually the intima—may be torn subcutaneously by a contusion or there may be partial or complete rupture of all the coats. Such lesions may be caused in the axillary vessels by forces from without, by the dislocated humerus, or the direct impact of fragments in case of fracture. Attempted reduction of old dislocations is a common cause. The intima alone may be ruptured, in which case thrombosis takes place quickly and gangrene is threatened. There is pain and numbness in the hand and absence of pulsation in the peripheral vessels. If the diagnosis is made early enough it is advisable to cut down on the vessel, remove the clot, resect and suture (Bloodgood, Progress. Med., Dec., 1899, p. 187).

If thrombosis does not occur the injury may result in the formation of an aneurism. The brachial artery is seldom ruptured by blunt force, but more often its inner coats are injured with one of the above-described results.

The effects of contusions of the small vessels are of less significance because of abundant collateral circulation. In general the danger of gangrene is five times greater in the leg than in the arm.

Actual subcutaneous tearing of the axillary or brachial arteries is recognized by the increasing hematoma. It must be remembered, however, that there may be little bleeding in complete division because of retraction of the intima and plugging of the lumen, even in so large a vessel as the axillary. Absence of distal pulsation with symptoms of impending gangrene are suggestive. In either case exploration and repair or ligation are indicated. Injuries of the larger *veins* of the arm may result in thrombosis or hemorrhage. Occlusion of the veins, while causing great discomfort from swelling, is usually followed in time by compensation. Extensive hemorrhage demands exploration and suture or ligation of the vessel.

Bullet Wounds.—Injuries from the old soft bullets were serious because of extensive laceration of the involved vessels. Modern steel bullets cut rather than tear and may pass directly through a large vessel inflicting an injury which may be plugged by surrounding tissues. On the other hand, the axillary artery may be so sharply cut that there is no retraction of the intima and rapid fatal hemorrhage results. The statistics of recent wars show a large percentage of bullet wounds of the axillary and brachial arteries. While actual ligation is less often necessary with steel bullets, because of the clean-cut wounds, aneurisms are

more common. The vein and artery may both be injured with a resulting arterio-venous aneurism, a not uncommon occurrence in the axillary vessels. The treatment of bullet wounds of vessels is first confined to control of hemorrhage and the prevention of infection until proper operative conditions are obtained, when exploration should be done at the earliest possible moment and the injury repaired or the vessel ligated.

Open Wounds of Vessels.—With the exception of the axillary and brachial, little importance is attached to open wounds of the vessels of the upper extremity, for hemorrhage is readily controlled by pressure or the tourniquet until the injured vessel can be ligated. The development of vessel suture in recent years has revolutionized the treatment of injuries of the axillary and brachial vessels. These vessels are frequently opened in incised or lacerated wounds from various causes or in the course of operative procedures. Such injuries no longer always demand ligation, but are sutured and the continuity of the vessel retained. An instance of resection and end-to-end suture of the axillary artery severed by an accident recently, reported by Buchanan (Surg., Gyn. and Obst., 1912, XV, 648), serves as an example of the practicability of this procedure. Every surgeon should familiarize himself with the details of vessel suture, which has been placed upon a practical basis by the work of Carrel and others. The following technique of end-to-end suture is based upon Bernheim's description (Bernheim, Surgery of the Vascular System, 1913). For the history of the development of the method as for the surgery of the vascular system in general, one may refer to the classic article by Matas in Keen's Surgery (1909, Vol. V), or to the report of Monod and Vanvert (Revue de Chir., 1910, XLI, 784).

Technique of Vessel Suture.—Perfect asepsis and proper technique are essential to success. Rough handling and ragged wounds lead to thrombosis and failure. The armamentarium is small. There should be prepared suitable needles and silk, blunt-pointed forceps, a couple of rubber protected Crile clamps, medicine dropper, soft rubber syringe, and plenty of sterile salt solution and liquid vaseline. The needle recommended by Bernheim is a ground down No. 12 about 1 in. long and the silk No. 00000 either white or black. The needles are threaded with 12 in. of silk, stuck in pieces of paper with the thread wound in a figure-of-eight and its end fastened in a slit in a corner of the paper. These are placed in liquid vaseline in a flask, sterilized and kept sealed until needed. The severed vessel is freely exposed and

bleeding controlled by placing about an inch to either side of the point of injury a Crile clamp protected with rubber tubing. Branches coming off between these clamps are ligated and divided to permit free manipulation of the vessel. The vessel is then washed out thoroughly with salt solution injected with a rubber syringe. The adventitia which overhangs is trimmed well back from the edge of the wound, which must be clean cut and even. The vessel being washed clean with salt solution is treated inside and outside by means of a medicine dropper with liquid vaseline to prevent drying, and this washing and oiling should be continued throughout the remainder of the operation. The smooth ends are now approximated by three stay sutures placed at points equidistant around the lumen passing through all coats and tied with the knots on the outside. By drawing these taut and using them as retractors the round vessel is converted into a triangle. Each of the sides is sutured in turn by a continuous over and over stitch. At each stroke the needle passes through all three coats of each vessel end, starting on the outside of one and ending on the outside of the other. A knot is tied at each stay suture and all knots are placed on the outside of the vessel. The stitches are placed just far enough from the edge of the vessel to secure a comfortable hold on all three coats, the number of needle punctures depending on the size of the vessel. The blood flow is started gradually, removing the distal clamp first and protecting the line of suture by wrapping it with dry gauze and applying slight compression. There may be one or two little leaks and oozing from the stitch holes but these will usually stop after a few minutes' pressure, or it may be necessary to temporarily interrupt the blood flow and apply an additional stitch.

In all forms of vessel suture the technique is practically the same and attention to seemingly slight details goes far toward success.

Bursæ—Not only are the normal anatomical bursæ subject to traumatic affections, but bursæ may be actually formed by constant or repeated trauma, as over the middle of the clavicle from the irritation of a gunstock in military drilling. Of the bursæ of the upper extremity only the subdeltoid and the olecranon are often affected and that beneath the biceps tendon on the tuberosity of the radius but rarely.

Subacromial Bursitis; Subdeltoid Bursitis; Codman's Shoulder.—Codman (Bost. M. and S. J., 1906, CLIV, 613; 1908, CLIX, 533; 1911, CLXV, 115) has rendered an important service in calling attention to the fact that the vast majority of stiff and painful shoulders following traumata are due to an injury of the subacromial bursa. The condition

may be acute, subacute or chronic. The essential symptoms are tenderness on the point of the shoulder, just below the acromion and to the outer side of the bicipital groove; pain at the same point and down the outer side of the arm on attempted abduction; limitation of external rotation and abduction, the scapula moving with the humerus after about 10 degrees of motion. The pain is especially annoying at night and the patient is unable to sleep on the affected side. The lesions are acute traumatic bursitis and a partial rupture of the supraspinatus tendon. In old cases there may be a deposit of lime salts in the bursa.

Treatment.—In the acute stage rest and comfort are best obtained by keeping the arm in an abducted position. Fixation for more than a day or two should be strictly avoided in order to prevent adhesions. Massage applied to the surrounding muscles, but not to the bursa, is of value.

In mild subacute cases the same treatment applies. In the more severe cases where adhesions have formed there are three possible methods: (*a*) gradual stretching, massage, exercise, etc.; (*b*) manipulation under an anæsthetic with fixation in abduction; and (*c*) incision into the bursa and division of adhesions, or excision of the subdeltoid portion of the bursa. A spontaneous cure may be expected in any case in a few months or in a year or two; but where the pain is severe or disability great, relief may be obtained by a simple operation of little danger (Codman).

Olecranon Bursitis—Miner's Elbow.—As a result of single or repeated trauma of the elbow an acute or chronic inflammation is seen. The condition is common in miners who rest upon their elbows while at work, or it may be the result of apparently mild pressure as in a case of ours where the patient was in the habit of sleeping in a chair resting his elbow on its wooden arm. The contents of the bursa may be clear fluid or, from secondary infection, may become purulent. Simple cases will yield to the ice-bag, strapping or aspiration, or incision and drainage in case of infection. In chronic cases excision of the bursa under local anæsthesia is indicated.

Muscles.—Injuries to the muscles of the upper extremity may be subcutaneous in the form of contusions, sprains or ruptures; or open, incised and lacerated wounds.

Contusions are usually caused by blows from without or they may result from the impact of bones in fractures or dislocations. The immediate and remote results must be considered. The immediate effects are rupture and hemorrhage or muscle hernia, followed by an acute

myositis varying in degree according to the violence of the injury. The remote results of such injuries are ossifying myositis and sarcoma. In milder contusions there is tearing of a few fibers with slight hemorrhage which, with rest and massage, is quickly absorbed allowing a return to normal. Such injuries, which also include sprains and strains, are not uncommon in the deltoid, biceps or brachialis muscles of athletes and by them are grouped under the term "Charley horse," with similar injuries in the thigh.

In the more severe cases with extensive tearing and hemorrhage it may be advisable to evacuate the blood, as unabsorbed blood clots are replaced by scar tissue and according to location may more or less interfere with function. This scar can often be felt, and persistence of such a muscle tumor should call for an exploratory incision in view of the possibility of later ossifying myositis or sarcoma.

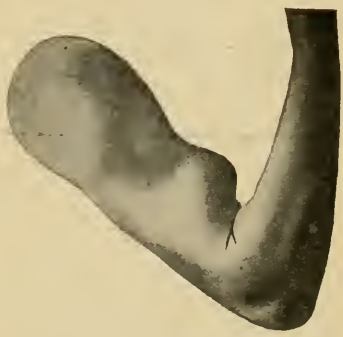

Fig. 6.—Rupture of biceps. (*v. Bruns.*)

Wounds of Muscles.—It has been shown (Caminiti, Cent. f. Chir., 1909, XXXVI, 894) that muscle fibers have little power of regeneration and that in the healing of divided muscles, gaps are filled by replacement with scar tissue. It should, therefore, be our chief aim to secure good approximation by catgut and guard against infection in order to obtain primary union. Incised or lacerated wounds are not uncommon in military practice and in accidents from machinery.

Hernia.—From violent or unusual contraction of a muscle there may be a rupture of the sheath which allows the muscle to protrude. Such lesions are less common in the arm than in the leg but may occur, especially in the biceps. If causing trouble, the hernial opening may be closed by suturing the fascia which has been freed and overlapped or by transplanting a flap of fascia from the thigh.

Rupture.—This may be complete and usually results from over-exertion or violent overstretching of the contracted muscle as in lifting a heavy weight or from throwing. Cranking an automobile is not an unusual cause as in a case of ours involving the biceps. It is accompanied by pain, hemorrhage and loss of function. Sometimes there is a sudden snap. A depression can often be felt marking the site of rupture and the proximal fibers contract forming a tumor or false her-

nia, which is most pronounced when the muscle voluntarily contracts. The biceps is most frequently affected, especially the long head (Fig. 6). Loos (Beitr. z. Klin., Chir., 1900, XXIX, 410) in 1900 collected 66 cases of biceps rupture and in 49 of 56 of these the long head was the seat of rupture. Bloodgood in 1912 (Prog. Med., 1912, XIV, 276) reviews the extensive literature of this and other muscle injuries. The triceps is less frequently involved than the deltoid, but the brachialis is often partly or completely ruptured in fractures or dislocations of the elbow.

Treatment.—In incomplete rupture satisfactory results may be obtained by rest and bandaging in a position which maintains the muscle in relaxation, or best of all by strapping with adhesive plaster. In complete rupture, however, early incision and accurate suture offers the best outlook. This is especially true if the injury is in the tendinous portion.

Myositis Ossificans Traumatica.—This interesting condition, recognized for a long time, has in recent years attracted considerable attention, especially in its distinction from and relation to sarcoma (Bloodgood, Prog. Med., 1913, XV, No. 4, 259). In the arm it is especially apt to occur about the brachialis anticus, as in a case reported by Finney (South. Med. J., 1910, III, 36).

Volkmann's Contracture—Ischemic Myositis.—This condition is properly included under traumata of muscles, although it has been a disputed point as to whether the chief injury is to muscle, nerve or blood-vessels. It is, in substance, a contracture of the wrist and hand which usually follows the application of a tight splint or cast to the forearm during the period of swelling after fracture or joint sprain (Figs. 7 and 8). The primary condition is generally conceded to be a myositis due to interference with circulation and inactivity of the muscle. The condition untreated results in permanent disability of the hand.

Bloodgood (Prog. Med., 1913, XV, No. 4, 254) emphasizes the fact that it is preventable and recommends early treatment at the first sign of myositis. He also reviews the treatment in later cases after the contracture is well established.

Treatment.—The original treatment of Volkmann of stretching under an anæsthetic survives today in Jones' method of treatment by means of manipulation and mechanical supports. Alexander (Ann. of Surg., 1913, LVII, 555) reports excellent results in two cases and gives details of the apparatus.

Various operative measures have been employed: dissection of the

involved muscles with freeing of the nerves, plastic elongation of the tendons or muscles, transplantation of muscle or resection of bone.

Tendons.—The tendons of the arm, forearm and hand are liable to the same injuries as are muscles and nerves. In the neighborhood of the wrist they are more subject to contusion, sprain and division.

Tenosynovitis Crepitans—Traumatic Tenosynovitis.—As a result of a direct contusion or single strain, or more often after repeated and long-continued overexertion of a muscle or group of muscles unaccustomed to this exertion, the condition may appear. There is swelling and pain on motion of the tendons and crepitation is apparent to the touch or with the stethoscope, much resembling the signs of pleurisy.

FIG. 7.—(*Progressive Medicine.*)

FIG. 8.—(*Progressive Medicine.*)

It is most common in the tendons of the wrist. It has always been looked upon as a dry synovitis, but in some cases it has been shown to be a peritendinitis. Neglected, the condition becomes chronic.

Treatment consists primarily in rest and fixation. We have found that the most comforting and efficient treatment in acute cases is to brush over the affected surface lightly with the Pacquelin cautery, apply a flannel bandage and fix the hand, wrist and forearm with light stave splints secured with a starch bandage. This gives almost immediate relief of pain. After four or five days it will be found that crepitation and swelling have disappeared, when massage and light motion may be started. In old cases it may be necessary to break up adhesions under an anæsthetic and then continue with massage, baking, etc.

Snapping Finger.—While the etiology and true nature of this condition have attracted a great deal of attention and are still unsettled, it is so often associated with trauma as to be included here. It is known as "jerking finger" or "trigger finger." The finger can be flexed to a certain point, when it meets with an obstinate obstruction which is passed with a jerk usually accompanied with pain, and sometimes accomplished only with assistance. The same may occur also with extension. Those cases which have been explored have shown the obstruction to be due to a localized thickening of the tendon or narrowing of the sheath or both. In two cases of ours both conditions were found and perfect relief obtained by dividing the constriction in the sheath. These both occurred in the left thumb and both followed a single trauma in the shape of a fall.

Treatment.—In mild cases massage may relieve. In marked instances, open operation and relief of the obstruction in tendon or sheath is almost always successful.

Sprains.—The term sprain is used to cover several different anatomical lesions; stretching and laceration of ligaments, laceration and avulsion of tendons, injuries of cartilage, etc. They may be caused by direct violence or from forced motion. The diagnosis of sprain is a dangerous one and should be made only after excluding by X-ray examination and every possible means any injury to bone, bursæ, etc. At the shoulder, true sprains are rare and injury to the subdeltoid bursa is too often put down as sprain. Here, as at the elbow and wrist or even in the fingers, fractures are often thus miscalled and maltreated. Sprains at the elbow are fairly common as a result of a fall on the hand or a twist of the forearm. There may be swelling about the joint, but the bony landmarks retain their normal relationship.

Tennis elbow is characterized by pain especially at the insertion of the pronator radii teres. It is due to tearing or stretching of the fibers of this tendon. A similar injury in rowing men is known as *sculler's sprain.*

At the wrist, where true sprains are most often seen, one must be careful to exclude a Colles' fracture. Sprains occur here on either flexor or extensor surfaces and may be complicated by tearing off of chips of bone at the insertions of tendons or ligaments. They are characterized by intense pain aggravated by any attempt at motion, by swelling due to extravasation of blood or synovial fluid in the joint or tendon sheaths, and by loss of function.

Treatment of all sprains consists primarily in absolute rest. During the early period of swelling, alternating hot and cold applications are

most soothing. The application of the Pacquelin cautery followed by a flannel bandage and fixation with crinoline or starch bandage and light splints will usually be quickly followed by cessation of pain. Caution against too long-continued fixation is urged. As soon as pain and swelling have disappeared, massage, hot and cold douches and light passive motion should be substituted for fixation in order to bring about early return of function and prevent adhesions. Old sprains require passive motion, exercise and massage, baths, hot compresses or hot air baking.

Division of Tendons.—Tendons may suffer division from contusions or sudden over-exertion without breaking the skin; or, as is most often the case in open wounds, cuts or lacerations.

Subcutaneous division, rupture or avulsion occurs most often in the upper arm and has already been discussed in relation to the biceps, triceps and brachialis anticus. Codman (Bost. M. and S. J., 1908, CLIX, 533) calls attention to the frequent partial rupture of the supraspinatus tendon in injuries to the subdeltoid bursa.

Subcutaneous division of tendons in the forearm and hand are uncommon. The lesion in "*drummer's paralysis*" has been shown to be in some cases at least a rupture of the tendon of the extensor longus pollicis, which has been weakened by continued or repeated attacks of tenosynovitis caused by the exacting use of this tendon with the drum stick. Open division is seen most often in wounds about the wrist or hand, and failure to recognize and repair a divided tendon is a common cause of disability. In the examination of even the slightest wounds in this region one should be absolutely certain of the continuity of the tendons before thinking of closure. Every divided tendon should be sutured, the one contraindication being the presence of infection, for primary union is absolutely essential to success. If there is already infection present when the wound is first seen, it is better to wait until the wound is healed and then reopen and perform the suture under better conditions. This may be advisable also where there is extensive laceration and possibility of sloughing. If the injury is first seen under conditions which render immediate suture impracticable or unsafe, it is here also advised to render first aid by aseptic treatment to prevent infection and do the suture later; inadequate treatment which may add infection is more dangerous than failure to suture.

The technique of a primary suture comprises the following steps: (1) Thorough cleansing of the wound, the removal of tags of tissue and the control of bleeding. (2) Identification of the tendons and securing the

retracted proximal stumps. It may be necessary to enlarge the wound in the line of the tendons. The ends when found should be secured by passing silk threads through them in order to draw them down. A fine-toothed forceps or artery clamp passed up in the sheath may often secure the stump and save an extensive wound. If part of the tendon has been destroyed so that the ends cannot be approximated the gap may be filled by a plastic operation. (3) Freshening of the stumps by a clean cross cut and suturing with fine silk by means of a round needle. Various methods of passing these sutures are recommended. The simplest method is to pass two sutures through the substance of the tendon at right angles to each other—one fairly close to the edge for accurate coaptation, the other at some distance to bear the strain. (4) Closure of the wound and immobilization of the arm in a position to relieve tension on the tendon. Passive motion may be begun in two or three weeks.

The Use of Local Anæsthesia.—The writer cannot refrain from mentioning here the great advantages of local anæsthesia in the treatment of these injuries. In the first place many of these occur in the course of severe accidents when the desire to avoid a general anæsthetic may prevent proper repair. Again the consciousness and cooperation of the patient are often of material assistance in the identification of tendons and the demonstration of their function immediately after suture. The forearm and hand are especially favorable and easy fields for local anæsthesia. Three methods are available. (1) Infiltration is generally sufficient. Novocain in ½ per cent. solution with suprarenin is freely injected in the skin edges, into the depths of the tissues and into each nerve and about blood-vessels as exposed. If it is necessary to enlarge the wound a further injection is made in the direction of the incision. The tendons themselves are not sensitive and the sheaths can be injected as encountered. We have frequently done tendon sutures in children without the slightest difficulty in this way. (2) In extensive wounds the nerves (median, ulnar and musculo-spiral) may be exposed and injected well above the wound when complete anæsthesia is obtained, or they may be reached by puncture through the unopened skin and anæsthetized by perineural injection of novocain in 1 per cent. solution. (3) A third method of obtaining anæsthesia of this region is by Bier's intravenous injection of novocain. Nowhere is this useful method so easily and satisfactorily applied as by utilizing the basilic vein at the elbow. In the case of the hand or individual fingers one of the superficial veins at the wrist may be used.

SECTION II

FRACTURES OF THE UPPER EXTREMITY

By

J. W. PERKINS, M.D., F.A.C.S.

FRACTURES OF THE CLAVICLE

Fractures of the clavicle are common, and may occur during intra-uterine life and in childbirth. They are very frequent in children and young adults. The most common cause is indirect violence—falls on the shoulder or against the rigid arm—but some result from muscular action and from direct violence. The bone is subcutaneous throughout its length; forming the only bony attachment of the upper extremity to

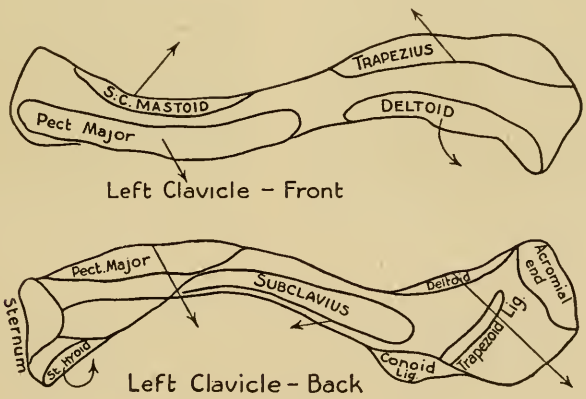

Fig. 9.

the body, and its principal function is to hold the shoulder out from the median line, giving it room for its varied movements. Incidentally it forms a base for muscles above and below it, and a knowledge of its anatomy and association is essential. Shaped like an italic *F* its inner or sternal end is triangular, the middle is round, and its outer end is thick and flattened from above downward. The weakest part of the bone is the middle third. Above are attached the sternohyoid, sterno-

cleido-mastoid and the trapezius. Below the pectoralis major and deltoid muscles (Fig. 9).

The sternohyoid, sterno-mastoid and trapezius muscles pass upward from the bone, while the pectoralis major and deltoid pass downward. The subclavius muscle running the whole length of the undersurface of the bone is attached at its middle and outer portions.

The outer end of the clavicle is firmly united to the acromion and coracoid processes by ligaments in three different places. The inner-end of the bone articulates with the manubrium sterni and the first rib. The articular ligaments are strong and one of them extends across to the opposite clavicle.

Direct violence may break the clavicle at any point but indirect violence does so at the weakest part, viz., in the rounded middle third of

Fig. 10.

Fig. 11.

Fig. 10.—Greenstick fracture in child.
Fig. 11.—Fracture clavicle in child. Characteristic deformity. Inner fragment rotated upward, outer rotated downward.

the bone. A blow on the shoulder or force transmitted through the rigid arm may rotate the upper extremity and compress or twist the clavicle, often causing long oblique and spiral fractures. In children, the fracture is usually transverse—often incomplete (greenstick) and sometimes multiple (Fig. 10).

The deformity produced is fairly constant, the arm falling downward, forward and medialward. The inner fragment is but slightly displaced, but if at all, appears as though displaced upward (Fig. 11). The inner fragment is sometimes torn loose from its sternal attachments (Fig. 16).

The outer fragment falls with the arm, which also is drawn medialward and forward by the Pectoralis major and the Latissimus dorsi.

The amount of the approximation of the arm to the body is measured by the overlapping of the fragments (seen in the X-ray, Fig. 13), or it may be measured from the suprasternal notch to the tip of the acromion, usually about 1 in., but occasionally 2. In its forward movement the shoulder rotates over the chest wall and exaggerates the deformity so that the superior surface of the clavicle becomes anterior. This rotation is more marked when the fracture is in the outer third, and may become as much as 90 degrees. If the fracture is outside the coraco-acromial ligaments. In the inner third deformity is usually much less marked and rotation slight. When between the coraco-clavicular ligaments it may be slight and diagnosis of the fracture difficult.

The attitude in a fresh case is characteristic—with his head inclined toward the injured clavicle, his face away from it, the victim relaxes the trapezius and raises the arm with his hand on the elbow

FIG. 12.

FIG. 13.

FIG. 12.—Fracture at outer end.
FIG. 13.—Oblique fracture middle clavicle. Much overlapping.

and his forearm supporting the forearm. The deformity is usually evident when seen early, but the greenstick fracture of children is not easily made out (Fig. 10).

Hematomata are sometimes excessive. Tenderness is always present at the site of the break, but at the extremities of the bone the X-ray must often be used to point the exact line of fracture. At the inner end the injury often simulates a dislocation, and is sometimes accompanied by a dislocation of the inner fragment.

Complications are relatively infrequent. Sometimes the sharp inner fragment sticks through the skin. The sharp outer fragment may wound the subclavian vessels or the brachial plexus where the cords pass

over the first rib, causing paralysis of more or less of the arm, but the subclavius muscle lies between and usually prevents this. The top of the pleura and lungs have been opened and the resulting emphysema may extend over the neck and body. Hemoptysis results as from a broken rib. Large hematomata are not rare, and may originate from

FIG. 14.

FIG. 15.

FIG. 16.

FIG. 17.

FIG. 14.—Fracture middle clavicle. View from behind.
FIG. 15.—View from in front after repair by dowel.
FIG. 16.—Fracture inner third clavicle. Dislocation inner fragment. View from behind.
FIG. 17.—Dowel (nail) fixation. View from in front.

both the smaller and larger vessels. The carotid has been pierced and cases of consequent aneurism have been reported.

Prognosis.—Union in children takes places in two to three weeks; in adults, three to five weeks. Non-union is uncommon, but follows double fractures and interposition of muscle and fascia.

Treatment.—First find the position of the arm in which the fragments come together without deformity. This is easily done by carrying the shoulder upward—outward—backward. Maintenance of this position is difficult. Three weeks in bed with a hard pillow under the shoulders permits of recovery with little deformity. The shoulder falls outward of its own weight and the arm can be raised on a lateral pillow so as to overcome the rotation. In children where there is little displacement Sayre straps are efficient if properly applied.

FIG. 18.

FIG. 19.

FIG. 18.—Comminuted fracture middle clavicle. Use of nail dowel with wire loop to hold middle fragment.
FIG. 19.—Shows absence of deformity and symmetry of shoulders.

If the fracture is very oblique and the displacement great, the Moore bandage gives fair results—shortening and deformity are the rule. These may be avoided by plating, or by the use of a bone or steel dowel (Fig. 15). Multiple fractures are often irreducible and the resulting deformity great. Here the open method is best. The bone is firm, and holds screws well. A thin plate or dowel is the best treatment. The resulting scar, placed superiorly, is negligible. Sutures by wire give unsatisfactory results on account of torsion. The most difficult cases are those outside the conoid-trapezoid ligaments, where the plate is of the greatest service and the functional results perfect.

Dressings like the Velpeau, manytail and Recamier bandages which hug the arm to the side are objectionable in that they maintain the deformity while keeping the arm at rest, but they are serviceable, when there is little or no deformity. Deformity and shortening is the rule with these dressings. Without the plates or dowels it is probably the most difficult fracture in which to obtain perfect results.

FRACTURES OF THE SCAPULA

Fractures of the scapula occur in four parts of the bone, viz., (1) the acromion and (2) coracoid process, (3) the glenoid, which may be chipped, split, crushed or separated from the body of the bone through its neck, with or without injury to the coracoid, and (4) the body of the bone and its spine. They are all the results of direct violence, well localized and intense, for the ready mobility of the bone, its lack of firm backing and its heavy coating of muscles protect the thin-shelled body and exposed processes.

There is a great difference in scapulæ; in some the borders are thick, the processes and spine are relatively heavy, and are often

FIG. 20.

FIG. 21.

FIG. 20.—Gumma of clavicle with fracture simulating sarcoma.
FIG. 21.—Fracture middle clavicle partly united. Amount of deformity after treatment by sling.

found bristling with osseous prolongations into their muscular attachments. These are not to be mistaken for splinters when seen in the X-ray. In others the bone is thin and its processes are diminutive.

The acromion unites with the spine of the scapula after the fifteenth year, and is more frequently fractured than any other part. Fracture through the tip outside the articulation with the clavicle involves no displacement. Crepitus can sometimes be found and abnormal mobility is always present. Ligamentous union often follows but causes no permanent disability.

A fracture through the acromion into the articulation with the clavicle or behind it, is much more serious, and calls for a careful use of the X-ray for its demonstration (Fig. 24). The immediate disability is marked, and under an anæsthetic crepitus can usually be found, but there is often little or no deformity. The importance of this in determin-

ing the usefulness of the shoulder makes an X-ray diagnosis of the injury highly desirable). From a tearing apart of the joint and its ligaments with or without a dislocation of the clavicle upward, it is difficult to differentiate it without the X-ray, but it is important, for the disability caused by the dislocated joint is considerable and calls for operative measures. Where the fracture of the acromion is behind the

FIG. 22.

FIG. 23.

FIG. 25.

FIG. 24.

FIG. 26.

FIG. 22.—Extensive comminuted fracture of scapula with overlapping fragments.
FIG. 23.—Fracture neck of scapula.
FIG. 24.—Fracture of acromion with separation acromio-clavicular joint.
FIG. 25.—Fracture of neck of scapula with dislocation of head humerus, due to a fall from wagon.
FIG. 26.—Complete fracture through body of scapula just behind glenoid. Large powerful man.

articulation, the outer fragment may be drawn down by the weight of the arm and rotated to a right angle with the inner fragment. Disability is marked.

The *coracoid* rarely breaks, but sometimes succumbs to a crushing blow after the clavicle has given way. Fracture from muscular effort

is very rare. The fragment is dragged down by the biceps' short tendon, and the X-ray is needed for diagnosis. The coracoid epiphysis unites with the scapula after the fifteenth year.

The *glenoid* may be separated along with the coracoid by a fracture through the suprascapular notch, which usually extends down to the infraglenoid tuberosity (Figs. 23, 25, 26). The arm falls away from the shoulder without flattening and closely simulates a dislocation, but there is no fixation of the movements of the shoulder, crepitus is readily detected, and the deformity returns as soon as the arm is released.

More frequently the glenoid is crushed, split or chipped by the impaction of the head of the humerus. This is difficult to recognize without the X-ray. A correct diagnosis is important in estimating the probable result of shoulder injuries in medico-legal cases, as the period of disability is prolonged after there is permanent interference with the joint functions.

The body and spine of the scapula does not break along the lines of least resistance, but along the lines of the fracturing force. This is usually so great that the fractures are multiple; hematomata are quick-forming and large, and exact diagnosis difficult without the X-ray. When this is used these fractures are amenable to treatment by plating, both of the spine and the axillary border which may be exposed and plated in the axilla (Med. Press and Circular, vol. XCVIII, Lane).

Deformity following these fractures is often negligible, as they are so well imbedded in muscles, but the period of disability is prolonged, and a perfect functional result is rarely obtained. Tenuity of the bone is probably responsible for the occasional report of scapular fracture by muscular action (Malgaigne).

Treatment.—In all these fractures fixation of the arm is necessary. The processes are readily wired or plated according to their size, as is also the spine and body. To keep the weight of the arm off the shoulder is indicated, but difficult. Folding the arm across the chest with the hand high on the opposite shoulder, pressure upward on the elbow with counter pressure on the shoulder, and slinging the arm from the opposite shoulder are available, and are useful according to the site of the fracture.

Union takes from three to six weeks. The estimation of the time and degree of resulting disability is difficult. In a general way, lesions around the acromio-clavicular joint and the glenoid take longer and there is a greater chance for permanent interference with functions than in the other parts of the bone.

HUMERUS

This bone may be broken by direct or indirect violence, and, as is well known, is the bone most frequently broken by muscular action. The age of the patient often indicates the variety most likely to be produced, but the X-ray is the quickest aid to exact diagnosis (Figs. 27 to 81).

FIG. 27.

FIG. 28.

FIG. 29.

FIG. 30.

FIG. 31.

FIG. 32.

FIG. 27.—Simple greenstick or "buckling" fracture of surgical neck in child.
FIG. 28.—Impacted fracture surgical neck.
FIG. 29.—Impacted fracture surgical neck.
FIG. 30.—Fracture surgical neck split through head.
FIG. 31.—Fracture surgical neck. Impacted. Old.
FIG. 32.—Impacted fracture. Head slightly turned.

Fractures of the upper end occur:

1. At the anatomical neck or through the head and neck.

2. At the surgical neck. This is usually taken to mean the upper fourth of the bone. Both 1 and 2 may be associated with fracture of

the tuberosities, one or both of which may be torn away from the shaft.

3. Separation of the epiphysis, possible up to the age of twenty-five.

Diagnosis.—Fractures in these three situations are fairly constant, but are often very difficult to diagnose with exactness unless the

FIG. 33.

FIG. 34.

FIG. 35.

FIG. 36.

FIG. 37.

FIG. 38.

FIG. 33.—Impacted fracture. Impacted neck.
FIG. 34.—Oblique fracture of surgical neck.
FIG. 35.—Oblique fracture of surgical neck.
FIG. 36.—Fracture surgical neck.
FIG. 37.—Oblique fracture of surgical neck with displacement.
FIG. 38.—Fracture of surgical neck with rotation of head and consequent outward displacement of shaft.

X-ray is used. The measurement of the length of the upper arm, generally taken from the acromion to the external epicondyle, will show a possible shortening. The presence or absence of the head in its socket is to be determined, and it is important to know whether or not it rotates with the arm. Under an anæsthetic the range of motion

can be tried. With the hand over the joint, gentle movements of the shaft in all directions sometimes give the clue to the exact seat of fracture. But with a fracture high up and the fractured surface of the head turned back, it may be impossible even to elicit crepitus.

Fig. 39.

Fig. 40.

Fig. 41.

Fig. 42.



Fig. 43.

Fig. 44.

Fig. 39.—Fracture of surgical neck with displacement of shaft and fracture of tuberosity.
Fig. 40.—Oblique fracture of surgical neck with parts held in good position by a nail.
Fig. 41.—Impacted fracture of surgical neck in boy of eight years.
Fig. 42.—Impacted fracture of surgical neck repaired by plate.
Fig. 43.—Comminuted fracture of surgical neck in girl of six years.
Fig. 44.—Comminuted fracture of surgical neck repaired by plate.

Interposition of muscles, great swelling, hematomata and impactions at various angles interfere and often prevent any exact knowledge of the injury. Fissure fractures through the head, with crushing of the cartilaginous surface, often found at operations, are not shown in the X-ray unless caught at just the right angle.

Pain, fixation, flat shoulder, sometimes shortening, and pain on pressure over the site of fracture are the common symptoms. Crepitus and pain on pressing the elbow upward may both be absent. The resemblance to a dislocation is often confusing but the loss of fixation is marked unless the fracture is impacted, and rotation outward is free.

Fracture through the anatomical neck is rare. It usually occurs in patients past middle age, and is due to a fall or a blow on the top of the shoulder. The shaft may be impacted in the head, or it may be dislocated into the axilla, or the end of the shaft may occupy the glenoid, with the head split and lying on either side. The greater tuberosity may be fractured by the same force. Dislocation of the head with subsequent fracture sometimes shows the fracture through the anatomical neck.

Fig. 45.—Dislocation of head of humerus with fracture of tuberosities. Five attempts at reduction of dislocated head. Appearance from in front four months after accident.

Fracture of the tuberosities occur as isolated injuries (mostly of the greater tuberosity) following direct blows or forcible outward rotation. They are also of frequent occurrence in connection with dislocations and fractures both of the anatomical and surgical neck (Fig. 39). Their presence often obscures the site of the main fracture in the X-ray, the free tuberosity overlying the break.

The tuberosities are torn away with comparative ease from the underlying bone, as the dense cortex of the shaft is not continuous over them, and the underlying cancellous tissue is often more attenuated than in any other part of the head, so that it is far easier to tear away the tendons with the tuberosities attached than to tear the tendons from the tuberosities.

Diagnosis is difficult without the X-ray. Sometimes crepitus and mobility of the greater tuberosity can be obtained. Sometimes the sharp edges can be felt, and a piece may lodge between the head and the acromion, locking the joint, just as a piece of condyle does in the knee joint. X-rays at various angles may be necessary to demonstrate the lesion. Many cases remain undiagnosed, passing as sprains

of the shoulder and are troublesome for years. They are to be suspected when the shaft is felt to be intact, and pain on rotation and pressure remain after days. Whether occurring as a complication or as an isolated injury, treatment should be by the open method and the tuberosity spiked to the bone. Recent cases of this injury treated in this way show excellent functional results.

Fig. 46.

Fig. 47.

Fig. 48.

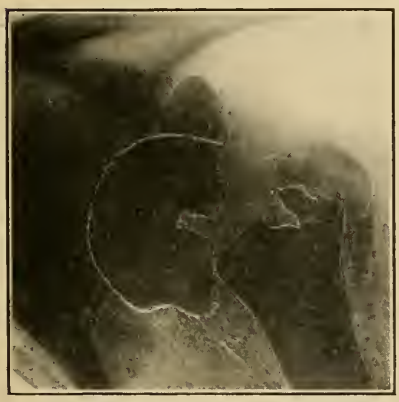

Fig. 49.

Fig. 50.

Fig. 46.—Fracture surgical neck with great displacement, shaft upward and rotation of head.
Fig. 47.—Fracture of surgical neck with sub-coracoid dislocation. Arm is useful.
Fig. 48.—Fracture anatomical neck with dislocation of head end of shaft in glenoid.
Fig. 49.—Subglenoid dislocation with fracture of tuberosity.
Fig. 50.—Subglenoid dislocation without fracture.

FRACTURES INTO AND AROUND THE ELBOW-JOINT

These must be considered collectively and separately. Multiple lesions frequently coexist, often associated with resulting dislocations. They occur in both young and old, as the result of direct and indirect

violence, are often difficult of diagnosis, and demand the highest skill in treatment to obtain good functional results. With the best of treatment there is often some limitation in motion or deformity about the joint.

The topography and skiagraphy of the normal elbow of the child and adult must first be understood.

1. The three points of bone, the internal and external epicondyles and the tip of the olecranon form a tripod on which the examination is based. When the elbow-joint is extended these three points are on the same level, lying in a plane at right angles to the shaft of the humerus, but the olecranon is posterior to the epicondyles. When flexed to a right angle, the three points form a triangle with the apex at the tip of the olecranon, and the three points lie in a plane, coincident with the shaft of the humerus.

2. The forearm, when extended and supinated, normally makes an obtuse angle with the arm, the angle opening outwardly, constituting a slight degree of valgus. This is commonly called the "carrying angle." It varies, in individuals, from 10 to 15 degrees, and there is often a marked difference between the arms of the same individual. It is generally greater in females than in males, and is less marked in children than adults. It disappears on pronation of the forearm, and on flexion of the forearm on the arm.

FRACTURES OF BONES OF FOREARM

Fractures of the bones of the forearm may occur separately or together.

1. Fracture of the shaft of the ulna in the upper third is a common injury, usually from direct violence. It is often compound and usually oblique. This is often associated with dislocation of the head of the radius, partial or complete. Often the dislocation escapes recognition until the fracture has united, when the arm is found to lock at a right angle.

This fracture-dislocation is as distinctive an injury as a Colles or Potts fracture, and is just as deserving of a distinctive name. The dislocation may take place forward and upward, outward, or backward. All three positions are illustrated (Figs. 103, 107, 108), also the method of fixation by a dowel pin and plate (Figs. 104, 105, 106).

Pringle (Fractures and Their Treatment, 1910, Fig. 112) pictures a similar fracture with unreduced dislocation forward.

If the ulna has overlapped so as to shorten the forearm, it will then be exceedingly difficult, if not impossible, to reduce the dislocated radial head, and it will be necessary to resect the shaft or remove the head in order to obtain flexion beyond a right angle.

Diagnosis is easy, as the posterior surface of the ulna is subcutaneous and the fracture easily felt. Shortening of the forearm occurs only when the radius is dislocated. This should be suspected when there is difficulty in maintaining reduction.

Prognosis is only fair. Union is often delayed or wanting, and the tendency to an angular deformity is considerable.

Treatment.—Great care should be taken in the reduction and one should be certain that the head of the radius is in place. Difficulty in reduction of the fracture may be due to the sharp ends of the bone picking up strands of fascia and needling them between the fragments. When this happens open treatment is called for. Open operation is necessary in a majority of these cases in order to obtain a good result. An internal angular splint with a right or obtuse angle (135 degrees) should be used with a flat splint on the back of the arm. The forearm should be set in supination.

2. Fracture of the shaft of the ulna and radius occurs both from direct violence, in which case, if both bones are broken, it occurs at the same level, or indirect, especially common in children, when the level of the two fractures may vary. The radius usually breaks higher up than the ulna. The fractures are generally transverse in adults, oblique or greenstick in children. The subcutaneous shaft of the ulna often penetrates the skin posteriorly.

The obvious deformity with pain and swelling makes diagnosis easy. Crepitus is a very variable symptom in children. In the greenstick variety there is no crepitus. In transverse fractures the periosteum may prevent crepitus, even although the deformity may be marked. The deformity consists in an exaggeration of the normal outward bow of the radius and the arm is convex forward, sometimes giving a corkscrew appearance to the forearm.

These fractures are often overlooked in fat children until the continuous disuse of the arm draws attention to what has been considered a sprain.

Fracture of the shaft of the ulna alone, results from a direct blow or when the arm is raised for protection, or to guard the body against a fall. The bone is driven inward and the fracture may vary from a mere fissure to one with much comminution. The diagnosis is easily made

by palpation along the subcutaneous edge of the ulna, if there be displacement, but fissure fractures require the X-ray.

The fissure may be on the internal or external aspect. Swelling of the forearm is sometimes slight but often very marked. There is no shortening, the unbroken radius serving as a splint in maintaining the shape and length of the arm. Rotation is possible but difficult and painful. Displacement due to muscular pull is slight.

Fracture of the shaft of the radius alone also results from direct violence, and may vary as in the ulna, from a fissure to a much comminuted bone. Surrounded by muscles it is not so easily felt as the ulna, but the displacement is often great, due to the muscular attachments. Crepitus cannot always be obtained; the head of the radius does not rotate if the fracture is loose, but does if it is a fissure. Voluntary rotation is possible but painful. Displacement depends on the site of fracture.

In the upper third of the bone the pull of the biceps supinates the upper fragment, while the lower fragment is pulled inward and pronated by the pronator radii teres and pronator quadratus. If the fracture is below the middle of the bone, the upper fragment is pulled upward and inward by the biceps and pronator radii teres, while the lower fragment is pulled toward the ulna by the pronator quadratus.

Prognosis and Treatment of Fractures of the Bones of the Forearm.—Union generally takes place in four to five weeks, but non-union is not uncommon and is due to interposition of slips of fascia or muscles drawn between the fragments, or to comminuted fragments turned sidewise.

In no fracture does correct treatment stand in closer relation to good results both as to union without deformity and functional perfection. The problems are many and varied as in no other part of the body. Compound fractures in the forearm are common on account of the subcutaneous situation of the ulna and infections are frequent. The outer ends of the bones penetrate the skin and are often reduced by bystanders, carrying infectious material into the forearm when it is imprisoned behind the bone. In one case a ball of horse manure was thus forced into the tissues and not discovered until the onset of tetanus. In all compound fractures, no matter how small the opening, the hole should be enlarged, the bone turned out into the position it occupied after fracture, and the cleaning of both sides and the cavities should be most thorough.

The occurrence of an open wound removes any qualms about treatment by the open method and it should be adopted in its best applica-

tion. Greenstick fractures should be made complete by bending the arm forcibly at the seat of fracture until the bone cracks, and then backward until it is completely broken. Marked deformity is the rule when one attempts to treat a greenstick fracture without making the fracture complete.

Reduction of the bone is usually obtained easily by making forcible extension in the line of the forearm. Recurrence of the deformity after the ends are in place means the interposition of fragments, slips of fascia or tendons, and calls for the open method.

There are some facts in regard to the anatomy to be kept in mind, and the pull of the muscles should be understood. The action of the pronators and biceps has been already mentioned. The bones of the forearm are not straight, and the unbroken arm should be first examined to determine any possible deviation from the normal. The subcutaneous edge of the ulna usually presents a straight line from just below the olecranon to the styloid process, but is sometimes curved markedly. The radius normally curves outward when the hand is in supination, but one finds frequently that this curve is greatly exaggerated, and a straight setting of the curved bone throws the plane of the wrist-joint out of proper alignment. Recovery with a straight arm but a functionally poor wrist is to be reckoned a bad result. Always must the function of the wrist-joint be kept in mind.

After reduction the position in which the arm is to be placed has to be determined. If the open method is used and the fracture plated, it should be placed in the most comfortable position and confined with light retention splints. The "thumb to chin" position, where the arm is halfway between supination and pronation, has been considered acceptable in most cases. In this position the space between the bones is at a maximum, and on that account it is not always possible to get a good result.

In the above-mentioned position the outward curve of the radius and ulna normally keep the interosseous membrane taut. When the bones are broken they approximate, the membrane becomes at once slack and trouble arises, unless plates are used. Swelling and ecchymosis into the tissues shortens the interosseous membrane abnormally, so that it is better to use the supine position in which the bones are more nearly parallel, and in which the straight subcutaneous edge of the ulna can be used as a guide for fixing the deeply placed radius, the styloid process of which acts as an indicator of its complete supination.

The danger of Volkman's paralysis is always to be kept in mind and

tight bandages avoided. Tight bandages and narrow splints also favor the approximation of the bones. The danger of a fusion of the two bones, where the fracture is at or near the same level, is an ever present one, also the possibility of different degrees of rotation of the bones where treatment is undertaken other than in the position of extreme supination. To maintain this position it is necessary to fix the elbow-joint at a right angle.

With the fracture reduced and the forearm in supination a posterior splint should be applied, extending from the elbow to the metacarpo-phalangeal articulation. The splint should be held by adhesive straps, one at each end of the splint, one over the styloid, and one in the middle of the forearm. An internal angular tin splint should then be used to maintain the supination. The hand must not be left loose as it furnishes the best leverage for supination. The loose hand undoes all efforts to maintain supination. A wooden interosseous splint is of service in maintaining the position and keeping the bones separate.

Fractures of the radius or ulna alone are to be treated the same as fractures of both bones. Especial care should be exercised in obtaining a good primary "setting" which may be very difficult.

Fractures of bones of the forearm in children which have been left poorly reduced and out of line are often found nearly if not quite straight and with shortening entirely compensated after a year or two of growth.

3. The head of the radius is subcutaneous posteriorly and is to be felt just below the external epicondyle when the forearm is extended, and in front of it when flexed to a right angle.

4. Lateral movements of the elbow are not possible in the adult but are often marked in children, varying greatly. The normal amount in any case is determined from the uninjured elbow. The skiagraphy of the normal elbow at varying ages is important, and is best demonstrated by means of illustrations.

The injuries which may occur about the elbow are:

1. Supracondylar fracture.
2. Separation of the lower epiphyses.
3. Fracture of the internal condyle and trochlea.
4. Fracture of the external condyle (capitellum).
5. T- or Y-shaped fracture into the joint.
6. Fracture of the olecranon (ulna).
7. Fracture of the coronoid (ulna).
8. Fracture of the head or neck of the radius.

9. Dislocation of the ulna.
10. Dislocation of the radius, partial or complete.
11. Fracture of the upper third of the ulna with dislocation of the radius.
12. Sprains of the elbow.

In the *examination* of the injured elbow, note first the situation of the tenderness, swelling and ecchymosis, the position in which the patient holds the arm, and the general outline of the elbow.

Note the direction in which the elbow can be moved without pain, and that in which motion is painful. Note crepitus and its situation. Dislocation of the ulna backward or laterally is apparent, simulated by supracondylar fracture, in both of which the elbow goes backward and the forearm extends.

Under an anæsthetic locate the crepitus if present, then the relation of the three points at the elbow is to be determined. Examine the uninjured elbow with the forefinger on the tip of the olecranon, and the thumb and middle finger on the adjacent condyles. Get the relation first with the arm flexed, then extended, if they remain in their normal relation in the injured arm it will exclude a dislocation of the ulna, or a fracture of either condyle or olecranon. Maintenance of the normal relation with appearance of a dislocation means a fracture of the lower end of the humerus.

Widening of the distance between the condyles, but with an otherwise normal relation, means an intracondylar fracture, always associated with fracture of the lower end of the humerus. If the head of the radius rotates normally in its proper position in front of the external condyle, it excludes a fracture of the head or neck of the radius, or a dislocation of the head.

In fractures of either condyle the corresponding bony point is lost or its position distorted; the arm can be bent laterally toward the broken condyle and the carrying angle is lost.

Gross fracture of the olecranon is at once manifested on flexing the arm by its separation from the shaft, but small pieces may be held intact in the triceps tendon.

X-ray examination of the elbow is of importance, both before the arm is set and after. Pictures should be taken in three positions if possible—from before, backward and from each side. It must be noted that the X-ray is often confusing and different angles may have to be employed, as the shaft of humerus may hide fragments. Often it apparently bears little relation to the schematic pictures, because of the

varying displacement of the pieces and the disappearance of some of them behind the shaft.

1. **Supracondylar Fracture.**—This occurs (*a*) from falls on the hand with the arm extended, called by Kocher the extension variety; (*b*) from a fall or blow on the elbow when the arm is flexed (flexion fracture). The extension fracture is oblique from behind, downward and forward, the sharp upper fragment being driven into the tissues of the bend of the elbow, where it often becomes compound anteriorly or laterally. It may injure or cut the brachial artery, the radial and median nerves. As the arm falls after the fracture, it is usually carried to the inside (body side) and rotates inward so that the sharp end of the upper fragment can be felt or seen under the skin of the outer side of the elbow. The elbow goes backward and simulates a dislocation.

In the flexion variety the bone is broken obliquely from in front backward and downward. The sharp end of the lower fragment can be felt in the bend of the elbow and cuts its way through arteries and nerves as before, but from below upward. Its resemblance to a dislocation is marked. The upper fragment seldom penetrates posteriorly, as it is protected by the strong tricep tendons, but it often injures the ulnar nerve.

In both varieties of supracondylar fracture the diagnosis from dislocation is easily made (1) by the crepitus, (2) by the immediate recurrence of the deformity when reduction is made. Great care should be exercised in the examination not to injure the vessels and nerves. Spicules with sharp, cutting edges are common. The same advice applies to the determination of possible nerve lesions in this fracture before setting, as has been given in regard to injuries at the shoulder. It is better to examine for and demonstrate a possible nerve lesion before treatment, rather than to have the patient demonstrate it afterward.

2. **Separation of Epiphyses.**—These occur in children from direct violence or hypertension. The possibilities vary with the age of the patient (Fig. 70).

There are four points of ossification:

1. Capitellum, appears at two years.
2. Internal condyle appears at five years.
3. Trochlea appears at 12 years.
4. External condyle appears at 13 to 14 years.

The centers comprising the trochlea, capitellum and external condyle blend together and unite with the shaft at 16 to 17 years. It is this blended epiphysis which is most often found separated. After the eighth year a displacement of the capitellum and external condyle

together may occur. After the thirteenth year there are only possible epiphyseal separations of the three coalesced nuclei (external epicondyle, capitellum, trochlea) and the internal epicondyle.

From the sixteenth or seventeenth year and up to the eighteenth or nineteenth, only epiphyseal separation of the internal condyle is possible. Up to the eighteenth year when there is a fracture in the neighborhood of the elbow-joint the chances of its being epiphyseal are about 25 per cent.

Separation of the epiphysis may be purely intra-articular. The fragments may go forward or backward according to the direction of the force. The capsule is sometimes torn and the fragment is found outside. A portion of the diaphysis may adhere to the epiphysis, epiphyseal separations are often associated with fractures either of the epicondyle or of the epitrochlea. In these cases, of course, the fragments are found outside of the joint. On examination of the elbow there will be found abnormal mobility to both sides laterally as well as forward and backward. Crepitus when present is always soft in character, but it is often absent. The X-ray examination is indispensable to show the exact points of fracture. Without this the age of the patient may give the clue as to what has happened.

3. **Fractures of the Internal Condyle (Trochlea) and Epicondyle.**—These generally occur between the ages of 10 and 20, and as indicated above are separations of the epitrochlea epiphysis with or without some of the diaphysis attached. The ulnar nerve is often injured by the fragment, either through pressure or by cutting.

Fracture of the Internal Condyle is Common in Adults.—The line of the fracture begins at the inner border of the humerus and passes through the olecranon fossa and the trochlea, but may extend across into the capitellum.

Displacement occurs upward, inward and backward. The ulna moves with the fragment and usually takes the radius with it. If the force is sufficient the forearm twists inward, toward the body and hangs helpless, giving the appearance of a dislocation, but without fixation.

Isolated fracture of the trochlea may occur as an independent lesion. The fragment lies loose in the joint and is discoverable by the X-ray.

Diagnosis.—In the examination the three bony points are found out of line—the finger on the internal condyle being posterior and high above the horizontal line. Lateral mobility of the forearm to the inside is marked, and if the swelling is not too great the broken fragment can often be caught between the thumb and fingers.

4. **Fracture of the external condyle** is the most frequent of all the fractures about the elbow, and is the common accident of childhood, comparing with the Colles' of adults. It is produced (*a*) by falls upon the hand, the force being transmitted through the radius directly against the capitellum; (*b*) falls on the elbow in such a way that the olecranon is driven against the capitellum, (*c*) direct violence applied to the condyle.

The epicondyle is rarely fractured alone and this by direct violence. It need not be considered apart from the condyle.

In most cases the line of fracture begins above the epicondyle and passes obliquely downward and inward, taking the whole of the capitellum and a portion of the trochlea. The arm rotates inward carrying the fragment forward and upward. The rotation of the fragment is often excessive, sometimes as much as 180 degrees, and a partial dislocation of the ulna often is found with it, when the force has been applied to the olecranon. A fracture of the olecranon is also often found associated and the internal lateral ligaments are often torn across.

In the examination, the three bony points are out of line, the external condyle usually found higher and forward of its normal position. The carrying angle is increased and the arm can be easily adducted. The fragment can usually be taken between the fingers, but crepitus is not always easily obtained owing to the rotation of the cartilage-covered surface against the line of fracture on the humerus. The arm often cannot be flexed above a right angle.

The musculo-spiral nerve which passes directly in front of the capitellum is often subjected to pressure or injured, the position of the fragments in front of the joint locks the joint, preventing the movement above a right angle. This affords one of the most important indications for treatment.

5. T- or Y-shaped fractures (Figs. 63–64) into the joint resemble in most respects the supracondylar fractures, but are produced by a greater force and are often compound. In the examination, however, the outer bony points (epicondyles) are found widely separated and the olecranon is sunk more or less between them. Lateral movements of the elbow are free in both directions, and the fragments often can be grasped and moved separately. An X-ray is most desirable unless the open operation is decided upon at once. This is one of the most difficult of the elbow fractures to treat with good functional result.

6. Fractures of the olecranon occur from direct violence, rarely from muscular action. One of the jiu jitsu tricks sometimes results in this

fracture. The left wrist of an opponent is grasped by the left hand and strongly pronated as it is jerked forward when a blow from the right fist on the elbow dislocates the joint or breaks the olecranon.

Hyperextension from other causes or by a fall upon the hand with the arm extended may also result in fracture of the olecranon. Produced in this way the fracture is often associated with a forward dislocation of the ulna and radius.

This fracture usually occurs in the middle but may occur at any point along the process. Separations at the epiphysis may occur. The epiphysis unites with the shaft at about the sixteenth year.

The fragment may be closely held by the muscular and tendinous attachments so as to allow little if any separation (Fig. 92), or these may be extensively torn and the fragment drawn upward by the tonicity of the triceps (Fig. 93). In this case the lacerated attachments fold in between the fragment and the ulna, and reposition is difficult or impossible. Non-union may result.

In the examination, pain on pressure over the site of fracture, and pain on extension with inability to completely extend, are found. Where there is much laceration of the attachments and wide separation of the fragment, ability to extend may be nil. Flexion is possible and the arm may extend from its own weight. Swelling may be marked, the bursa pouching out enormously with blood, but the fragment can often be grasped, and the sulcus felt.

Associated with this injury one may find (1) dislocation forward of the ulna and radius; (2) fracture of the head of the radius; (3) fracture of cartilaginous portions of the condyles of the humerus which may be left free in the joint.

7. Fracture of the coronoid process as an isolated injury is rare, but is more often found associated with other injuries about the elbow, especially posterior dislocation of the ulna. The fragment detached is usually small and is pulled up in front of the joint by the brachialis which is attached to it.

In the examination it is seldom felt on account of its small size but its presence may be suspected by an otherwise unexplained interference with forced flexion. Pain on pressure is felt about an inch above the joint, and is increased by flexion. If much of the process is gone the posterior dislocation recurs easily. An X-ray will confirm the diagnosis, provided it is taken with special reference to the fragment which is small and easily overshadowed by the denser bone against which it must not be projected.

8. Fractures of the head or neck of the radius are not uncommon. They follow falls upon the hand and occur as isolated injuries as well as associated with other injuries about the joint. The head may be (1) split (fissure) and the fragments remain in place, or (2) a greater or less portion of the head may be fractured obliquely into the shaft, or (3) the fracture may take place through the neck, which may or may not be impacted (Fig. 90).

Where a piece is split from the head it may dislodge into the joint. A larger portion with the biceps attachment may be pulled up in front of the joint. If the fracture occurs between the biceps attachment and the head (neck) the *lower* fragment is pulled up by the biceps, and the upper fragment (head) rotates upward and a little outward.

In the examination pain on pressure over the upper end of the radius is marked. If a fissure the head still rotates, but if the fragment is detached it escapes from the annular ligament and does not rotate. Sometimes crepitus can be obtained on rotation. The projecting end of the upper fragment can sometimes be felt in front of the joint. Flexion is incomplete and very painful. Rotation painful. The X-ray will show the lesion, but must be taken with special reference to this lesion. A fissure will often be hidden. Late pictures are often obscured by excessive callus formation. Permanent loss of rotation often follows.

Dislocation of the ulna and radius occur most frequently in children and young adults from falls on the hand, sometimes from direct blows on the elbow, and must be considered in the diagnosis of elbow injuries. The bones may go together forward or backward of the humerus, or laterally; or they may be dislocated divergently, the ulna backward and the radius forward or to the side, the radius to the outer, and the ulna to the inner side.

Dislocation of the radius alone takes place commonly in young children by lifting them by the arms, and is a common complication of fracture of the ulna in the upper third, and of fractures about the joint produced by direct violence. These dislocations are considered elsewhere, but must be kept in mind in the consideration of all fractures about the joint.

9. Fracture of the ulna in its upper third, with dislocation of the head of the radius forward is a common injury. It is the result of direct violence. Its importance is suggested by the frequency with which the dislocated head of the radius is left undetected until revealed by the attempt to flex the arm after the ulna is reunited (Fig. 109).

Complications of injuries about the elbow are many. The swell-

ing sometimes becomes so great as to imperil the integrity of the arm below, and is due primarily to hemorrhage into the tissues and thrombosis of the veins, with resulting œdema, blebs and bullæ. In these cases multiple incisions or the open treatment provide the necessary drainage, the circulation in the parts below is restored and the swelling disappears. The artery is sometimes torn and more often occluded by tight splints.

Volkman's contracture is the immediate result of rupture or compression of the artery. It may occur after any severe injury in the vicinity of the elbow, and may be due to the injury itself or to injudicious subsequent treatment. It has been found in cases where neither splints or bandages were used, the brachial artery being torn by a condylar fracture, but it undoubtedly has more often followed the injudicious application of splints which have served to occlude an otherwise open artery. In the latter, it is usually found associated with pressure sloughs on the front of the forearm near the elbow, and the sloughing may extend to the bones. The ulnar has been known to slough in its entirety. The condition is a serious one for it quickly involves the integrity of the arm and permanently impairs its usefulness.

Volkman's paralysis is an ischæmic myositis. There is no doubt of a nerve involvement in the majority of cases, although it was Volkman's contention that the muscles only were involved. When the blood-supply of the arm is shut off the muscle substance coagulates and an exudate into its substance occurs, causing a contraction of the muscle similar to rigor mortis. This rigidity is marked from the first, differentiating it from the contractions due to nerve lesions alone, which come on late. The ischæmic muscle is slowly replaced by scar tissue and contracts. Unless remedied early the contraction remains as a permanent lesion.

The effect on the nerves is similar, but comparatively few observations have been made of the early lesions. Later the median, ulnar and interosseous have been found embedded in scar tissue, smaller than normal and evidently atrophied by pressure. Relief of pressure by dissection of the scar tissue has been followed by recovery of nerve function in these cases so that it is evident that the integrity of the nerve has not been lost, as is the case with the muscle substance. This is of importance in considering the subsequent treatment.

The *symptoms* come early and are severe (Fig. 97). Pain in the hand and arm is almost intolerable, swelling great, and the skin becomes purple and covered with blebs. If the occlusion of the artery is not re-

lieved, the hand within 24 hours assumes the claw-like appearance which is subsequently found to be characteristic of the lesion, and especially where tight splints have acted as the cause, the skin and underlying parts are found necrotic.

The flexor muscles on the ulnar side of the forearm are chiefly involved (Fig. 101). Their condition suggests post-mortem rigidity. The fingers may be flexed tightly into the palm, or if the extensors are involved the two terminal phalanges will be flexed and the proximal extended, with the wrist partly flexed.

If the nerves have been involved primarily, loss of sensation in their distribution will be found. Secondary involvement of the nerves, usually the ulna or median, takes place through their compression by scar tissue as already noted. In the examination of these cases the sensation of the arm should be charted so that a record can be kept of any changes.

The later stages of Volkmann's contracture are easily followed. The muscles atrophy and contract until they are mere bands of fibrous tissue and the arm assumes the position shown in Fig. 102.

By forcibly flexing the wrist the fingers can be extended more or less, while by forcibly extending it they become more tightly flexed. The arm may be pronated and incapable of supination.

Treatment in the early stage should be directed toward freeing the circulation. Pressure by fragments, splints and bandages should be removed as early as the condition is suspected. In all elbow injuries inspection should be made at intervals of a few hours for the first two or three days, and the splints removed or loosened at least once every 24 hours, when the muscles can be moved and massaged if necessary and all joints moved.

If much swollen and the integrity of the arm appears to be in question, multiple small incisions into the soft parts will relieve the œdema and venous congestion. Anastomosis of the artery may be attempted if it is found crushed. Removal of the clot from an occluded artery is possible and directly suggested. Massage of the muscles may serve to relieve them of the extreme tension, especially when it is combined with multiple small incisions into their substance.

Later treatment depends upon the length of time which has elapsed, the degree of cicatrization and contraction, and the extent of the nerve involvement. The earlier the treatment the better the results. Partly cicatrized muscles can be revived and the restoration of the integrity of the nerves is often followed by surprising results. Without treat-

ment the condition is hopeless and as a rule goes from bad to worse. In the treatment of the late cases it is the first essential to free all imprisoned nerves from the scar tissue, leaving them free or imbedded in fatty sheaths so as to insure their integrity.

The contractions can be dealt with in various ways. The most successful is the method of Robert Jones and depends upon the fact that when the wrist is fully flexed the fingers can be more or less extended. In this position iron splints are attached to the fingers, beginning with the distal joints, and the hand is then extended with the fingers imprisoned until the contractural elasticity of the distal joint is lost. The next joints proximally are then included, and the contracted hand is gradually unfolded and extended until there is no longer any tendency to contract. This takes many weeks, but gives a good functional result.

Rapid stretching of these muscles under an anæsthetic is not satisfactory, and even when repeated many times often fails to remedy the contraction. Drehmann's procedure in which the arm is opened so as to expose all the affected muscles and nerves is of value. The nerves are dissected out, as well as the muscles, from the enveloping scar tissue. The muscles are lengthened by nicking them on either side, until the contraction is overcome and the fingers can be fully extended. The tendons of those muscles which are most involved are then divided at the wrist and united to the tendons of healthy muscles.

Other methods of treatment consist in lengthening of the contracted tendons and shortening of the bones of the forearm to compensate for the contracture. The latter is difficult and unsatisfactory. The former gives a fair number of successes. Myotomy of the muscles has been successfully done by Bradford. Passive movements, massage, and electricity must follow the operative measures in order to obtain the best functional results.

Lesions of the nerves occur independently of interference with the circulation. Contracted into a small space at the bend of the elbow, they are frequently cut, torn, penetrated by spicules or compressed. The method of examination has been already described. The integrity of the nerves is easily proved or disproved by following out the peripheral distribution; the median and ulna are most often involved, but it is to be borne in mind that a portion only of the nerve may be cut and its distributive functions only partly interfered with.

Treatment of the injuries about the elbow must be considered together and individually. Normal movements of the elbow, with

pronation and supination of the hand; with retention of the carrying angle and the normal contour are the desiderata, in the order named.

A perfect result has been defined as "one in which the full and normal range of motion is the sequel of the treatment of a fracture of the elbow." According to the treatment, "perfect" results have varied from 18.5 to 81 per cent. of the cases treated where large groups have been considered.

It is a matter of importance when all of these cannot be obtained to know what to sacrifice when there is a choice, where the motion which can be secured should be located, and what deformities are consistent with good functional results. On account of the uncertainty of the exact lesion in many cases during the stage of swelling it is desirable to adopt a method of treatment which will give good results as to motion, while avoiding as much deformity as possible. Such has been found in treatment by the flexed and acutely flexed position.

Treatment in the acutely flexed position, originated by Jones of Liverpool and expanded by Ashurst under the term hyperflexion, has given the largest percentage of perfect results. This original treatment has been modified by (*a*) reducing the term of immobilization and (*b*) the early use of passive motion and massage.

The rationale of this treatment is seen when a broad view is taken of elbow fractures. Most of them are oblique, with the tendency of the fragment to go backward and upward, and to rotate according to the "hang" of the forearm. Attached by ligaments and muscles to the forearm, the fragments move in accordance with its position, so that the control of the lever action of the forearm becomes the chief problem in the treatment. The fragments may be completely reduced and the normal contour restored, but a slight variation of the forearm in adduction or abduction pulls them out again. Maintenance of the forearm in the proper position where extended or partly flexed is difficult on account of the fact that the plane of movement of the forearm does not coincide with the plane of the upper arm. When the forearm is extended from the position of extreme flexion the hand moves through the arc of a circle until in complete extension the forearm makes an angle of 10 to 15 degrees with the upper arm. This has been already described as the carrying angle, and is dependent on the fact that the axis of rotation about the trochlea is not at a right angle to the shaft of the humerus. This varies in different individuals and in the arms of the same individual. It is evident then that if the arm is to be set in extension it cannot be set straight but must be set so that the carrying angle

is restored. This is an unknown quantity and can only be estimated. As the arm is flexed the angle disappears, but not *pari passu*, and the question of pronation, supination or the half and half position comes in to complicate it, but in the acutely flexed position the plane of the forearm coincides with the plane of the upper arm. The pull of the distributing muscles and ligaments is lost through relaxation of all of them except the triceps, whose broad tendon and its aponeurosis extends around the fragments and tends to hold them firmly in the reduced position. The lever action of the forearm is in this position easily controlled, and abduction or adduction prevented by holding it in line with the humerus which acts as a natural splint.

Under an anæsthetic the fragments should be reduced, as accurately as possible, and it is best in doing this to put the arm through the movements of reducing a dislocation. The arm should be extended with some force, pressure being made over the head of the radius, and then flexed to the acute position, paying especial attention to the position of the head of the radius.

In the hyperflexed position the fragments can often be completely reduced and the arm fixed in this position. This is done by inserting three or four layers of gauze, well covered with talcum, in the bend of the elbow. Then with a gauze or muslin roller the hand is bandaged and the bandage extended up over the wrist and lower third of the ulna, which is first covered with a layer of linette or absorbent cotton (with talcum).

The forearm is then held flexed upon the upper arm, the axis of both coinciding, and the forearm supinated, the thumb pointing outward. The bandage is then passed around the upper arm and back over the forearm, securing the two firmly together. A piece of adhesive is applied outside the bandages high up, for better security. The most acute flexion which can be obtained is used, but the radial pulse must not be obliterated. The angle will range from 20 to 45 degrees according to the swelling.

An X-ray examination of the elbow should be made as soon as practicable to correct errors of setting.

The length of time in which the arm should be kept in this position will vary with the condition. It is wise to release the bandage and allow any obstruction to the circulation to be determined at the end of 24 hours. This can be done with but slight relaxation from the acutely flexed position. Blebs shall be opened and the gauze in the bend of the elbow replaced. After four or five days, as the swelling

begins to disappear, the motion is increased, proper support to the arm being given, and gentle massage used to prevent joint stiffness and to relax muscle spasm.

This should be done without an anæsthetic and always within the limit of pain. The shoulder, wrist and finger joints should all be moved and the massage extended to the muscles of the arm and forearm. All painful movements are to be avoided. As most of the cases are in children, pain must be carefully avoided in order not to excite spasm of the muscles and a struggle which may result in displacement of fragments.

Voluntary motion of the shoulder, wrist and fingers are to be encouraged from the first, and of the elbow after the first week. After the third week at least half the normal motion should be passively present in the elbow, and the patient encouraged to use the muscles as much as possible to prevent atrophy.

After each treatment the arm is returned to its original position in hyperflexion. After the third week the arm should be released during the daytime, but the bandages reapplied during the night. After the fourth week bandages can be dispensed with altogether.

Most of the fractures about the elbow in children and the majority of adults can be treated by this method with a maximum of good results. Statistics show that the earlier the massage and movement is begun the larger the percentage of good results. The objection to adhesive next the skin in children is the difficulty of frequent removal; fortunately it does the work equally well outside the bandage.

Fracture of the lower end of the humerus, just above the condyles, is best treated by an internal angular splint, at a right angle. The lower fragment goes backward with the forearm, and this splint holds it well forward and presses the upper fragment backward at the same time.

Motion should be begun early, in this as in all other fractures about a joint, at least at the end of the first week.

Treatment of fracture of the olecranon alone should be in the extended position. The degree of extension varies with the interval between the fragments and the ease of reduction. All complete fractures of the olecranon open the elbow-joint, and there is usually much swelling and ecchymosis infiltrating the tissues. The tendon and aponeurosis of the triceps may hold the fragment with little displacement when the elbow is bent at a right angle, and an internal right-angled tin splint will be sufficient to hold the arm much more comfortable than

a position in complete extension. The least angle should be chosen for setting which gives close apposition.

Plaster of Paris or tin splints with obtuse angles may be used. Where the fragment is small and separation great, the position of full extension on a straight splint (or plaster of Paris) is best.

Many of the fractures of the olecranon are compound, and should be treated like other compound fractures, with the fullest asepsis. The compound opening should be enlarged if necessary for perfect drainage, and the opening utilized for the suturing of the fragments. This can be done by kangaroo tendon or silver wire inserted subcutaneously above and below the break, including the fascia and tendons, and bone if necessary.

Union is often fibrous, rarely bony, even if the apposition is good, but is more often bony than fibrous after suturing. The splints should be kept on for about four weeks, but should be removed daily after the fifth day and passive motion and massage begun, with reapplication of the splints after each treatment. The shoulder, wrist, and finger joints should be moved passively and actively, and motion begun in the elbow. Even with fibrous union and a considerable final separation of the fragment, a good functional result is the rule. Non-union is not uncommon, due to torn slips of fascia intervening between the broken surface, and operative treatment is then indicated.

Fracture of the coronoid may require special treatment in that the fragment may fail to unite and may interfere with the flexion. The hyperflexed position gives the best results, but if the fragment remains loose and interferes with the joint function it should be removed.

Fractures of the neck or head of the radius are both best treated in the hyperflexed position. Pieces of the head may lie free in the joint and must be removed (Fig. 88). Passive movements early show the presence of such and the desirability of removal.

Prognosis in elbow joint fractures should be guarded. The seriousness of these fractures is well known to the laiety and profession, but the friends should be carefully informed of the possibilities of deformity and limitation of motion. Nerve injuries also should be recognized, if possible, and charted *before* treatment. In a general way, the younger the patient the better the result, and the quicker the union. Usually three weeks immobilization in children, and four to six weeks in adults gives good union.

The deformities, cubitus varus or valgus are unusual under the

hyperflexion treatment, and are due to imperfect reduction. Projecting bosses can generally be removed, but this does not improve the hang of the arm. Non-union is very rare. Full flexion and most of the extension of the arm can be obtained. Treatment should be continued until the maximum motion is obtained. Joint bodies may need removal and nerve lesions sometimes demand suture or electrical treatment before complete recovery is obtained.

Old fractures with deformity and limitation of movement are susceptible of great improvement by operative treatment, osteotomy through a projecting condyle, or both condyles where they are turned forward, gives good results.

Transference of the arc of motion is practicable and easily accomplished in suitable cases where the forearm, for instance, can be extended and flexed only to a right angle. The usefulness of the arm is much limited by inability to get the hand to the head or mouth. By a simple resection close above the joint this arc of motion can be transferred so that the 90 degrees of motion can occupy a position of 45 degrees in extension to 45 degrees in flexion, and this without entering the joint or risking the movement already present. With this in view, a small rhomboid-shaped piece is removed just above the condyle, allowing the condyle to come against the shaft at an angle of 45 degrees. The forearm is used as a lever to obtain this position, and after union the arc of motion is found transferred to its new position, with much increased usefulness as a result. The writer has used this expedient a number of times with success. Varus or valgus deformities can often be thus corrected at the same time by properly shaping the rhomboid. The hyperflexed position is of the greatest value in the post operative treatment of these later lesions.

Fracture of the surgical neck is common in both young and old. In the old, it most frequently follows direct falls or blows upon the upper arm, while in the young it also follows falls upon the rigid arm.

Longitudinal section of the bone shows the firm cortex continuous almost to the articulating surface of the head on the medial surface, and it is not clear at first sight why the weakest part of the bone should be at the "surgical neck." The nutrient artery enters lower down and runs toward the elbow and there are no grooves to weaken its structure. The explanation lies, I think, in the "setting" of the joint. An unusually firm capsule, together with the long biceps tendon and coracohumeral ligament hold the head firmly in the glenoid cavity. Wrapped outside of these, the tendons of the muscles from the scapula add much

to the resistance. The lines of fracture here frequently run in and out between these reënforced parts, suggesting directly the part they play, in protecting the underlying structure.

Spicules are common, impaction of more or less of the lower fragment into the cancellous tissue of the head is frequent. The whole shaft may be driven up into the head, or a projecting tongue or spicula may impale it eccentrically. The impaction may be such as to hold the fractured surfaces apart, as when a spicule from the outer margin of the bone is driven into the inner (medialward) portion of the head.

When not impacted, the upper fragment rotates outward, providing the tuberosities have not been torn off (Fig. 37). The lower fragment is pulled inward by the latissimus dorsi, pectoralis, and upward by the arm muscles which are attached to the scapula. The end may lie in the axilla—subglenoid—like a dislocation, or be displaced into the muscles front or back.

Subperiosteal fracture occurs in young children, and is difficult of diagnosis. It follows a fall on the rigid arm, and there is immediate inability to use the arm. Marked tenderness is found in the upper fourth of the humerus, but no crepitus or abnormal mobility. Spasm of the muscles follows. An X-ray is necessary for the diagnosis. Without it, the fracture is to be suspected in a child, with disability lasting for days and no apparent deformity or shortening.

Diagnosis.—The head of the bone is first sought in the glenoid cavity where it does not move with the shaft. Crepitus can usually be obtained, but is absent if there is impaction, or dislocation of the upper end of the lower fragment into the muscles, front and back. Shortening may be slight or marked. Pain on movement is great and spasm of the muscles sometimes prevents the abnormal mobility, which becomes evident under an anæsthetic. Swelling is marked, hematomata constant and ecchymoses often extending to the elbow. Under an anæsthetic the line of fracture can sometimes be found if the subject is thin, but in a muscular man, with much swelling, an X-ray is a necessity.

Separation of the epiphysis occurs under twenty-five, and results both from direct and indirect violence as well as from torsion and muscular action. It has been caused by lifting a child by the arm or by pulling on the arm in childbirth. In the older children, there is immediate inability to use the arm, with pain on motion and pressure. Crepitus not commonly found.

Displacement may be slight or very marked, as in fracture of the surgical neck, and the appearance of a dislocation is often simulated.

The head can be felt in the glenoid, and the sharp end of the lower fragment can be felt under the front of the deltoid or in the axilla, or under the coracoid.

Reduction of the fracture is followed by quick recurrence of the deformity, which distinguishes it from a dislocation. It is to be kept in mind that the epiphysis includes not only the articular head, but also the tuberosities. The spasm of the muscles pulls the tuberosities upward and the articular surface downward, so that the fractured epiphyseal surfaces do not come into contact when reduction is made, which accounts for the absence of crepitus, and the ease of reproduction of deformity.

Differential Diagnosis of Injuries of the Shoulder (Keene)

	Abnormal prominences	Convexity of shoulder	Position of head	Axis and length of arm	Crepitus abnormal mobility, etc.
1. Sprain.	None.	Unchanged.	Rotates in joint.	Unchanged.	Absent.
2. Dislocation.	Prominence above acromion.	Unchanged.	Rotates in joint.	Axis changed and arm shorter.	Outer end of clavicle shows abnormal mobility above acromion.
3. Fracture of acromion process.	None unless marked displacement.	Acromion lower, otherwise unchanged.	Rotates in joint.	Unchanged.	Crepitus and abnormal mobility above acromion.
4. Fracture of spine of scapula (rare).	Acromion very prominent.	Depression beneath acromion.	Head felt in axilla but rotates in joint and can be raised.	Axis unchanged but arm apparently longer.	Distinct crepitus and abnormal mobility.
5. Fracture of upper end of humerus (surgical neck or epiphysis).	Prominence of upper end of shaft below coracoid or acromion.	Shoulder somewhat flatter, according to degrees of displacement.	Head in glenoid cavity, does not rotate with shaft.	Axis changed more internal. Arm shorter.	Unless impacted, get distinct crepitus and abnormal mobility in adults. Less marked in children.
6. Dislocation of humerus.	Acromion prominent.	Depression or flattening beneath acromion.	Head felt below coracoid process or in axilla.	Axis changed, length increased.	Head fixed, adduction impossible. Only mobile if tuberosities broken.

However, in many of the cases, the epiphysis appears to be held to the shaft by a portion at least of its periosteum and in these cases the deformity is not great and the reduction easy. Care should be taken not to tear the shaft loose from the head until its effect is noted, for the strip of periosteum which holds the head to the shaft may, and in many cases does act to prevent the reduction by pulling the head out of line when traction is made on the shaft, like an impacted spicule. In these cases it is necessary to rotate the arm until the head is completely loos-

ened from the shaft, before reduction can be obtained, and an operative procedure is often necessary to secure proper replacement. Interference with the growth of the arm follows a separation at the epiphysis. This is slight where the reduction is perfect, but malposition results in loss of growth, and is one of the factors calling for operative interference.

Complications are Many and Serious.—(1) The fracture may take place after the head is dislocated, and this applies to all fractures of the upper humerus, but commonly the break occurs at the surgical neck, with one or both tuberosities torn away (Fig. 45). (2) The vessels in the axilla may be extensively torn. Rarely the axillary artery is torn. If the tear penetrates the lumen, the radial pulse disappears and a huge hematoma quickly forms in the axilla. If the coats are nicked, an aneurysm may result. The vessel may be twisted, and thrombosis result. The circumflex and subscapular arteries may also be involved. More frequently the axillary veins or large branches suffer. Then swelling in the axilla is great, but the radial pulse remains. Pressure on the vein may cause œdema of the arm, often excessive. (3) The brachial plexus and branches may be torn or paralyzed by the pressure of the dislocated fragment. The circumflex nerve winds around the humerus just below the head and is often torn. The musculo-spiral comes next in frequency. Cotton has drawn attention to the importance of establishing the presence or absence of sensory and motor paralyses *before* treatment lest an *already existing* and *inevitable* nerve lesion be laid to the operator or to the effect of his treatment. The long tendon of the biceps may be dislocated. This may follow fracture of the lesser tuberosity or independently of it. Slippage of this tendon seriously interferes with the usefulness of the arm. Combined with paralysis of the deltoid it allows the bone to drop away from the glenoid, and the disability is marked and difficult to remedy.

Treatment.—An anæsthetic is necessary, both for diagnosis (where the X-ray has not been used) and treatment. Perfect reduction is important, and where possible the open method is to be preferred in the majority of cases. The ease and certainty with which the fragments can be placed in apposition and retained leaves nothing to be desired (Fig. 44). Fixation of the fragments can be maintained by Lane's plates, by nailing, wires, dowels or Cotter pins.

The technique of the operation is simple but must be thoroughly understood and the necessary mechanical devices for repair must be at hand.

Operation.—

1. The skin should be shaved dry, cleaned with benzine and soaked with tr. iodine.

2. Make the incision anteriorly between the Deltoid and Pectoralis major, retracting the muscles or dividing them in part, if necessary.

3. Expose the fracture. Replace the fragments in position, using the arm for traction and rotation to obtain accurate apposition. Should the head be dislocated and difficult to replace, a hole may be bored in it and a nail or wire hook used to facilitate the manipulation.

4. Fasten the fragments together by plates, nails, dowels or bone splints, as may be indicated.

Fig. 51.

5. Suture the various layers with catgut, beginning with the periosteum and obliterating all dead spaces. Dress.

When the necessary operative work has been completed, the body can be used as a splint and the arm bandaged to the side where it should be maintained for three to five weeks, according to the age of the patient (Fig. 51).

Where there is little or no displacement, or where reduction can be made under the anæsthetic, and the open method not available, the following aids are of service:

1 **Fracture of the Anatomical Neck.**—Fracture of the anatomical neck after reduction is best held in place by a shoulder cap which can be moulded *in situ;* plaster-of-Paris bandages may be used or plaster on flannel in layers. Any loose-webbed material will hold an acetone-celluloid solution, which does not harden as quickly as the plaster, but is light and cleanly. Several glue-felt fabrics, easily moulded in hot water, are on the market and are useful. Should the greater tuberosity

be fractured it can sometimes be felt and forced into place and held to some degree by the shoulder cap.

Fixation of the lesser tuberosity *in situ* requires inward rotation of the arm. After the shoulder cap is applied, an axillary pad, not too large, should be held in place by adhesive, and the arm bandaged against the body which acts as a retaining splint.

2. **Separation at the Epiphysis and Fracture of the Surgical Neck.**—Under an anæsthetic the line of fracture and condition of the ends of the fragments are ascertained. If impaction exists, as a rule it is better to loosen it and place the broken ends in good apposition. "Setting" is best done with the arm in the abducted position, holding the upper fragment as firmly as possible with the fingers in the axilla, and thumb on the head of the bone. If the deformity returns when the arm is placed at the side, a triangular splint of thin wood, wire or glue-felt can be used to keep the arm at that angle with the body which seems best to hold the ends in apposition. This is fixed in place with adhesive and a shoulder cap or narrow coaptation splint can be used to keep the arm in line, exerting counter pressure by adhesive, against the triangle. The body forms a good splint in many cases. Some good absorbent material, like folded linen, should be placed between the arm and body, and the arm fixed by a modified Velpeau bandage.

Where the fracture cannot be kept in line, extension by weights can be used or traction apparatus employed.

Especially useful is Lambotte's "fixateur," which consists of a series of rods, 4—8, driven into the bone through the skin at right angles to the shaft, with a hand drill. The drill is uncoupled and the rods are fixed on a longitudinal bar which correlates them, holding them without the slightest movement.

3. **Dislocation of the Head with Fracture of the Epiphysis, or Fracture of the Surgical Neck.**—Dislocation of the head, with separation of the epiphysis or fracture of the surgical neck is not rare. It occurs as a result of the primary injury, but also as a result of violent efforts at reduction. If the dislocation is old and the fracture recent there is little chance of reducing the dislocation by manipulation. But if both are recent, with the fingers in the axilla, the head can sometimes be pushed upward through the rest, into the socket. To do this, it is necessary to make traction over the arm which may be tried in various positions but the best results are obtained with the arm in abduction, at right angles to the body.

If manipulation fails, the dislocated head must be reduced by opera-

tion, and even then the reduction may present great difficulties. McBurney made an incision over the head and bored a hole into the head. A rod or hook was used to pry or lift the head into position. If subsequent plating is to be employed, a more liberal incision is needed and the head can be lifted with bone forceps. If the dislocation is old, it may be very difficult to reduce and be so overgrown with callus and bone as to be useless if reduced. Many of the fractures have occurred in these old dislocations where the head was so fixed to the scapula and tendons as to be practically immovable.

The excessive callus formations found around the head and shaft in these old cases comes from the repeated attempts at reduction with repeated tearing away of the tuberosities, if they have been previously fractured, and repeated strippings of the periosteum from the bone. In these cases, the head and shaft cannot be freed from the callus and osteophytic growths, and it is better to remove the head and cover the end of the humerus with fascia for a new joint. Care should be taken not to remove too much bone as a flail-joint results. The head, or a portion of it, may be kept and the fascial transplantation relied on to prevent ankylosis.

Prognosis.—From three to five weeks is usually needed for union. Early removal of the splints is desirable. Apparatus should be removed at least twice a week, to move all joints below seat of fracture and the shoulder should be gently moved after 10 days. Union is generally prompt. The more accurate the apposition, the quicker the union. Non-union in this location is very rare.

Function of the arm is usually good to fair, even with considerable deformity, but the full use of the arm is not obtained in malpositions inside of six to 12 months. Abduction is usually limited. Fracture with head dislocated may give permanent disability with little function, and constant pressure pain, but in some cases where the head has united at right angles to the shaft, the function may be fairly good.

Old fractures, with much impaired function, due to ankylosis, dislocated biceps tendon, vicious impactions, spicules, malpositions, slippage of the joint in motion, pressure pains, nerve paralysis, with muscle atrophy or atrophy *ex abusu*, often call for the highest skill in correction. Radiograms at various angles are necessary and the cause of the impaired function accurately determined. Excision has been hitherto frequently resorted to in these cases, but should be used

only for persistent pain, and in the aged, where the usefulness of the joint is a minor object.

Excision, even when ankylosis is prevented by fascial transplant, is followed by shortening, loss of power, both of abduction and adduc-

FIG. 52.

FIG. 53.

FIG. 54.

FIG. 55.

FIG. 56.

FIG. 57.

FIG. 58.

FIG. 59.

FIG. 52.—Humerus-shaft transverse fracture—periosteum intact.
FIG. 53.—Humerus-shaft transverse fracture—recent.
FIG. 54.—Spiral fracture of shaft of humerus.
FIG. 55.—Spiral fracture shaft—comminuted.
FIG. 56.—Oblique fracture of humerus—comminuted.
FIG. 57.—Oblique—comminuted.
FIG. 58.—Same—repaired alignment faulty.
FIG. 59.—Fracture—old case of osteomyelitis.

tion, loss of strength in the shoulder and much diminution of the driving power (striking force). As these depend on the shortening, the length of bone should, if possible, be kept intact, and other procedures used to restore function.

Spicules, projecting bosses and osteophytic outgrowths may be removed, the periosteum being carefully replaced and sutured so as to limit the formation of new bone. Arthroplasty may be resorted to for ankylosis. The shaft may be straightened by V-shaped incisions

Fig. 60.

Fig. 61.

Fig. 62.

Fig. 63.

Fig. 64.

Fig. 65.

Fig. 60.—Sarcoma with fracture.
Fig. 61.—Carcinoma with fracture.
Fig. 62.—Wassermann ++++, oblique fracture.
Fig. 63.—Fracture lower end of humerus—split condyles.
Fig. 64.—Fracture lower end of humerus split between condyles—fragments forced apart by end of upper fragment.
Fig. 65.—Same as Fig. 64. Lateral view.

(osteotomy), and retained in corrected position by wedges or plates. The head can be turned and held in the same way, with bone grafts to replace the missing bone.

Fractures of the shaft include all those occurring below the surgical neck and above the supracondyloid tips. They result from direct

violence, falls on the elbow or rigid arm, muscular action and torsion. Direct violence usually causes more or less transverse fractures, which may be multiple (Fig. 52). Indirect violence and torsion give the oblique and spiral forms (Fig. 54). Greenstick fractures are rare. The seat of fracture and direction of the force determine the displacement.

Fig. 66.

Fig. 67.

Fig. 68.

Fig. 69.

Fig. 70.

Fig. 71.

Fig. 66.—Oblique fracture through lower end of humerus and internal condyle.
Fig. 67.—Oblique fracture through lower end of humerus and internal condyle showing method of fixation.
Fig. 68.—Fissure with displacement. Crack into internal and external condyle and up the shaft.
Fig. 69.—Crack into external and internal condyle and up the shaft.
Fig. 70.—Separation of united epiphyses (crescentic fracture).
Fig. 71.—Comminuted fracture both condyles.

Where the fracture is in the upper third, the upper fragment is usually found pulled inward by the Pectoralis major, latissimus dorsi and teres, and the lower fragment is pulled upward by the deltoid, biceps and triceps. In the middle third, there is often no displacement

in single fractures, but if multiple, the arm crumples up. In the lower third the triceps pulls the elbow backward.

Diagnosis is usually easy, pain, shortening, abnormal mobility and crepitus being pronounced. In the middle third with no displace-

Fig. 72.

Fig. 73.

Fig. 74.

Fig. 75.

Fig. 76.

Fig. 77.

Fig. 72.—Comminuted fracture both condyles.

Fig. 73.—Oblique fracture lower end of humerus. Displacement of fragment backward, simulating a dislocation.

Fig. 74.—Fracture through condyles. Anterior displacement of fractured portion.

Fig. 75.—Fracture internal condyle—recent.

Fig. 76.—Fracture of internal condyle ununited after 9 years. Condyle had slipped back partly closing olecranon fossa, and preventing full extension of arm (Loss of 35°).

Fig. 77.—Side view of same—note distortion of normal shadow on humerus.

ment the shortening is not present. To determine the amount of shortening, keep the arms against the body and measure from the tip of the acromion to the ext. epicondyle.

Complications are important. Injury to the musculo-spiral nerve is most frequent and a knowledge of its course in relation to the bone

and of its distribution is important. It is the largest branch of the brachial plexus. Starting as a continuation of the posterior cord, it descends behind the first part of the axillary and the upper part of the brachial arteries, and in front of the tendons of the latissimus dorsi and teres major.

FIG. 78.

FIG. 79.

FIG. 80.

FIG. 81.

FIG. 82.

FIG. 83.

FIG. 84.

FIG. 78.—Fracture of external condyle. Front view.
FIG. 79.—Fracture of external condlye. Side view.
FIG. 80.— } Fractures of external condyle with the capitellum
FIG. 81.— } showing different degrees of displacement.
FIG. 82.—Fracture head of radius. No displacement of fragments. Note lip on inside of head showing that whole articular surface is involved.
FIG. 83.—Fracture head of radius, outer lip only.
FIG. 84.—Fracture head of radius. Outer lip only, Comminution.

It winds around the humerus from the medial to the lateral side in a groove with the artery (superior profunda) between the medial and lateral head of the triceps. It pierces the lateral intermuscular septum, and passes between the brachialis and brachioradialis (supina-

tor longus) to the front of the external condyle, where it divides into two branches, the superficial radial and deep interosseous.

In the axilla it gives off a cutaneous branch (with the inner muscular branch). It passes through the axilla to the inner side of the arm,

Fig. 85.

Fig. 86.

Fig. 87.

Fig. 88.

Fig. 89.

Fig. 90.

Fig. 91.

Fig. 85.—Fracture head of radius. Extensive comminution.
Fig. 86.—Fracture through neck of radius. Head remaining *in situ*.
Fig. 87.—Fracture through neck of radius. Head displaced.
Fig. 88.—Showing result after resection of head of radius.
Fig. 89.—Fracture of neck radius with displacement of head.
Fig. 90.—Fracture radial head. Comminuted and impacted.
Fig. 91.—Fracture radial head. Comminuted with displacement of fragment.

supplying the skin on the posterior surface nearly to the elbow. Lower down two other cutaneous branches are given off, which perforate the outer head of the triceps at its attachment to the humerus. The upper one supplies the skin of the upper arm on its anterior surface, the lower one emerges from the deep fascia just below the insertion

of the deltoid, and passes down along the outer side of the arm and elbow, and supplies the skin along the back of the radial side of the arm as far as the wrist.

In the arm, from the inner back and outer parts, the musculo-spiral gives off muscular branches to the triceps (medial and lateral

FIG. 92.

FIG. 93.

FIG. 94.

FIG. 95.

FIG. 96.

FIG. 92.—Fracture olecranon—slight separation.
FIG. 93.—Fracture olecranon—separation more marked.
FIG. 94.—Comminuted fracture of the olecranon—slight separation.
FIG. 95.—Comminuted fracture of the olecranon—wide separation.
FIG. 96.—Osteophytic growth on tip of olecranon. Fracture of osteophyte only.

head) anconeus, brachioradialis (supinator longus), Ext. carp. rad. longior, and the lateral part of the brachialis anticus. At its termination, the superficial branch (radial) is continued into the forearm and hand, where it supplies:

1. The skin of the radial side and ball of thumb.

2. The ulnar side of the thumb, the radial side of the index finger, the adjoining side of the index and middle fingers, and the adjacent sides of the middle and ring fingers.

The deep branch supplies all the muscles of the radial and posterior

FIG. 97.

FIG. 98.

FIG. 99.

FIG. 100.

FIG. 97.—Volkman's paralysis recent case—contracture just beginning.
FIG. 98.—Same—ulna side view.
FIG. 99.—Same—dorsal view. Power to spread fingers (interossei retained).
FIG. 100.—Volkman's paralysis contracture marked; shows maximum extension—2 years after injury

brachial regions, except the anconeus, brachioradialis (supinator longus) Ext. carp. rad. long.

When the musculo-spiral is paralyzed, the wrist drops and cannot be extended. The fingers are flexed but the last two phalanges can be extended by the interossei. Supination is lost in the extended arm, but when flexed can be flopped over by the biceps. If the injury is high up, the triceps is involved and the arm cannot be extended.

Anæsthesia is found over the area supplied by the superficial branch of the radial. If high up, the lateral side of the upper arm and the back of the forearm also are involved. Especially important is it to examine for nerve injury both in its sensory and motor distribution before any attempt at setting the arm is made; also it is important

FIG. 101.

FIG. 102.

FIG. 103.

FIG. 104.

FIG. 105.

FIG. 101.—Same—ulna side view.
FIG. 102.—Volkman's paralysis—appearance twenty years after injury. Comparison with uninjured arm and hand.
FIG. 103.—Fracture upper third ulna with dislocation of radial head forward and upward.
FIG. 104.—Same as 103. Dislocation reduced. Fracture fixed with dowel pin.
FIG. 105.—Same as 103. Front view.

to remember that the nerve is not necessarily completely divided, but may be partly so, or its function may be interfered with by pressure, or undue strain, and it may be injured by the trauma apart from the fracture. These are important in both prognosis and treatment. Also fractures of the ulna in the upper third may produce

paralysis of the radial, with these same results below the point of injury.

If the paralysis is recognized early, it should be an important influence in selecting operative interference, both for the possibility of immediate repair and the prevention of excessive callus, which is an important element in determining the permanent nature of the lesion.

FIG. 106.

FIG. 107.

FIG. 108.

FIG. 109.



FIG. 110.

FIG. 111.

FIG. 106.—Fracture upper third ulna. Radial dislocation reduced. Fixation by plate.
FIG. 107.—Fracture upper third ulna. Dislocation radius backwards and downwards.
FIG. 108.—Fracture upper third ulna. Dislocation radius outwards.
FIG. 109.—Old fracture upper third ulna. Unreduced radial dislocation.
FIG. 110.—Fracture middle of ulna. No separation.
FIG. 111.—Fracture lower third ulna. Front view.

A musculo-spiral paralysis is a very disabling lesion. Occurring at the time of the injury, unless there is a quick return of sensation in the distribution of the nerves, within the first few days, there is little chance of recovery.

STATISTICS ON RECOVERY

Prognosis.—Where the paralysis develops quickly it may be due to stretching or compression of the nerve and recovery begins, if the nerve is freed, in a few hours and should be complete in from one to 10 days, but where the nerve is crushed or divided, completely or

FIG. 112.

FIG. 113.

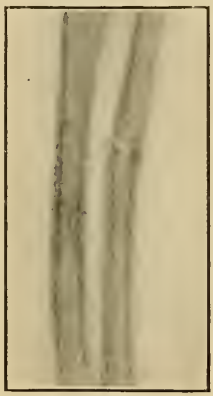

FIG. 114.

FIG. 115.

FIG. 116.

FIG. 117.

FIG. 118.

FIG. 112.—Fracture lower third ulna. Inward displacement.
FIG. 113.—Ununited fracture ulna. Much callus. False joint.
FIG. 114.—Fracture upper third radius in child.
FIG. 115.—Fracture lower third radius. Front view.
FIG. 116.—Fracture lower third radius. Side view.
FIG. 117.—Oblique fracture lower third radius.
FIG. 118.—Spiral fracture lower third radius.

in part, improvement is not to be expected in the paralyzed parts inside of three to six months, and callus formation or shifting of fascial planes and muscles, due to altered position of the bones, may permanently prevent recovery.

Little if any value attaches to the electrical changes in the muscles. It is the situation of the nerve ends and the possibility of their permanent separation which is in question. This can often only be revealed

FIG. 119.

FIG. 120.

FIG. 121.

FIG. 122.

FIG. 123.

FIG. 124.

FIG. 125.

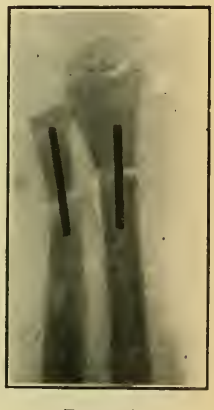

FIG. 126.

FIG. 119.—Fracture both bones forearm. Front view.
FIG. 120.—Fracture both bones forearm. Side view.
FIG. 121.—Comminuted fracture both bones forearm.
FIG. 122.—Fracture lower third both bones forearm.
FIG. 123.—Greenstick fracture both bones forearm in child.
FIG. 124.—Transverse fracture both bones forearm child. Side view.
FIG. 125.—Same as 124. Fixation with dowel pins. One pin in ulna could not be held in place after insertion.
FIG. 126.—Same as 124 and 125. Ulna fixed with dowel pin. Lack of alignment in ulna was due to callus which resulted from delay in operation.

by the open incision. An X-ray has little value here. When the nerve paralysis is not present at the time of injury, but is found after the "setting," it is probable that the nerve has been caught between the bone ends or torn in the "setting," or cut by splinters.

Overtight splints or undue pressure by pads may give a temporary paralysis, but if the paralysis comes on slowly, often preceded by tingling sensations and numbness, as well as paresis of supplied muscles,

FIG. 127.

FIG. 128.

FIG. 129.

FIG. 130.

FIG. 131.



FIG. 132.

FIG. 133.

FIG. 134.

FIG. 127.—Recent and old fractures of both bones forearm. (Recent in upper third.)
FIG. 128.—Fracture middle both bones. Fixation by plates. Note maintenance of the marked but normal bow of radius.
FIG. 129.—End result. Fracture middle both bones. Good rotation. Treatment by splints.
FIG. 130.—End result. Fracture both bones at different levels. Treatment by splints.
FIG. 131.—End result. Fracture both bones at different levels, resultant osteomyelitis. Non-union. Front view.
FIG. 132.—End result. Fracture both bones well united but distinct sequestrum in radius.
FIG. 133.—End result. Fracture both bones. Coalescence of callus. Non-union. Note displacement of ulna at wrist. Front view.
FIG. 134.—Same as 133. Side view.

and develops into a more or less total paralysis of the musculo-spiral group, the nerve has been caught in the callus, and there is practically no chance of recovery except by surgical interference.

Musculo-spiral paralysis, following fracture of the shaft, after

the 10-day interval is past, demands the open surgical method. As soon as the 10-day period determines the permanency of the paralysis, the operation should be done as quickly as possible, the bone fixed in position, the nerve freed or sutured, and its torn portion protected by fascia, or fat transplanted so that it may not be included in an infringing callus. This protection is especially needed where the break in the bone and nerve coincide.

Early operation is followed by prompt restoration of function. Late operation after the three to six months' interval, during which one is tempted to wait to see if the nerve is going to unite, is beset with many difficulties, due to the callus, altered bone surface and position, readjustments in muscles and fascial planes and internal cicatrices. Probably less than half of these late cases are benefited by surgical intervention. It is an operation which requires the highest surgical skill, and often involves refracture or resection of the humerus to obtain the desired result.

COLLES' FRACTURE

Fractures about the wrist are among the most frequent of all fractures. Above the joint they are usually bunched under the term "*Colles' fracture,*" which by common acceptance is applied to any fracture of the lower end of the radius with its associated injuries, commonly produced by a blow or fall on the hand. But Colles' classic article (Ed. Med. Jr., 1814) was written to call attention to the fact that the so-called dislocations of the wrist, sprains and contusions were in reality fractures, and that the radius was commonly fractured ½ in. above the joint.

As a matter of fact, Colles' location of the common fracture of the radius was too high, the vast majority of cases occurring lower down, but his original contention has been abundantly verified by the X-ray, which has demonstrated a large and increasing variety of fractures and associated lesions about the wrist resulting from falls upon the hand.

The following conditions may occur:

1. Fracture of the lower end of the radius—Colles' fracture.
2. Fracture of the ulna, low down, or of its styloid process.
3. Dislocation of the lower end of the ulna—with rupture of the radioulnar ligaments.
4. Rupture of the anterior annular ligaments of the wrist, with or without fissure fractures in the end of the radius.

5. Fracture and dislocations of the carpal bones, especially the scaphoid and semilunar.

6. Dislocation of the wrist joint (rare).

7. Dislocation of the metacarpo-phalangeal joints.

It is not uncommon to have two or more of these lesions resulting from the same traumatism. The mechanism of these fractures has always been a subject of interest and of some considerable dispute. In a fall upon the heel of the palm the strong anterior carpal ligament becomes tense and the force of the blow is transmitted to the end of the radius through the carpal bones. The force of the blow tends to supinate the hand, so that when the bone breaks, the hand, together with the fractured fragment tends to go backward and outward while the shaft of the bone is pronated inward. The spiral fractures are suggestive of this twisting force. The twist frequently fractures the scaphoid or semilunar alone, even where the force is not great.

The anterior ligament may tear, and the joint dislocate (rare) or a fissure fracture of the radius result. Most commonly the cancellous tissue of the end of the radius gives way, and is pushed backward, giving the so-called silver fork deformity.

A fall upon the outstretched fingers, or upon the back of the hand, with the wrist flexed may produce the same result. Impaction may or may not be produced, according to the force, and the impaction may be posterior, on the dorsal surface, or anterior.

The "silver fork" deformity is a resultant of the forces which turn the broken end of the radius upward and backward as upon a hinge, and at the same time rotate it outward. The radius is distinctly shortened as measured along its outer border, and its articular surface faces down and backward, instead of down and forward. The shortening is in proportion to the angular displacement, and the crushing or impaction of the fragment. As a direct consequence the hand (which articulates solely through its carpal bones with the radius) swings to the radial side, outward—and the plane of the palm no longer coincides with the plane of the wrist, but faces relatively outward.

Where the lower fragment is tilted forward and impacted anteriorly the rotation is inward instead of outward, the shortening of the radius occurs as before, but the articular surface of the radius faces farther forward and downward than normal. To the deformity thus produced the name of "gardener's spade" has been applied. But the deformity in this variety is often not marked.

The most frequent lesion is a fracture transverse from side to side, and oblique from before backward and upward, but there are many variations:

FIG. 135.

FIG. 136.

FIG. 137.

FIG. 138.

FIG. 139.

FIG. 140.

FIG. 141.



FIG. 142.

FIG. 135.—Typical Colles' fracture. Impaction of radius. Note fragment of tip of ulna and sliding of hand to radial side.

FIG. 136.—Colles' fracture. Front view. Note split in end of radius.

FIG. 137.—Same. Side view showing mild silver-fork deformity and spicule protruding among tendons.

FIG. 138.—Colles' fracture. Crack in articular surface of radius.

FIG. 139.—Colles' fracture. Common form. Mild silver fork.

FIG. 140.—Colles' fracture. Common form. Mild silver fork.

FIG. 141.—Colles' fracture. Common form. Note that the radial articular surface points directly forward.

FIG. 142.—Colles' fracture. Moderate silver-fork deformity. Note that radial articular surface points slightly upwards.

(*a*) The fractured end of the radius may not include the whole articular surface. (*b*) It may be split longitudinally by one or more fissures (Fig. 155). (*c*) It may be comminuted. (*d*) The line of fracture may be oblique from side to side but not from before back

ward. (*e*) It may begin in the articular surface of the radius and run backward, without involving the anterior portion of the shaft. (*f*) The styloid process alone may be fractured, with displacement of the

FIG. 143.

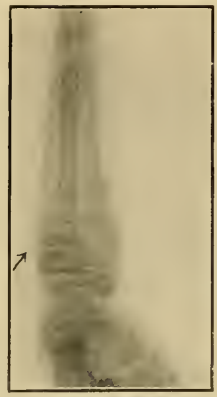

FIG. 144.

FIG. 145.

FIG. 146.

FIG. 147.

FIG. 148.

FIG. 149.

FIG. 143.—Colles' fracture. Marked silver-fork deformity. Radial articular surface points decidedly upward.

FIG. 144.—Colles' fracture. No impaction. Position apparently good. Note fracture of articular surface of ulna.

FIG. 145.—Colles' fracture. Only inner half of articular surface broken. Fragment held to ulna by radio-ulnar ligament. Tip of ulnar styloid fractured.

FIG. 146.—Colles' fracture. Impacted. Fragment comminuted. Note longitudinal splitting of fragments in two places.

FIG. 147.—Same as 146. Side view. Mild silver-fork deformity.

FIG. 148.—Colles' fracture, impacted. Deformity slight. Six months after the accident the hand was practically useless.

FIG. 149.—Colles' fracture. Complete separation of epiphysis. (The pin is in the dressings.)

carpal bones outward. (*g*) The internal angle of the radius carrying the sigmoid cavity may be torn off.

The *ligaments* are usually torn to a greater or less extent. The radio-ulnar ligament frequently gives way, and the ulna projects later-

ally, entirely free from its attachments to the radius—the triangular cartilage may be torn away, together with the whole of the sigmoid cavity.

Associated fracture of the ulna is common. The styloid alone is fractured in the majority of cases, but where the force is considerable

FIG. 150.

FIG. 151.

FIG. 152.

FIG. 153.

FIG. 154.

FIG. 155.

FIG. 150.—Epiphyseal separation. Reduced.
FIG. 151.—Side view of 150.
FIG. 152.—Colles' fracture. Unusual form. Impaction. Note crack on anterior surface radius.
FIG. 153.—Colles' fracture. Unusua form. Note crack on posterior surface radius.
FIG. 154.—Colles' fracture. Unusual type. Ulna remains attached to radius. Wrist bones dislocated backward.
FIG. 155.—Colles' fracture. Unusual type. Fracture high. Longitudinal split in radius. Fracture tip ulna.

the head of the ulna may be broken off, comminuted, fissured, impacted or broken spirally. As a result of the fracture the hand is carried toward the radial side, in proportion to the shortening of the radius, and the loosening of the external lateral ligaments. This is plainly seen in the figure showing the "silver fork" deformity (Fig. 146).

Where the force is considerable as in a fall from a height onto the outstretched hand, there are often associated fractures of the scaphoid or semilunar, or dislocations of one or both, the semilunar being the most frequently dislocated, and the scaphoid most frequently fractured.

Fig. 156.

Fig. 157.

Fig. 158.

Fig. 159.

Fig. 160.

Fig. 161.

Fig. 156.—Colles' Anterior displacement. Gardener's spade—mild.

Fig. 157.—Colles' fracture. Anterior displacement. Gardener's spade deformity more marked. Note elevation of shaft of ulna which has torn away from the distal fragments.

Fig. 158.—Colles' fracture. Anterior displacement. Note projection of ulna and its fragments on flexor surface.

Fig. 159.—Colles' Anterior displacement. Gardener's spade deformity marked.

Fig. 160.—Fracture. Unusually high. Note marked alteration of position of articular surface of radius, also oblique fracture of tip of ulna, carpus crowded to ulna side.

Fig. 161.—Fracture of radius. Projecting spicules rounded off by callus. Note position of os magnum which has been broken between the scaphoid and semi-lunar so as to articulate with the radius, also shortening of carpus.

Injuries to the vessels are rare except where the force is great and the fracture compound, when the sharp edge of the radius may cut off all tissues in front and project forward on the flexor wrist surface.

Flexor tendons as well as vessels may be injured, and sometimes severed, when the fracture is compound, but the chief injury to the tendons is due to the infringing of the edge of the upper fragment against the mass of flexor tendons as they pass through the box-like space, "wrist box," between the two bones and the annular ligament.

Fig. 162.

Fig. 163.

Fig. 164.

Fig. 165.

Fig. 166.

Fig. 167.

Fig. 162.—Fracture of radius. Radius here appears intact. Note dislocation of semi-lunar, cup forward and upward, and os magnum. Shortening and thickening of carpus is marked.

Fig. 163.—Fracture of radius and ulna. Dislocation of semi-lunar and scaphoid upwards. Os magnum against radius.

Fig. 164.—Side view of Fig. 163. Note dislocation of semi-lunar, scaphoid and os magnum. Marked shortening and thickening of carpus.

Fig. 165.—Auto arm. Note comminution of lower end of radius.

Fig. 166.—Auto arm. Note comminution of lower end of radius with slight displacement.

Fig. 167.—Same, side view showing anterior displacement.

The firm swelling on the palmar surface of the forearm, noted by Colles, is often marked and persistent for years, and is immediately due to the alteration in the pull of the tendons, and hemorrhagic effusion into their sheaths. A similar appearance on the back of the hand occurs

below the joint, but is less marked. The bunch of flexor tendons with their sheath and periosteal bed is often torn loose from the bone beneath, with underlying hemorrhage, into which callus formation enters, and these structures are completely restored to their former position. The

FIG. 168.

FIG. 169.

FIG. 170.

FIG. 171.

FIG. 172.

FIG. 168.—Auto arm—high fracture. Note absence of impaction.
FIG. 169.—Auto arm. front view of Fig. 168. Note fracture through ulna with unbroken periosteum.
FIG. 170.—Auto arm. Both bones broken high. Shows futility of plating the radius alone.
FIG. 171.—Auto arm. Both bones broken low.
FIG. 172.—Auto arm. Separation through epiphysis. Taken after reduction.

tendon and median nerves are compresssed in the "wrist box" as a consequence, and the tendons pull out of line. The hand becomes numb.

The altered relation in the "pull" of the tendons is responsible for the varying degrees of disability which follow, most marked in old people. The disability leads to non-use of the hand and varying degrees

of ankylosis of the phalangeal and carpo-phalangeal joints. The narrowing of the "wrist box" is probably largely responsible for this condition, which is at a minimum, where the shortening is great and the wrist box correspondingly enlarged. Many cases are seen where the outward displacement of the hand is marked, yet with a functionally good hand.

Injuries to nerves are not uncommon, but serious lesions are rare. The ulnar as it passes over the head of the bone is often stretched, sometimes torn. This is followed by numbness in the ulnar distribution, with loss of function of its muscles.

Fig. 173.

Fig. 174.

Fig. 175.

Fig. 173.—Obliquity restored and radius lengthened by osteotomy through line of fracture. Separation maintained by celluloid plug which does not show on the picture.

Fig. 174.—Pianist with stray end of radius projecting among flexor tendons.

Fig. 175.—Same after operation. Obliquity restored and full length of radius obtained by "U" splint, as shown.

The disability is usually temporary, but where the injured nerve is caught under cicatricial bands or by callus, the lesion becomes permanent. The fingers assume the semiflexed position typical of ulnar paralysis, the interossii, lumbricales, adductor pollicis or short muscles of the little finger become atrophied, and the trophic changes in the skin are marked.

Primary injury to the median is not common, but it occasionally is subject to pressure sufficient to cause paralysis in its distribution. This pressure is sometimes due to the injudicious application of splints to an unreduced Colles', to the direct infringing of ill-placed fragments where the end of the radius is comminuted or to stretching, where the deformity is great and unreduced. As in the case of the ulnar, the paralysis becomes permanent if the nerve is imprisoned in the cicatrix. Cases where there is no immediate evidence of nerve injury, a gradual

onset of symptoms after some days suggests pressure from callus formation or cicatricial contraction.

The result of involvement of the median is a paralysis of more or less of the sensory distribution with trophic changes in the hand which are quite characteristic. The hand becomes stiff, the fingers rigid, and relatively cold, and there is total loss of power. There is usually marked loss of power of rotation. The skin becomes glossy and the seat of a burning sensation, relieved by cold-water applications. Atrophy of the skin is marked, the rugæ over the joints disappear. The X-ray shows changes in the bones like those of rheumatoid arthritis. This condition is usually diagnosed as rheumatism or traumatic arthritis, and is not often found in old people.

Forced movements with deep massage of the wrist under repeated anæsthetics may suffice to free the nerve. If it does not succeed, the nerve should be cut down upon, or freed from its cicatricial entanglements, after which it should be surrounded by non-contractile tissue to prevent a recurrence.

These cases are comparable to those described by Weir Mitchell under the term "causalgia" following the cicatricial contraction of gunshot injuries. See case by Hamilton (Median) Dublin Jr. Med. Sc., 1838.

The musculo-cutaneous nerve has also been injured in the same way with corresponding lesion in its distribution.

Chauffeur's fracture or auto-arm are names applied to the injury resulting from the backfiring of a gas engine while being cranked. There are two varieties, one due to a direct blow on the heel of the hand by the handle as it comes up. This causes a Colles' fracture in some cases with lesion and deformity similar to that produced by a fall on the hand. In other cases there is a fracture of both bones low down, or separation at the epiphysis in young adults. The second variety is due to a blow on the back of the arm by the handle of the backfired crank. In this variety both bones are broken at the point of impact usually 2 or 3 in. above the joint (picture). Auto-arm may be regarded as the first stage of a Colles' without impaction and rotation.

If the handle strikes the end of the radius it may break off the styloid alone or a long spicule with the styloid attached. If the blow is received lower down the bones of the carpus may be fractured, usually the scaphoid.

Diagnosis of Colles' Fracture.—This can usually be made directly from the presence of the "silver fork" deformity, which is character-

istic. From the side, the hand appears elongated, with a marked firm prominence in the back and a depression above it. The front of the wrist is bulging and soft. The fingers are semiflexed, and the hand as a whole displaced to the radial side and rotated slightly outward. Voluntary pronation and supination are painful and difficult or impossible, and passive extension of the fingers causes distress.

The ulnar side of the wrist is abnormally prominent, and the end of the ulna can be felt projecting against the skin. The wrist appears wider than normal. The relative position of the two styloids is of importance. Normally the radial styloid lies distinctly below the level of the ulnar. When, in the pronated arm, a line is drawn through the middle of the long axis of the radius, and crossed at right angles by a second line drawn through the tip of the ulnar-styloid, the tip of the radial styloid lies well below this second line. The articular surface of the radius makes an angle of about 15 degrees downward from it.

In Colles' fracture the tip of the radial styloid is found to be abnormally high, on a level or higher than the ulnar styloid, and often posterior to it, not in continuity with the shaft. This might be termed the Colles' cross. It is of importance in medico-legal cases where X-ray examination may fail to show other indications of a previous Colles'.

Pain on pressure over the site of the fracture is marked. Abnormal mobility and crepitus can both be obtained under an anæsthetic, but the attempt to obtain them without it is usually so painful, and the diagnosis so obvious from the deformity, that the necessity rarely exists. The exact lesions and the degree of displacement can best be determined by the X-ray, which should be used both before and after the reduction and in two planes.

Treatment.—An anæsthetic is a necessity. Impaction is the greatest obstacle to complete reduction and should be broken up by loosening the fragments from the shaft with the fingers, using force if necessary. The hand should then be clasped by the surgeon as in a handshake, and traction made upon the wrist, rotating the hand inward and forward, and carrying it toward the ulna side. With the fingers of the opposite hand, the fragment is pushed down and rotated into place. The "silver fork" deformity disappears, the outward rotation is easily corrected, and there is no tendency of either to recur. The lateral deviation, caused by the shortening of the radius is not so easily disposed of in some cases. The crushed cancellous tissue may offer little resistance and the hand swings to the radial side when relaxed, so that in order to maintain the normal obliquity of the articular surface of

the radius it is necessary to fix the hand in a markedly adducted position, which carries the lower fragment with its articular surface into the normal position.

The arm can be held by wooden splints or plaster of Paris. Most manufactured splints do not give satisfactory results, and with plaster of Paris the maximum adduction with slight flexion can be obtained, with the arm semipronated.

If the wood is used a dorsal splint narrower than the arm should be applied from just below the elbow to the carpo-phalangeal joints, and a ventral splint from a corresponding point on the front of the upper arm to the fold of the wrist, stopping just short of the hypothenar eminence. Pads are not necessary. The arm should be kept in the "thumb to mouth" position with the maximum adduction of the ulna. Perfect results may be obtained with these wooden splints. They should be rather loosely applied. The fingers must be unconfined, and movements active and passive insisted upon from the first. After the first week passive movements of the wrist should be begun and used daily. In three or four weeks the splints can be discarded, sometimes earlier.

Prognosis.—Union is usually prompt; an ununited fracture is almost unknown. The function of the hand is the point, and everything possible should be done from the beginning to keep the fingers in motion. Especially is this the case in aged and rheumatic women. Where the splints are removed daily after the first week, the function of the hand is rarely interfered with. Any tendency to stiffness should be met by immediate removal of the splints.

Poor results anatomically may give excellent functional results. Tight splints are an abomination, and by interfering with the tendons and nerves in the wrist box have often given poor functional results in spite of an anatomically good position.

In the repair of an *old* Colles' fracture the problem is the same as in the original setting, viz.:

1. To reduce the angular tilt of the radius backward and its abnormal rotation.

2. To restore its length and the normal obliquity of the articulating surface.

This can be done by a simple osteotomy of the radius, from the outer side, following as nearly as possible the line of fracture, where the angularity begins. The lower fragment can then be forced downward and forward, and rotated into position. By driving a dowel,

wedge of bone or celluloid into the cleft, the normal length of the radius will be obtained, and the normal obliquity of the articular surface restored. The osteotomy must be done in such a way as to hold the wedge firmly between the cut surfaces when the reduction is complete. It may be advisable to plate the radius along its external border, but the cancellous tissue holds screws poorly. A steel pin may be used in lieu of the plate (Lambotte). By this procedure the deformity is removed, the cramping of the wrist box is relieved, the tendons pull in a straight line through it, and the function of the hand is restored to a variable degree.

The most difficult cases are those where the ulna has been torn away from the radius and there is excessive broadening of the wrist, with the head of the ulna projecting under the skin. If the reduction of the rotation has been complete, this partly disappears but it may be necessary to raise the ulna head, remove some of the lax ligaments beneath it and replace it in a new bed, approximating the radius more closely.

If the shortening of the radius cannot be entirely obviated, the ulna can be exposed just back of the head, and enough removed to allow the articular surface of the radius to swing into its relatively normal position. Shortening is to be avoided if possible.

FRACTURES OF THE CARPUS

Fractures of the carpal bones occur both from direct and indirect force. Most frequently they are found associated with Colles' fractures where the force applied has been severe.

The scaphoid is most frequently fractured, and this may happen from a fall on the hand or from forced supination. The semilunar may also be fractured in the same manner, but more frequently is dislocated.

The X-ray is usually necessary to the diagnosis of carpal fractures, but great care must be exercised in making the plate. Both hands should be taken simultaneously with the hands pronated and the height between. Side views of both should also be taken and this may be needed at varying angles. The reason for this care is to be found in the occurrence of many anomalies in the carpal bones, variation in relative sizes, and the occurrence of unusual sesamoids. Even with the X-ray a fracture may be concealed by the overlapping of the bones or fragments in an ill-taken picture.

Fracture of the scaphoid alone may be recognized by a localized

tenderness and swelling over the scaphoid, obliterating the snuff box, with acute pain on adduction and extension of the wrist.

The fracture usually occurs about the middle of the bone and the distal (external) fragment may be displaced forward. Union is very uncertain. Where the bone is cracked without displacement it apparently unites, but where there is displacement there is no union. The position of a displaced distal fragment leads to permanent disability, which consists of limitation of the movement of the joint, especially in extension and adduction, and persistent pain.

The consequences of this fracture are often entirely out of proportion to its size, and great care should be devoted to its treatment.

Treatment should consist of the reduction of the outer fragment, if displaced. On account of the possible resulting disability, Lambotte has proposed an operation by which the two parts are fixed together with a pin inserted longitudinally through the bone and at right angles to the line of fracture.

Reduction failing, the open treatment should be adopted, and if Lambotte's proposal cannot be carried out, the distal fragment should be excised. If there is no displacement or if the distal fragment can be replaced, the arm should be splinted in a position of slight radial flexion. Passive movements of the wrist should be begun early.

In old cases where pain and ankylosis persist, as is the rule, the lower fragment or both should be excised. A good functional hand free from pain results.

Fractures of the semilunar are less frequent than of the scaphoid. The swelling and tenderness are directly over the semilunar. Reduction is easier than with the scaphoid, if early diagnosis is made. In old fractures, as well as in old dislocations of the semilunar, it is best to remove the bone.

The os magnum is sometimes crushed through force applied through the fingers, as well as by direct violence. Swelling and tenderness follow, and marked interference with the function of the hand. A prominence appears in the normal hollow over the os magnum on the back of the hand. In recent cases replacement can usually be made, but though unreduced the ultimate resulting disability is usually slight.

The remaining carpal bones suffer only from direct violence and the exact diagnosis is dependent upon the X-ray. They deserve most careful consideration, and often operative interference.

FRACTURES OF THE METACARPUS AND PHALANGES

Fractures of the metacarpals are common and result from direct blows or force applied to the ends or bases of the fingers. Direct violence usually gives a transverse fracture near the middle of the bone, while force applied to the fingers may give lesions at or near the heads of the metacarpals.

A blow when the hand is closed or a fall upon the knuckles of the closed fist may crush the heads of several. The twisting force applied alternately to the metacarpals by a fall on the fingers may cause spiral fracture beginning in the second and running seriatim through two or more of the others.

The fractured end of the distal fragment usually is displaced toward the palm while the distal end of the proximal fragment goes backward (flexion fracture), but where the force is directly applied to the ends of the metacarpals as from a "striking" blow, the displacement of the distal fragment may be backward and the proximal fractured end is displaced toward the palm.

Lateral displacement is frequent. Longitudinal, impacted and spiral fractures, and comminutions are all found, and fractures of several of the bones often coexist.

Diagnosis is unusually easy. Pain, deformity, swelling or marked ecchymosis are usually present. Crepitus can often be obtained. The sinking of the knuckle is diagnostic where one bone only has been fractured.

Separation of the epiphyses occurs. There is but a single epiphysis on each of the metacarpals, as well as on the phalanges. The epiphyses of all the phalanges and the first metacarpal are situated at the proximal ends of the bones, while on the second, third, fourth and fifth metacarpals it is situated at the distal end (picture).

An exact diagnosis of the extent of injury is best obtained by the X-ray.

Fracture of the first metacarpal at the base occurs from a blow on the point of the thumb. It is usually oblique, passing through the articular surface, but may be transverse and the shaft may be impacted into the base (Fig. 176). The oblique form is most common and had received the name of "Bennett's fracture." The small fragment with a part of the articular surface remains in place, while the shaft is driven backward and upward. The thumb is shortened.

Treatment.—Fractures of the second and fifth metacarpals can usu-

ally be manipulated into place, but are hard to hold in place. Where the deformity recurs or cannot be reduced a dowel can be easily inserted and holds the knuckle in line until union takes place (Fig. 181). In laboring men where the grip is of importance, care must be taken to obtain end-to-end union in straight position, and the open operation is, therefore, quite essential. After reduction, a large roller bandage placed in the palm of the hand is a serviceable splint.

Where the open treatment of a metacarpal fracture is inadvisable and there is deformity with shortening, extension may be employed to maintain a corrected position by applying adhesive to the front and

Fig. 176.

Fig. 177.

Fig. 178.

Fig. 179.

Fig. 176.—Fracture of first metacarpal at base. Side view.
Fig. 177.—Fracture of first metacarpal at base.
Fig. 178.—Fracture of the scaphoid.
Fig. 179.—Fracture of the scaphoid and pisiform, also tip of radius.

back of the finger, like a Buck's extension, and attaching to this a heavy band of rubber or rubber tubing. The rubber is fastened to the projecting end of a dorsal splint which should extend from the middle of the forearm to about 4 in. beyond the end of the finger.

Fracture of the first metacarpal (Bennett's fracture) deserves especial care. If evenly impacted and if shortening is not great it may best be left alone, but the oblique fractures through the articular surface must be fastened with a steel pin to obtain a perfect result.

Treatment without operation should be by immobilization in the hyperextended position with a light plaster splint.

Reduction should be made under an anæsthetic and the splint applied. Passive movement and massage should be begun as early as the end of the first week.

Fractures of the phalanges are of frequent occurrence, from both direct

and indirect violence. They may be transverse, oblique, longitudinal, or comminuted. Longitudinal fractures often run the entire length of the phalanx and involve the articulation at both ends.

A common fracture is of the shaft close to the articulation, with a longitudinal fracture of the fragment (T fracture). Crushing of the

Fig. 180.

Fig. 181.

Fig. 182.

Fig. 183.

Fig. 184.

Fig. 185.

Fig. 180.—Fracture second metacarpal bone in middle. Note callus.
Fig. 181.—Fracture fourth metacarpal in middle, showing method of fixation by dowel.
Fig. 182.—Fracture fifth metacarpal at distal end.
Fig. 183.—Fracture fifth metacarpal in middle.
Fig. 184.—Fracture second, third and fourth metacarpals in child.
Fig. 185.—Fracture second, third and fourth metacarpals in child. Result after treatment by roller.

bones is frequent in industrial accidents, the shaft splitting in two or more longitudinal planes and being crushed together. Crushing of the ends also occurs, and the adjacent ends of several phalanges may be simultaneously involved, the shafts escaping intact. This happens

where the hand is drawn between rollers. Many of the cases are compound.

These fractures are often of great importance, involving the integrity of the fingers of musicians and artisans, where an ankylosed joint may destroy their means of livelihood.

FIG. 186.

FIG. 187.

FIG. 188.

FIG. 189.

FIG. 190.

FIG. 191.

FIG. 186.—Fracture proximal end first phalanx of thumb.
FIG. 187.—Fracture distal end first phalanx of thumb. Inner half articular surface.
FIG. 188.—Fracture middle phalanx index finger with longitudinal fracture through proximal fragment.
FIG. 189.—Fracture middle phalanx of little finger.
FIG. 190.—Fracture of the base proximal phalanx of little finger.
FIG. 191.—Fracture in middle second phalanx of little finger.

Diagnosis is usually easy from the subcutaneous nature of the injury. Deformity, crepitus and mobility are usually unmistakable, but some fractures into the joints can only be determined accurately by the X-ray. Union is prompt in simple cases, apt to be delayed in compound, and non-union is rare.

Treatment.—Reduction and fixation on a finger splint is sufficient in most cases. When near a joint early passive movement and changes in the shape of the splint tend to prevent ankylosis. Where accuracy of setting and good functional results are demanded, steel pins may be used to hold the fragments. These may be passed directly through the bones laterally and kept in place until sufficient union has taken place to insure the length and approximation of the bone.

SECTION III

DISLOCATIONS OF THE UPPER EXTREMITY

By

A. F. JONAS, M.D., F.A.C.S.

DISLOCATIONS OF THE CLAVICLE

Dislocations of the clavicle are not frequent and usually occur between the ages of 25 and 50. In the author's experience, dislocations at the acromioclavicular joint are more common than at the sternoclavicular articulation. Dislocations at both ends of the clavicle at the same time are extremely rare. Several cases have been recorded.

Displacement of the sternal end of the clavicle does occur in the following directions: 1. Forward and upward; 2. upward; 3. backward. While displacement of the sternal end of the clavicle can occur in an upward and forward direction and in a backward direction, the most frequent dislocation is forward and upward. A forward dislocation is uncommon, a backward dislocation is very rare.

1. **Forward and upward dislocation** is more frequent than all other forms. It occurs when force is applied at the shoulder, forcing it backward. When falling on the shoulder, especially when the arm is thrown outward and backward or a severe blow is applied to the anterior surface of the shoulder or when falling on the extended hand, the force exerts itself on the sternoclavicular joint, tearing off its ligaments and joint capsule.

Physical Signs.—The sternal end of the clavicle can be seen projecting upward beneath the skin at the sternal notch. The shoulder falls forward. The projecting end, when grasped between the thumb and finger, is freely movable and, when the shoulder is pushed backward, the dislocated clavicular end can be pressed back into its sternal articulation but it immediately becomes displaced when pressure is released. Every movement of the shoulder moves the displaced bone. The diagnosis is easy and can usually be made by inspection alone.

Treatment.—The dislocated clavicle can be easily replaced by pulling both shoulders backward; this manœuver can be aided by placing the knee on the spine between the shoulder blades, at the same time making

pressure over the dislocated end. Reduction is easy, but it is often very difficult to maintain the bone in place. The most useful appliance has been found to be a carefully applied figure-of-eight bandage, which draws both shoulders backward. A firm pad in the form of a roller bandage applied over the dislocated end is held in place by a long strip of adhesive plaster. Another method, employed successfully by the author in one case, is to mould a lead plate over the sternoclavicular articulation, holding it in place by a roll of cotton bandage which, in turn, is immobilized by a long adhesive strap, passing from low down on the chest, over the shoulder and far down the back.

Sometimes all methods by external strapping and padding fail, when it becomes necessary to resort to an open operation. The articular surfaces are carefully denuded, a bronze aluminum wire is passed through drill holes in the clavicle and sternum and the bone is firmly drawn into place. The usual external retentive methods must be applied after the wound has been closed.

2. **Upward Displacement.**—This dislocation is due to a force applied to the outer end of the clavicle, suddenly depressing the shoulder, putting a severe strain on the sternoclavicular joint, tearing its ligaments and capsule, and thereby liberating the end of the bone.

Physical Signs.—The shoulder appears depressed; the sternal end of the bone has been pulled upward by the outer head of the sternomastoid and can be felt above the sternal notch in front of the trachea, sometimes interfering with breathing and deglutition. The end of the dislocated bone can be palpated without difficulty.

Treatment.—Local pressure over the sternal end of the bone may be tried by means of pads and lead plates held in place by adhesive plaster. To this is added a figure-of-eight bandage and elevation of the shoulder by means of a triangular bandage. These alone are usually unsatisfactory. Final union is imperfect. The result is usually a more or less loose joint admitting of a high degree of movement. In the author's opinion, the best form of treatment, provided an accurate aseptic operative technique can be followed, is to approximate the articular ends by a bronze aluminum wire through an open operation, followed by the usual external appliances to insure immobility.

3. **Backward displacement** is very rare. The author has seen only one case. In this case a blow was struck directly over the sternal end of the clavicle, forcing the head of the bone directly backward and slightly downward so that its lower margin rested behind the sternum. The dislocation was complete. It is possible to produce this displace-

ment by other means, for example, by a sudden blow or pressure on the outer and posterior side of the shoulder.

Physical Signs.—Like other forms of displacements of the clavicle this one is not difficult to recognize. The shoulder is inclined to fall forward. A depression is distinctly seen and felt at the sternal articulation. In the author's case, there was much pain on movement at the sternal end of the bone. There was complaint of dysphagia and dyspnœa. There was no absence of the radial pulse as has been observed by others. There was no cyanosis.

Treatment.—While reduction is usually easily effected by pressing both shoulders backward, this was ineffectual in the author's case. Manipulation under anæsthesia was unsuccessful. It became necessary to do an open operation. The incision, exposing the sternal notch and about 2 in. of the clavicle, revealed the head of the clavicle firmly wedged behind the sternal margin. Gentle leverage with an elevator liberated the bone which was then easily brought into place. The articular surfaces were removed with a chisel. A bronze aluminum wire was passed through drill holes in the clavicle and sternum, and the clavicle was easily drawn into its place and the wire twisted. The costoclavicular ligament was sutured with chromic gut and an unsatisfactory attempt made to suture the remnants of the sternoclavicular capsule. The wound was closed. After the application of the usual aseptic dressing, both shoulders were drawn backward with a figure-of-eight bandage, the elbow was elevated with a triangular bandage. Recovery was complete and uneventful.

Displacement of the Clavicle at its Acromial End.—Dislocation of the outer end of the clavicle may occur in three directions: 1. Supraacromial; 2. subacromial and 3. subcoracoid.

1. *The supraacromial dislocation* is the most common, the clavicle being displaced upward. On account of the small articular surfaces that make up the joint, the dislocation is usually, though not always, complete. It is usually caused by a direct blow or a fall upon the shoulder joint producing a laceration of the superior and inferior acromioclavicular, conoid and trapezoid ligaments and the joint capsule. The end of the clavicle is pulled in an upward direction by the trapezius muscle. If the structures are only partly torn, the dislocation is partial or incomplete. The latter condition is very rare.

Physical Signs.—In comparing both shoulders, it is observed that the outer clavicular end is lifted above the acromion and is surrounded by a swelling which, on palpation, is tender and painful, especially on

movement. The end of the bone can be felt to move backward, forward and downward. The shoulder often drops forward. In an incomplete dislocation, all these signs are present in a much less degree. The displaced bone can be easily reduced, but it slips out of place the instant that pressure is removed. In our examination, we must be certain that we can exclude a fracture of the outer end of the clavicle or of the acromion process.

"In the fractures of the outer end of the clavicle, a measurement of both clavicles should show the injured bone, apparently, to be the shorter one. The clavicles are apparently shorter if the measurements are made between points extending from the middle of the sternal notch to the acromion processes on both shoulders. If the clavicles themselves are measured from their extreme ends, there will be no actual shortening."

Should there be a fracture of the acromion process, it can be determined by palpation, usually the rough fractured surfaces can be felt and crepitus in most cases will determine the nature of the injury. If a comparative measurement is made of both clavicles, the injured side will appear shorter. The pain, on movement, is greater, and swelling is more pronounced at the point of injury. The displacement can be corrected by putting the arm against the thorax, placing the hand of the operator on the elbow and pushing it upward. In fleshy individuals, should any doubt exist as to the nature of the injury, a skiagram would reveal the exact location of the fracture.

In dislocations of the outer end of the clavicle, an inspection of both clavicles would show the injured bone apparently to be the shorter one. The clavicle is apparently shorter, if the measurements are made between points extending from the middle of the sternal notch to the acromion processes on both shoulders. If the clavicles, themselves, are measured from their external ends to their sternal attachments, there is no actual shortening. Crepitus, when present, points with certainty to a fracture. The deformity is not difficult to correct by lifting the arm.

Treatment.—A dislocation of the outer end of the clavicle can be easily reduced by pulling the shoulder backward, lifting up the arm and making pressure over the dislocated bone, but the displacement recurs as soon as support is removed. The author, in his experience, has found that a pad, composed of six or eight layers of gauze placed over the acromioclavicular joint and over this a lead plate moulded to it and fastened in place by a broad adhesive band that passes downward

in front and below the elbow and upward on the back of the arm to the point of commencement, will retain the dislocation in place. A broad adhesive strip should be applied around the arm immediately below the pectoralis attachment, pulled backward and attached to the back in such a way as to pull the shoulder backward. The arm should be flexed and fastened over the chest so that the finger tips rest against the opposite shoulder. The union between the ends of the bones is seldom perfect; the joint is more or less a relaxed and an excessively movable one. Sometimes in complete dislocations where all ligamentous and capsular structures are torn, permitting a wide separation of the joint surfaces, no form of external dressing is effective; in such, an open operation is indicated.

Operation.—An incision is made, perferably slightly above or below the joint so as to avoid having the skin suture line directly over the suture in the joint. The articular surfaces are denuded of their capsular remnants and other fibrous structures, so as to vivify the joint surfaces. A wire passed through a drill hole in each bone is twisted, thus coaptating the displaced bones. The practice of attempting to unite the ligaments and joint capsule with kangaroo tendon or chromic gut or silk appears ineffective on account of the difficulty of approximating the capsular margins. In two instances the author maintained the bones in place by passing a bronze aluminum wire through drill holes in the acromion process and end of the clavicle, taking great care to place the twisted ends of the wire on the lower surface of clavicle so as not to irritate the skin. In both cases the outcome was good; the wires have not been removed.

2. *Subacromial dislocations* are very rare; the writer has never seen a case. Very few are found in the literature.

The dislocation occurs usually when a blow is struck in a downward and backward direction directly upon the shoulder joint while the arm is extended in an outward direction. The outer end of the clavicle is found below the acromion process.

Physical Signs.—On inspection it is at once apparent that the outer end of the clavicle has disappeared. The contour of the shoulder has changed. It has dropped forward. The end of the clavicle can be palpated beneath the acromion process. The movements of the arm are limited and very painful. The brachial plexus may be compressed, causing more or less anæsthesia of the arm.

Treatment.—Reduction can be effected by the methods described in connection with other forms of dislocation of the outer end of the

clavicle. The dressings recommended in other forms of displacement of the outer end of the clavicle, are more or less effective and may be tried but, in the opinion of the writer, the only effective treatment is to wire the displaced bones.

3. *Subcoracoid dislocation* may be mentioned because of the possibility of such an accident, but it occurs so infrequently, that very few surgeons have ever met with it. In the event of such an occurrence, the diagnosis is easily made. The outer end of the clavicle is found in the axilla and under the acromion process. There is an absence of the clavicle at its acromial attachment. The shoulder drops forward and is immovable on account of the pain. Reduction may be effected by an extreme outward and backward pull of the shoulder but if this is not successful, an open operation should be performed.

Supraspinatus Dislocation.—The literature contains very few examples of this form of dislocation. Klar (Deutsche Zeitschrift für Chirurgie, LXXIII) discusses his personal experience and speaks of the rarity of this displacement. The outer end of the clavicle is crowded directly backward, as a result of direct violence and the bone is found below the spine of the scapula. Klar states that reduction is easily accomplished when the subject is placed on his back and the clavicle grasped and pulled forward. Retention is difficult. Any external apparatus is ineffective. It would seem that the only effective treatment is an open operation and the wiring of the clavicle to its articulation with acromion process.

Total Dislocation of the Clavicle.—By this condition is meant a dislocation of both ends of the clavicle at the same time and acquired in the same accident. The displacement is usually produced by great external violence, the force being exerted along the horizontal axis of the shoulders.

Physical Signs.—According to Stimson, "The sternal end has always been displaced forward, and the only additional change in position that is mentioned, is in Morel-Lavelleo's case, that it had moved rather upward than downward. The acromial end was displaced backward in four cases (once to a distance of three finger breadths), upward and outward twice, and once each forward and outward, downward and incompletely upward." On account of the superficial location of the clavicle, the diagnosis can usually be made by inspection. The dislocated ends of the bone can be seen. Palpation will quickly verify other visible signs.

Treatment.—Reduction, by pulling both shoulders backward, is

easy, but as in all other forms of clavicular displacement, maintenance of the corrected position is difficult. Any of the forms of retention dressings employed for other forms of displacements of the clavicle may be used, and in a large proportion of cases will produce satisfactory results. In most cases there is some deformity but the functional results are good.

DISLOCATIONS OF THE SHOULDER-JOINT

Before we begin the study of shoulder-joint luxations, it will be necessary to take into account several anatomic landmarks: (1) The head of the humerus. (2) The acromion process. (3) The conoid process of the clavicle. (4) The coracoid process. (5) The spur of the acromion on the scapular spine.

1. The head of the humerus can be easily felt as a firm rounded body under the acromion process. The greater tuberosity and sometimes the bicipital groove can be palpated when the arm is rotated or moved backward and forward.

2. The acromion process is the most conspicuous landmark about the shoulder-joint. Any disturbance in its relation to other structures of the joint, is instantly recognized. The shoulder may be greatly swollen or thickly covered with muscle and fat but the acromion still remains the most marked guide in our examination and assists us in locating the position of the humeral head.

3. The conoid tuberosity of the clavicle is directly above the coracoid process and affords attachment for the conoid ligament. It sometimes serves as a guide in finding the coracoid process below and the spur of the scapula behind.

4. The coracoid process can usually be found by palpating with the thumb or the index-finger below the clavicle, immediately beneath the conoid process. It is easily palpable unless there is a dislocation forward of the head of the humerus.

(5) The spur of the acromion on the scapular spine is a prominence on the posterior margin of the spine of the scapula and forms a prominent point under the skin on a line directly posterior to the tip of the coracoid process.

These landmarks are arranged about the shoulder-joint, which is composed of the head of the humerus and the glenoid cavity. The glenoid does not usually exist as a cavity, even when its cartilaginous rim is unusually developed. It is very small when compared to the head of the humerus, is little more than a point of contact and, of itself, could not hold the humeral head in position. It is not at all comparable

to the acetabulum which fits snugly to the femoral head. The freedom of movement of the joint, is due, in part, to the wide and elastic capsule. The head of the bone is maintained in place, aside from its capsule, by the acromion and coracoid processes, assisted by the strong ligaments between them. The following muscles assist in forming a sort of a socket: viz., in front, the subscapularis; behind, the supra- and infraspinatus and the teres minor. The deltoid envelops the outer side of the joint. These muscles are attached to the upper end of the humerus; the subscapularis is closely adherent to the capsule, materially strengthening it, and preventing it from becoming folded between the articular surfaces. The joint is further strengthened by the coracohumeral ligament and the supraspinatus, filling the triangular space between the head of the humerus and the coracoacromial ligament. It plays a rôle similar to the Y ligament in hip-joint dislocations.

Dislocations of the shoulder-joint are more frequent than dislocations of all other joints combined. They occur more often in men than in women, are most common between the years of 20 and 60. This is accounted for by the greater liability to accident of men engaged in physical labor. Displacements of the shoulder-joint are of many varieties. When one considers the various occupations of men, and the great force that they are sometimes exposed to, it is not difficult to imagine extreme and unusual luxations, even to the driving of the head of the humerus into the thoracic cavity. Clinically we have found that the number of directions in which the humeral head is displaced is limited. A simple dislocation directly upward without fracture seems practically impossible. The joint is not only restricted by the overhanging of the acromion process, but is protected by the unusually strong coracoacromial ligament. In spite of this unusual protection, luxations in an upward direction have been observed.

Dislocation of the head of the humerus directly downward occurs only when the triceps is torn off, an accident that is very infrequent. There remain two other principal directions in which the head of the humerus may be displaced, viz., forward and backward. The latter is extremely rare on account of the firm attachments of capsule and ligaments to the posterior margin of the glenoid cavity.

When we consult the literature in reference to classifications of shoulder dislocations, we are overwhelmed by the multiplicity of varieties. Almost every author differs. It is interesting to note some of the many varieties. At least 15 types having been described as follows: "Subcoracoid, intracoracoid, subclavicular, supracoracoid, subglenoid, axil-

FIG. 192.—Subcoracoid dislocation of humerus.

FIG. 193.—Subacromial dislocation of humerus.

lary, supraglenoid, luxatio erecta, retroglenoid, superior and inferior, subacromial, retroaxillary, subspinous, intrathoracic, subtricipital" (Cotton).

These varieties are confusing and impractical. Many of the distinctions cannot be made out clinically; therefore, we must use a more practical and simple classification and avoid the above more or less imaginary anatomical distinctions. The following would seem to comprise the principal types as found in our daily work; they are arranged according to their relative frequency.

1. Dislocations forward. Usually subcoracoid (Fig. 192), seldom intracoracoid and very rarely thrust into the thorax.

Fig. 194.—Subglenoid dislocation of humerus.

2. Dislocations backward. Uncommon. May be subacromial (Fig. 193) or subspinous.

3. Dislocations downward. Uncommon, known as subglenoid (Fig. 194), and luxatio erecta (Fig. 195) (Middledorpf).

4. Dislocation upward. So infrequent that many surgeons with a large service of emergency surgery, have never seen a case.

The vast majority of shoulder dislocations are caused by indirect violence and occasionally by muscular action alone. Very few are caused by direct violence. In the majority of cases there is a fall on the outstretched hand while the arm is abducted and rotated outward. The full weight of the body is thrown on the head of the humerus at a

point on the lower and inner margin of the glenoid cavity, lacerating the joint capsule at its weakest part. There is an immediate contraction of the pectoralis major and minor, the latissimus dorsi and deltoid muscles, pulling the head of the humerus forward into a position beneath the coracoid process. This is the most common position of the dislocated humeral head. The position of the head is also determined by a secondary force. Usually the elbow is immediately brought to the side of the thorax, thus determining a subcoracoid position. Should the elbow be forced further toward the median line immediately after the humeral head has left the joint capsule, the bone might pass upward to the outer side of the coracoid process and possibly beneath the clavicle.

Fig. 195.—Luxatio erecta.

When we study recent shoulder-joint dislocations, we find that the capsule sustains an extensive rent on its lower and inner border, between the long head of the triceps and the subscapularis. It is possible but not very probable that dislocations may take place without a laceration of the capsule; several such cases are reported by Stimson.

The infra- and supraspinatus, the subscapularis and teres minor are often more or less contused and lacerated. The long head of the biceps is sometimes displaced from its groove but is not often torn. The greater tuberosity is often torn off, favoring a displacement of the biceps tendon which may be wedged between the articular surfaces making a reduction difficult if not impossible. There may be a penetration of the subscapularis, by the humeral head. It is questionable if the breaking off of the tuberosity occurs by a rotatory mechanism alone. It would seem that a rotatory and inward thrusting movement and an impingement of the tuberosity against the margin of the glenoid cavity in its passage out of the joint cavity is the principal mechanism.

Recently it has been shown by röntgenoscopy that fracture of the surgical and anatomic neck of the humerus and glenoid cavity are not infrequent complications. We find (British Medical Journal, June 16, 1906) in a review of 200 complicated shoulder dislocations, that the radiographs showed 22 fractures of the upper humeral end. Of these there were 16 in the surgical neck. Robert Jones arranged these fractures in the order of their frequency as follows: (*a*) fractures through the

surgical neck; (*b*) separation of the greater tuberosity; (*c*) fracture through the anatomic neck embracing the tuberosities; (*d*) fracture through the neck of the scapula, embracing the coracoid; (*e*) separation of the lesser tuberosities; (*f*) separation of the anatomic neck, not including the tuberosities.

Injuries to the blood-vessels and nerves are not common but still they occur with such frequency that we must not overlook their possibility. Both the axillary artery and vein and branches of the brachial plexus may be involved. The author has encountered no injury to the axillary vessels, but has seen several patients in whom branches of the brachial plexus had been so contused as to manifest a more or less prolonged numbness of the arm and hand.

Diagnosis.—If we keep in mind the anatomical landmarks described above, we can, in the vast majority of cases, make a clinical diagnosis in all individuals who are not too fat. As a rule we can exclude complications if a reduction is easily affected and the bone remains reduced. Should there be difficulty in reduction or if the reduction cannot be maintained, the probabilities are that we have one or more of the complications noted in the above list by Robert Jones. A skiagram should be taken at once to determine, if possible, the nature of the complication. The clinical diagnosis should always be made before a skiagram is made. The tendency, by many surgeons, is to make a superficial examination because an X-ray will always clear up the nature of the injury. Our patients are often some distance away from an X-ray plant and its use is not available; therefore if we have neglected to cultivate clinical signs, we are helpless. Laboratory refinements have a tendency to lead practitioners away from the study of physical diagnosis.

1. **Dislocation Forward.**—*A. Subcoracoid.—Diagnosis.*—The diagnosis is not difficult. As soon as one sees the patient, it is at once apparent that he has sustained a shoulder-joint injury. His head is inclined toward the injured side and he holds the forearm of the affected arm with his other hand (Figs. 196 and 197). When we compare both shoulders we find that the painful one has lost its normal rotundity. Since the contour of the normal shoulder is dependent on the humeral head and the overlying deltoid, we find that a loss of the form of the shoulder can be explained only by an absence of the head of the bone from the glenoid cavity or by an atrophy of the deltoid muscle. To differentiate between an atrophy of the deltoid and a luxation, only a single digital contact is required. If one presses beneath the acromion

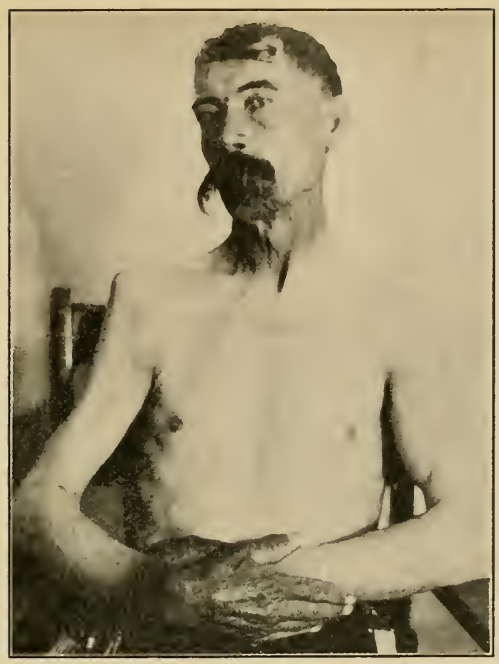

FIG. 196.—Subcoracoid dislocation of humerus.

FIG. 197.—Subcoracoid dislocation of the humerus.

with two finger tips, the humeral head is found to be absent; instead of a round hard body, a cavity is felt. The head of the humerus is not in its normal position. If we search from behind, immediately under the lateral end of the spine of the scapula, we can palpate the posterior margin of the glenoid cavity, which has remained in its normal position, but the head of the humerus is missing. If we observe the patient from in front, we find the axis of the arm is no longer vertical and in the direction of the glenoid cavity, but points toward the junction of the outer and middle thirds of the clavicle. We must find the head in this direction. At a glance we observe that the fossa infraclavicularis is filled and bulges slightly outward and we instantly conclude this bulging to be due to the head of the humerus. The palpating finger at once detects the head under the coracoid process as a smooth, rounded, hard bony mass. If we grasp the arm and make passive movements, this rounded bone mass turns and moves with each movement. We are then certain that the humerus head has left its contact with the glenoid cavity and now rests under the coracoid process. The bone was forcibly driven out of its joint, the capsule was torn on its median side, allowing the head to escape. While we have made our examination from behind forward, we sometimes proceed in the opposite direction by beginning at the coracoid process and proceeding in a backward direction. At other times we begin with the axis of the humerus and proceed upward to the new position of the head. It matters little at which point we begin so long as we keep in mind the typical landmarks.

While we have noted the cardinal signs, we still have other symptoms of importance to corroborate our diagnosis. If we note the configuration of the injured region, we observe a changed appearance of the anterior axillary wall. It appears longer; this is due to the fact that the head has been pushed toward the median side; the humeral insertion of the pectoralis, which forms the anterior axillary fold, being approximated to the median line, causes the soft parts to partially fold together. A similar condition is found in the posterior wall. While the head rests under the coracoid process, the distance from the clavicle to the pectoralis margin appears long. The humerus appears considerably but is only slightly longer than its fellow; sometimes it is really shorter; this sign is unimportant. A more important sign is the mobility of the arm. On account of the great pain and muscular rigidity, movements are very limited. We find that abduction and elevation forward of the arm are impossible. The arm can be moved only backward and forward to a limited degree. Adduction is possible

only to a very limited degree. Limitation of movement is one of the important physical signs. It often distinguishes between luxation and fracture of the neck.

B. Intracoracoid or Subclavicular Dislocation (Fig. 198).—The latter are very uncommon. The physical signs are very much like those of subcoracoid, with this difference, that the arm is less abducted, and the humeral head can be felt to the inner side of the coracoid process. If we include under this caption those cases where the head of the humerus is so placed that two-thirds or three-fourths of its transverse diameter lies

FIG. 198.—Intracoracoid dislocation.

to the inner side of the coracoid process, as was done by Malgaigne (Stimson), then, of course, we have a much larger percentage of intracoracoid dislocations. But if we regard only those where the entire head is internal to the coracoid, we have very few indeed.

This injury is usually caused by hyperabduction of the arm. We have the same forces that produce subcoracoid dislocations but in an exaggerated form. The head is forced further forward on to the chest; then, when the elbow is lowered and the arm abducted, the head of the bone passes under the subscapularis and to the inner side of the coracoid process.

2. **Backward Dislocations.**—These are usually known as subacromial and subspinous dislocations. In the subacromial type the head passes out of the glenoid cavity through a rent in the posterior wall of the capsule and locates itself beneath the acromian process. In the subspinous type, the head lies under the spine of the scapula. The axis of the humerus, at its upper end, is inclined backward; the lower end of the axis, at the elbow, points forward. In both types, but especially in the subspinous, there is adduction and limited mobility of the arm. The acromion and coracoid processes are prominent and conspicuous. The glenoid cavity cannot be felt because the upper end of the humerus rests against it. The humeral head is palpable behind and below the acromion, when the arm is rotated.

3. **Dislocation Downward** (*Luxatio erecta*).—Middeldorpf designated this form of displacement as luxatio erecta. The humeral head is displaced downward; the arm is directed upward; and the hand rests on the head. This form is extremely rare. The author has seen only one case. The subject, a carpenter, was coming down a ladder when one of the rungs broke off, the full weight of the man was thrown on to the right arm while holding on to a rung above his head. He saved himself from a fall to the ground by clutching a rung further down with the left hand. He found that he could not bring his right hand down to his body and was brought to the writer with an uplifted arm. The head of the humerus could be felt under the glenoid cavity. Under ether narcosis the dislocation was easily reduced by making upward extension and then, while continuing the traction, by bringing the arm in a curve from above outward and downward, at the same time lifting the humeral head into the glenoid cavity.

Subglenoid is a very rare form of displacement. The head of the humerus has been crowded downward and rests against the upper part of the axillary scapular border with the triceps on its outer side. Von Pitha, quoted by Bardenheuer, says that he had seen it only in cases in which he had an opportunity to examine the patient immediately after the accident and before any movements had been communicated to the limb or attempts made to reduce it (Stimson). The author has seen one case. The arm was both apparently and actually longer than its fellow. The shoulder was flat. The humeral head could be felt below and posterior to the glenoid cavity. As the elbow was lifted preparatory to reduction, the head slipped to a subcoracoid position. Kocher's method of reduction failed, probably on account of the capsular rent

being on the lower glenoid margin. Outward traction with scapular fixation succeeded.

4. **Upward Dislocation.**—This dislocation is so rare that one is disinclined to give it a place here. Dislocation upward without fracture of the acromion process is impossible. The few cases recorded were all complicated by an acromial fracture and extensive laceration of the deltoid and capsule. The lesion appears to be caused by a direct thrust upward as by falling on the elbow. The diagnosis would not seem to be difficult. Nor would the reduction offer any difficulties unless broken bone fragments should be crowded between the articular surfaces. Downward traction will effect a replacement.

Treatment and Methods of Reduction in Anterior Dislocations.—1. Richet's method, also known as the direct method. The patient sits

FIG. 199.—Sir Astley Cooper's method.

on a chair; the surgeon stands in front of him. He holds the dislocated humerus gently with one hand, then grasps with his other hand the head of the humerus in the axilla and presses it directly into the glenoid cavity. This can be done only in recent cases and where there is no muscular resistance. Where the latter condition is present, an anæsthetic will be required. The writer has succeeded several times by this method. In others the simplest outward traction sufficed.

2. La Mothe's method, also known as the elevation method, a very old one, was known to Celsus and practised by Prunus in the 13th

century. The subject may be sitting or in a horizontal position. The scapula is fixed by an assistant. The dislocated arm is slowly elevated to nearly a horizontal position, a strong pull being exerted on the arm by an assistant so as to move the humeral head into the glenoid cavity where it becomes prominent, the arm is then rolled outward, while the operator with his thumb on the head of the bone, presses it into its place. The arm is then lowered to the side of the body.

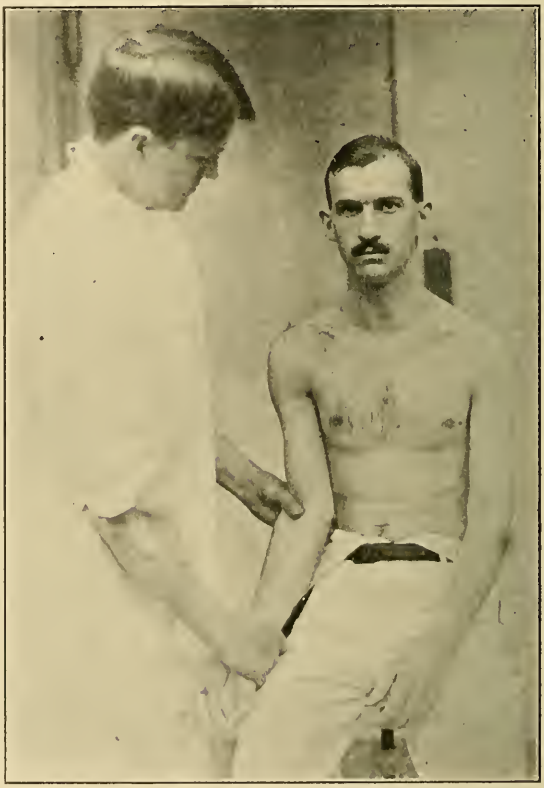

FIG. 200.—Kocher first movement. The arm is brought down by the side.

3. Sir Astley Cooper's is the old Hippocratic method. The injured one lies on a table or on the floor (Fig. 199). The operator places his shoeless heel into the axilla, against the humeral head; the dislocated arm is then grasped and pulled downward and forward. In recent cases this manœuvre succeeded very well. The method has been modified so that the subject sits in a chair, the arm is abducted, a pad is placed in the axilla and the arm is pressed and pulled downward against the body. Sir A. Cooper modified the latter method. He stood behind the patient,

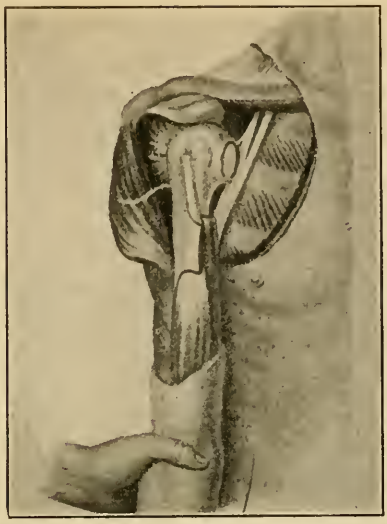

FIG. 201.—Adduction of the arm until the region of the elbow comes in contact with the trunk, which is in a straight position (step I). No material change in the position of the head of the humerus is produced by this step. (*Helferich.*)

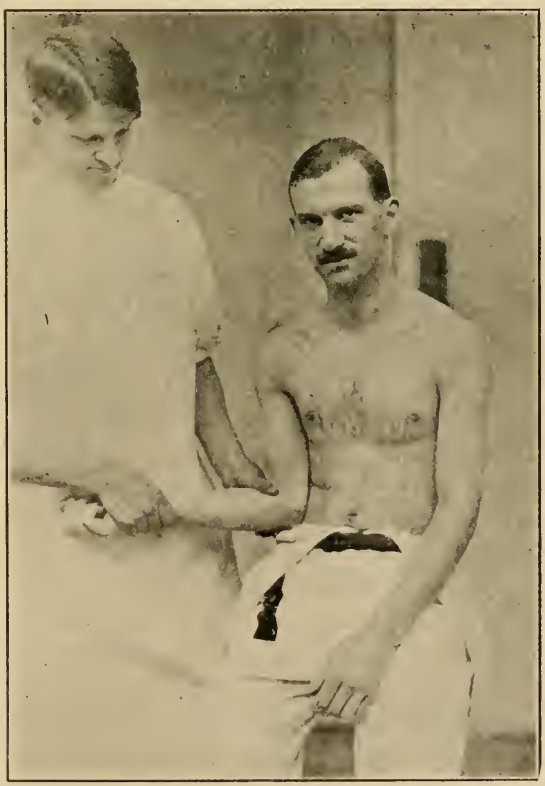

FIG. 202.—Kocher second movement. The forearm is flexed to a right angle, it is swung outward as far as possible rotating the humerus head toward the glenoid cavity.

placed his knee in the axilla, fixed the shoulder with one hand and forced the arm down with the other.

4. Schinzinger's method antedates Kocher's. He rotated the arm outward as far as possible, pulled the hand outward to a line posterior to the elbow and then pressed the humeral head upward and outward with the fingers resting on the head; or he turned the arm inward, the head being held and pressed into place while the arm was rotated inward. He did not place the elbow on the chest before rotating as Kocher did later.

5. Kocher's method. Rotatory manœuvre. The patient is in a sitting position. His shoulder is fixed by an assistant, who stands on

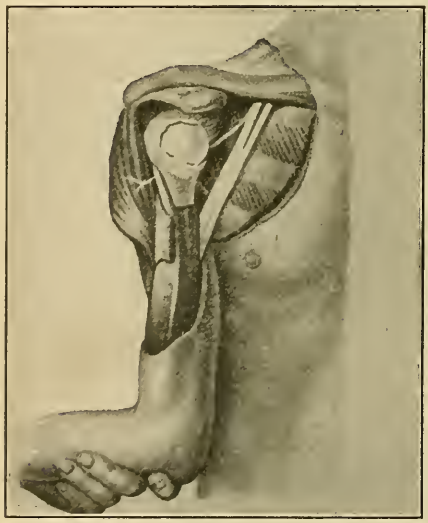

FIG. 203.

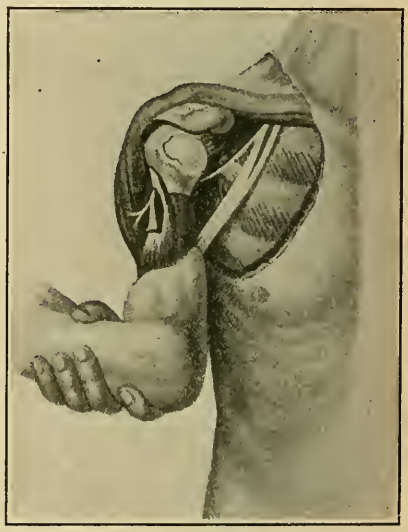

FIG. 204.

FIG. 203.—Outward rotation of the adducted arm by means of the forearm flexed at right angles (step II), until the forearm approximately occupies the frontal plane of the body. The opening in the capsule is plainly visible; the head has moved nearer the acromion and further away from the brachial plexus. (*Helferich.*)

FIG. 204.—Elevation of the arm held in adduction and outward rotation (step III), in other words, the arm is raised and directed forward. This partially reduces the dislocation. (*Helferich.*)

the side of the unaffected shoulder and places one hand in front, the other behind the chest of the subject, so that they meet under the affected shoulder. The operator stands before the patient. If the right shoulder is affected, the surgeon places his left hand under the elbow (Figs. 200 and 201). With the right hand he grasps the forearm near the wrist, and bends the elbow to a right angle; the arm is in a vertical position, the forearm is in a horizontal plane pointing forward and the

elbow is pressed firmly against the body. The arm is now rotated outward by moving the forearm, still in horizontal flexion, outward and backward as far as possible, so that the elbow approaches or touches the scapular angle (Figs. 202, 203 and 204).

By repeated pressure of the elbow in this direction, the capsular rent will be opened. The arm is now brought forward, without changing the angular flexion of the arm. The elbow is pushed forward toward

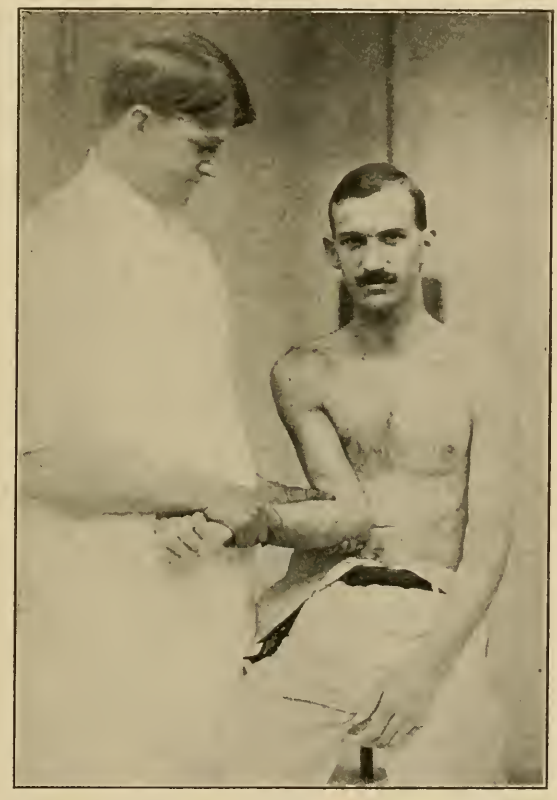

FIG. 205.—Kocher third movement. The elbow now brought as far as possible toward the median line.

the median line as far as possible (Figs. 205 and 206). Now the forearm is turned quickly inward, so that the hand of the affected arm rests in the opposite pectoral region (Fig. 207). In recent cases, this procedure can be carried out without an anæsthetic. The writer has found in several cases where the luxation had existed from one to three days that an attempt, in a sitting position, was so painful and the muscles so rigid, that an anæsthetic was necessary. The same movements were

successfully carried out while the patient was in a recumbent position on a table.

6. König's hyperabduction method is carried out as follows. While the subject is lying on his back on a table, the surgeon grasps the arm while an assistant fixes the shoulder, including the shoulder blade. The surgeon pulls the affected arm slowly outward to a hyperextended position; an assistant standing at the head of the patient, places his hand on the humeral head, fixes it and pushes it into the glenoid fossa while the surgeon quickly adducts the arm. The writer reduced his first case of shoulder dislocation in this way. It was easily accomplished, even in a very muscular subject.

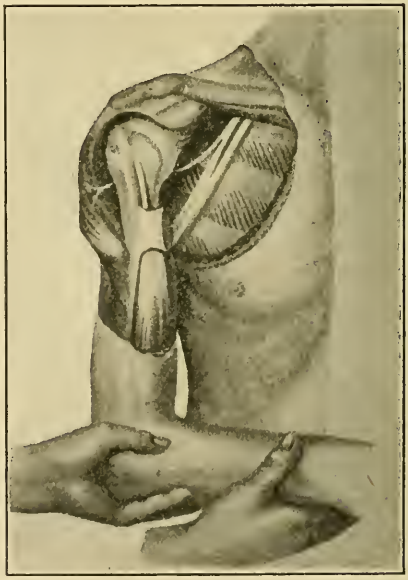

FIG. 206.—Inward rotation completing the act of reduction (step IV). (*Helferich.*)

7. Simon's *pendel methods.* The patient is put on the floor and his unaffected arm is fastened to his side with a bandage, so that he cannot use it. An assistant stands on a chair, grasps the affected arm by the wrist and pulls it upward. The operator grasps the shoulder-joint and assists in pushing the humeral head into the capsule by direct pressure. Malgaigne pursued a similar plan long before Simon. If reduction was not effected by a vertical upward pull as described by Simon, the bascule was used. Malgaigne placed the patient in a standing position beside a door and the arm was raised vertically by a strong band fastened to the elbow or wrist and carried over the top of the door. The

patient was instructed to flex his knees, so as to support the entire body weight by the affected arm. Sometimes an assistant added his own weight by clasping his hands over the shoulder of the patient. These methods have never become popular on account of the danger of increasing the lacerations of the subscapularis and the joint capsule and the further danger of injury to the axillary vessels by overstretching them over the head of the humerus.

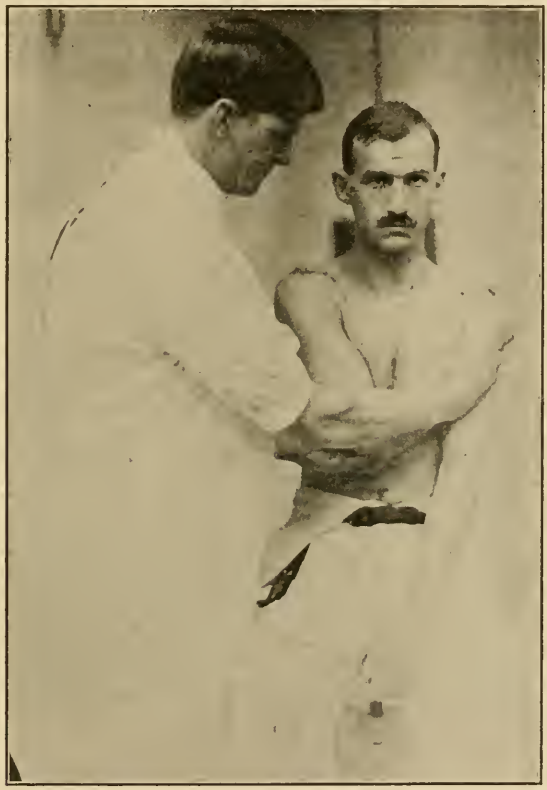

FIG. 207.—Kocher fourth movement. The arm is now swung inward rotating the humeral head so that it returns through the torn capsule to its normal position.

8. Hofmeister's traction method. The injured one is placed in bed. Adhesive plasters are applied to the affected arm. Twenty to 40 pounds of weight are attached to the plaster by means of a cord and this is hung over a pulley. In a few minutes, sometimes three-quarters of an hour, replacement occurs.

9. Hochenegg describes a method as follows. He places the patient in a chair, with the well arm resting over the back of the chair. The

shoulder is fixed by means of linen sheets, one around the thorax, one over the shoulders; these are pulled by an assistant. Another assistant standing on the unaffected side, holds the dislocated shoulder fast. A skein of yarn is placed around the arm above the elbow-joint with which a third assistant makes traction in a horizontal plane. The surgeon places his finger in the axilla and pushes the head of the bone into its place.

10. Stimson's downward traction method. "A round hole 6 in. in diameter is made in the middle line of a canvas cot about 18 in. from one end, and through this hole the injured limb is passed so as to hang



FIG. 208.—Stimson's downward traction.

vertically downward (Fig. 208). The patient lies on his side on the cot. At the wrist or elbow is attached a weight of about 10 pounds, and the cot is raised on blocks so that the arm will be free from the floor. In a few minutes, never more than six in my experience, reduction of the dislocation takes place quietly and without pain during the waiting." (Stimson, "Fractures and Dislocations," pp. 585–1910.)

11. Traction with weight and pulley, according to Duplay. This method is out of date and is introduced here only on account of its historical interest. "Pulleys are made fast to the arm above the elbow by a broad leather band buckeled tightly around it by a strap or band

made fast by several turns of a wet bandage. As a furt er precaution against slipping, the forearm should be bandaged and the elbow fixed at a right angle. It is also advisable to interpose a dynamometer between the pulleys and the limb to indicate the amount of force that is being employed and a pair of 'liberation forceps' to allow the traction to be suddenly relaxed" (Stimson). The other pulley is fixed by means of a screw in a door frame. The body of the subject must be held by one or more assistants while the operator pulls on the rope.

Of the foregoing methods, the writer has found the Kocher method to have been of the greatest service in all recent subcoracoid dislocations. He has never failed to effect a reduction in uncomplicated cases. The replacement has been equally successful whether the patient was in a sitting or recumbent position.

The after-treatment has consisted in fixing the arm over the chest so that the hand of the injured arm rested against the opposite shoulder. The arm should always be placed in such a position that the humeral head can exert little or no pressure on the rest of the capsule; therefore the form of dislocation must be taken into consideration. The arm should be fixed to the body by means of a firm bandage for from three to six weeks, giving the injured capsule time to undergo repair. It is advisable to begin passive motion about the third week after reduction.

Recurring dislocations or habitual dislocations occur more often in the shoulder than in any other joint.

This is a class of cases where the dislocation tends to recur even after only trivial injury. The primary luxation is caused by a violent trauma. In the author's experience, the subcoracoid type is the most common. According to some authors, the posterior type furnishes the larger number (Stimson). The causes given by the majority of authors are: (*a*) defective repair of the rent in the capsule, which may be due to a very extensive capsular tear and to an infolding of a part of the capsule; (*b*) laxity of the joint capsule; this is a theoretical cause and it may or may not be present. (*c*) Jössel found, in anterior dislocations, the capsule enlarged in its upper portion, due to rupture and laceration of the attachments of the supraspinatus and infraspinatus muscles, producing a laceration of the capsule at the same level and causing a free space between it and the subcoracoid space. He studied five autopsy cases, where there had been habitual dislocations during life (Deutsche Zeitschrift für Chirurgie, 1880, Vol. XXII, p. 167). (*d*) Others have shown cases where an enlarged capsule formed an imperfect closure of the tear at the inner and lower margin of the glenoidal margin

(Turner Thomas). (*e*) Many specimens of changes in the humeral head and glenoid fossa have been shown. These changes are often due to fractures and loss of substance. There is either a permanent displacement or an absorption of small broken off particles of bone leaving a defect in the glenohumeral articular surfaces. Cases have been reported by Volkman, Kuster, Cramer, Lobker and others.

Treatment.—Resection of the head of the humerus has, perhaps, been performed more frequently than any other method. The results are good as far as function is concerned. The shoulder is flattened and the arm is first elongated, but as cicatricial contraction takes place, there may be final shortening. Perthes sought to restore the normal relations of the lacerated structures (Deutsche Zeitschrift für Chirurgie, Dec., 1906); Hildebrand attempted to enlarge and deepen the glenoid cavity and restore the capsule; Ricard made a tuck in the relaxed capsule.

The writer has found that the best approach to the shoulder-joint is offered by an incision over the pectoro-deltoid interval. Through this the joint and the axillary contents can be exposed. The upper end of the incision should reach to the acromioclavicular articulation. The wound margins can be widely separated and the humeral head and the joint capsule can be inspected. The next step, in the operation, depends on the findings. Any of the methods described may be followed. If, in the joint capsule, there is a rent through which the humeral head passes in and out, it should be sutured. If the capsule is infolded, it should be trimmed. If muscle tissue covers the glenoid cavity, it should be separated and pushed aside and an attempt at replacement should be made. If the capsule is torn beyond repair and no other neighboring soft structures can be used to hold the head of the bone in place, a resection of the head of the humerus should be made.

Compound dislocations are very rare. The writer has never encountered one. The external wound is said to be in the axilla or through the pectoralis major and sometimes on the posterior aspect of the joint. The diagnosis is made at first glance. The treatment will depend chiefly on the wound. Reduction is not difficult but the care of the wound requires the highest antiseptic technique. It may not be so difficult if the protruding head has not been pulled back under the skin. If the head has been pulled back, infection has always been carried into the wound. The head should be thoroughly irrigated and asepticized before reduction. If the humeral head has been reduced, the wound must be enlarged so as to gain access to the deeper parts

for thorough irrigation and disinfection. After thorough wound preparation, through-and-through drainage from the most dependent parts is imperative. A good-sized, well-perforated rubber drainage tube must be used. The after-care is as usual.

Dislocation of both Shoulders Simultaneously.—Stimson states that he has found the records of five cases in the years 1880 to 1885. The accident is very rare and it would seem that the methods and principles followed for diagnosis and treatment in single dislocation would apply for the double lesions.

Old Irreducible Dislocations of the Shoulder-joint.—Old dislocations of the shoulder-joint comprise a class of cases where the humeral

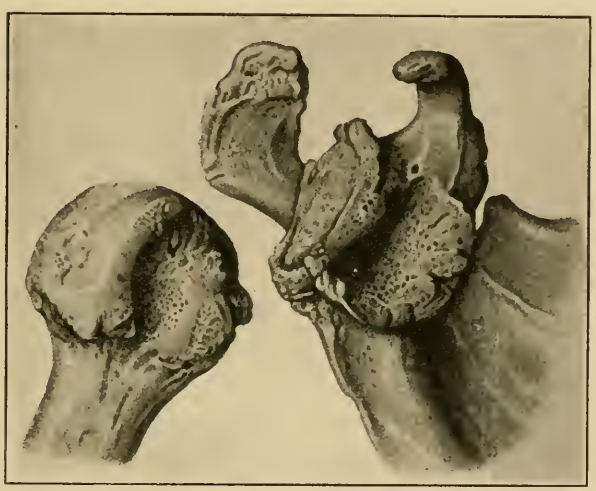

FIG. 209.—New socket formed in a case of irreducible subcoracoid dislocation of the shoulder-joint. (*Helferich.*)

head has been forced out of the glenoid cavity and has not been replaced. The head of the humerus may have escaped over the glenoid margin through a rent in the joint capsule in any direction; usually, however, it escapes over its anterior edge and rests between it and the coracoid process (Fig. 209). We understand by old unreduced luxations all cases which have not been reduced immediately, that is, within a month, because many of them, if not all, become irreducible by manipulation in that time.

The writer reported 11 cases and their results in the Annals of Surgery (June, 1910). In all of these cases attempts at reduction by the various forms of manipulation had been resorted to before an open operation was undertaken. The anteoperative methods chiefly relied

upon were rotation and circumduction with manual traction in various directions while the shoulder blade was supported by an assistant or a bandage.

Great care must be employed in manipulation because the axillary structures in some instances have become closely adherent to the head of the humerus and a sudden release and replacement of the head of the bone, after having been dislocated many months, might injure vessels and nerves by tearing them at their points of adhesion.

The Kocher method was found to be ineffective on account of the firm adhesions of the humeral head in its subcoracoid location and the firmness with which the margins of the capsular rent cling to the humeral neck. It is dangerous on account of the possibility of breaking off the head, as did occur in one of our cases, and of injury to the axillary contents, as has often been recorded. When manipulation failed, an operation was performed. The findings were as follows: the torn capsule was usually thick, making dissection difficult; there was excessive fibrous tissue about the neck and head; the head was usually deeply seated in close contact with the axillary vessels and nerves and sometimes adherent to the ribs; the muscles were usually atrophied and contracted and offered a decided obstacle to reduction; fractures of the tuberosities and of the margin of the glenoid cavity were found; the glenoid cavity was often filled with fibrous tissue and parts of the torn capsule.

The methods of procedure may be as follows:

1. The method of choice, when possible, is to replace the humeral head in the glenoid cavity, because it restores the bone to its normal position and seems to promise the best functional results.

2. The head of the bone may be excised by separating it from the humeral neck at the surgical neck thus producing a pseudarthrosis, which gives a very wide range of motion, but at the expense of the strength of the shoulder.

3. In cases where the humeral head has become firmly adherent to the coracoid process and ribs, an osteotomy may be made, severing the head of the bone, leaving it undisturbed in its subcoracoid location and then placing the upper end of the humerus in the glenoid cavity, thus insuring a false joint.

The anterior route was used in most of our cases. An incision through the pectoro-deltoid depression, with division of some muscular bundles was found to be the easiest operation.

DISLOCATION OF THE ELBOW-JOINT

The forms of elbow-joint dislocation are very numerous. One or both bones of the forearm may be displaced. When both bones are luxated, both may be dislocated in the same or in opposite directions. Both bones may be displaced backward (the most frequent form); inward, outward or forward, making four forms. Another, but rare form, is described by some authors as a rotatory dislocation; here both bones are displaced in the same direction and then become rotated. When they become rotated in opposite directions, one in front of the humerus and the other behind, it is known as a divergent dislocation.

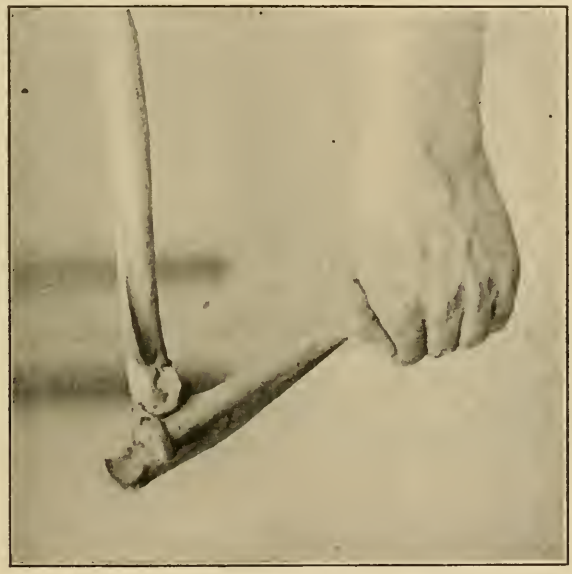

FIG. 210.—Backward dislocation of elbow.

The ulna is displaced only in a posterior direction. The radius may be dislocated in three directions; backward, forward or outward. To these may be added incomplete luxations in any one of the above-mentioned forms.

In our examination of the elbow-joint, we must take note of several landmarks, the chief being the two epicondyles and the tip of the olecranon. While the arm is flexed at a right angle, in normal cases, these bony points form a tripod with the tip of the olecranon below the level of the epicondyles.

1. Dislocation of both bones of the forearm in a posterior direction

is the most frequent lesion: it is more frequent than all the others put together (Figs. 210 and 211).

Signs.—A posterior dislocation is easily recognized in spite of the great swelling that sometimes takes place. The forearm is flexed on the arm at an angle of 135 degrees. The arm is shortened. The lower end of the humerus rests on the lesser sigmoid fossa of the ulna, thus shortening the forearm. Posteriorly the point of the olecranon is pushed upward above the olecranon fossa.

The triceps muscle appears relaxed and forms a depression above the olecranon. The axis of the arm and forearm do not cross in the

FIG. 211.—Backward dislocation of elbow.

joint, but somewhat deeper on the forearm. The joint appears enlarged in an antero-posterior direction but is unchanged in its transverse diameter. In old dislocations, the landmarks become more prominent on account of atrophy of the soft parts; the radial head and olecranon can be plainly seen.

Recent cases show the change in the landmarks so plainly that they can be seen at a glance. But a day or two later, the swelling becomes so great that careful palpation is necessary. These landmarks apply to the ulna only; to ascertain if the radius is also displaced, it is necessary to find the empty trochlea and the capitellum in front, and the presence of the radial head beside the olecranon behind; the latter can be felt when the forearm is pronated and supinated.

On inspection the shortening is at once evident; the forearm can

be brought only to a right angle; palpation on the posterior side of the elbow discloses the prominent olecranon and the radial head.

The dislocation is usually caused by falling on the hand while the arm and forearm are extended. Sometimes the arm is at a right angle when the fall occurs. It is generally conceded that a dislocation backward is caused by falling upon the outstretched palm while the elbow is in complete extension and that certain ligaments rupture. The internal lateral ligament tears at its upper insertion, the rupture involving the anterior ligaments and the brachialis anticus. As a result the elbow bends inward and the articular surface of the humerus passes in front of the coracoid process and the radial head.

When inspecting the joint, with its ligamentous structures, one becomes impressed that in dislocations, the primary lesion must be a rupture of one or both lateral ligaments as they prevent not only lateral motion but over-extension. The form of displacement must depend on the direction of the force, on which ligament is torn first and on whether the arm is abducted or adducted. The internal epicondyle is often broken off, detaching the flexors of the hand. When the internal lateral ligament is torn off, the ulna is liberated and permitted to pass in a backward direction. At the same time the external lateral ligament is ruptured and the radial head lacerates the corresponding portion of the capsule. Sometimes the coronoid process is broken off.

Aside from the tearing off of the flexor muscles, the brachialis anticus is lacerated and the biceps tendon sometimes is displaced to the outer side of the external condyle. The periosteum is sometimes stripped off but remains adherent to the capsule of the joint where the external condyle is broken by the radial head. The deviation of the forearm depends on whether the radius or the ulna is the more displaced.

There may be a fracture of the olecranon, the coronoid, the epicondyle or the head of the radius.

Treatment.—As a rule it is not difficult to reduce a backward dislocation of both radius and ulna. (1) In recent cases a reduction can sometimes be effected by grasping the hand of the patient and making downward traction while the arm is flexed at an obtuse angle. If such a manœuvre is attempted, it should be done quickly, otherwise there may be a contraction of the triceps which will defeat the attempt. (2) Should this method fail, an anæsthetic will be necessary. The arm is placed over the operator's knee while his foot rests on a chair in such a way that the knee is in the bend of the elbow; the forearm is grasped by one hand of the surgeon, and forward traction is exerted;

pressure forward on the tip of the olecranon and on the radial head completes the reduction. (3) The operator may stand in front of the patient, his foot resting on a stool; the elbow is placed with its flexor surface against the knee; a pull forward on the forearm usually now effects reduction (Fig. 212) (Sir Astley Cooper). (4) The patient may be in a horizontal position; an assistant grasps the hand and forearm and makes moderate extension. The operator grasps the elbow, especially the lower

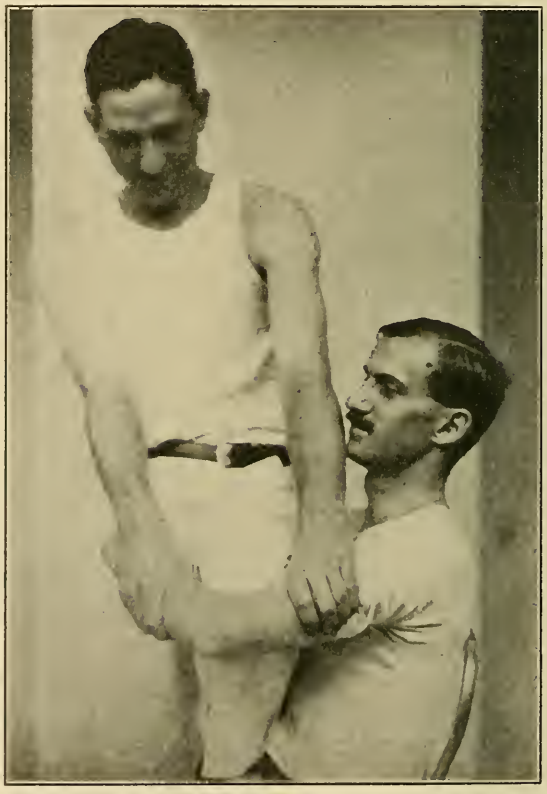

FIG. 212.—Sir Astley Cooper's method of reducing a posterior dislocation of the elbow.

humeral end with both hands, presses very firmly on the olecranon with both thumbs; the assistant, while making traction, pronates and supinates the arm. (5) Roser's method. This must be used with great care. The principle of the method is that the reduction should be made in the same position that the arm occupied when the dislocation took place. Roser placed the arm in strong hyperextension and then bent the forearm. The hyperextension lifts the coronoid process out of the olecranon fossa where it is sometimes firmly imbedded, making re-

duction impossible. The lifting of the process out of the fossa makes replacement easy during downward traction and flexion combined with pressure backward on the trochlear surface. The ulna resumes its normal position and the radial head follows. There is little danger of injury to the median nerve or the brachial artery by the over-extension. (6) Dumreicher's method consists of flexing the arm to a right angle. In this position the tip of the coronoid is only very slightly higher than the lower trochlear surface. If now a downward pull is exerted on the upper end of the forearm, the coronoid will be depressed so that it easily glides forward over the trochlear surface and a quick

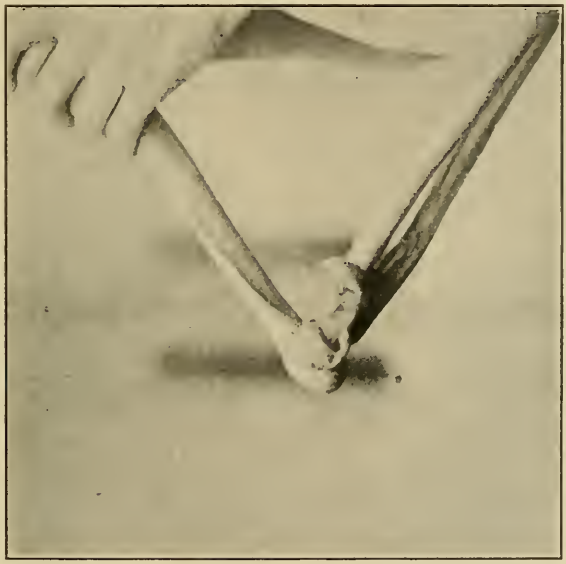

FIG. 213.—Forward dislocation of elbow.

extension of the forearm will replace the ulna, the radius following the ulna. The manipulation is best carried out as follows: The injured one lies on a table. A towel is passed through the axilla so that traction can be made upward by an assistant. The operator places another towel over the elbow which is bent at right angles. With one hand grasping the towel he pulls downward; with his other hand he grasps the wrist and fixes the forearm. As soon as the coronoid moves downward the arm is extended. If reduction is successful, the arm can be flexed to an acute angle.

After-treatment.—The arm should be held at an acute angle, in a felt or metal splint or in a plaster-of-Paris mould which should be cut

down the sides so that it can be removed for inspection or passive motion.

Forward displacement is exceedingly rare (Fig. 213 and 214). It may occur in childhood before the olecranon is fully developed. In adults it seems impossible without coincident fracture of the olecranon. The strong lateral ligaments must be torn before the posterior capsule can rupture. The mechanism of the dislocation is as follows: the subject falls on the olecranon while the elbow is acutely flexed; the

Fig. 214.—Elbow of child with excessive mobility. Forward dislocation of both bones of the forearm.

coronoid process strikes the humerus and acting as a fulcrum, permits the olecranon to be raised from the trochlea and pass forward.

Physical Signs.—The outlines of the lower end of the humerus can be seen and felt on the posterior aspect of the joint; the olecranon is absent. Anteriorly, the contour of the olecranon can be felt on the ulnar, and the radial head on the radial side.

Reduction is effected by increasing the flexion to an extreme degree so as to liberate the olecranon, one hand of the operator being

placed at the angle of flexion to act as a fulcrum. As soon as the olecranon is freed from the humerus, the forearm is extended and the ulna is pushed backward. The reduction is not difficult. Correct position is easily maintained unless the olecranon is broken, then reluxation occurs and a wiring of the broken bone may be necessary.

Incomplete luxation takes place when the progress of the olecranon is arrested on the trochlear surface. The arm is then extended and increased in length. The reduction is easily effected by extension and flexion of the forearm.

III. **Incomplete lateral dislocations** occur both in an outward and inward direction. They are exceedingly rare. A few cases are recorded.

IV. **Complete inward displacement** without fracture is more rare than outward dislocation. As the trochlear surface is deeper than the capitellum and as the articular surface of the humerus includes the external epicondyle, it is easier for the bones to be forced outward. The arm is usually held in a partially flexed and pronated position. Reduction is effected by gradual extension and supination of the forearm together with lateral pressure at the elbow.

V. **Complete Outward Dislocation.**—Rare. Usually the mechanism of the dislocation is uncertain. In most cases the arm is rotated outward, the radial head rests on the upper margin of the trochlea and the fossa sigmoidea embraces the external epicondyle. The external epicondyle is sometimes broken off. The joint appears broadened. The sharp point of the internal condyle is very prominent. Palpation discloses the new position of the olecranon on the outer side of the joint. Reduction is effected by means of extension of the forearm and lateral pressure. Supination and lateral movements of the forearm are helpful.

VI. Divergent also Known as Antero-posterior Dislocation.—In this form, the radius is dislocated in one direction and the ulna in another, the ulna backward and the radius forward, or the ulna inward and the radius outward. The latter is so rare that it may only be mentioned here.

An antero-posterior dislocation is usually caused by falling with great violence, striking on the hand while the arm is forcibly pronated. The internal lateral ligament is ruptured. The coronoid process may be broken off, the capsule is usually completely torn and the annular, interosseous, both lateral ligaments and the biceps and the brachialis anticus are lacerated.

Physical Signs.—Most frequently the elbow is slightly flexed, in some instances it is nearly straight; the arm is usually halfway between pronation and supination. Flexion and rotation are impossible; passive movements are restricted. Palpation usually discloses the ulna behind, the radius in front and both displaced in an upward direction.

Treatment.—Reduction may be difficult, especially if some days have elapsed since the accident. There are a number of recorded instances where a replacement could not be made. Usually traction in the axis of the forearm will reduce the ulna. Outward lateral flexion

Fig. 215.—Dislocation of upper end of radius.

will avoid the external lateral ligament. The radius can then be pushed back into its place unless the torn annular ligament is interposed.

VII. **Dislocation of the Radial Head Forward.**—This form of luxation is quite frequent (Fig. 215). While lifting or throwing, contraction of the biceps may pull the head of the radius out of its joint. A force that may fracture the upper end of the ulna, if continued, may dislocate the radial head. If a force is applied to the ulna from behind so that the internal condyle is broken off, the radius may be displaced. The dislocated radial head resting on the anterior surface of the

humerus prevents flexion of the forearm beyond a right angle. The space beneath the epicondyle, where the radial head usually rests, is empty. On inspection of the radial sides of the joint and the forearm, the latter appears shortened and is in radial flexion; the forearm is moderately pronated. On the flexor side of the joint, we find the head of the radius to the inner side of the epicondyle.

Treatment.—Reduction is effected by simultaneous supination and extension of the arm, assisted by pressure on the radial head. The reduction in most cases is easily accomplished but the retention of the radial head in the lesser sigmoid cavity may involve many difficulties; these may be due to the capsular tear being so small that the radial head is pulled back through it with difficulty. The capsular rent may sometimes be enlarged by hyperextension. Contraction of the biceps may favor a recurrence of the displacement. Flexion of the arm may relax the biceps or hyperextension of the arm may so over-stretch it as to relax it. The arm is put in such a position as will effectually retain the radial head in position. A right-angle position is usually effective. There is danger of fibrous ankylosis; therefore passive motion must be begun early. The splint should be opened no later than the eighth day, in order to ascertain if the bone is still in place. Passive motion should be commenced not later than two weeks after reduction and should be carried out with the greatest care.

In difficult cases, in which there are associated fractures, a dressing in an extended position may have many advantages, especially where there has been a fracture of the external condyle.

When displacement speedily recurs after reduction, an open operation may be necessary. Cases are seen where the dislocation has persisted through life. In proposing operative measures, one should not promise too much because, while some operative efforts have been rewarded with success, there have been many more partial successes and many failures. G. G. Davis has operated as follows: "An incision 2 in. in length was made on the outer side of the elbow, its center being over the lower end of the external condyle. The capitellum was then exposed by separating the fibrous tissues and the remains of the external and lateral and orbicular ligaments. The head of the radius was then forced back into place until the normal concave upper surface articulated naturally with the capitellum. It remained in place when the elbow was bent at an obtuse angle, but when flexion was increased, the head of the radius immediately jumped forward and resumed its original position on the outer edge of the trochlea.

"The head was again reduced and held in place by chromic catgut; the sutures were passed around the neck and into the tissues posteriorly; and by suturing, with the same material, the remains of the external lateral and orbicular ligaments were adapted as well as possible over the head of the bone. The radius was kept fairly well in position and the arm placed in an anterior obtuse angular splint, being flexed at the elbow at an angle of about 130 degrees"—"The result was only partially successful" (Journal, Am. Orthop. Surgery, Feb., 1911).

VIII. **Dislocation of the Radius Head Backward.**—This displacement may be caused by forced supination and extension of the forearm (Streubel). Other authors insist that the determining factor must be a moderate pronation of the forearm while the arm is extended. When seen shortly after the accident, the arm can be flexed only to a moderate degree; pronation and supination are impossible. On the posterior side of the joint, the radial head can be felt very plainly and its contour can be palpated. In front we find, under the lateral condyle, a depression over which the biceps tendon can be felt. The arm, on the radial side, appears shortened. This dislocation is often associated with fracture or dislocation of the ulna or a fracture of one or both condyles.

Treatment.—Reduction can be effected by extension, supination and direct pressure on the radial head. Sometimes when this manœuvre fails, hyperextension, supination and adduction succeed. The bones will usually retain a corrected position when immobilized at a right angle.

IX. **Dislocation of the Head of the Radius in an Outward Direction.**—This dislocation is very rare. Usually the displacement is not directly outward and is associated with a fracture of the ulna. The causative force usually comes from inward, directly upon the radial head forcing it outward. The arm is usually moderately flexed in an outward direction and pronated if the ulna is not fractured; if the latter fracture occurs, the arm is shortened. Reposition may be difficult. Hyperextension, supination and ulnar flexion with pressure on the radial head usually succeed.

X. **Incomplete dislocations of the elbow-joint** occur more often than was formerly believed. Since the more common use of the Röntgen rays, many partially dislocated elbows have been found. When we take into account the anatomical arrangement of the elbow-joint, we cannot expect to find a lengthening or shortening of the arm in partial dislocations, because the bones have been pushed to one side

or the other only to a moderate degree. The antero-posterior diameter remains unchanged; the transverse diameter may be increased; the radial head may be laterally prominent; if so the increase in the breadth of the joint comprises the width of the trochlea. In recent dislocations in young persons the internal epicondyle can be plainly felt, providing it is not broken off. No operative measures should be undertaken until the nature of dislocation is made clear by a skiagram.

Treatment.—On account of the rarity of this accident, no especial method to effect reduction has been generally adopted. In a general way, it would seem that hyperextension and supination of the forearm might be effective. If this is not effectual, a strong radial flexion following the above movements, would be of great assistance. An interposed separated epicondyle might effectually prevent reduction. Extirpation of the bone fragment might be necessary.

Old Irreducible Dislocations of the Elbow-joint.—The head of a displaced radius may be thrust through an overlying muscle and so firmly gripped as to be irreplaceable without excision of the head of the bone. An interposed tendon or muscle may prevent the head of the radius from being returned to its proper place without division of the restraining bands. A fracture of the head, neck, or process of the bone may, by its displacement, render reduction difficult or impossible without resection. Adhesions, contraction of the aperture in the torn capsule; contraction, adhesion and atrophy of the surrounding muscles and soft parts secondary to the trauma and exerting pressure upon important nerve trunks; adhesions of important blood-vessels to the torn capsule of the injured joint—all tend to make reduction by manipulation not only difficult or impossible but extremely dangerous. Inasmuch as the exact conditions existing in any given case of old irreducible luxation of an important joint can only be ascertained by direct inspection through an open incision, such an operation should be resorted to after a reasonable amount of manipulation has failed.

The author has operated on a number of old dislocations of the elbow and has found that the conditions opposing reduction were different in nearly every case and were as follows: (*a*) a broken off epicondyle; (*b*) a separated coronoid process; (*c*) interposed tendon and muscle; (*d*) fracture of the radial head in one case; (*e*) many adhesions of the soft parts existed; (*f*) contraction of the torn capsule; (*g*) contraction, adhesions and atrophy of the surrounding soft parts; (*h*) pressure on nerve trunks and the brachial vessels. It is evident that it is impossible to know the exact complications in any given case, without an open

operation. The parts must be inspected and corrected through an open wound, a skiagram giving no information regarding the condition of the soft parts. The author has employed a long incision on the radial side of the joint, supplemented by another incision on the inner side. The arm was made bloodless by an Esmarch constrictor. The restraining structures were removed or corrected according to the rules laid down by Stimson in his work on Fractures and Dislocations (pp. 692–693, Edition, 1910).

Complications.—The most serious and dangerous complication is where the bones are thrust through the skin (compound dislocations). Modern aseptic and antiseptic surgery has taught us that this complication is largely shorn of its dangers. Next to thorough disinfection of the wound, drainage is important. If the fractured surfaces are crushed or so soiled as to be beyond thorough aseptization, it may be best to resect the injured bones. The median and ulnar nerves are seldom injured. Other complications that may be serious are fractures. The epicondyle is sometimes torn off in outward dislocations. The ulna may be fractured and the radial head dislocated outward. There may be fracture of the olecranon plus anterior dislocation. The head of the radius may be broken off. Separation of the coronoid process is not infrequent and often delays convalescence. When possible, a skiagram should be made in all elbow-joint injuries. The joint is compound being both a hinge and a pivot. Complications are easily overlooked. Periarticular swelling occurs early so that the usual landmarks are obliterated. In all doubtful cases, the surgeon should call a consultant to share the responsibility. A stiff elbow may follow the most careful and exacting treatment.

DISLOCATIONS OF THE WRIST-JOINT

A dislocation of the wrist joint is exceedingly rare, but occasionally occurs. It is very often associated with fracture of the styloid process of the ulna and fracture of a portion of the radial articulation.

The firm dorsal and palmar ligaments and capsule of the wrist-joint account for the rarity of dislocations.

I. **Dorsal dislocation** is the most frequent of all wrist-joint displacements. Severe direct blows on the dorsum of the hand may initiate palmar displacement and if, at the same time, there is a palmar flexion of the hand, the outcome may be a dorsal dislocation of the carpus on the radius and ulna (Fig. 216). The important landmark is the

styloid process, its relation to the carpus indicates the position of the latter. The proximal surface of the carpus lies on the lower end of the radius and ulna and lifts up the extensor tendons which are visible and can be plainly palpated.

Often the lower articular surface of the radius and the styloid process if not broken off, are easily palpable. Under a severe trauma, the styloid process may be forced between the flexors and the adductor longus pollicis and through the fascia and skin, producing a compound dislocation. The prominence of the dorsum is much greater than in fractures of the radius and comprises the full width of the dorsum; the axis of the hand is not changed in its relation to the forearm; the fingers

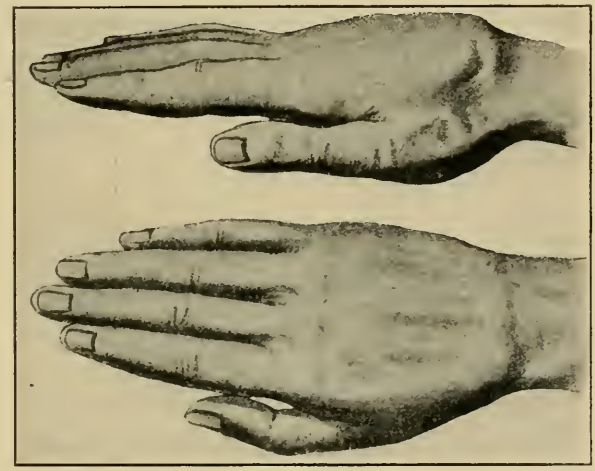

FIG. 216.—Dorsal dislocation of the carpus. (*Leipziges Universaitäts-Poliklinik, Friedrich.*)

are in a position of partial flexion. The forearm, when measured to the end of the middle finger, shows shortening.

Treatment.—Traction, flexion and pressure downward on the displaced carpal articulation by the operator's thumbs, will usually effect replacement. The hand should be placed on a splint in a position of dorsal flexion. This position approximates the lacerated ligaments and joint capsule. A pad should be placed on the back of the replaced carpus, to exert moderate pressure and insure its retention. It must not be forgotten that the danger of redislocation is very great. The prognosis as to function should be guarded. The extensive lacerations of the periarticular soft structures do not always undergo perfect repair. Weakness and joint tenderness may remain.

Habitual dislocations are so rare that very few surgeons have seen one. When redislocation has been observed, it has usually appeared in the first week or 10 days.

Fig. 217.—Palmar dislocation of wrist.

Fig. 218.—Palmar dislocation of wrist.

II. **Palmar Dislocations.** (Figs. 217 and 218.)—When we take into consideration the rarity of any form of wrist-joint dislocation, we at

once recognize the fact that few of us can hope to see a case (P. L. Friedrich reports a case, Handbuch der Praktischen Chirurgie, Bd. IV, 1901). A young physician could, by his own efforts, produce a downward dislocation of the carpus. He could maintain the subluxation, but after some minutes, he experienced more or less discomfort.

III. **Isolated Dislocation of the Ulna and Radius.**—Isolated dislocation of the radius or ulna backward or forward is uncommon, that

FIG. 219.—Isolated dislocation of the ulna.

of the radius particularly so. We have all observed a limited displacement of the ulna. The writer has seen one case of inward displacement of the ulna (Fig. 219) and a number of cases where there was a laceration of the articular ligaments admitting of considerable forward and backward movements. He has never observed a case of radius dislocation at the wrist unassociated with fracture.

IV. **Dislocation of Individual Carpal Bones.**—In consulting the textbooks in surgery, one would be led to believe that dislocations of carpal bones individually or severally are of rather infrequent occurrence.

Many authors dismiss the subject with only a brief reference; some of the books contain no reference to it. The American Text-book states that all of the carpal bones may be dislocated, but gives no detailed description.

Park's Surgery by American Authors, Vol. I, p. 765, refers briefly to the os magnum as the one bone that is most frequently displaced.

The International Text-book of Surgery, Vol. I, p. 623, speaks of the scaphoid and semilunar being occasionally displaced.

Similar short references may be found in Helferich on "Fractures and Dislocations," 1894, Hamilton, "Practical Treatise on Fractures and Dislocations," 1891, and many other authors who were consulted by the writer. The most detailed information on the subject may be found in the works of Stimson ("Treatise on Dislocations," 1907, p. 694), Cotton (Dislocations and Joint Fractures, p. 365, 1910), and von Bergmann (Handbuch der Practischen Chirurgie, IV Bd., p. 381, 1901).

Dislocations of individual carpal bones are far more frequent than is usually supposed. Many partial and often complete carpal dislocations are not recognized on account of swelling of the overlying soft parts. After a hasty examination, the case is usually dismissed with a diagnosis of sprain or contusion of the wrist. Not until pain, local tenderness and an inability to use the hand persist, is the real condition suspected when a skiagram reveals the nature of the lesion. It has become the author's practice to obtain a skiagram when possible in all injuries of the wrist-joint, for the reason that the clinical landmarks are all uncertain, for not only the swelling resulting from the contusion but the overlying tendons obscure the real nature of the injury. In most instances only a probable diagnosis can be made by palpation. The importance of an early recognition of displaced carpal bones is shown by the resulting limitations of function. It has been shown that reposition becomes increasingly difficult, and in many cases it is impossible, as the case becomes older.

It must not be forgotten that even with the aid of a skiagram the diagnosis may be difficult on account of the various anomalies which sometimes exist in the carpal bones and the inconstant sesamoids which may be present under normal conditions.

Scaphoid.—While the reported cases of dislocation of the unfractured scaphoid are not numerous, it often occurs when not suspected. When we consider that the majority of wrist injuries are not X-rayed, it will not be surprising that this is so. In most cases, the dislocation

is backward. The dislocation may be partial or complete. The displaced bone can sometimes be palpated on the dorsum of the wrist. It is believed to be produced by forced palmar flexion. Cameron, quoted by Stimson, reports a case of forward dislocation of the scaphoid. It may be possible, though not always, to replace the bone (if it is dislocated backward) by direct pressure, forcible flexion and hyperextension. If reduction by manipulation is impossible, it may be advisable to remove the bone.

Semilunar.—Next in the order of frequency to the scaphoid, the semilunar bone is dislocated. The bone is usually rotated on its trans-

FIG. 220.—Downward dislocation of the scaphoid and semilunar bones.

verse axis and pushed forward on the palmar surface of the wrist (Fig. 220). The bone, in recent cases, can usually be felt under the flexor tendons, sometimes resting on the lower end of the radius and a gap may be felt on the dorsum between the radius and os magnum. The luxation is caused by extreme dorsal flexion of the wrist. Fracture of the scaphoid may sometimes occur at the same time. If fracture of the scaphoid exists crepitus may or may not be felt. As reduction is often difficult and uncertain and as when it is accomplished the dislocation often recurs, removal of the bone is the better treatment. It gives as good and often better results than reduction.

Unciform.—Stimson reports two cases of dislocation of the unciform,

one by Buchanan, reduced by direct pressure, the other by Eigenbrodt in which the bone was excised.

Pisiform.—Fergusson and Gros, quoted by P. L. Friedrich, each described a case of dislocation of the pisiform. In both instances it was caused by a sudden forcible contraction of the flexor carpi ulnaris.

Os Magnum.—Dislocation of the os magnum may be produced by falling, striking the dorsal surface on the ground in such a way as to produce extreme palmar flexion, forcing the fingers to touch the palmar surface of the forearm. It may also be caused by falling upon the closed fist. If a dislocation has occurred, we find a hard, marble-sized mass on the dorsum of the hand at the base of the third metacarpal bone. The hand may be slightly bent. Any attempt to extend it may cause pain. Reduction may be effected by flexion and pressure on the os magnum and it may be retained in position by maintaining hyperextension.

Trapezoid.—Dislocation of the trapezoid is extremely rare, but when it occurs, the bone can be felt at the base of the metacarpal bone of the index finger. The dislocation may be produced by striking a firm object with the clenched fist. An attempt may be made to reduce it by direct pressure.

Trapezium.—Dislocation of the trapezium can be brought about by falling on the supinated hand in such a way as to strike the terminal phalangeal joint of the thumb and cause forced flexion at the metacarpo-trapezoid joint. There is usually increased mobility, the bone can be felt moving to and fro, while the thumb is flexed and extended. A distinct swelling corresponding to the bone may be felt at the base of the first metacarpal bone. Reduction can be effected by pressure. The metacarpo-trapezoid joint must be immobilized, and a lead plate should be moulded so as to fit over the carpometacarpal articulations.

Dislocation of Carpometacarpal Joints.—First Metacarpal (Fig. 221). Dislocations of the metacarpal bone of the thumb are relatively common and are usually in a backward direction, although forward dislocations have been recorded. Backward dislocations are rarely complete. The dislocation is usually produced by forced flexion of the thumb into the palm of the hand or by a blow received on the thenar eminence. The bone is displaced backward and slightly inward and is flexed in complete cases. When the displacement is incomplete, the posterior edge of the base of the metacarpal can be felt and observed in the space between the tendons of the extensor primi and secundi internodii and, in fresh cases, the bone can be reduced by pressure. Flexion increases the displacement. Movements are painful and limited. When the displacement

is complete, the bone is prominent and it can be distinctly felt in the base of the thumb as it rests on the trapezium. The thumb is shortened and flexed at the carpometacarpal joint.

Treatment.—Direct pressure over the end of the dislocated bone, while extension is being made, usually effects reduction. The thumb

FIG. 221.—Dislocation of first metacarpo-phalangeal joint.

should be secured in a position of abduction by means of plaster of Paris and should be held thus for a period of three or four weeks.

The second metacarpus alone has been reported dislocated at its carpal end, but this is extremely rare.

The third and fourth metacarpal bones, individually, have been regarded as having been misplaced, but the occurrence is so rare that very few surgeons have seen examples. The four inner metacarpal bones have been displaced backward (Fig. 222). Reduction was affected by extension of the fingers, and thumb pressure exerted directly on the displaced bones. The displacement was caused by a fall on the closed hand, causing hyperflexion. Stimson reports a number of

cases in his work. Dislocations of all five metacarpals are extremely rare. Stimson reports the cases of Poulet and Erichson.

Dislocation of the Phalanges.—*Thumb.*—The metacarpal end of the thumb is more frequently dislocated than are any of the phalanges (Fig. 223). Farabeuf in 1875 read a most elaborate paper on dislocations of the thumb before the *Societe de Chirurgie* of Paris. He gave a minute anatomical description of the joint, the cause of the various dislocations and the difficulty encountered in their reduction. His views have been generally accepted.

Backward dislocations are the most frequent. This form is brought about by extreme dorsal flexion of the first phalanx. The anterior

FIG. 222.—Complete backward dislocation of the base of the metacarpal bones.

ligament is torn at its attachment to the metacarpal bone. The dislocation may be incomplete, when the articular end of the phalanx lies on the posterior margin of the metacarpal bone, being held in this position by parts of the adductor and abductor muscles.

A complete dislocation takes place when the movement is carried to a point where the phalanx escapes from the articular surface of the metacarpal bone; it carries with it the sesamoid bones and the anterior ligament. The internal and external lateral ligaments are torn. The head of the bone tears the capsular ligament. The phalanx often stands almost at a right angle to the metacarpal bone and is held by the adductor and abductor. The head of the bone can be felt on the thenar eminence as a rounded, smooth body under the skin. There is much lateral movement and some rotation of the thumb and it may even be extended. In one of my cases, where reduction by manipulation was impossible and an arthrotomy became necessary, the torn anterior ligament was found stretched behind the head.

Reduction.—The chief manœuvre consists in grasping the thumb

with the hand and then producing extreme hyperextension combined with a rotary motion. While the thumb is overextended, the operator pushes the end of the bone into its normal position. The writer has succeeded in effecting a comparative easy reduction in this way. The thumb was fixed in an abducted position by a plaster-of-Paris mould for four weeks. There was little tendency toward redislocation before the application of the dressing and none afterward. In one case where

FIG. 223.—Dislocation of both the metatarso-phalangeal and terminal phalangeal joints of the thumb.

reduction by manipulation failed, an arthrotomy was done. The anterior ligament was divided, when reduction became easy.

Forward dislocation is much less frequent than the backward form and is not difficult to replace. It is produced by a blow or fall on the back of the flexed thumb. The internal lateral ligament and the posterior and lateral portions of the capsule are lacerated. The head of the phalanx rests on the anterior surface of the metacarpal bone and can be felt on the thenar side of the thumb. The thumb is slightly flexed and, in some cases, appears to be rotated on its axis.

Reduction is not difficult. The operator grasps the dislocated bone with one hand, the metacarpus with the other, and pushes the bone into place with the ends of his thumbs.

Old dislocations of the thumb usually require open operation.

Metacarpo-phalangeal Dislocations of the Fingers.—This form of dislocation is much less frequent than those of the thumb and is produced by dorsal flexion of the finger. It occurs in a *backward* direction. The anterior portion of the capsule is usually torn and is often interposed between the bones offering an obstacle to reduction. The index-

FIG. 224.—Complete dislocation of terminal phalanx of thumb.

finger is more often displaced than the others. The dislocation is easily made out by feeling the prominence of the base of the phalanx on the dorsum of the hand, the metacarpal head being found in the palm. The finger is shortened and there is limitation of motion. These findings apply to all the fingers. Occasionally a forward displacement occurs, when the physical signs described in backward dislocations are reversed, the base of the phalanx being in the palm while the metacarpal head is prominent on the dorsum of the hand.

Reduction.—In all cases it is advisable to make traction so as to increase the deformity and thereby unlock the displaced bones, and then to exert thumb pressure on the head of the luxated bones and

push them into place. After reduction, the hand should be immobilized with the metacarpo-phalangeal joints in hyperextension.

Dislocation of the Phalanges.—The most frequent form of dislocation is in a backward direction (Fig. 224). The most frequent cause is a fall on the palmar surface while the fingers are in hyperextension. The displacement is easily recognized by palpation. The proximal phalanx may remain overextended, or it may assume a position that is parallel to the others. The anterior part of the joint capsule is usually torn and may be interposed between the joint surfaces and form an obstacle to reduction. The phalanges may be displaced forward completely or incompletely. The signs are the opposite of those in backward displacements. Replacement is effected by extension and by pushing the bone into its normal position. Lateral displacements have been recorded and, while rare, they are usually compound. The diagnosis is easy. The same general principles are to be followed as in the reduction of other phalangeal displacements.

Displacement of the Distal Phalanges.—The most common form is in a backward direction and is caused by a fall on the extended finger. It may be complete or incomplete and is sometimes compound. The displacement is usually directly backward but sometimes the bone may assume a slight lateral position. As in other phalangeal displacements, the joint capsule is torn anteriorly and the anterior ligament ruptured. The flexor tendon may be separated from its attachment. If there is lateral displacement, the internal ligaments may be torn. Reduction is usually easy if there is no interposition of the capsule or other soft parts. There is often a wound on the palmar surface which may complicate the treatment and often leads to infection with its possible consequences, viz., ankylosis, gangrene and infection extending up the tendon sheaths. Reduction should be preceded and followed by thorough disinfection of the wound. A careful aseptic wound treatment is imperative. Occasionally the displaced bones may be so locked as to make replacement impossible. Under such circumstances the wound must be enlarged to permit of correction or removal of the obstacle.

In forward dislocations, the same rules for diagnosis and management must be followed as in other forms of phalangeal dislocations. In all cases of irreducible simple dislocations an open operation under the strictest aseptic precautions must be carried out. After reduction of the displacements, the fingers together with the hand and wrist must be immobilized in splints and the after-treatment carried out as described for other dislocations.

SECTION IV

DISEASES OF THE UPPER EXTREMITY

By

DEAN LEWIS, A.B., M.D., F.A.C.S.

Furuncles or Boils.—Because of the absence of hair follicles upon the palmar surface of the fingers and hand, boils occur only upon the dorsal surface. They are circumscribed abscesses involving the entire thickness of the skin, and frequently the inflammatory process extends to the subcutaneous tissues. Boils are especially common in people whose daily work brings them into contact with infectious material, being most commonly observed in harness makers, butchers, surgeons and pathologists.

Boils upon the dorsum of the hand do not differ clinically from those occurring upon other parts of the body, except in the rapidity and frequency with which the lymph nodes which drain the site of infection are affected. They are frequently accompanied by a marked œdema of the back of the hand, because the subcutaneous tissues are so loose.

Lowering of general resistance, such as occurs in diabetes, chronic nephritis, the anæmias and infectious fevers, favors the development of boils. Local irritation, which forces the bacteria lying upon the surface into the hair follicle, is often the determining factor in the development of the lesion.

The furuncle begins as a pimple which then develops into an indurated red swelling in the center of which a small pustule, situated at the root of a hair, develops. There is usually considerable tenderness and throbbing pain. The amount of general reaction depends upon the virulence of the organism and the resistance of the patient. A large percentage of the boils beginning with violent symptoms are caused by the streptococcus, while those accompanied by milder symptoms are due to the staphylococcus.

If let alone, a boil will usually discharge spontaneously at the end of a week, leaving a ragged opening from which the necrotic material forming the "core" is discharged or removed.

Prophylaxis is of importance in those who are frequently subject to boils. The surfaces affected should be kept clean and protected, and

conditions should be provided which will prevent the infection of adjacent hair follicles. The general resistance should be raised by proper diet, exercise and by providing good hygienic surroundings.

The different forms of abortive treatment which have been attempted from time to time have not been successful. In the early stages a hot boric acid dressing should be applied until the boil has fully developed or become "ripe." When pus has formed, the boil should be opened and the necrotic center removed. The character of the dressing to be used after the boil is opened depends upon the amount of reaction about the inflamed area. In incising a boil, an anæsthetic is often unnecessary as the incision causes but little pain when made quickly with a sharp knife. If an anæsthetic is necessary, nitrous oxide is to be preferred, as freezing is painful and infiltration anæsthesia may favor an extension of the inflammation.

Bier's passive hyperæmia, induced by means of a constricting bandage or a suction cup, has been used extensively during the past few years in the treatment of infections. Care must be exercised in producing the passive hyperæmia, for the pulse should not be weakened or made to disappear, but the part in which the hyperæmia is induced should remain warm and become somewhat œdematous. When the right degree of hyperæmia is induced the pain associated with the lesion subsides or disappears and this indicates whether or not the right degree of hyperæmia is being induced. When the cup is applied it should not be allowed to remain on too long and the vacuum induced should not be too great, for hemorrhages into the tissues may occur, thus reducing their resistance.

Bier's hyperæmia may be used to favor softening of the inflammatory lesion which can then be opened by a small incision. It can be used to advantage also after the inflammatory focus has been opened, for the extravasation of serum which occurs after the cup is applied after incision of the focus, is of decided advantage. It seems to be the consensus of opinion that passive hyperæmia is most useful in the treatment of localized inflammatory processes with little or no tendency to spread.

When boils recur frequently and the inflammatory process is not easily controlled, as in axillary folliculitis, vaccines are of decided value. Autogenous vaccines should be used, for stock and mixed vaccines are of little or no value. The dosage and the time at which the injection should be repeated may be determined either by the opsonic index of the individual or the clinical course of the inflammatory process.

Axillary Folliculitis (*Hydroadenitis of Verneuil*).—The skin of the axilla is abundantly supplied with hair follicles and sweat glands, and the moisture and apposition of the skin surfaces provide conditions which favor the development of infection. Furunculosis of the axillary skin is not uncommon, multiple furuncles developing, the infection being carried from a diseased follicle to a healthy adjacent one. Small hard nodules develop in the skin, the majority of which soften to form small boils. In many instances the infected area does not resolve and the axillary skin may then contain many small nodules which may remain indefinitely.

This type of furunculosis is often resistant to treatment, for infection is easily carried from one follicle to another and the moisture of the axilla, together with the friction between the opposed surfaces, favor the infection of follicles adjacent to the ones primarily diseased.

In treating axillary furunculosis, conditions should be provided which do not favor the carrying of infection from one follicle to another. The arm pit should be shaved and the infected follicles which are mature should be opened. The skin should be washed twice daily with hot water and castile soap. Alcohol should then be applied and after the skin is dried, sterile talcum powder should be dusted on. A little sterile cotton or gauze is then applied to take up the moisture. Moist dressings macerate the skin and favor the spread of the infection. They are, therefore, not indicated in treating this type of infection.

Erysipelas as it occurs upon the face and scalp is rarely observed in the upper extremity, especially upon the fingers and hands. In the latter situation erysipelas quite frequently occurs as an accompaniment or complication of some other type of infection, such as a paronychia or tenosynovitis. It may appear as an uncomplicated lymphangitis, or the inflammation may extend to the deeper subcutaneous tissues, which may become necrotic and present the clinical type known as phlegmonous erysipelas. (Pathologically, simple, gangrenous and phlegmonous erysipelas are the same process. They differ in degree only.)

Erysipelas is due to a streptococcus which enters the lymphatics through an accidental or operative wound or through a fissure or abrasion which is often so small as to escape detection. Lowering of the general resistance naturally favors the development and spread of the infection. The streptococcus described by Fehleisen is no longer regarded as the specific organism. Since Petruschky has shown that the streptococcus pyogenes may cause erysipelas, the organism described

by Fehleisen is regarded by most investigators as the streptococcus pyogenes. Recent bacteriological studies in inflammatory processes of the skin which resemble, clinically, erysipelas are interesting. Jordan has found staphylococci; Rheiner, typhoid bacilli and Perls-Neelsen, pneumococci in such cases. These findings would seem to indicate that erysipelas is not a specific disease, but that inflammatory processes, clinically very closely allied, may be caused by any one of a number of different organisms, if they gain access to the lymphatics of the skin and subcutaneous tissues.

It is difficult to determine the period of incubation of erysipelas in man. In animals, used in the study of experimental erysipelas, the incubation period varies from 15 to 60 hours.

Onset and Symptoms.—Erysipelas begins almost always with a chill, which may vary in intensity from a chilly sensation to a distinct rigor. The temperature then rises and is variable. It may be as low as 99° or 100°, or rise to 105° or higher. The severe general reaction may be accompanied by vomiting, aching of the back and extremities and the symptoms associated with severe general infections. Severe general symptoms at the beginning are especially common in children. The inflamed skin is red, hot, indurated and painful. Palpation reveals a firm, tense œdema of the skin, and when pressure is withdrawn the skin often presents for a short time a peculiar yellowish hue. The edge of the inflamed area has an irregular, zigzag, sharply defined border, which is quite characteristic of the inflammatory process. Pale areas of skin are found between the flame-like tongues and points which extend from the margins of the inflamed zone. The inflammatory process follows the parallel linear furrows and connective-tissue bundles of the corium mostly in the direction of the lymph stream, but also against it. While one inflamed area is clearing up, another may become affected at a distance, apparently healthy skin intervening. The mode of extension may thus be very irregular.

Gradually the process subsides, the length of the clinical course and the clinical symptoms varying in different cases. The symptoms may subside in two days or may extend over weeks, fresh areas of skin being affected from time to time. The tendency of erysipelas is to subside spontaneously in from 6 to 10 days. In the superficial forms, the skin desquamates and the hair falls out. In weak subjects and in severe cases, gangrene of the skin may develop while in the phlegmonous types abscesses may form.

Prognosis.—In the superficial non-suppurative forms of erysipelas

the prognosis is good, unless occurring in patients suffering with diabetes, syphilis or addicted to alcohol, whose general resistance has already been greatly lowered. Erysipelas in these cases may be the terminal infection. Occurring in the hand and forearm as a complication of another infection which threatens the function of the part involved, it adds to the gravity of the prognosis.

Diagnosis.—The diagnosis is usually readily made. The sharply delimited redness of the skin with irregular borders and the tense œdema, accompanied by fever preceded by a chill, are quite characteristic.

Treatment.—Any number of methods of treatment have been introduced. Most of these are useless, for they attempt to prevent the invasion of the lymphatics by the organism by mechanical or chemical means. Erysipelas is a self-limited disease and the main object in the treatment is to relieve the discomfort and maintain or increase the local and general resistance. A vaseline or hot boric acid dressing fulfills most of the indications for local treatment. The arm should be kept at rest and if the patient is suffering from diabetes or nephritis such disease should receive appropriate treatment.

It is not necessary to isolate these patients, for there is no more danger of their carrying infection than there is in other inflammatory processes. Due precautions should, however, be taken in the dressing and care of the patient to prevent infection being carried to other patients.

Erysipeloid.—Erysipeloid is an inflammatory process involving the skin which in some ways resembles erysipelas. It was formerly called chronic erysipelas and erythema migrans. Erysipeloid is seen most frequently upon the fingers, developing from small wounds. It does, however, occasionally develop upon the cheeks, nose and neck.

The disease occurs in cooks, butchers, tanners, fish mongers and in those engaged in opening oysters. The handling of decomposing material evidently bears some relation to the development of the infection. In almost all cases a small wound which is the infection atrium can be demonstrated.

Rosenbach in 1887 isolated a cladothrix-like organism from some cases of erysipeloid. This organism when injected into the skin causes an inflammatory reaction which resembles erysipeloid clinically.

The infection usually begins with a mild burning and itching of the skin unaccompanied by fever or any general reaction. The skin becomes swollen, painful and deep red in color. The inflammation gradu-

ally extends from the infection atrium toward the hand from the base of the finger to the neighboring one, the area first involved becoming pale. The process rarely extends as high as the middle of the hand. Some lymphangitis, which may be resistant to treatment, is observed in about 10 per cent. of the cases.

After lasting a week, the inflammation usually subsides. Cases do, however, occur in which the process continues three or four weeks. This occurs particularly when no active treatment has been instituted.

Erysipelas extends more rapidly than erysipeloid and is accompanied by general symptoms. There should not, therefore, be any difficulty in differentiating between the two. The redness associated with lymphangitis reticularis which also occurs upon the fingers has indistinct, never sharply defined, borders.

The treatment consists of immobilization of the fingers for a few days and the application of a vaseline dressing. The inflammation usually subsides rapidly under this treatment. It may recur if motion is begun too early.

Syphilis.—Primary syphilitic lesions occur about the nails and fingers as the result of infection through hang nails or fissures. Such lesions are not infrequently seen in doctors, the infection occurring after examinations in which fissures or denuded areas are exposed to syphilitic virus or after pricks with needles or scissors, sustained while operating upon syphilitic patients.

The initial lesion appears as a hard, painless, red, sharply delimited, round or oval nodule. It may be so small as to attract little or no attention, or it may become as large or larger than a quarter dollar or shilling. If secondary infection occurs a phagadenic ulcer may develop; while if the epidermis is cast off, an ulcer covered by a firmly adherent crust forms. If caustics are applied to the lesion, or ordinary cleanliness is observed in caring for it, an ulcer with a hard, parchment-like base and slightly raised, indurated borders, which are not undermined, may develop.

The lesions of the eruptive stage of syphilis are of but little interest to the surgeon, as they are most frequently seen and treated by the dermatologist. The late cutaneous manifestations of the disease are, however, of considerable interest, because of the diagnostic difficulties offered by them and because of their significance in the diagnosis of the obscure lesions.

The gumma is a granuloma which may occur as a single or multiple lesion in any tissue of the body. Cutaneous gummata are frequently

met with in the early stages of tertiary syphilis. In the severe, rapidly developing forms of syphilis, cutaneous gummata may appear during the first 18 months following the infection. Cutaneous gummata appear as somewhat elevated, firm, red nodules, often arranged in groups. The nodules in the center of a group may become absorbed or ulcerate, extension taking place from the periphery by the formation of new nodules. If the nodules fuse, a diffuse infiltration of the skin, which is somewhat elevated, red and has serpiginous borders, develops. A spreading form of syphilitic skin infiltration is not infrequently observed about joints (elbow, shoulder, etc.).

The lesions occurring in cutaneous syphilis may be quite similar to those observed in lupus. The lesions of syphilis are, however, more often multiple, occurring in many isolated patches, than are those of lupus, and the destruction of tissue in syphilitic lesions is much more rapid. A syphilitic lesion extends more rapidly peripherally than does a tuberculous; besides, the apple-jelly-like granulation tissue found in lupus is quite characteristic. The scars resulting from the healing of an ordinary lupus are apt to be thick and hyperæmic. They are also prone to ulcerate. The scars following the healing of syphilitic infections are white, parchment-like and supple, with but little or no tendency to break down.

Cutaneous Tuberculosis.—The skin of the dorsum of the fingers and hand is one of the favorite sites for tuberculous infections. The anatomical tubercle (verruca necrogenica) occurs in the interdigital folds or upon the knuckles of those who are exposed to tuberculous infections in handling diseased meats or performing autopsies. The tubercle is thus most frequently observed in butchers, pathologists and cooks. The lesion appears as a dark red, indurated nodule which is covered by a cornified fissured epidermis and a yellow or brown crust. When the crust is removed an ulcer is not necessarily found, for the nodule is usually covered by a fissured epidermis. Usually there is no ulceration and the lymphatics draining the site of the lesion are not enlarged unless a secondary infection has occurred. The anatomical tubercle is characterized by its chronicity and tendency to recur. Often, however, after persisting for months such a lesion disappears spontaneously and never recurs.

Lupus may appear in a number of different forms. It is of surgical interest only when ulceration leads to mutilation of the fingers or hand, or the resulting scar formation results in crippling contractures. The non-ulcerative types of lupus are usually seen and treated by dermatologists. Lupus usually begins as a nodule in the corium which is slightly raised above the level of the surface. As it enlarges, the nodule becomes more prominent and assumes a pale yellow, yellowish red or dark color. It is usually soft and tender. In the beginning the nodule is usually single. Multiple nodules are, however, of frequent occurrence. The lesion usually enlarges by marginal extension. If multiple nodules are present, these may fuse so that eventually the lesions may assume various shapes.

The ulcers which form when the nodules break down have an indolent floor, covered by apple-jelly-like granulations and more or less raised margins which may be thickened by desquamation or hypertrophy of the epidermis, or present a warty appearance, if the papil-

læ have undergone hypertrophy. Although the lupus ulcer ordinarily does not extend deeply and involve bones, joints and muscles, it may, when occurring upon the hand, lead to mutilation of the fingers (lupus mutilans) and the resulting scar may give rise to marked and disabling contractures.

Verrucous Tuberculosis.—The hands are the favorite site for the development of this form of tuberculosis. It follows injuries of the skin in which tubercle bacilli of either the human or bovine type are carried into the skin. Lexer cites an interesting case of this type of tuberculosis, observed in Von Bergmann's clinic, which followed an injury of the back of the hand with a milk pail. When fully developed the lesion of verrucous tuberculosis appears as a somewhat elevated, round or irregular flat infiltration of the skin, with a rough warty surface and bluish borders. It runs a chronic course without ulcerating, the diseased area becoming as large as a silver dollar or even in some cases involving the entire dorsum of the hand and extending onto the forearm (Fig. 225).

FIG. 225.—Verrucous tuberculosis of the skin of back of hand. (*De Quervain.*)

Clinical Course.—Lupus pursues a chronic course. It lasts for a number of years resisting treatment or yielding with difficulty to the same, recurrence taking place after longer or shorter intervals of improvement. Many patients with lupus eventually develop tuberculosis of the bones, joints or viscera. Lupus mutilans may destroy the fingers, or in healing may be followed by such contractures as to almost wholly destroy the function of the fingers.

Treatment.—Excision is the treatment of choice in lupus involving the dorsum of the hand. This should be followed by skin grafting, the Wolff or pedunculated graft being used in closing the defect, for epidermal grafts may interfere with the function of the tendons, or cause contractures. The incision should be carried ¼ in. outside of the lesion. When the lesion is small and so situated that the scar will not interfere with function, X-ray therapy and other less radical procedures may be attempted, but excision accomplishes at a single sitting what may require months for less radical procedures.

Blastomycosis.—Blastomycosis of the skin of the hand, forearm and arm may occur as a solitary lesion, or as a part of a general cutaneous involvement. Many of the cases of blastomycosis that have been observed have occurred in Chicago and Ormsby states that this city is apparently the center of infection, as a majority of the cases, both cutaneous and systemic, have been observed there.

The following description of the organism of blastomycosis is given by Ormsby: The size varies from 5 to 15μ, but many times organisms as large as 30μ are observed. Taken as a whole the organism is round or oval or somewhat irregular, surrounded by a homogeneous, doubly contained, refractile capsule, immediately within which is a clear zone, while the center contains granules of various sizes and shapes and sometimes a vacuole. These protoplasmic granules are at times basophilic, as they stain red with Unna's polychrome methylene blue.

While endogenous spore formation is not proven in these organisms, one may often see ruptured capsules and in the immediate neighborhood small granules similar to those within the capsule. The organism is well seen in fresh pus or tissue mounted in a 10 per cent. solution of potassium hydrate and may be easily stained with any of the common aniline dyes.

Blastomycetes present multiform cultural appearances depending upon the media used and the temperature at which they are grown. Ordinarily they grow well in glycerin and glucose-agar, blood-serum-agar, and in broth. A moist, pasty growth occurs on glycerin-agar at room temperature, with only moderate aërial hyphæ, while more aërial hyphæ form on glucose-agar and agar-agar at the same temperature. Cultures begin to develop in

Fig. 226.—Blastomycosis of skin on lateral aspect of elbow. (*Ormsby.*)

from 2 to 14 days, subcultures usually in from 2 to 5 days. Mycelial formation is more abundant during the first few weeks, but later budding forms occur.

Character of the Lesion.—The cutaneous lesion varies in size from a papulo-pustule to a large patch several inches in diameter (Fig. 226). Ormsby gives the following description of a patch the size of a silver quarter dollar. It is surrounded by a bluish-red areola in which small miliary abscesses, characteristic of the disease, are found. The areola gradually slopes from the elevated patch to the normal surrounding skin and is about 14 in. in width. The main part of the lesion is elevated about ⅛ in. and the top of the patch is more or less flat, papillomatous or verrucous, crust covered or discharging, or superficially ulcer-

ated. Pus may be squeezed from between the papillomatous projections as in verrucous tuberculosis. The miliary abscesses in the sloping border of the patch are characteristic and vary from minute, scarcely visible points to lesions the size of a pinhead, from which a muco-purulent material can be obtained and from this the organisms can be recovered in pure cultures. Where reparative processes have occurred, a superficial scar is found which is usually soft and smooth, but may be irregular and corded.

Clinical Course.—Cutaneous blastomycosis is usually chronic. Periods of activity alternate with periods of quiescence. The process of repair may be combined with that of inflammatory infiltration and invasion of unaffected areas. Montgomery states that a single patch may at one time present all the stages of the disorder, showing at the same time several of the following features: the advancing border, new lesions forming on old scars, verrucous or cauliflower-like lesions in various stages of development or disappearance, a base in places dry and firm and in others soft and infiltrated with muco-pus, a scar tissue in part thick and irregular and in part smooth, supple and non-attached to the deeper tissues.

Pathology.—The most marked pathological changes occur in the upper layers of the corium and the epidermis. The stratum Malpighii is hypertrophied and prolongations are sent down in different directions into the corium. Miliary abscesses of different sizes develop in this layer. These abscesses contain chiefly polymorphonuclear leukocytes, particles of epithelial cells, disintegrated nuclei and débris and the organisms which usually are found in pairs. The epithelial proliferation is often marked enough to suggest an epithelioma, but the cells do not pierce the basement membrane. Plasma and giant cells are found in the diseased tissues. The latter may contain the organism.

Diagnosis.—Cutaneous blastomycosis has been mistaken for verrucous tuberculosis, syphilis and carcinoma. In verrucous tuberculosis the dorsum of the hand alone is apt to be involved, while in blastomycosis if the hand is involved, other areas, such as the face in the neighborhood of the eyelid, are apt to be affected. The indurated pearly border of an epithelioma without miliary abscesses is usually characteristic enough to enable one to differentiate it from cutaneous blastomycosis.

Potassium iodide in large doses, combined with radiotherapy, will usually cure the disease. The entire lesion, if localized, may be excised. Abscesses require opening.

Sporotrichosis.—Hamburger in 1912 found in American literature reports of 28 cases of undoubted sporotrichosis as proven by positive cultures which appeared during the 13 years following Schenk's original publication. In addition he found 30 cases of highly probable sporotrichosis, that is, cases clinically identical with the 28 positive cases, but with no positive cultures.

These cases were distributed in the various states as follows: 22 in North Dakota, 13 in Kansas, 5 in Nebraska, 3 in Missouri, 2 in New York, 2 in Minnesota, 1 in California, 1 in Iowa, 1 in Indiana, 1 in New Jersey, 3 in South Dakota, 1 in Montana, 1 in Wisconsin. In the reports in which sex is mentioned, it is stated that 32 cases occurred in males and 21 in females. The youngest patient was 3 years of age, the oldest 70. Twenty-seven cases occurred in persons between 15 and 45.

Infection occurrred in farmers and farmers' children fifteen times; in florists twice, and once each in an iron worker, a berry picker, a packer in an express company, a housewife, a school teacher, a potato peeler, a woodman and a soldier. The infection occurred upon the back of the hand five times, upon the index-finger four times, upon the palm of the hand twice, upon the thumb twice and once each upon the wrist, arm, thigh, anterior surface of leg, knee and calf.

The following clinical features aid in making a diagnosis. The disease occurs in farmers, florists, berry pickers and fruithandlers, being most common between the fifteenth and forty-fifth years. It has a slow period of incubation, develops after an injury and is characterized by a slowly progressive involvement of the lymphatic vessels in the course of which there develop small hard, round, subcutaneous nodules, which later soften to

form indolent cold abscesses or ulcers (Fig. 227). Notwithstanding the long course of the disease there is little or no pain or fever, and the patient's health remains good.

The disease has a clinical course varying from 3 weeks to 18 months. There have been reported in this country no cases of systemic infection.

Beurmann gives the following classification of the clinical varieties of this infection:

1. Localized sporotrichosis with sporotrichotic chancre and ascending lymphangitis with local lymphadenitis.

2. Disseminated gummatous sporotrichosis; multiple subcutaneous nodules being distributed throughout the body without systematic arrangement. Early small, hard, painless round masses and later small and large soft, cold abscesses; no ulceration.

3. Disseminated ulcerative sporotrichosis, multiple polymorphic ulceration simulating tuberculous, syphilitic, ecthymatous, rupial or furuncular lesions or a combination of these.

FIG. 227.—Sporothricosis of skin on dorsum of hand. (*Ormsby.*)

4. Extracutaneous sporotrichosis with localization in mucous membranes, muscles, bones, joints, eye, synovial membranes, kidney (one case) and lungs (two cases).

Treatment.—Beurmann sums up the treatment as follows: Potassium iodide should be administered in increasing doses, as much as 6 gm. or even more being given in a day. The local lesions should be dressed with a weak iodio-iodid solution (water 500 gm., potassium iodid 10 gm., iodin 1 gm.). Tincture of iodin should be painted on the ulcerated areas. Prolongation of treatment for a month after complete apparent recovery is necessary to prevent relapses and recurrences.

Botryomycosis.—A few cases of this peculiar infection have been observed in man. The disease is frequently observed upon the bellies of horses and asses. Poncet and Darin 1897 reported four cases. In three of these the lesion occurred upon the fingers and in one upon the skin covering the shoulder. These lesions were identical in appearance with those which are at times observed upon the bellies of horses following castration.

The infection is characterized by the development of mushroom-like, bleeding granulomata in the skin, in which are found grape-like or mulberry-like groups of cocci, which

apparently cannot be differentiated from the staphylococcus aureus. These granulomata are confined to the skin. As they bleed easily they may be confused with angiomas which are frequently pedunculated and small.

The growths can easily be excised, for they are confined to the skin and do not invade the deeper tissues.

Osteomyelitis.—Osteomyelitis is an inflammatory process of bone due to invasion of the bone by pathogenic microörganisms. Infections of bone may occur in different ways. Osteomyelitis developing without direct infection must be regarded as of hematogenous origin, bacterial or infected emboli being carried in the blood from some primary inflammatory focus and deposited in the bone where they lodge owing to peculiarities in the arrangement of capillaries, or because a favorable soil for their growth has been provided by trauma, exposure to the cold, or some other factor which has reduced the resistance of the tissues.

The bones of the upper extremity are not involved as frequently as are those of the lower, as the statistics published by Trendel in 1904 from von Bruns' Clinic indicate. His report deals with 1279 osteomyelitic foci observed in 1058 patients. Eleven hundred and ten of the foci occurred in long hollow bones, while 169 occurred in short flat ones.

The long hollow bones were involved in the following order of frequency:

Femur.....	508 times.....	45.8 per cent.
Tibia.....	386 times.....	34.8 per cent.
Humerus.....	103 times.....	9.2 per cent.
Radius.....	43 times.....	3.9 per cent.
Fibula.....	36 times.....	3.2 per cent.
Ulna.....	35 times.....	3.2 per cent.

It will be seen from these statistics that the bones of the upper extremity are far less frequently involved in an osteomyelitic process, than are those of the lower, and that the disease is more common in the humerus than in the radius and ulna.

Etiology.—The essential factor in the development of osteomyelitis is the deposition and multiplication of bacteria in the bone. These must be virulent enough to overcome the bactericidal action of the tissue fluids, or the resistance of the tissues in which they are deposited must be so reduced by trauma, exposure to cold, etc., that their growth is favored. In most cases of osteomyelitis some etiological factor which tends to reduce the general or local resistance can be elicited if a careful history is taken.

The anatomical arrangement of the blood-vessels in the metaphysis of the long bones, where osteomyelitic foci are most common, favors the

lodgement of bacteria. The mechanical conditions found in the epiphyseal zone of growing bones favor the deposition and retention of bacteria, for there is in this zone a physiological hyperæmia with slowing of the blood stream and peculiar arrangement of the smaller blood-vessels and capillary loops which pass down into the primary medullary spaces of the epiphyseal cartilage.

The staphylococcus pyogenes aureus is the organism which is most frequently found in cases of suppurative osteomyelitis. This is due to the frequent occurrence of suppurative lesions in which the staphylococcus aureus is the exciting organism. It is the organism which is common in furunculosis and it is not at all unusual to find, in taking a clinical history of a case of acute osteomyelitis, that the process in the bone has been preceded a few days by a furuncle, from which the organisms were carried into the blood to be deposited in the bone.

The growth of the staphylococcus in groups favors retention in the metaphyseal blood-vessels, where conditions are provided which favor the occlusion of vessels by such groups of organisms. This tendency to grow in clusters or groups may explain to some extent, also, why the staphylococcus is the organism most commonly found. The streptococcus has been found in a few cases, and in some cases the pneumococcus has been isolated. The clinical course and the pathological findings in those cases in which these organisms have been found have not been distinctive enough to enable one to differentiate the osteomyelitis due to them from that due to the staphylococcus. They have, however, some interesting clinical features which will be considered later. The typhoid bacillus is not infrequently found in suppurative processes in bone, the ribs and sternum being the favorite sites for the lesions caused by this organism. The bones of the upper extremity are but rarely involved in this type of infection.

The organisms above mentioned are the ones most commonly found in osteomyelitis, but cases are occasionally reported in which the bacillus of Friedländer, the colon bacillus and even the gonococcus have been found. Osteomyelitis is not, therefore, to be regarded as a specific disease, as it may be caused by any one of a number of different organisms provided they are able to overcome the bactericidal properties of the tissue fluids. When the disease has developed there are no specific clinical features which enable one to determine the nature of the infecting organism.

Osteomyelitis is a disease of the young, being most common in children and young adults, in whom the growth of the bones is most

active. The disease is, however, not infrequently met with in adults and may occur in the aged. About one-half of the cases are said to occur between the thirteenth and seventeenth years. The disease is about three times more common in the male than female sex, the former being more frequently subject to lesions from which organisms gain access to the blood, and to trauma and exposure to cold which may reduce the local resistance of the tissues.

Trauma undoubtedly plays an important rôle in reducing the local resistance of the tissues. This has been proven by clinical observations and experimental work. Ullmann has shown that suppurative processes will develop at the seat of fractures or contusions when cultures of virulent organisms have been injected intravenously at the time the trauma was produced or somewhat later. Exposure to cold seems to have a definite effect in lowering resistance, for frequently in eliciting a history in a case of osteomyelitis, a direct relationship between exposure to cold and the onset of the disease can be elicited.

Osteomyelitis occurring during or subsequent to infectious diseases may be due to the specific organism of the disease, or to a secondary infection. When a secondary bone infection occurs in these cases, it is generally due to the lowering of resistance caused by the primary infection. Most cases of osteomyelitis occurring during typhoid are due to the typhoid organism, but there are other cases in which the osteomyelitis is caused by a staphylococcus or streptococcus which has gained access to the circulation through the intestinal ulcers.

Pathology.—Acute suppurative osteomyelitis in nearly all instances begins in the diaphyses of long bones near the epiphyseal cartilage. As the infection develops, it may spread in different ways. The marrow cells are killed by the organisms and the process extends along the Haversian canals, the vessels of which become closed by thrombi. An infarct of the diseased bone then develops and the inflammatory process extends to the periosteum, which becomes raised from the subjacent bone, a subperiosteal abscess forming. If this abscess breaks through the periosteum, a submuscular or subaponeurotic abscess is formed.

In other instances the inflammatory process extends to the marrow cavity along which it travels so that, within a few hours, the process may involve the entire shaft of the bone, having spread from one epiphyseal cartilage to the other. When the marrow cavity is exposed in such a case, a mottled tissue is found, green areas of necrotic marrow, yellowish areas of suppuration and injected hemorrhagic areas being intermingled. The shaft of the bone becomes necrotic and separated

from the periosteum which is raised by a layer of pus, to form a sequestrum. Such a sequestrum comprising the entire shaft is called a total sequestrum.

The cortex of the bone, if exposed early, after having been stripped of its periosteum appears white and has a luster. Later it may become of a dead white color or after remaining some time as a sequestrum it may become brown or black in color.

An inflammatory process situated as near the epiphyseal cartilage as the osteomyelitic focus usually is, may spread along the surface and cause separation of the epiphysis, which is one of the complications of this disease.

The size of the sequestrum naturally varies widely in different cases. When the inflammatory process has been circumscribed, and has extended outward to the periosteum, without stripping the latter from the cortical bone to any great extent the sequestrum may be very small, while in those cases in which a medullary phlegmon has developed, the entire shaft of the bone from one epiphyseal cartilage to the other will become necrotic. When the inflammatory process is not so extensive, a partial necrosis of the shaft results, the dead cortical bone being separated from the healthy bone by a line of demarcation formed by granulation tissue. Central and total sequestra of the diaphysis are usually tubular or cylindrical, while cortical sequestra resemble discs or chips.

The time required for the separation of the sequestrum varies with the amount of bone which has become necrotic and the rapidity with which the reparative process goes on. Six months or more may be required for the complete sequestration of a large piece of dead bone, while in those cases in which the sequestrum is small and superficial, the dead piece of bone may be so completely separated that it is discharged when the subperiosteal or subaponeurotic abscess is opened soon after the beginning of the disease. A very small sequestrum, especially when formed from spongy bone may, if not removed, be destroyed by granulation tissue. This, however, is the exception and a sequestrum even when very small will keep up a discharging sinus unless removed or discharged spontaneously.

While destructive processes are going on and leading to necrosis of a part, or all of the cortical bone, reparative processes occur in the periosteum and endosteum. The periosteum takes a very active part in the formation of a granulation tissue surrounding the dead bone This newly formed tissue which develops from the periosteum in the

early stages, resembles somewhat the callus which forms at the seat of a fracture. These reparative processes are most active in the long hollow bones. In the early stages this granulation tissue is soft, form-

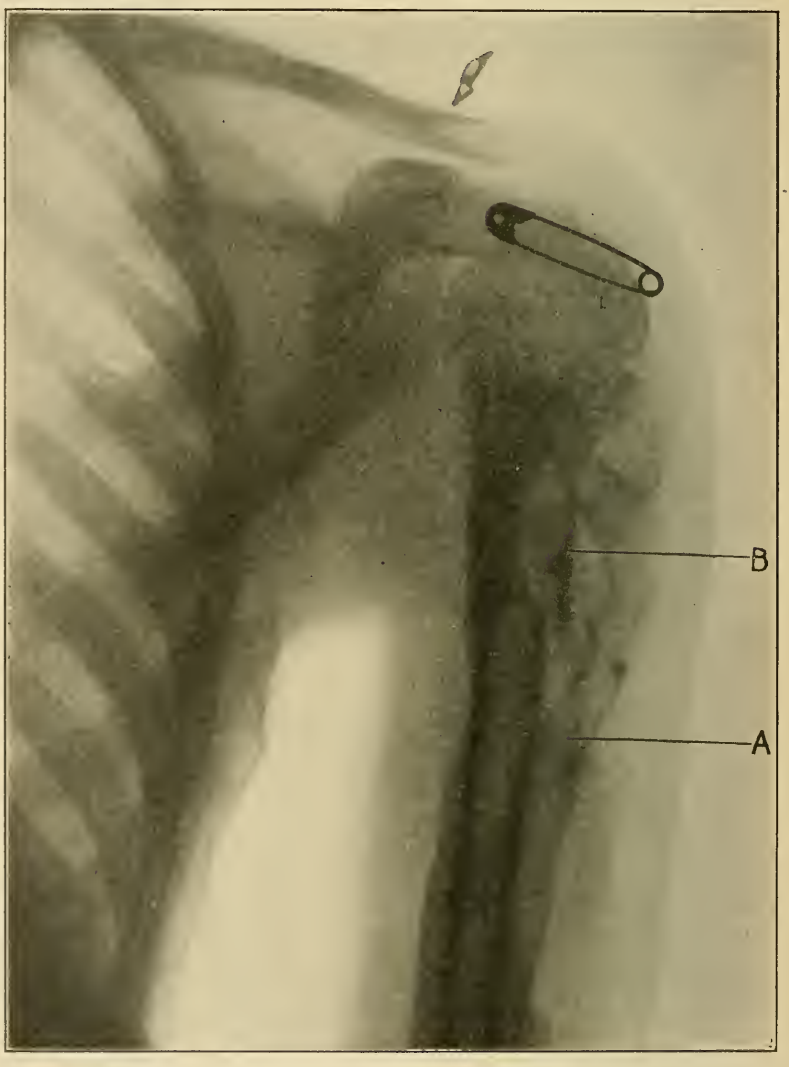

FIG. 228.—Osteomyelitis of the humerus in a boy aged 12. *A*, Involucrum, extending halfway down the shaft; *B*, sequestrum, flat, disk-shaped. At operation several small chips of bone were removed from the position indicated by *B*. The greater part of the shaft was alive, although the X-ray might indicate that sequestration would be more extensive. (*Lewis.*)

ing a vascular irregular mass of rather friable tissue. Often, as early as a week after the beginning of the inflammatory process, delicate

layers of spongy bone begin to develop within this granulation tissue which has been formed by the inner layers of the periosteum, and gradually a bony shell, which at first is thin, fragile and porous, develops and surrounds the necrotic bone. Eventually, the newly formed bone

FIG. 229.—Osteomyelitis metacarpal bone in patient whose humerus is represented in Fig. 228. An extensive involucrum is found. No abscess has formed in this pyogenic bone infection nearly six months after beginning of disease. (*Lewis.*)

becomes hard, and in most cases in which the sequestrum is removed late, the involucrum is found to be formed of eburnated bone, hard as ivory.

Canals of different sizes lined with granulation tissue pass through

the involucrum. Through these canals, to which the term "cloaca" has been applied, the pus which forms about the sequestrum is discharged into the sinuses, emptying upon the surface. They represent also the points at which the subperiosteal abscess or abscesses ruptured through the periosteum into the submuscular or subaponeurotic spaces.

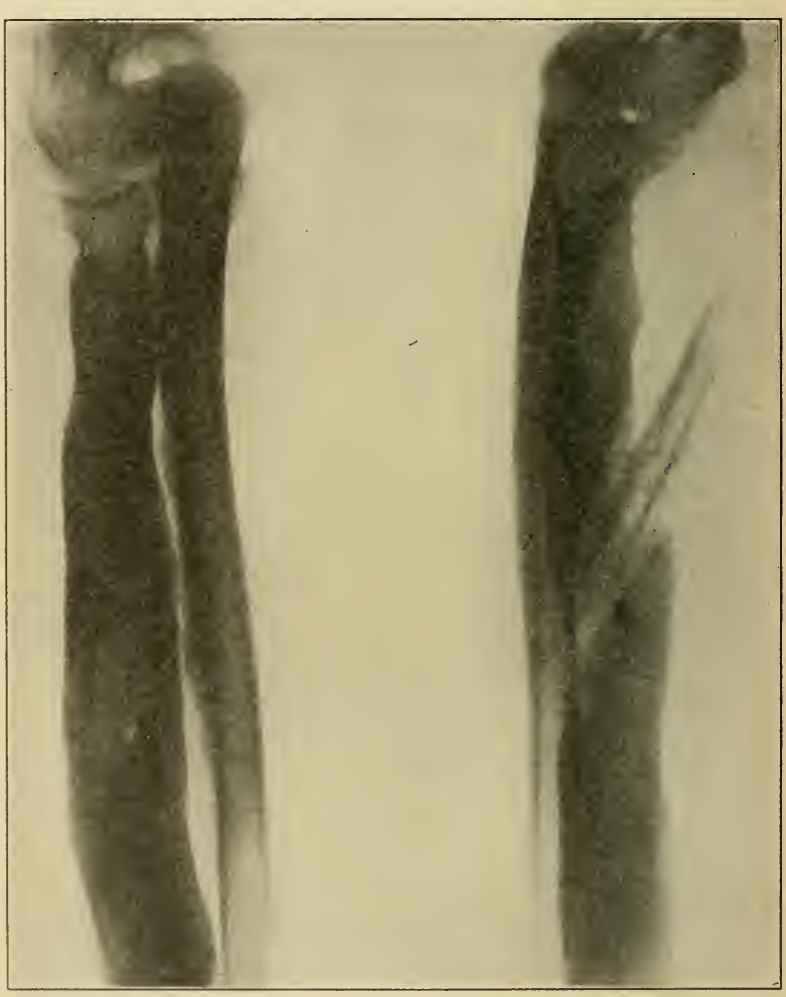

FIG. 230.—Osteomyelitis of shaft of radius showing thickened irregular shaft and sequestrum projecting outward. (*Potter.*)

The involucrum passes over at both ends of the sequestrum to the healthy bone, gradually becoming continuous with the periosteum of the same.

A sclerotic process occurs about bone abscesses, in which no definite sequestrum is found and may extend for a considerable distance into

the bone surrounding a very small abscess cavity, so that in many cases an abscess containing but a few drops of pus will be surrounded by a thick capsule of hard, eburnated bone. In the sclerotic forms of osteomyelitis, such as have been described by Garré, this newly formed eburnated bone may encroach upon and gradually obliterate the marrow cavity, and a large part of the bone; or the ends of it may be converted into a solid mass with no marrow cavity. Abscesses, small islands of granulation tissue enclosing a small central sequestrum, may be found surrounded by this sclerotic bone.

The clinical course of osteomyelitis of the bones of the upper extremity does not differ from that of osteomyelitis occurring in other bones. The foci are found most frequently in the upper end of the humerus and in the lower end of the radius, the osteomyelitis associated with osteal felons being excluded. The clinical picture and course differ widely in different cases depending upon the virulence of the bacteria, the susceptibility of the patient, the location of the primary focus and the direction in which the inflammatory process extends.

The disease usually has an acute onset, with or without a chill. The patient complains of severe agonizing throbbing pain in the extremity. In many instances the pain is so severe that it is difficult for the patient to designate its exact location. The inflammatory process is under tension and there is rapid absorption of toxic materials. The temperature is high, reaching 103° or 104°F. with but little morning remission. There is a leucocytosis, the white cells numbering all the way from 15 to 30,000. The face is flushed and has an expression of pain; the tongue is coated and tremulous and a mild delirium indicates the general reaction to the absorption of toxins.

Movements of the joints are usually not painful in the early stages, but percussion of the bone increases the pain. Soon there develops a definite localized point of tenderness over the inflamed area, which is one of the early and most valuable diagnostic signs. In a few hours or days, varying in different cases and depending upon factors already mentioned, a swelling of the affected part develops. This swelling is usually coincident with the formation of a subperiosteal abscess or the rupture of such an abscess into the submuscular or subaponeurotic spaces. The symptoms may improve somewhat when this occurs, for the inflammatory products are no longer under as great tension.

In most cases the diagnosis can be made without much difficulty. The acute onset with severe pain, and the localized point of tenderness are quite characteristic. It should be remembered too that osteo-

myelitis is common in children and young adults. Formerly many cases of osteomyelitis were regarded as rheumatism, but such errors in diagnosis should be rather easily avoided, as rheumatism is usually a polyarticular affair and the changes are confined to the joints. The diagnosis may be difficult when absorption is so rapid that the patient is dulled mentally or delirious so that a history cannot be elicited, or any accurate information given concerning the localization of the pain.

The most important sign which aids in early determination of the situation of the inflammatory focus is the localized point of tenderness. An X-ray examination is not of much service, for I have examined several early cases, and it is only at the end of a week or later that changes have occurred which can be demonstrated with the X-ray. In performing an early operation, we must rely upon the localized point of tenderness to indicate the position of the inflammatory focus.

Streptococcic and Pneumococcic Osteomyelitis.—It has been previously stated that the symptoms and clinical course of the different forms of osteomyelitis give no indication as to the nature of the infecting organism.

Osteomyelitis due to the streptococcus and pneumococcus have, however, some peculiar features which demand especial attention. In 1898 Lexer published an article dealing with some cases of streptococcus osteomyelitis which had been carefully studied clinically and bacteriologically. The most striking facts were the early age at which this type of osteomyelitis developed, the disease occurring in children between three weeks and two years of age, and the fact that the inflammatory process, situated in the typical position in the shaft, remained rather definitely localized but was frequently associated with a suppurative arthritis, or a para-articular phlegmon which caused little or no destruction of the tissues entering into the formation of the joint. The inflammatory process caused by the streptococcus has less tendency to spread along the epiphyseal cartilage and to cause a separation of the epiphysis than that due to the staphylococcus.

The relation between streptococcic osteomyelitis and acute suppurative arthritis occurring in young children is interesting. Krause was the first to draw attention to the fact that the acute suppurative synovitis occurring in children was due to the streptococcus. In cases in which the joint is incised early the synovia has the consistency of thick nasal mucus, is glossy in appearance and covered with streaks of thick yellow pus.

Lannelongue believed that these cases of streptococcic arthritis oc-

curring in children were secondary to osteomyelitic foci which were overlooked. This view is probably not correct, for cases of suppurative arthritis due to the streptococcus are observed in which the lesion heals rapidly without impairment of function of the joint after simple incision. If there were a bone focus in such cases, it is not probable that the inflammatory process would subside so rapidly after simple incision, no attempt having been made to locate or remove an osteal focus.

Pneumococcic osteomyelitis is much less common than streptococcic osteomyelitis.

Complications.—Spontaneous fractures of the bones of the upper extremity in cases of osteomyelitis are rare. Funke reports but one case of pathological fracture of the humerus in 46 cases. The relative infrequency of pathological fracture is probably due to the fact that the parts are well protected while the patient is in bed and if up and about, a sling or protective dressing is usually worn. Pathological fracture is observed in cases of total necrosis, when the dead shaft may be broken before the involucrum is formed. In other cases a weak involucrum has been formed but passive motion is begun early to prevent or correct a fibrous ankylosis and the involucrum which is but poorly developed is fractured. Spontaneous fracture of the upper end of the humerus is more common than that of any of the other bones of the upper extremity.

Separation of the upper epiphysis of the humerus was observed by Trendel in three cases of osteomyelitis of the humerus.

Spontaneous fracture and epiphyseal separation usually delays the reparative process and may lead to shortening of the extremity. In those cases in which fracture has occurred after the involucrum is fairly well formed, the sequestrum should be removed, and the ordinary dressing for fracture should be applied, provision being made for dressing the wound. As mentioned above, some of these fractures occur rather late when passive motion is instituted to overcome a fibrous ankylosis.

Involvement of Adjacent Joint.—Arthritis is a common complication of an osteomyelitis involving the extremity of a bone. This arthritis is usually not suppurative in character. An effusion is poured into the joint and a position of the joint is assumed which if not corrected leads to contractures which may be difficult to correct later. Trendel's statistics show that among 180 cases of osteomyelitis involving the humerus, radius and ulna, some permanent disturbance of joint function was observed in 82 cases or practically one-half.

Treatment.—The treatment will be considered under two heads: (1) that employed in the acute stage; (2) that employed in the chronic.

The treatment to be instituted in the acute stage of osteomyelitis is the same as that employed for suppurative processes in any of the other tissues of the body. As soon as a diagnosis of acute osteomyelitis is made, an operation which should provide for free escape of pus and good drainage of the marrow cavity is indicated. Two types of operation have been employed: (1) simple incision with removal of a portion of the cortex to provide for drainage; and (2) excision of a large piece of bone with removal of the diseased marrow by a sharp spoon. The second operation was performed with the idea of removing all of the infected material at once in the hope of lessening the general reaction and preventing extensive necrosis. Experience has shown, however, that this extensive operation, associated with a higher mortality than simple incision, does not immediately lessen the general reaction, neither does it in all instances lessen the amount of necrosis; for this reason it has not been generally accepted, although employed at the present time by some very capable surgeons. More or less of the endosteum is destroyed by the inflammatory process and curetting removes more of it, favoring necrosis of the inner layers of the cortex.

In performing the first operation an attempt should be made to carry the incision through intermuscular planes in reaching the bone. The localization of the focus in the early cases must be dependent upon the localized point of tenderness, for in the very early cases, as previously mentioned, the X-ray gives little or no aid because changes have not taken place in the bone which permit of differentiation. When the bone is exposed, a piece of cortex is removed with chisel or trephine sufficient to expose the diseased marrow. If liquefaction of the marrow has occurred, pus upon which float oil droplets will escape. In very early cases the marrow may appear necrotic, no pus escaping, because liquefaction has not occurred. It should be remembered that the different spaces in the marrow cavity communicate freely and that a fairly good sized opening in the cortex will drain quite a large part of the marrow cavity. If the operation is performed early enough to preserve the endosteum, regeneration without sequestrum formation may occur, but this is the exception, for usually a sequestrum is found which later must be removed.

When drainage has been established either by operation or spontaneously and the process in the bone has become limited, the disease passes into a subacute or chronic stage. Discharging sinuses are pres-

ent leading down to the sequestrum which is surrounded by proliferating bone. In some of those cases only a part of the cortex has become necrotic, and at operation a sliver of bone is found lying upon a bed of granulation tissue. In most of the cases, however, the necrosis involves the entire thickness of the cortex.

The time at which the sequestrum should be removed depends upon whether the proliferating, but plastic periosteum, has support from a neighboring bone, which splints, as it were, the poorly developed involucrum when the sequestrum is removed. In most cases it is preferable to defer removal of the sequestrum until the involucrum is well enough developed to carry on the function of the shaft. In many cases which come to operation the involucrum is formed of dense bone. Such an involucrum has but little power of central growth, and discharging sinuses leading down to a central cavity which is exceedingly difficult to obliterate may persist even after removal of the sequestrum. As soon as the involucrum is able to take on the function of the shaft, the sequestrum should be removed. According to Nicoll, the operation may be undertaken when the total diameter of the involucrum is equal to one-half the diameter of the normal shaft. This usually is about 12 weeks after the beginning of the infection. The time at which the operation should be undertaken should depend upon X-ray findings, rather than upon the length of time which has elapsed since the beginning of the infection.

Those cases in which a heavy involucrum composed of dense, ivory-like bone has formed, offer the greatest difficulties in obtaining satisfactory results. Such an involucrum has but little central growth and after the sequestrum is removed, a suppurating cavity remains. The attempt to close such a cavity by allowing blood to collect after thorough sterilization of the cavity and suturing the skin over, is only occasionally successful, for the cavity cannot be thoroughly sterilized and the clot becomes infected and in many cases the bone has not reparative power enough to develop granulation tissue to infiltrate the blood clot. In some instances I have tried to close such cavities, after removing the sequestrum, by applying pure carbolic acid to the walls of the cavity, neutralizing this with alcohol and then drying the cavity with an actual cautery, a constrictor on the limb preventing hemorrhage into the cavity. When thoroughly dry the cavity is filled with the Mosetig-Moorhoff plug and the skin sutured over the cavity. In some instances rather large cavities have been obliterated in this way. In other cases infection has developed and the plug has been extruded or

removed. In some cases after partial extrusion of the plug, the cavity has become closed. In all of these operations it is necessary that all of the dead bone be removed.

Transplantation of fat seems to offer much in the closing of some of these bone cavities. If the cavity can be rendered clean, a mass of fat may be transplanted into the cavity and the skin sutured over it. It is possible to obliterate an old suppurating cavity by inverting skin flaps into it. A piece of the cortical bone surrounding the cavity is removed so that the latter is more or less flattened. Then skin flaps are inverted into the trough which is formed and are held against the granulation tissue by sutures or dressings. The granulating cavity is obliterated in this way, but no new bone is formed. New bone formation is not necessary in these cases, for the bone in the involucrum is usually strong enough to carry on the function of the part. Obliteration by skin grafting at least rids the patient of the discomfort of an old suppurating cavity.

The following statistics compiled by Trendel show the outcome of a considerable number of cases of osteomyelitis of the bones of the upper extremity.

Bones involved	Cases	Healing without suppuration	Healing without necrosis	Sequestrotomy	Spontaneous discharge of sequestrum	Not operated on
Humerus.....	112	5	21	65	14	7
Radius.....	45	3	2	36	2	2
Ulna.....	40	2	7	23	2	6

Tuberculous Osteitis.—Tuberculous foci in bone are usually situated in the epiphysis. The process generally extends to the joint, so that clinically the symptoms due to the arthritis overshadow those caused by the bone involvement. The localized epiphyseal form of bone tuberculosis will be discussed in the chapter dealing with tuberculous arthritis.

Tuberculosis of the marrow cavity of the short bones is common, but a tuberculous osteomyelitis of the long pipe bones is uncommon. Statistics from the von Bruns' clinic show that there were only six cases of tuberculous osteomyelitis of the long bones among 2127 cases of bone and joint tuberculosis which were observed clinically. It is possible that some of the cases in this series which were regarded as due to pyogenic organisms were tuberculous.

There are two forms of tuberculous osteomyelitis; a primary and a

secondary. In the primary form the tuberculous process begins in the marrow of the shaft (Fig. 231), while in the secondary form the tuberculous process extends to the marrow cavity from a diseased joint, or a focus in the spongiosa.

Primary tuberculous osteomyelitis of the long pipe bones is most common in small children between the ages of two and six. Generally there is tuberculosis of other organs or tissues, but the disease may

FIG. 231.—Tuberculosis of the shaft of the radius. (*Tietze.*)

develop in individuals previously healthy as cases observed by Krause and Küttner indicate.

Pathology.—The pathological picture in tuberculous osteomyelitis differs, as the focus may be circumscribed, or the entire marrow may be infiltrated. In the circumscribed form only tuberculous granulation tissue is found, while in the diffuse, infiltrating forms of tuberculous osteomyelitis, sequestrum formation is observed. The sequestra which form in diffuse tuberculous osteomyelitis are usually small, but Küttner has observed a case in which the sequestrum was 4 cm. in length. Schernigflug has observed two cases of total necrosis of the ulna, and

Karewski one of total necrosis of the radius in this diffuse form of tuberculous osteomyelitis.

The tuberculous granulation tissue observed in both forms may liquefy to form tuberculous pus, which extends through the bone to the periosteum and perforates the latter to form submuscular or subcutaneous abscesses. After these are opened or discharge spontaneously, sinuses lined by indolent granulation tissue which lead down to the diseased bone focus persist.

There is also a rare form of primary tuberculous osteomyelitis, which corrsponds clinically to spina ventosa. In these cases the shaft of the bone becomes symmetrically distended from expansion and destruction of the cortex by the tuberculous tissue and from the formation of new bone by the periosteum which in turn is destroyed. This form of tuberculous osteomyelitis is observed less frequently in the radius, ulna and fibula than in the metacarpal and metatarsal bones, but is more common in these than in the tibia, femur and humerus.

Secondary Tuberculous Osteomyelitis.—In this form of tuberculous osteomyelitis the inflammatory process extends to the marrow cavity from a diseased joint or from a localized focus in the adjacent spongiosa. It appears clinically in two forms: (1) as caries carnosa; (2) as a progressive infiltrating tuberculosis.

Caries Carnosa.—Caries carnosa is a rare form of tuberculous osteomyelitis, usually associated with rather acute and severe symptoms. It is observed almost exclusively in the upper end of the humerus, being secondary to tuberculosis of the shoulder-joint. As the marrow becomes involved the arthritis becomes of secondary importance and is overshadowed clinically.

The tuberculous process destroys the articular cartilage of the humerus and the bone becomes so soft that it can be cut with a knife. The marrow becomes converted into a red, fleshy mass of soft consistency, which is composed almost entirely of young connective tissue infiltrated with miliary tubercles and the cortex becomes thinned, there being little or no reaction on the part of the periosteum to the inflammatory process.

The Progressive Infiltrating Form of Tuberculous Osteomyelitis.—This form of tuberculous osteomyelitis is rare, as the statistics compiled by Küttner from Von Brunn's material would indicate. During a period of 25 years, there were observed in Von Brunn's clinic only five cases of progressive infiltrating tuberculosis, forming but 0.23 per cent. of the cases of bone and joint tuberculosis observed during that period.

In this form of tuberculous osteomyelitis the articular cartilage is usually destroyed and the spongy bone infiltrated diffusely. It is light yellow in color, has a dry, anæmic appearance and sometimes contains small foci of suppuration. Volkmann has stated that the infiltrated bone in these cases resembles Limburger cheese in appearance. The compact bone when involved has a homogeneous light yellow color and the characteristics of a tuberculous sequestrum. The extent of the lesion naturally varies. In advanced cases the entire marrow may be converted into a fungus mass, throughout which are scattered small suppurating foci (suppurative tuberculous osteomyelitis).

This form of tuberculous osteomyelitis is most common in adults between 45 and 50 years of age. It has, however, been observed in the young. It is apt to occur in individuals whose general resistance has been lowered by tuberculosis of some of the other tissues or organs.

The extent of the process is not usually recognized by the clinical examination and, before routine X-ray examinations were made, the operating surgeon undertaking a resection of a joint for tuberculous disease was often surprised to find the marrow extensively involved, necessitating resection of the diseased bone or perhaps amputation.

Treatment.—An attempt should be made to remove all of the infected bone. The focus in the bone can be located by an X-ray picture. The bone at the site of the lesion is exposed and after the cortex is removed if the lesion has not extended through it, the focus is removed by a curette or chisel. The operation should be carried into the healthy bone so that there will be no possibility of leaving any diseased tissue. Such a cavity should be disinfected with pure carbolic acid which is neutralized by alcohol and dried with a cautery. The cavity may then be filled with a bone plug (Mosetig-Moorhoff) and the skin sutured over it. Tuberculous disease of bone in children tends to be a self-limited disease and the reparative processes attending curettage are often sufficient to overcome the tuberculous process.

Stiles favors a more radical procedure in the treatment of tuberculous osteomyelitis. It has been his experience that the early results of the treatment outlined above are satisfactory enough, but that too often the patient sooner or later returns with an infected scar and a sinus leading down to disease in bone which had not been removed. He believes that such a result is not to be wondered at when it is remembered that it is almost impossible to remove all the affected tissue by curette or gauze. After some disappointments with the conservative procedure, he adopted subperiosteal resection of the diseased part

of the diaphysis as the operation of choice. The bone is divided well above and below the focus and is removed radically as if it were the seat of a malignant tumor. In the after-treatment a dressing is applied which will maintain the correct position of the part and is worn until the new bone which develops is hard enough to maintain its function. If the disease has not involved the periosteum the new bone is perfectly reformed in from three to six months. When the periosteum has been invaded the reproduction of bone is less perfect. The technique employed by Stiles in resection of the different bones of the upper extremity cannot be discussed because of lack of space. For a detailed description of the technique the reader is referred to Burghard's System of Operative Surgery, 1909, II, pp. 9–23.

The treatment to be followed in cases of caries carnosa and the progressive infiltrating form of tuberculous osteomyelitis varies. The extent of the operation depends upon the amount of bone involved and the condition of the patient. As many of the patients have tuberculosis in other organs, amputation may be indicated to get rid of an extensive tuberculous process and promote rapid convalescence. The type of operation must be determined after all factors, such as rapidity of convalescence, general health of the patient, etc., have been considered. The prognosis of tuberculous bone disease in adults is much worse than in children and extensive disease in adults is, therefore, often best treated by amputation rather than by the more conservative procedures which are often successful in children. The X-ray examination reveals the extent of involvement of the marrow, so that the operative procedure can be more definitely outlined than formerly.

In the localized forms of tuberculous osteomyelitis, the diseased bone is opened with a chisel after the location and extent of the focus is determined by an X-ray examination. The diseased focus is then removed by a curette or gouge, the removal of bone being wide enough to insure that all diseased tissues have been eradicated.

Spina Ventosa.—Tuberculosis of the shaft of long bones, as previously stated, is not common. In tuberculosis of the short bones the changes are most pronounced in the shaft giving rise clinically to quite a typical appearance, as the bone becomes expanded symmetrically and becomes fusiform in shape. Spina ventosa is the term applied to tuberculosis of the phalanges and metacarpal bones (Fig. 232). We shall later learn that syphilis of these bones may produce the same changes and be associated with about the same clinical picture.

The anatomical distribution of the nutrient arteries accounts for the frequency of tuberculosis of the shaft of the phalanges and metacarpal bones. Soon after entering the bone the artery breaks up into its finer branches, and thus bacterial or other emboli are retained

in the shaft and, developing there, produce the typical deformity and clinical picture of spina ventosa.

In tuberculosis of the phalanges and metacarpal bones the process may begin in the periosteum or in the marrow. In adults the lesion begins more frequently as a periostitis, while in children the lesion is almost exclusively primary in the marrow. In the periosteal

FIG. 232.—Periosteal and medullary spina ventosa. (*de Quervain.*)

form the entire shaft is gradually deprived of its nutrition as the periosteum becomes more and more involved and separated from the bone. The total sequestrum which forms, remains, unless discharged through a sinus or removed. The tuberculous periosteum does not produce a heavy involucrum, such as is formed in pyogenic infections, and as a consequence the finger is shortened and deformed. Frequently small sinuses leading down to

small pieces of bone which have been formed by the diseased periosteum persist after removal of the necrotic shaft.

The appearance of spina ventosa is characteristic. As the tuberculous process develops in the bone, the part involved becomes fusiform in shape, the expansion usually being quite symmetrical. The skin at first has a white waxy appearance, and seems œdematous. A peculiar elastic feel is imparted to the palpating finger. As the inflammatory process approaches the surface the skin becomes red and cyanotic. This color may be diffuse or it may be localized to points at which small abscesses subsequently appear. The appearance is so typical that usually there is very little difficulty in making a diagnosis. Syphilitic dactylitis may, however, present all of the features associated with a tuberculous lesion and there is often difficulty in making a differential diagnosis, the therapeutic test being the last resort.

Tuberculosis of bone in children tends to spontaneous cure. In the treatment of spina ventosa, in children, which in most cases is primary in the marrow, a conservative treatment should first be instituted. The patient should be placed in a good climate and the hygienic surroundings required by tuberculous patients provided. Tuberculin is of distinct value in the treatment of this type of tuberculosis. I have seen many cases of spina ventosa cured in children by a conservative line of treatment, when the conditions found at the first examination seemed to warrant an operation.

If the process does not improve under general hygienic treatment and abscesses form which demand opening, operative treatment should be instituted. This consists in exposing the marrow cavity and removing the focus of disease or any sequestra which may have formed.

These operations, as formerly performed, left much to be desired cosmetically, for after operation the fingers were often deformed and permanently shortened. To prevent these deformities bone grafting should be utilized. The grafting should be done at the time of the primary operation, even when there have been discharging sinuses, because a bone graft will often heal, even in the presence of a mild infection. Partial sequestration of the graft may occur in such cases but the small sequestrum may be removed. Some of the results obtained by removal of the diseased bone, followed by bone grafting, have been most gratifying.

As previously stated, the periosteal form of spina ventosa, which occurs most commonly in adults, is more apt to be associated with deformity than the medullary, and in this bone grafting offers great hope.

Syphilitic Osteitis.—Hochsinger found in examining 263 children having congenital syphilis that the first manifestation of the disease developed in the bones in 95 and that 64 of these 95 children were the first-born of syphilitic parents. Still-born babies of syphilitic parents present almost constantly osteal changes. In marked cases practically all the bones of the skeleton are involved. Cases of multiple separation of the epiphyses have been observed in which the pathological changes observed in other organs would seem to indicate that the separation was due to a syphilitic change involving the epiphyseal cartilage and the bone immediately adjacent.

Syphilitic Osteochondritis.—Wegner, in 1870, demonstrated in the syphilitic still-born and in children dying shortly after birth quite a constant change in the transition zone between the epiphyseal cartilage

and the epiphysis which he called syphilitic osteochondritis. The pathological change is most marked in the epiphysis, but may extend into the diaphysis, differing in this way from rickets. In syphilitic osteochondritis the epiphyseal cartilage becomes widened, wavy and irregular and of a grayish yellow color. This grayish yellow color is due to fatty degeneration of granulation tissue which develops in the marrow adjacent to the cartilage.

Syphilitic osteochondritis is observed most frequently in the lower end of the femur; then in the lower epiphyses of the bones of the leg and forearm, in the upper epiphysis of the tibia and the upper epiphyses of the femur and fibula. The humerus is more rarely involved and very much less often the upper epiphyses of the radius and ulna. The lower epiphysis of the humerus is the one least frequently affected.

Less common than syphilitic osteochondritis is the congenital ossifying gummatous periostitis which leads to thickening of the diaphyses of long hollow bones, chiefly at the middle. In this form of syphilitic osteitis the shafts of the femur, humerus and tibia are involved with about the same frequency and intensity. The bones of the forearm are much less frequently diseased than those just mentioned. The simultaneous occurrence of syphilitic osteochondritis and ossifying gummatous periostitis is but rarely observed.

The pseudo-paralysis associated with congenital syphilitic bone disease may be due to separation of an epiphysis resulting from an osteochondritis, or to an extension of the inflammatory process to the muscles inserted into or arising from the bone immediately adjacent to such epiphysis. When the upper extremity is involved in this form of pseudo-paralysis the arm is applied closely to the trunk, the forearm and hand being held in pronation. The muscles contract when the skin is pricked with a needle or electrical stimulation is applied. There are usually no sensory disturbances and no indication of any disturbances of the central nervous system.

The treatment of syphilitic osteochondritis, even when associated with pseudo-paralysis, is very satisfactory. When mercury is administered, most conveniently and satisfactorily by inunctions, the tenderness soon disappears and active motions are begun again. The movements normal to the part are rapidly restored even before the osteal enlargement associated with the osteochondritis has completely subsided.

Gummatous osteitis is not infrequently observed in the humerus and radius, less frequently in the ulna. The bones of the upper ex-

tremity are, however, much less frequently affected than the tibia, sternum, clavicle and bones of the skull. The gumma is the most important syphilitic lesion of bone and occurs in both the congenital and hereditary forms. The periostitis which occurs in the earlier stages of syphilis cannot be differentiated from the periosteal gumma and is probably but a mild form of the latter. In gummatous periostitis a circumscribed inflammatory process develops in the inner layer of the periosteum and leads to the formation of nodular thickenings of the surface of the bone. In most instances the periosteal gummata are probably associated with gummata in the endosteum and some believe that the periosteal growths are due to inflammatory processes extending from gummata situated more deeply. The endosteal gumma extends to the surface of the bone, which it invades by way of the Haversian canals. Proliferative are combined with destructive processes, so that nodules or diffuse thickenings develop upon the bone, the surface of which may appear ragged upon X-ray examination. Small cortical sequestra may also be revealed by the X-ray.

When incised, as occasionally happens when a wrong diagnosis has been made, a periosteal gumma is found to contain a rather thick, tenacious fluid, to have a grayish red appearance and to be somewhat elastic to the touch.

Gummatous periostitis is characterized clinically by the relatively slow development of the lesion, its chronicity, and the size which it attains. When the gumma develops, a nodule or swelling forms upon the bone, which is painful and often exquisitely tender. The skin covering such a lesion is at first practically normal. When regressive changes occur, a fluctuating swelling forms, but the lesion before these changes appear, has an elastic feel. As the bones of the arm and forearm are well covered by muscles, the skin is but rarely involved in the specific forms of osteitis.

A diffuse syphilitic periostitis and osteomyelitis occurs in the bones of the forearm, especially in the radius. When a bone is involved in this diffuse process it becomes thickened, sclerotic and heavier than normal (Fig. 233). The periosteal proliferation leads to the formation of a heavy shell of new bone, while the marrow cavity may be obliterated by the changes associated with the syphilitic changes in the marrow. The most typical example of this diffuse form of syphilitic periostitis and osteomyelitis occurs in the tibia in the condition sometimes called syphilitic osteitis deformans. This diffuse process also occurs in the bones of the forearm, especially in the radius. Central

gummata may cause pathological fractures. As they develop they may cause a rarefaction of bone. Cases of pathological fracture due

FIG. 233.—Syphilitic periostitis of the radius. (*Tietze.*)

to gummata have been reported in which a pseud-arthrosis has persisted even after the specific lesion has been controlled.

The diagnosis of specific bone disease is usually not difficult, especially when there are other manifestations of disease. In congenital

syphilis the Hutchinson teeth, rhagades and interstitial keratitis may give a clue to the true nature of a bone lesion. In some instances there may be some difficulty in differentiating a gumma from a tumor of bone. The X-ray renders such differentiation possible in most cases. In doubtful lesions the Wassermann reaction is of great assistance.

Syphilitic bone lesions usually rapidly subside when antisyphilitic treatment is given. If a sequestrum forms, an operation will be required to remove it. Such indication for operative interference is rare, except in those cases in which the process has extended to the skin, which has become ulcerated, and a cortical sequestrum is found in the base of the ulcer.

Syphilitic dactylitis is observed in both congenital and acquired syphilis. It appears in two forms. In one the gumma develops beneath the periosteum or in the marrow cavity of the phalanges. As the inflammatory process develops, the bone or bones affected, for the lesion is frequently multiple, becomes symmetrically enlarged. Clinically this specific lesion resembles spina ventosa, discussed in the chapter dealing with tuberculosis of the phalangeal and metacarpal bones, and it is often difficult to determine whether the lesion is specific or tuberculous. Such a lesion may regress under antisyphilitic treatment, may lead to pathological fracture (this is rare because enough new bone is usually formed to prevent fracture) or may soften and discharge externally, sinuses forming which lead down to small cortical sequestra. Much the same clinical appearance is noted when a diffuse gummatous process develops in the subcutaneous tissues, and gradually extends over the entire finger. In the second form the gummatous process extends from the subcutaneous tissues to the periosteum of the phalanx and to the neighboring joint, the articular cartilages of which may be destroyed. The joints then become stiffened and when the process subsides under antisyphilitic treatment more or less crepitation may be found and the function of the joint may be permanently impaired. Dislocation forward, backward, or to the side, may result from an extensive involvement of the joint surfaces in such a process.

In either form of syphilitic dactylitis, bone destruction may be great enough to cause marked deformities of the fingers. In some instances the diseased phalanx has become longer than the ones not involved.

Tuberculous and syphilitic disease of the phalanges and metacarpal bones is so similar clinically that it is often difficult to make a differential diagnosis. The preceding history of the case is naturally of utmost importance, for a history of a chancre or the secondary manifestations of syphilis points to a syphilitic nature of the disease. The Wassermann reaction is of value in determining whether or not the lesion is specific in character.

Syphilitic dactylitis usually responds readily to antisyphilitic treatment. Operative interference is not indicated unless sequestration of part of the bone involved occurs. Even when the process has extended into the interphalangeal joints, as frequently happens in the subcutaneous form of syphilitic dactylitis, motion at these joints may be retained when the process subsides under antisyphilitic treatment.

Fibrous Osteitis and Bone Cysts.—Fibrous osteitis is a disease of bone characterized by the transformation of the marrow into fibrous tissue. As this fibrous tissue develops, the cortex of the bone is gradually absorbed, so that finally it is not much thicker than an egg shell. Giant cells are found where the bone is undergoing destruction or where

hemorrhages are being absorbed, and, therefore, the tissue found in fibrous osteitis resembles quite closely that of a giant-cell sarcoma. As the cortical bone becomes thinned spontaneous fractures and deformities occur and the names of chronic deforming osteitis and chronic deforming osteomalacia have been given to the disease (Fig. 234).

FIG. 234.—Myxoma of middle phalanx showing thinning of cortical bone as in the case of cystic disease. (*Lewis.*)

Pathology.—The essential features of fibrous osteitis are the development of fibrous tissue in the marrow cavity, throughout which may be scattered giant cells (Fig. 235); decalcification and expansion of the cortical bone, ending in pathological fractures or deformities, and liquefaction of the newly formed tissues resulting in cyst formation. Bone cysts

are but the terminal stages of fibrous osteitis. The different theories as to the origin of bone cysts will be discussed later. The cyst wall varies considerably in different cases. A small cyst may be surrounded by a large mass of tissue, while a large cyst may be surrounded by a membrane composed of delicate connective-tissue fibrillæ. The wall of such a cyst may contain hyaline cartilage, as in the case reported by Virchow, or tissue resembling histologically a giant-cell sarcoma. The contents of a bone cyst are usually of a reddish or chocolate brown color.

Theories as to Etiology of Bone Cysts and Relation of Fibrous Osteitis to Cyst Formation.—Virchow believed that bone cysts were the result of liquefactive changes in pre-existing enchondromas. He

FIG. 235.—Section fibrous osteitis showing character of tissue which fills marrow cavity. Few giant cells are seen in this section. In fibrous osteitis they are found when bone is being absorbed and about hemorrhages. (*Lewis.*)

found in the walls of a cyst of the humerus of a woman 56 years of age, and in the adjacent bone marrow, islands of hyaline and fibrocartilage. Because of the cartilage, he believed that the cyst resulted from liquefaction of an enchondroma. It has been suggested that bone cysts are due to hemorrhages into the marrow cavity and that they are analogous to the brain cysts which follow apoplexy. If such were the case they would certainly be more common than they are. Repeated examination of fractures in different stages of repair fail to reveal

anything which corresponds to the findings in bone cysts as revealed by the X-ray. Lexer has demonstrated by animal experiments that healing takes place without cyst formation, even after extensive destruction of the spongiosa of long bones, with considerable intraosteal hemorrhage. It has also been suggested that bone cysts may develop as the result of mild infections which do not end in pus formation.

Bone cysts are probably but a terminal phase of fibrous osteitis. These two lesions have many things in common (1): the long bones are apt to be involved in each; (2) the age incidence of each is the same; (3) both are cured by simple incision and curettage; (4) transitional stages can often be followed through different phases, from the development of fibrous tissue in the bone marrow to cyst formation following the liquefaction of this newly formed tissue.

Fibrous osteitis is essentially a disease of the young, occurring most frequently during the second decennium. The disease has been observed in young children, Pfeiffer having reported a case in a boy two and one-half years old. The following statistics from Pfeiffer's article indicate the ages at which the lesion has been most frequently observed. The statistics are based upon 49 cases.

Between 1–10	6 cases
Between 10–20	29 cases
Between 20–30	7 cases
Between 30–40	4 cases
	46 cases

Three of the cases were of advanced age. Westphal's patient was 82 years old; Frank's 56; and Helbing's 50. It is possible that some of these should not be classified under this disease, or, on the other hand, it may be that the lesion appeared early in life and pursued an unusually latent course, the symptoms becoming pronounced at a late period of life.

In the 46 cases mentioned above, the femur was involved in 19 cases. In five of these the lesion was bilateral. The tibia was affected 12 times. The humerus was involved in 10 cases, the lesion being in the upper third in eight and in the middle third in two. The humerus is more frequently affected than any of the other bones of the upper extremity. A few cases of fibrous osteitis of the ulna, radius, metacarpal bones and phalanges have been observed.

The lesion occurs much more frequently in the metaphyses of the long pipe bones than in the diaphysis or epiphysis. This relationship

should be taken into consideration when making a differential diagnosis. The frequent involvement of the metaphysis is not easily explained, but it is supposed that it is because this part of the bone is more frequently subjected to strain and stress than the others are.

Clinical History.—The first symptoms are usually indefinite pains, often described by the patient as rheumatic in character, and an enlargement of the part involved. In some instances the pain has not been severe enough to attract the patient's attention and the first indication

Fig. 236.—X-ray of a case of fibrous osteitis of the upper end of the humerus. The multilocular nature of the lesion is shown. The fibrous tissue expands the bone equally in all directions, filling the interior of the thinned cortex like a mould. The cortex of the outer side has been fractured at one point. There has been no extension of the mass through this fissure. Symmetrical expansion of the bone, absence of extension through the thinned cortex and lack of periosteal proliferation are the most characteristic X-ray findings of fibrous osteitis. (*Lewis.*)

of the disease has been a pathological fracture, or a slowly developing deformity. The enlargement is usually symmetrical and fusiform. The X-ray findings are quite typical and an accurate diagnosis can usually be made upon these. Fig. 236 indicates the typical appearance of fibrous osteitis of the upper end of the humerus. The shadow occupies the metaphysis, but extends well down into the shaft. The lesion is limited above by the epiphyseal cartilage, beyond which it does not extend, and the bone is symmetrically expanded until it has become of egg-shell thinness. The cortex has been fractured on the outer side, but there has been no extension of the process into the overlying soft tissues.

Usually the course of fibrous osteitis is long, the disease extending over a period of years. A typical instance of this long course is shown in a case observed by Rehn. His patient was a poorly nourished girl 23 years of age. She complained first of pain in her right hip. Soon a swelling developed and the affected bone began to bend. Other bones softened and spontaneous fractures occurred. Three operations were performed upon the osteal enlargements associated with the spontaneous fractures, and in each instance a diagnosis of giant-cell sarcoma was made. Finally after nine years the patient died of cachexia. Although the diagnosis of giant-cell sarcoma was made by a reliable pathologist, in this case the disease was undoubtedly fibrous osteitis.

Clinically I believe that we must recognize two forms of fibrous osteitis, a diffuse and a localized. Cases are not uncommon in which the disease affects the metaphysis of one of the long bones and remains localized, the general health of the patient remaining good even after symptoms have been noted for a number of years. There are other cases, such as that cited above observed by Rehn, in which a number of bones are successively involved and the patient eventually dies in a cachectic state after the disease has progressed slowly for a number of years.

X-ray Diagnosis.—In most instances an accurate pre-operative diagnosis can be made from the X-ray findings. Occasionally there will be some difficulty in differentiating between fibrous osteitis and central giant-cell sarcoma. Bloodgood believes that there may be some relationship between the two. He states that from gross and microscopic studies of bone cysts, osteitis fibrosa and central giant-cell tumor, he is forced to the conclusion that there may be some relationship between these pathological processes. Very frequently there are found in fibrous osteitis currant-jelly areas which cannot be differentiated from the giant-cell tumor, and in central giant-cell sarcomas there are often found white areas which are histologically identical with osteitis fibrosa.

In fibrous osteitis the shadow is usually in the metaphysis and extends well down into the shaft, being fusiform in shape. Usually the bone has undergone a symmetrical expansion, until there remains nothing but a layer of cortical bone of egg-shell thinness. There is no extension of the process of the surrounding tissues, even when the thinned cortical bone has been fractured, and the epiphyseal cartilage limits the process from extending into the epiphysis. Giant-cell sarcoma, when occurring in the metaphysis, does not extend so far into

the shaft as does fibrous osteitis and tends to form a spherical rather than a fusiform swelling. While in central giant-cell sarcoma the expansion tends to be asymmetrical, there are cases in which it is as symmetrical as in fibrous osteitis. Rupture through the thinned cortical bone and extension through the epiphyseal cartilage are indicative of a giant-cell sarcoma. Bone abscesses, tuberculosis and syphilis of bone offer few difficulties in diagnosis and can usually be readily differentiated from the lesion under discussion.

Treatment.—Fibrous osteitis is a benign disease, probably inflammatory in character. A pathological fracture may institute reparative processes which end in cure. In cases of fibrous osteitis, when pathological fracture occurs, the fracture should be reduced and a proper dressing applied to maintain the fragments in apposition. Operative interference should be postponed until the fracture has had a chance to unite, because a cure may result during the process of repair.

Removal of the fibrous tissue or the contents of a cyst by curettage, followed by the introduction of a bone plug, Mosetig-Moorhoff or bismuth, will cure most of these cases. Transplantation of bone into the cavity is probably the best procedure. If marked deformity has resulted or the cortex has been greatly thinned so that there is little or no hope of repair, resection of the diseased portion of the shaft, followed by transplantation of bone, is indicated.

In the localized form of the disease, the trauma associated with fracture or almost any type of operation, will institute reparative processes ending in cure. When the disease attacks many bones it is apt to be progressive, and while bone repair may occur at the site of the different lesions when operative interference is instituted, the general health of the patient gradually deteriorates and death from cachexia occurs many years after the first symptoms appear.

DISEASES OF THE JOINTS

Acute serous arthritis is not very common in the upper extremity. Any or all of the larger joints may be involved in acute articular rheumatism. A serous inflammation of the wrist- and elbow-joints is common in gonorrhœa and may appear as a part of the clinical picture of arthritis deformans. It is not uncommon to find an acute serous arthritis associated with an osteomyelitic focus. A pyogenic focus in the lower end of the humerus, or in the upper end of the ulna or radius, may be associated with a serous inflammation of the elbow joints.

Traumatic Arthritis.—Any joint when sprained or dislocated may become acutely inflamed. This traumatic form of arthritis usually rapidly subsides and the serous exudate, which followed extravasation of blood into the joint, soon disappears. The traumatic cases present the usual symptoms associated with acute arthritis, the objective findings naturally varying somewhat with the joint involved.

Acute suppurative arthritis follows trauma in which infection has been carried into the joint through some wound. Compound dislocations, gunshot and stab wounds, are common causes. Suppurative arthritis also occurs as a metastatic process in scarlet and typhoid fever, small-pox and pyemia. The shoulder-joint is relatively frequently involved in the suppurative arthritis occurring in scarlet fever. The metapneumonic forms of arthritis have already been cursorily mentioned in discussing streptococcic and pneumococcic osteomyelitis. During the course of pneumonia, or after the crisis, a suppurative arthritis may develop in one or more joints. This form of arthritis is usually suppurative in character and has been thought by some to be secondary to a bone focus, so situated that the inflammatory process extended rapidly through the cortical bone from which it passed beneath the capsule into the joint. The rapidity with which these metapneumonic processes in joints repair after simple incision, or even after aspiration, seems to preclude any possibility of bone infection in most cases of arthritis of this type.

Acute suppurative arthritis associated with severe pain, high fever, swelling of the articular and paraarticular tissues and impairment or loss of function of the affected joint. When the inflammatory process perforates the capsule there may be some improvement in the symptoms, but a subcutaneous phlegmon then develops, the skin becoming red, œdematous and fluctuating.

Acute suppurative arthritis, in all instances, is serious, both as to the life of the patient and the function of the joint. The treatment consists of incision into the joint to provide for escape of the pus and the establishment of drainage. During the treatment, the joint should be immobilized in the position which will be most useful in case anchylosis should occur. Failure to prevent contracture often results in malposition of the limb leading to partial or complete loss of function.

Gonorrhœal Arthritis.—Arthritis may develop at any time during the course of a gonorrhœal infection, recent or old. It is metastatic in character and since improved cultural methods have been introduced the gonococcus is now frequently isolated from the joint fluid. Irons

states that the proportion of cases in which the gonococcus can be obtained in cultures from the joint fluid is variously estimated from 30 to 70 per cent. The acute cases give the greater proportion of positive results and cultural methods often succeed where microscopic examination has failed to reveal the organism in the joint fluid.

While this form of arthritis may occur in any joint, the larger ones are most commonly affected. The joints are affected in the following order of frequency as indicated by statistics based upon 695 cases:

Knee	258	Temporo-maxillary	16
Ankle	125	Small joints of foot	46
Wrist	76	Heel and toes	21
Elbow	33	Small joints of hands	50
Shoulder	44	Other articulations	24
Hip	42		

The arthritis usually develops within two or three weeks of the gonorrhœal infection. At one time it was supposed that arthritic manifestations occurred when the inflammatory process extended to the posterior and prostatic parts of the urethra, but it is now generally believed that the arthritis occurs when the organisms extend to the deeper layers of the mucous membrane from which they gain access to the general circulation through the lymphatic and blood-vessels.

Local traumatism of the mucous membrane, either by the use of strong antiseptic solutions or by instruments, favors the entrance of the bacteria into the circulation. Changes in the genitalia occurring in pregnancy and the trauma sustained during labor favor the development of metastatic joint infection in women. The so-called articular rheumatism occurring in pregnancy differs from ordinary articular rheumatism in a number of ways, especially in the frequency with which the joints become anchylosed. This type of rheumatism is in most instances gonorrhœal in origin. Trauma seems to play a part in determining which joint is affected. A number of instances might be cited in which a joint has been slightly injured or over-worked just before the acute inflammatory symptoms developed. The fact that the joints of the lower extremity are more exposed to slight injuries, often over-looked, may account for the frequency with which gonorrhœal arthritis is observed in the knee and ankle. It is peculiar that the wrist-joint is so frequently affected in women. In half of the cases observed by Nasse in women, the radiocarpal and carpal joints were involved. No satisfactory explanation can be given for this frequent involvement of the wrist in women.

The clinical picture of gonorrhœal arthritis is well known and quite characteristic. In the ordinary cases there develops, within a few days after the initial urethritis or the recurrence of an old urethral infection, pain, tenderness and swelling of the joint. While the symptoms may be pronounced in one joint, for example the wrist, careful history taking will often reveal some pain, tenderness or swelling in some of the other joints. Contrary to the general belief, gonorrhœal arthritis is nearly always polyarticular, although the changes occurring in some of the joints may not be very painful.

The general symptoms vary in the different cases. One patient may be slightly indisposed, with a temperature of 99° to 100°F., while another may present all the symptoms associated with a severe sepsis, such as high fever, dry tongue, etc. Usually these symptoms subside in a few days, and the constitutional symptoms are not always directly proportional to the degree of joint involvement.

The changes in the joint vary. In some cases there may be no gross changes, pain in the joint being the only indication of any involvement. Usually the joint becomes swollen and painful and serofibrinous exudate is poured into it. There is limitation of motion and the joint assumes the position which permits of the greatest accumulation of fluid. Occasionally severe suppurative arthritis develops during gonorrhœa. This is usually due to staphylococci which have gained access to the general circulation through the diseased mucous membrane. Some of the most painful and serious forms are those in which there is little or no exudate but considerable capsular and periarticular involvement.

Instead of developing acutely, gonorrhœal arthritis may come on subacutely. After an acute onset the swelling may persist, the exudate not being absorbed, and in these cases we have a chronic hydrops. In the joints of the upper extremity the shoulder is most frequently the seat of a chronic hydrops.

Treatment—Prophylaxis.—The mucous membrane infected with the gonococcus should not be traumatized during treatment and conditions should be provided which favor the limitation of the inflammatory process.

After arthritis has developed the joint should be immobilized by a dressing, in such a position as to insure the best possible function should anchylosis develop.

The most efficient treatment in any case of gonorrhœal arthritis, acute or chronic, is the injection of formalin, 2 per cent., glycerin, 98

per cent., into the diseased joint. I have seen cases of acute serous arthritis cured by one injection. In the chronic cases, even the dry serous forms, formalin and glycerin injected into the joints give good results.[1] If the symptoms do not subside after the first injection, a second and third injection may be required. An ounce of the solution can usually be easily injected into the elbow or wrist.

In chronic cases associated with considerable pain, and in chronic hydrops, vaccine therapy is of distinct value. This may be combined with the intra-articular injection of 2 per cent. formalin in glycerin. Immobilization should be maintained during the treatment.

In the suppurative forms the joint should be incised and drainage established, as in any other form of suppurative arthritis.

During the acute stage traction is of decided value as it separates the opposed joint surfaces and relieves the pain to a great extent.

Tuberculous Arthritis.—The joints of the upper extremity are not as frequently the seat of tuberculosis as are the hip and knee. The elbow-joint is more frequently affected than are the shoulder- and wrist-joints. The statistics from Garrè's clinic, recently published by Lenhard, deal with 145 cases of tuberculosis of the joints of the upper extremity, which were treated during the past 19 years. The joints of the upper extremity were involved in the following order of frequency:

Elbow-joint	79 times	51.0 per cent.
Wrist-joint	41 times	28.2 per cent.
Shoulder-joint	25 times	17.2 per cent.

Tuberculous arthritis in most instances is secondary to a focus in the epiphysis of one or more of the bones entering into the formation of the joint. König claimed, some years ago, that most of the cases of tuberculosis of the shoulder-joint are primarily osteal, the focus being situated most frequently in the upper epiphysis of the humerus. According to his observation about 75 per cent. of the cases were primarily osteal, about 25 per cent. primarily synovial. The X-ray findings in tuberculous arthritis have confirmed these early observations of König. A general miliary tuberculosis of the synovial membrane, without a primary focus in the epiphysis, is extremely rare. An appearance simulating this is not infrequent and at the time of operation it may be impossible to say whether one is dealing with a synovitis secondary to a bone lesion or with a primary tuberculous synovitis, but in nearly all cases where the joint can be examined

[1] Formalin-glycerin solution ought not to be injected unless it has been prepared not less than 24 hours (J. F. B.).

post-mortem or after amputation, a primary focus in the epiphysis will be seen to be the primary cause of the infection.

The X-ray does not reveal the primary bone focus in all cases, for the tuberculous process may have extended to the synovial membrane, causing extensive changes in the same, before the bony trabeculæ have softened enough to render differentiation of the bone focus possible. In advanced cases of tuberculous arthritis the bone will probably be diseased, but it is impossible to determine by X-ray examination whether the bone has been primarily or secondarily involved.

The changes in the synovial membrane which occur after the tuberculous process extends from the bone, consist of the development of a tuberculous granulation tissue, the pouring out of an exudate and a reactive inflammation on the part of the capsule and surrounding tissues, which tends to encapsulate the tuberculous tissue and renders spontaneous healing possible. The tuberculous granulation tissue extends from the attachment of the synovial membrane over and beneath the articular cartilages, which become softened, fibrillated and raised from the underlying bone. In the shoulder-joint the tuberculous process may extend to the marrow which becomes transformed into a soft, fleshy mass. The name of caries carnosa has been applied to this form of tuberculosis, which has already been discussed under the secondary forms of tuberculous osteomyelitis.

The newly formed tuberculous granulation tissue may cicatrize, in which case there is little or no exudate, and the thickened capsule becomes shrunken. The tuberculous granulation tissue in the joint may increase in amount, the exudate being absorbed and the typical fungus then forms. If caseation occurs, the synovial membrane is covered by a soft spongy tissue and the paraarticular tissues become œdematous. If the softened and caseated mass ruptures into the joint cavity, a suppurative form of tuberculous arthritis develops. If such abscesses rupture through the capsule sinuses remain after they are opened or discharge spontaneously and lead down to the diseased focus. These cold abscesses are more often secondary to the bone focus than to the rupture of a softened, ceaseated focus. In tuberculosis of joints the first stage may be a hydrops, this is followed by the formation of tuberculous granulation tissue, which may caseate and give rise to the suppurative forms of the disease.

Formation of Rice Bodies.—There are found in tuberculous joints quite frequently, especially in the serous and dry forms, small, spheroidal, opaque masses, called rice bodies. These small bodies, which are quite characteristic of tuberculous disease, may be present

in large numbers. There has been considerable difference of opinion as to their origin. König believed that the pedunculated and free rice bodies developed from fibrinous deposits, while Garrè and Goldman believed that they were formed from degenerated parts of the diseased synovial membrane. They are in all probability formed of the fibrin precipitate from the serous exudate and their form is probably dependent upon joint motion. The origin of rice bodies and the effect which motion has upon the determination of their shape will be mentioned again in discussing tuberculosis of the ulnar bursa.

Caries sicca is the most common form of tuberculosis of the shoulder-joint. In caries sicca a thin layer of tuberculous granulation tissue develops without any exudation; this gradually extends from the attachment of the synovial membrane of the articular cartilages. These cartilages are gradually destroyed, and the process then extends to the bone, which undergoes caries. Cicatrization ensues and the thickened capsule gradually shrinks, while the bone and cartilage is destroyed. In caries sicca there is a decided tendency to spontaneous cure. An entire epiphysis may be destroyed and tuberculous granulation tissue transformed into a cicatricial mass.

Etiology.—In discussing etiology, the joints of the upper extremity, will be considered together, and the statistics from Garrè's clinic, which have recently been compiled and published by Leonard, will be given in considerable detail. As previously mentioned, these statistics are based upon the study of 145 cases of tuberculosis of the shoulder-, elbow- and wrist-joints.

Tuberculosis of the shoulder-joint was observed 25 times. The disease occurred 18 times in men and seven times in women. The average age at which the patients visited the clinic was 27.3 years, but the beginning of the disease was much earlier, the majority of the cases developing between the tenth and twentieth years. The disease occurred more frequently in the right than left shoulder (69 per cent. to 31 per cent.). The relationship of trauma, which apparently determines the frequency of right shoulder involvement, will be discussed later.

Tuberculosis of the elbow-joint was observed 79 times. Fifty of the patients were of the male sex, 29 of the female. The average age of the patients was 22.3 years. The primary focus, as determined by X-ray findings and at operation, was situated in the lower epiphysis of the humerus in 8.6 per cent. of the cases; the entire joint was involved, it being impossible to determine the exact site of the focus in 60.3 per cent.; in the upper radioulnar joint in 5 per cent.; in the proximal end of the ulna in 20.7 per cent., and in the proximal end of the radius in 9

per cent. Involvement of the synovial membrane alone was found in but two cases.

Tuberculosis of the wrist-joint was observed 40 times, occurring in men 22 times and in women 18. The average age at which the patient appeared at the hospital for treatment was 31.4 years. The disease in most cases had persisted for some time, dating back to the first or second decennium.

The following table indicates the location of the primary focus:

Radio-carpal joint	8 times
Lower radio-ulnar joint	6 times
Carpo-metacarpal joint	8 times
Carpus	12 times
Lower epiphysis of radius	3 times
Lower epiphysis of ulna	1 time
Tuberculosis of tendon sheaths	2 times

The right wrist was affected 27 times, the left 13.

The frequent involvement of the joints of the right upper extremity suggests that trauma plays an etiologic rôle in tuberculosis of joints. In some cases the effect and character of the trauma is over-estimated by the patient, while in other instances the trauma may have been so slight as not to attract the attention of the patient. The changes induced by the trauma undoubtedly provide conditions which favor the deposition and growth of the organism. As pointed out years ago by König, the trauma which favors the development of tuberculosis of bones and joints is always slight. If the trauma is severe, the local resistance, associated with the reparative process, is increased so much that the tubercle bacillus is unable to develop.

Symptoms and Clinical Course of Tuberculous Arthritis.—There are certain symptoms common to tuberculosis of joints, such as pain, localized tenderness, limitation of motion, swelling, muscular rigidity and atrophy. The symptoms, however, vary in different joints and different cases, depending upon the location of the primary focus, the extent and character of the disease (whether a hydrops or of the granulating or suppurative type), upon the structure of the joint (whether simple or complicated), and upon the general resistance of the patient. High resistance favors the spontaneous healing of the disease, the involved tissue cicatrizing, so that the joint becomes atrophic and anchylosed.

Tuberculosis of the shoulder-joint usually begins insidiously and is very chronic. The tuberculous hydrops and the suppurative form of tuberculosis are seen but rarely in the shoulder. Hydrops may occur

early as the preliminary stage of a fungus tuberculosis, but when the patient comes under observation the joint is usually distended with tuberculous granulation tissue, the paraarticular tissues are infiltrated and doughy and the over-lying skin has the white, glossy appearance characteristic of tumor albus.

The symptoms associated with caries sicca are quite typical; the shoulder becomes flattened, the deltoid atrophies, and the acromion and coracoid processes become more prominent as the head of the humerus is partially destroyed. The joint becomes fixed early in the disease, and the fixation is marked enough to suggest anchylosis. These changes are often accompanied by severe neuralgia-like pains which radiate down the arm. Caries sicca is characterized by a long clinical course, there being a marked tendency for the newly formed tissue to cicatrize and undergo spontaneous healing.

Tuberculosis of the Elbow-joint.—Tuberculosis of the elbow-joint is characterized by swelling and limitation of motion. The swelling is usually first noticed posteriorly between the head of the radius and the lateral border of the olecranon. If this is due to hydrops fluctuation may be elicited. If tuberculous granulation tissue fills the joint, the swelling may have a doughy feel. Swelling may also be noted in the olecranon fossa on both sides of the triceps tendon, and in the groove for the ulnar nerve, posterior to the internal condyle.

The elbow-joint being superficial assumes a characteristic spindle-shape as the tuberculous granulation tissue fills the joint and the paraarticular tissues become infiltrated. The spindle-shape of the tuberculous elbow is accentuated by the marked atrophy of the muscles above and below (Fig. 237). If the tuberculous granulation tissue softens, cold abscesses form and after these are opened or discharge spontaneously sinuses remain leading down to the diseased joint.

Limitation of Motion.—Loss of full power of extension is usually first noted. Full flexion of the arm may be made with difficulty. The forearm gradually becomes partially flexed, so that it forms an obtuse angle with the arm, which is an undesirable position. If the primary focus is in or about the lower end of the humerus, or in the olecranon, supination and pronation may be unaffected. If the tuberculous process involves the capitellum, the head of the radius, or the part of the ulna bordering upon the lesser sigmoid cavity, there will be partial or complete loss of pronation and supination.

The amount of pain and fever is variable. The size and form of the swelling depends upon whether the process is a tuberculous hydrops, a

fungous tuberculosis, or a cicatrizing form, such as is seen in the shoulder-joint in caries sicca.

Tuberculosis of the Wrist-joint.—The clinical picture of tuberculosis of the wrist varies. The wrist-joint is complicated and contains a

FIG. 237.—(*Dean Lewis.*)

number of synovial cavities which communicate with each other. The process may easily extend from the wrist to the adjacent tendon sheaths, thus complicating the clinical picture. When the joint becomes tuberculous there is always more or less swelling, combined with limitation of motion, pain upon pressure and motion and changes

in the position which the hand occupies in relation to the forearm. Normally the hand occupies a position of slight ulnar flexion, but in tuberculosis of the wrist this may be lost, the hand being in the axis of the forearm, or there may be a slight dorsal subluxation (Fig. 238). The position of the hand depends a good deal upon the amount of destruction occurring in the carpal bones.

If the adjacent tendon sheaths are involved, the characteristic swelling associated with inflammatory processes in them will be noted. If the tuberculous granulation tissue has caseated, sinuses may be present which lead down to the diseased carpal bones. The cases in which the tuberculous process extends to the wrist from the lower end of the radius differ, as far as prognosis is concerned, from those in which the infection extends from the metacarpal or carpal bones, or is primary in the synovial membrane. When the disease extends from the radius there is often found a wedge-shaped infarct in the bone, associated with

Fig. 238.—Tuberculosis of the wrist-joint. (*De Quervain.*)

a progressive infiltrating tuberculosis of the shaft; the tuberculosis of the wrist is here of secondary importance, as the infiltrating tuberculosis of the shaft becomes the important part of the clinical picture. Tuberculosis extending to the wrist from the metacarpal bone is apt to be localized and can be easily controlled by conservative procedures.

Diagnosis.—One experienced in the diagnosis of surgical lesions has but little difficulty in recognizing tuberculous arthritis. The insidious onset and slowly developing symptoms, consisting of pain and fixation of the joint, are characteristic. Caries sicca may be mistaken for rheumatism, a joint neurosis, or a painful joint resulting from traumatism if an injury has been sustained shortly before the beginning of symptoms. X-ray examination in such cases should enable one to make a positive diagnosis, for the bone destruction and atrophy with little or no reaction on the part of the surrounding tissues characterize this condition.

Fungous tuberculosis of the shoulder might be confused with a

malignant tumor developing from the articular ends of the bone, but an X-ray examination and carefully taken history will usually enable one to differentiate between the two.

Gonorrhœal arthritis, acute osteomyelitis, arthritis deformans and traumatic arthritis will at times have to be considered in the differential diagnosis.

Gonorrhœal arthritis and articular rheumatism usually develop acutely and both are polyarticular. In gonorrhœal arthritis the joint first affected improves but little, while other joints are exhibiting symptoms and careful examination will reveal the primary infection. The acute onset with rapid involvement of joints are sufficiently characteristic to permit of an accurate differential diagnosis.

Acute osteomyelitis is usually recognized, as the pain and tenderness is confined to the bone above the joint line. Arthritis deformans as a rule is easily recognized by X-ray examination, for bone atrophy is usually accompanied by marked reactive changes leading to the formation of marginal osteophytes. In tuberculosis there is but little reaction on the part of the healthy bone immediately adjacent to the diseased focus.

The X-ray examination is the final resort in doubtful cases and correct diagnosis can usually be made upon these findings alone.

Treatment.—The indications for treatment vary, depending upon the age of the patient, the form of the tuberculosis, the general condition of the patient, and upon the results which have been obtained by the procedures previously employed.

In all cases considerable attention should be paid to the general treatment and favorable hygienic conditions be provided. The patient should sleep out-of-doors, or provided with a window tent so that plenty of fresh air can be had at all times. The general sun bath has proven to be very valuable. At first the diseased part is exposed to the sun's rays throughout the day and finally the whole body may be exposed. As a result of the exposure to the sun the general condition improves, the muscle tone increases, the skin becomes brown, the cutaneous circulation is improved, discharging sinuses dry up and the exuberant tuberculous granulation tissue decreases in amount. The improvement which has followed the sun-bath treatment is encouraging.

Forced feeding should be attempted, providing there are no contraindications. Milk and cream, eggs and butter should be given regularly.

Tuberculin in 1/1000 mg. doses may be a helpful therapeutic

measure. The effects of its administration must be carefully watched and if there is a marked reaction it should be stopped.

Tuberculosis in children tends to become localized and to undergo spontaneous cure. Conservative treatment, therefore, is generally indicated in the treatment of tuberculous arthritis in children. The treatment consists of immobilization of the joint involved, the injection of 10 per cent. iodoform in glycerin, curettage of sinuses and the removal of necrotic or soft tissue. It has been my experience that iodoform-glycerin emulsion is helpful in the treatment of tuberculous hydrops, but when a fungus or suppurative type of tuberculosis develops it has little or no therapeutic value.

In adults less is to be expected from the conservative treatment than in children and more radical treatment is indicated, as there is less tendency for tuberculous arthritis to remain localized and to cure spontaneously.

No definite rules as to treatment can be laid down. Each case must be treated according to the local findings and the general condition of the patient. The paper recently published from Garrè's clinic summarizes so well an experience extending over 19 years that I will quote extensively from it.

During the past 19 years Garrè has treated 25 cases of tuberculosis of the shoulder-joint. Most of these were injected with iodoform-glycerin emulsion. Usually the joint remained stiff. In one case in which there was complete absorption of the epiphysis the motion remained good.

The severe cases, those with sequestra, the suppurative and painful forms, were operated upon. Twelve resections were performed and the late results were much better than anticipated. About one-third power of the arm and about two-thirds of the motion, were lost, but the patients were able to carry on the work demanded of them as maids, farm hands, tinsmiths, etc. In view of these favorable results Garrè believes that in the future the indications for joint resection will be increased. In the treatment of tuberculosis of the shoulder in early childhood (during the first decennium) he favors the conservative method.

Garrè treated 79 cases of tuberculosis of the elbow-joint. In children, after one or two years' treatment with iodoform-glycerin injections and fixation, very satisfactory results were obtained. In adults with the fungous, suppurative and painful forms of the disease and when sinuses are present, resection of the joint is indicated.

The conservative treatment even in mild cases in adults is not satisfactory, for the late results show that while most are improved, only a few are cured and in these there is distinct limitation of motion.

The functional results after resection were not all that could be desired, for about one-half of the joints were anchylosed, but the patient did not wish a second operation, in which an attempt would be made to mobilize the joint.

It is doubtful whether an attempt should be made to secure a movable joint in doing a resection of a tuberculous elbow by the interposition of a plug of soft tissues, as has been practised by Helferich. Partial or complete anchylosis may favor thorough healing of the tuberculous process.

Garrè does not practise typical resection of the wrist-joint. Removal of both rows of carpal bone leaves a hand which is practically functionless. In the suppurative forms and in those cases in which tuberculous sequestra occur in the radius and ulna some operation must be employed. The diseased part should be exposed by incision and the dead bone or granulating mass should be removed with gouge or curette. If the process has extended to adjacent tendon sheaths these should be opened.

Iodoform-glycerin emulsion may be applied to the diseased joint to advantage. Conservative treatment should be continued after such an operation. The wrist-joint should be dressed in partial extension with the fingers somewhat flexed. This position may be easily obtained by permitting the hand to rest on a small roller bandage placed on an anterior splint.

Typical resections of joints are not attempted as much as formerly. The Langenbeck incision gives the best exposure in resection of the shoulder-joint, and the Ollier bayonet incision, or the Kocker j-shaped incision the best for resection of the elbow. The reader is referred to Burghard's System of Operative Surgery, or to Binnie's Operative Surgery for a discussion of the details of the resection of joints.

Syphilitic Arthritis.—*Congenital.*—Not infrequently an exudative arthritis, accompanied by but few symptoms, develops in children having congenital syphilis. A number of joints may be affected simultaneously or in rapid succession. The arthritis is generally secondary to syphilitic osteochondritis, which has already been considered in the section dealing with syphilis of bone. Of the joints of the upper extremity the elbow is most frequently affected, but an arthritis of the shoulder-joint associated with syphilitic osteochondritis, which may cause a separation of the epiphysis, is not uncommon. Syphilitic pseudo-paralysis of the upper extremity may be due to such lesion, but in most of these cases the impairment of function is due to syphilitic involvement of the muscle in direct relation to the diseased joint.

In syphilis involving the epiphyseal zone of the lower end of the humerus, soft granulation tissue develops which may lead to epiphyseal separation. The bone enlarges and suppuration may occur. If the pus breaks through the articular cartilage a suppurative arthritis develops. It may be difficult to differentiate between this form of syphilitic arthritis and tuberculous arthritis if the manifestations of congenital syphilis are absent or not marked.

Joint involvement may occur in the early stages of syphilis, accompanying or even somewhat preceding, the secondary symptoms. The joints become exceedingly painful and hydrops develops. As a number of joints may become involved, the disease somewhat resembles acute articular rheumatism. The differential diagnosis is difficult if the primary lesion has been concealed and the secondary symptoms have not developed or are not pronounced. When an operation has been performed in acute gummatous arthritis because of an error in diagnosis, histological examination has revealed miliary gummata in the tissue removed.

The joint changes observed in the late stages of syphilis are gummatous in character. The arthritis is either primary or is secondary to a periosteal or osteal gumma in the articular end of one of the bones. Of the joints of the upper extremity, the wrist is probably most frequently involved in this gummatous form of arthritis.

The synovial membrane becomes thickened and covered with villous and tumor-like masses. Infiltration of the capsule leads to contraction of the same and the articular cartilages become eroded. Usually the changes are more marked in the center than at the edges of the cartilage. As the erosions in the cartilage repair, small radiating scars are formed which resemble syphilitic scars developing in other tissues.

Gummata in the joint are usually accompanied by hydrops. The joint becomes swollen and as the articular cartilages are diseased, a distinct crepitus is felt upon palpation. Usually the subjective symptoms are relatively slight, while the objective findings indicate considerable joint change.

The diagnosis may be difficult as there is nothing especially distinctive about syphilitic arthritis. Multiple involvement and relatively few symptoms are suggestive of a syphilitic infection. The previous history is of prime importance. A Wassermann test is of great value in doubtful cases. The X-ray aids in the diagnosis, especially when there has been a primary gummatous periostitis or osteitis.

Most of these cases improve rapidly when antisyphilitic therapy is instituted. When there is hydrops, the joint should be aspirated and immobilized. In secondary arthritis an operation may be required if there are sequestra, and in suppurative cases, which are rare, incision of the joint to provide for the escape of pus, is indicated.

Arthritis Deformans.—Arthritis deformans is a progressive, non-suppurative disease of joints, characterized by pain, swelling and impairment of function. Eventually deformities develop and the affected joints become ankylosed. A number of different forms of the disease are recognized, the classification being based partly upon supposed etiological and partly upon certain clinical differences.

Etiology.—Definite changes exactly similar to those found in spontaneous arthritis deformans may occur in a joint after a trauma. The same changes may be met in syphilitic and tuberculous arthritis and after different forms of joint infections. But the more prominent the changes associated with arthritis deformans become, the less the clinical and pathological significance of the primary cause. The joint changes following trauma and the above-mentioned infections will not be dis-

cussed. We will consider only the spontaneous arthritis deformans, which is a distinct clinical entity.

Much the same pathological changes in the joints are observed in arthritis deformans and in the destructive lesions occurring in tabes, general paresis and syringomyelia. Because of this it has been suggested that arthritis deformans might be secondary to some disease of the spinal cord or peripheral nerves. Careful histological examination of the nervous system in cases of arthritis deformans fails to reveal any changes, comparable to those in tabes or syringomyelia, which would account for the destructive lesions in the joint or the trophic disturbances in the skin and its appendages, which are not uncommon in arthritis deformans.

Wollenberg has suggested that the changes are due to a local disproportion between arterial inflow and venous outflow, the lessened arterial inflow causing atrophic changes, the decreased venous outflow in hypertrophic ones. Atrophy and hypertrophy are practically always combined in arthritis deformans. Axhausen criticises some of the experimental work upon which Wollenberg's theory is based, but believes that localized anæmic necrosis in the articular ends of bones, due to arterial changes, the important factor in arthritis deformans. The living bone surrounding the areas which have undergone anæmic necrosis proliferate, giving rise to marginal osteophytes and eburnated bone. Thick-walled and diseased vessels have been found in the bones in cases of arthritis and interference with blood supply may be an important factor in causing the bone changes, but this is probably secondary.

Recent work by Billings, Rosenow, Davis and Jackson, has thrown considerable light upon the etiology of arthritis deformans. It seems likely that some latent infection, *e.g.*, in the tonsil, prostate, appendix gall-bladder, teeth, etc., may be the source of the toxin or of the general bacterial invasions which cause the changes in the articular cartilages, bone and synovial membrane.

Bacteriological studies by these observers of tissues removed, *e.g.*, tonsils, in cases of arthritis deformans, have yielded some very striking results. The dominant organism found in the abscesses and sealed crypts of the faucial tonsil are the streptococcus viridans and the streptococcus hemolyticus. By experimental inoculation of rabbits with this strain of streptococcus, Davis and Jackson have produced nonsuppurative, combined proliferative and degenerative joint lesions, quite similar to those observed in spontaneous arthritis deformans as observed in man. That there may be a diversity of etiological factors is indicated by the following statement made by Nichols: "In consideration of the very great lack of definite knowledge as to the origin of these joint troubles, it is desirable in many cases of non-tuberculous joint disease to be able to recognize the pathologic condition which is

present and leave the question of clinical differentiation into diseases alone. This is true for the following reasons; first, that any given cause may produce in the same patient any one or all of the five different anatomic types of chronic joint disease, and, second, any one or all of the five anatomic classes can be produced by any one of a great variety of irritants."

Pathology.—Five anatomic forms of chronic arthritis are described by Nichols: the serous, ulcerative, ankylosing, formative and fungous. Usually two or more of these types are combined and all of the forms may occur in a single joint some time during the course of the disease.

FIG. 239.—X-ray wrist. Arthritis deformans, new bone formation and anterior displacement of the wrist.

Proliferative and degenerative changes are usually combined in arthritis deformans. The articular cartilages become softened, fibrillated and ulcerated where exposed to the greatest pressure. The bones directly exposed by ulceration of the cartilages become smoothed off and polished by friction of the opposed surfaces where they come into contact (Fig. 239). Osteophytes develop at the margins of the articular surface. Enchondroses form first and later these become converted into osteoid tissue. These osteophytes are usually attached by a small pedicle which may be broken off, thus free bodies (floating cartilages) are formed. In some instances hundreds of free bodies may be found in the diseased joint. Free bodies also are formed by the detachment of calcified villous-like masses, which develop upon the synovial membrane in certain forms of chronic arthritis. Atrophy, combined with the formation of marginal osteophytes, gives rise to the peculiar

knobbed and knotty appearance of the interphalangeal joints, known as Heberdens' nodes. The capsule of the joint usually becomes thickened and contracted, limiting markedly the motion of the affected joint. Some of these cases were formerly classified as chronic articular rheumatism, which, according to Tillmanns is characterized by pathological changes which resemble more or less those of arthritis deformans, except that in the latter disease there is an increased growth of cartilage, while in chronic articular rheumatism the cartilage is replaced by vascular connective tissue. It is best to consider chronic articular rheumatism a form of chronic arthritis.

According to Billings, arthritis deformans is an infectious clinical entity, manifesting chronic periarthritis, synovitis, proliferative and degenerative osteoarthritis and chronic myositis with contraction of muscles and perineuritis or neuritis. Usually coincident, but secondary malnutrition and faulty metabolism aggravate the condition of the patient. The source of the infection is usually focal and located in the mouth, faucial tonsils or sinuses. Occasionally the focus may be in the prostate gland, seminal vesicles, the female genitalia and probably also in a streptococcic chronic appendicitis or cholecystitis, or a circumscribed streptococcic infection anywhere. The morbid anatomy of experimental chronic arthritis is the same as that found in man and is the specific reaction to the causative organism. Arthritis deformans may be differentiated from other types of chronic arthritis by the characteristic coincident involvement of periarticular and articular structures, chronic myositis with consequent muscular contractions and secondary trophic changes due to faulty metabolism, malnutrition, etc.

Symptoms.—Arthritis deformans may be monarticular or polyarticular. Usually the disease begins in middle life, but it is observed in children and young adults. It is more common in men than women. The large joints of the lower extremity are most commonly affected, but next in order of frequency come the elbow-, wrist- and shoulder-joint.

Usually the disease comes on insidiously. The joint affected is painful and there is limitation of motion. Crepitus may be elicited when the joint is manipulated and there may be some increase in the size of the joint if a serous exudate has been poured out, or the hypertrophic changes are marked. In arthritis deformans of the shoulder-joint the enlarged head of the humerus may rub against the acromion, the former becoming flattened and smoothed off where they come into contact (Fig. 240). The supraspinatus tendon also occasionally wears

through the capsule of the joint so that eventually the cavity of the shoulder-joint communicates freely with the subacromial bursa. Pain and fixation develop in the elbow-joint when involved, interference with motion developing early, because of changes in the head of the radius. Free bodies in large numbers are frequently found in the elbow-joint. The knee is the only joint which is more frequently the seat of free-body formation.

The interphalangeal joints are frequently knotted and knobbed and distortion of the hands to the ulnar side is common (Fig. 241). The enlargements occurring at the interphalangeal joints are called Heberden's nodes. The ulnar flexion of the hand with flexion of the fingers,

FIG. 240.—Early changes of arthritis deformans in shoulder. Distinct lipping with beginning formation of osteophytes are seen upon the lower part of glenoid fossa and head of humerus. (*Billings.*)

although occasionally the latter may be extended, is so characteristic that there is no difficulty in making a diagnosis.

In cases with an acute onset there may be considerable difficulty in differentiating arthritis deformans from acute articular rheumatism, this being especially true in the polyarticular forms. The disease is usually progressive, but there may be long periods during which there is more or less complete cessation of symptoms, although joint function is permanently impaired to some extent.

A chronic myositis, which is more or less selective, is common in arthritis deformans. The muscle of the upper extremity most commonly affected is the biceps humeri. This is a chronic, slightly painful, myositis which causes shortening of the muscle fibers. Most of the

patients give evidence of a neuritis or perineuritis, this being indicated by the trophic changes in the skin and its appendages.

The diagnosis can usually be readily made, although the acute cases, both monarticular and polyarticular, may offer some difficulties. The X-ray findings are usually quite typical. In the mildest cases the width of the joint space will be reduced and the articular ends of the bones become somewhat angular. In advanced cases marginal osteophytes, reduction in the width of the joint line, bone atrophy, with a rounding off and irregularities of the articular ends are characteristic enough to warrant a positive diagnosis.

FIG. 241.—Arthritis deformans showing typical changes about the joints. (*Billings.*)

Treatment.—The following plan has been followed by Billings in the treatment of arthritis deformans:

1. All possible sources of focal infection must be removed. Tonsillectomy; oral surgery for alveolar abscesses and sinusitis; vasectomy to drain and to use the vas deferens to wash out infected seminal vesicles and to drain the prostate gland; and any other measure necessary to remove all possible streptococcic foci of infection have been utilized.

2. The patient's immunity to the infecting organism should be improved by absolute rest for an indefinite period. This may consist in absolute or partial recumbency, dependent upon the individual and the character of the disease. (*b*) Improvement of the general and individual hygiene. The patient needs good air, sunshine, good wholesome food with plenty of proteins to replace wasted tissues,

restorative tonics when required, plenty of fluid drinks and the necessary laxatives. Fatigue must be avoided. A cheerful environment and constant moral support are essential to all these patients who are despondent because of long suffering. (*c*) Autogenous vaccination with the strains of streptococci isolated in each patient.

Under this line of treatment recovery has taken place in patients in whom no marked destruction of tissues had occurred. Patients with cartilaginous and osseous lesions have vastly improved and the progress of the disease has been apparently checked.

Appropriate dressing should be applied to prevent deformities. After these have developed correction under general anesthesia may be required. Resection has been attempted in some cases where there has been marked deformity, but usually the results of resection have not been very satisfactory.

Neuropathic Arthritis.—Neuropathic disease of joints presents quite characteristic anatomical and clinical features. The joint changes are frequently preceded by a slight trauma, occasionally by a severe one. In many cases no history of preceding trauma can be elicited. Two forms of neuropathic arthritis are recognized, the atrophic and hypertrophic.

The arthropathies are painless. A joint may be practically destroyed, the destruction being so complete that a flail joint develops and the patient suffers no pain. The soft tissues surrounding such a joint usually present the appearance of an extensive œdema, yet they are very resistant and do not pit upon pressure. Evidences of an inflammatory process and fever are not observed even in the acute cases but there may be a local elevation of temperature. The condition may remain stationary or subside after some weeks, when it may recur. The joints of the upper extremity are more frequently involved in syringomyelia than in tabes, as the following statistics show:

	Arthropathies in syringomyelia (Schlesinger)	Arthropathies in tabes (Wrezsäcker)
Shoulder	52	21
Elbow	31	10
Wrist	22	2
Thumb and finger	2	....
Hip	6	31
Knee	10	78
Ankle	....	9
Tarsus	8	13
Toes	....	....
Jaw	4	2
Sternoclavicular	6	....
Acromioclavicular	1	....

Pathology.—The anatomical changes are quite as characteristic as the clinical picture. There is almost always a large serous exudate into the joint. The exudate may be so large and under such tension that the capsule is torn. Fluctuation may be elicited, suggesting a cold abscess, but the tension is usually so great that the tissues do not even pit. The large exudates are most frequently observed in neuropathic disease of the shoulder-joint. As a result of spontaneous perforation of the soft tissues or incision of the same, sinuses may form leading into the destroyed joint and through them are discharged enormous quantities of synovial fluid.

The capsule of the joint may be completely destroyed or replaced by connective tissue. It is usually thickened and covered by large and small villous-like processes, which may become infiltrated with lime salts and become cartilaginous or ossified. If these changes do not occur, the synovial membrane appears grayish red and more vascular than normal. The synovial membrane may be completely absorbed. There may, however, be some hypertrophy. Siddel has observed a case in which there was an increase in the endothelium, as many as 10 to 20 layers of cells being found. Connective-tissue bands, round-cell infiltration and newly formed vessels form the greater part of the capsular wall, which may be covered with necrotic masses. Ossification of the capsule is frequently noted, and islands of actively proliferating cartilage may be found. Large numbers of free bodies form, but these are not accompanied by the symptoms associated with free bodies developing in other forms of arthritis.

The articular ends of the bones present different stages of destruction, varying from simple necrosis of the articular cartilages to the most extensive destruction of the bones entering into the formation of the joint. In the pure synovial form there may be no involvement of bone and cartilage. When the articular cartilages are destroyed the spongiosa is exposed and grooves may form which extend some distance into it. Frequently the end of the bone is as hard as ivory. Marginal bony masses and exostoses are found in the progressive hypertrophic form. Fractures and dislocation may develop.

In the atrophic form which is observed most frequently in the shoulder-joint, the destructive process may cause a complete loss of the head of the bone (Fig. 242). Shoulder dislocations occurring in the arthropathies, associated with syringomyelia, tend to become habitual, because in this condition the greater tubercle is frequently

separated. Atrophic and hypertrophic changes may be noted in the same joint.

In the shoulder-joint the head of the humerus may be destroyed while exostoses develop about the glenoid cavity, causing an enormous widening of the same. The changes are not limited to the joint, but the bones adjacent to it and the soft parts surrounding it are often markedly altered. In this way the joint changes in the arthropathies

FIG. 242.—Syringomyelia shoulder. Painless destruction of joint. Head of humerus is destroyed. Pathological dislocation. Several pieces of newly formed bone are seen on the outer side of the humerus beneath and within the deltoid. (*Potter.*)

differ from those of arthritis deformans. The atrophic form is more common in the shoulder-joint than the hypertrophic. As the destruction occurs the shoulder may become dislocated, but even then the function of the joint is not markedly interfered with. There is usually a large exudate. There develops a peculiar form of circumscribed myositis ossificans, which will be mentioned in the section dealing with this subject. According to Williams this form of myositis ossificans is

probably due to trauma, for only those muscles ossify which are exposed to continued irritation by motion in the affected joint. Mechanical insults are also an important factor in the development of floating cartilages. Circumscribed forms of myositis ossificans are occasionally found. Levy has seen an osteoma as large as the fist in the deltoid. The long head of the biceps is usually destroyed.

When the elbow-joint is affected the exudate, which is always present, is not especially marked, except occasionally. In the hypertrophic form fracture of the olecranon and coronoid process, dislocation of the head of the radius, associated with grotesque changes in it, destruction of the semilunar notch, free bodies, and ossification of the brachialis anticus occur in many different combinations.

Volar dislocation of the hand occurs in arthropathies affecting the wrist-joint.

DISEASES OF THE BURSÆ OF THE UPPER EXTREMITY

The acromial and subdeltoid bursæ are those most frequently involved in surgical lesions of any of the numerous bursæ about the shoulder-joint. The subscapular, subcoracoid and coracobicipital bursæ are so deeply situated that they are not frequently affected by trauma and when diseased the diagnosis is often difficult or impossible.

The acromial bursa is situated subcutaneously over the acromion process. It is frequently the seat of acute and chronic inflammatory processes. Inflammatory lesions usually develop secondary to trauma and acromial bursitis is most frequently observed in people who carry loads upon the shoulder, especially in hod carriers. The symptoms are so characteristic that the lesion can scarcely be confused with anything else. The location of the circumscribed swelling, over which the skin moves readily, is characteristic enough to warrant diagnosis of acromial bursitis.

In the acute stage of the inflammation the bursæ should be protected from trauma and cold applications used. If suppuration occurs, the bursa should be incised and drained. As a result of repeated trauma, or following an acute non-suppurative bursitis, a chronic bursitis or hygroma may develop. The bursa may become as large as an apple and has a tense elastic feel. Such a distended bursa moves freely over the subcutaneous tissues and the skin can usually be freely moved over the swelling. A hygroma of the acromial bursa can

hardly be confused with any other lesion. Lipomas which are common in this region do not have the smooth surface of the hygroma and are lobulated. Both develop slowly, are practically painless and may long remain stationary. If there is any doubt as to differential diagnosis, aspiration will determine the nature of the lesion. A hygroma of the acromial bursa usually causes no inconvenience. Unless frequently subjected to trauma because of the nature of the patient's work, or unless removal is desired for cosmetic purposes the hygroma may be left alone. If indicated or requested, excision of the bursa is easily performed, and is preferable to attempts at obliteration of the cavity by the injection of carbolic acid, iodine, alcohol, etc.

The subdeltoid is the most constant and largest of the bursæ about the shoulder-joint. It is situated between the under surface of the deltoid muscles and the upper end of the humerus and the capsule of the shoulder-joint. The bursa occasionally communicates with the cavity of the shoulder-joint occurring most frequently in elderly patients.

The bursa is so situated that it is well protected from trauma, and acute inflammatory processes are not so often observed in it as in the bursæ more superficially situated. Acute inflammatory processes have been observed, offering some difficulties in differential diagnosis. Acute subdeltoid bursitis may occur after trauma. Suppurative forms have been observed after pneumonia and during the course of an empyema. Some of the cases of pneumococcic bursitis, which have been observed, especially in children, have been mistaken for osteomyelitis.

In the suppurative forms occurring in the course of pyemia, incision of the bursa is required. In the pneumococcic form aspiration, with the subsequent injection of formalin. 2 per cent., glycerin, 98 per cent., is often sufficient. These cases tend to recover much as do cases of metapneumonic arthritis under conservative treatment.

Chronic Subdeltoid Bursitis.—As the result of repeated traumata or of a chronic infection, a hygroma of the subdeltoid bursa may develop, a swelling as large as an orange or infant's head sometimes developing upon the outer and lower aspect of the shoulder-joint. The bursa is filled with a mucoid material, frequently stained brown from admixture of blood. The walls of such a hygroma may have attached small pedunculated fibrinous masses, which become detached to form free bodies. These impart a peculiar creaking sensation upon palpation.

Occasionally tuberculosis of the subdeltoid bursa occurs, the so-called rice-body hygroma then developing, the rice bodies being the

detached villous-like bodies so common in tuberculosis of bursæ and synovial membranes. A tuberculous hygroma may become large and may be mistaken for a rapidly growing soft sarcoma of the upper end of the humerus or for one of the lipomas which are so common in this region.

Some difficulty may be experienced in differentiating between a hygroma of the subdeltoid bursa and an effusion into the shoulder-joint. If the patient is viewed from above and behind and if both sides are compared, a marked increase of the prominence of the shoulder will be noted in the hygroma, especially anteriorly and to the outer side. In cases of effusion into the joint, the prominence of the shoulder is not markedly increased, because the capsule is not distensible enough to permit of much elevation of the deltoid muscle. If in hydrops the exudate is large enough to elevate the deltoid to some extent, the swelling will be much more prominent where the joint is not so well covered by muscles, viz., posteriorly and along the course of the synovial sheath of the long head of the biceps.

In cases of arthritis, tenderness may be elicited anywhere about the circumference of the joint, while in bursitis it is limited to the region of the bursa. Usually the tense bursa can be felt as a distinct mass between the deltoid muscle and the bone.

The smooth surface, non-lobulated structure and typical position usually enables one to differentiate between a hygroma of the subdeltoid bursa and a lipoma. I have had some difficulty in differentiating between a rapidly growing sarcoma of the upper end of the humerus and a subdeltoid hygroma. The X-ray examination, however, revealed considerable bone destruction and permitted of easy differentiation between the two.

Aspiration of a hygroma, with subsequent injection of carbolic acid or iodine, may be attempted. Such injection should be followed by compression. In cases in which the hygroma has existed for a long time, extirpation of the sac will be required, for the walls are so thick and rigid that obliteration of the cavity cannot be expected to follow aspiration and injection.

Extirpation is indicated in tuberculous bursitis. When suppuration occurs the bursa should be incised and drained.

A chronic adhesive inflammation of the subdeltoid bursa has been described developing after direct or indirect trauma. This has been designated clinically as humeroscapular periarthritis. Codman has emphasized the frequency of subacromial bursitis and believes that it is often not recognized clinically, being regarded as neuritis, rheumatism, fibrous ankylosis, gout, rheumatism, or any one of a number of other rather vague lesions.

In this connection it should be remembered that in the adult at least, the subacromial bursa is usually fused with the subdeltoid and that it is to be regarded merely as an upward extension of the latter.

The subacromial bursa is frequently exposed to trauma. When the deltoid acts quickly without the supraspinatus, which must start abduction of the humerus before the deltoid can act to advantage, the fixed upper part of the bursa is forced against the under surface of the acromion and so traumatized. When the supraspinatus acts first, beginning the abduction, the bursa glides under the acromion without being subjected to injury.

Codman describes three types of subacromial bursitis: (1) acute or spasmodic; (2) subacute or adherent; (3) chronic or non-adherent.

The symptoms associated with subacromial bursitis are the same as those described by Duplay under the term humeroscapular neuritis. Pain is common to all of the types. It is apt to be especially severe at night and is usually located at the insertion of the deltoid muscle. If adhesions are present, abduction beyond 10 degrees may be impossible and if the bursal walls are rough, motion may be hindered at first, but may take place suddenly when extra effort is made, as in trigger finger. Some difficulty may be experienced in differentiating this form of bursitis from inflammation of the shoulder-joint. If the scapula is fixed, abduction of the arm is impossible in bursitis, while motions in the sagittal plane and rotation in the long axis of the humerus may be possible. In inflammatory lesions of the shoulder-joint motions in all directions are painful and limited. The tenderness in bursitis is limited to the bursa, the superficial parts of the joint posteriorly and in the axillary fascia being insensitive to pressure. This is not so in arthritis.

Treatment.—When the symptoms of subacromial neuritis are acute the arm should be kept quiet in abduction. Care must be exercised, however, to prevent the formation of adhesions. When adhesions are present the patient should be anæsthetized and careful passive motion instituted. This should be followed by massage, hot air and electricity. Motion should alternate with rest. In those cases which resist ordinary lines of treatment, excision of the bursa is indicated.

As a result of muscular effort, hemorrhage may occur into a bursa lying between the tendon of the biceps and the tuberosity of the radius. This bursa is small and deeply situated, so that the diagnosis of its lesions is often difficult. Inflammation of this bursa is characterized by tenderness, by functional disturbances, and by pain during pronation and supination. The history of the injury and the local findings may arouse suspicions of bursitis.

The olecranon bursa is exposed to trauma and acute and chronic inflammations of it are common. Acute bursitis develops most commonly after injury. It occurs in gout, in which disease there may be repeated attacks of acute inflammation. The X-ray examination is of importance in gouty bursitis, for it usually reveals the presence of urates in the wall of the bursa. After injury, in which blood is poured out in the cavity of the bursa, all the signs associated with acute inflammation develop. The bursa enlarged to form a hemispherical swelling over the olecranon. This swelling can usually be moved on the underlying tissues. Only in rare cases is the inflammatory process confined to the bursa. The infiltration involves the entire region posterior to the

elbow and only the fact that the changes are most marked in the area immediately adjacent to the bursa enables one to differentiate between a primary cellulitis and a bursitis. The swelling may even extend to the arm and forearm. The tendency of acute bursitis is to subside spontaneously. Occasionally the acute inflammation ends in suppuration. The arm should be kept at rest and hot dressings applied, or if more agreeable to the patient, cold compresses may be used. Usually the acute process subsides in three or four days. Some swelling may persist, however, and quite often a hygroma develops. If suppuration occurs, the bursa should be incised. There is no difficulty in differentiating between an arthritis of the elbow-joint and an olecranon bursitis for in the latter the motions of the joint are not interfered with.

DISEASES OF THE MUSCLES OF THE UPPER EXTREMITY

Myositis.—The muscles of the upper extremity are not especially subject to inflammatory processes. Infection of the muscle may occur through the blood stream, be introduced through wounds, or extend from neighboring foci.

An inflamed muscle becomes swollen and hard. Whenever thrown into action there is considerable pain. The joints generally are somewhat fixed in order to protect the affected muscle from injury. The indurated area soon breaks down to form an abscess and the overlying skin becomes reddened and œdematous as the inflammation approaches the surface. The lymphatics draining the inflamed area are usually enlarged and tender. There is some fever and general reaction.

The muscle should be kept at rest and hot dressings applied. When the indurated area softens to form an abscess, the latter should be incised. After evacuation of the pus, repair takes place, the amount of interference with the function of the affected muscle depending upon the amount of muscle destroyed by the inflammatory process.

Tuberculosis of the muscles of the upper extremity is very rare. When it does occur as a primary infection, foci are usually to be found in other muscles of the body. Infection may occur by extension from neighboring tuberculous foci in skin, glands, bones or joints, or the muscle may be primarily diseased as the result of a blood infection. The symptoms of tuberculous myositis are not very definite. There is usually but little pain or tenderness and interference with the function of the muscle may not be marked until the involvement is extensive.

The diagnosis is often difficult. The presence of tuberculosis in another part of the body and the slow growth of the lesion without much pain or disability, especially in the absence of symptoms of syphilis, should arouse suspicion.

When the diagnosis is made, operative interference is indicated. If the muscle is small and unimportant, it should be removed in its entirety. When the muscle serves an important function, the belly of the muscle may be removed and the tendon transplanted to another muscle. If the muscle is but partially diseased, the affected portion should be removed.

If caseation and abscess formation have occurred, the tuberculous débris should be aspirated and the abscess injected with iodoform-glycerin emulsion. Aspiration will probably have to be repeated. If improvement does not occur under this line of treatment, incision and drainage of the abscess is indicated.

Syphilitic Myositis.—Muscle pains are quite frequently observed early in the course of syphilis. These are usually associated with mild degrees of myositis, which does not develop to any extent and subsides rapidly under treatment. In some cases about one year after infection certain muscles, especially the biceps, begin to contract slowly. The contraction may be great enough to flex the forearm to an acute angle. Little is known concerning the pathology of these cases. If left alone, the contractures may persist for some years. They usually rapidly disappear under antisyphilitic treatment.

Syphilitic myositis may be diffuse or circumscribed, the latter being due to the formation of gummata. In the diffuse form the connective tissues proliferate to form a dense infiltration causing atrophy of contractile elements of the muscle. The muscles involved become hard and swollen, contractures develop and motions are painful. The history of infection, or in cases where such a history cannot be obtained, a positive Wassermann test should reveal the nature of the lesion. Improvement usually occurs rapidly when antisyphilitic treatment is instituted.

Gummata of muscle are not so common. They may be confused with sarcomata and are of considerable surgical interest because of the difficulties often encountered in making a differential diagnosis. Gummata may be hard or soft, depending upon the amount of liquefaction. They usually grow slowly and are not associated with much pain. The muscles of the upper extremity are relatively infrequently the seat of syphilitic lesions.

Parasitic Diseases of Muscles of Upper Extremity.—Parasitic diseases of muscles have but little surgical interest. They must be considered in differential diagnosis for they clinically may resemble tumors. The myositis, associated with the lodgment of the parasites may be mistaken for some other diseases. The parasitic diseases which will be considered are trichinosis, echinococcus and cysticercus. The bothriocephalus liguloides has been observed in muscles. Muscular infection with this parasite, is, however, extremely rare, only 19 cases having been observed and these have occurred in Chinese and Japanese.

Trichinosis.—The myositis associated with trichinosis is of surgical interest chiefly because of the difficulties encountered at times in diagnosis. The reason why the embryos are deposited in the muscles after having gained access to the blood from the intestines has been the subject of considerable discussion. The fine narrow-meshed capillary network and the variation of the size of the vessels during different stages of contraction are supposed to favor the lodgment of the worm.

The lodgment of the parasite is associated with degenerative and inflammatory changes in the muscle. The degenerative changes, fatty and vacuolar in character, the former predominating, are usually diffuse. Even before encapsulation of the worm occurs, an interstitial myositis, usually focal in character, develops. Large numbers of eosinophile cells are found in the acute stage of the myositis. Suppuration does not occur. After eight weeks the changes begin to subside and a muscular atrophy develops which is not confined to that part of the muscle immediately surrounding the parasite but is in those areas also in which fatty degeneration has occurred. Some regeneration of the muscle takes place after encapsulation of the parasite, but a considerable scar may develop in the infected muscle.

As previously stated, trichinosis has little surgical interest except from the viewpoint of differential diagnosis. The disease begins with severe gastro-intestinal symptoms and may simulate typhoid fever or ptomaine poisoning. Six or eight days after the beginning of the disease the symptoms associated with the myositis develop. These symptoms may be mild or severe. In the mild case the patient complains of muscular pain often mistaken for muscular rheumatism. In severe cases the muscles are extremely painful and every movement hurts. The different forms of polymyositis (pseudo-trichinosis) and meningitis, because of retraction of the neck, involvement of eye muscles, etc., must be considered in the diagnosis. A symmetrical facial œdema, most marked in the eyelids, but also occurring upon the forehead and cheeks, is an important symptom and aids in making a diagnosis where sporadic cases are observed. Trichinosis is associated with a marked eosinophilia. The diagnosis is definitely settled when the worm is found in the muscle. The X-ray affords but little help in diagnosis, for even when calcification has occurred, the shadow is not definite enough to permit clear differentiation from the fat and skin.

Echinococcus Disease.—Most's statistics dealing with 200 cases of echinococcus disease of muscle show the following relative distribution of the lesions. The muscles of the head were affected 9 times; those of the neck 26; those of the trunk 65; those of the upper extremity 25; and those of the lower extremity 75. The more peripheral the muscle, the less frequent, the nearer the abdomen, the more frequent the involvement.

Certain muscles in the different parts of the body seem to be predisposed to echinococcus disease. Of the muscles of the upper extremity the biceps and the deltoid are most frequently affected. It is stated that the infection occurs most frequently in muscles which are used most and in those which are immediately adjacent to large vessels. This relation to large vessels is very interesting and suggests that the active passage of the embryos along the vascular sheath may occur for their rather characteristic distribution in muscles bordering upon large vessels.

Symptoms associated with the invasion of the muscle are few or wanting. The disease first attracts attention when the cyst becomes large enough to be felt or seen. A cyst, when lying deep, may become quite large before it attracts any attention. Trauma may direct the attention of the patient to the cyst, or a cyst lying upon a nerve may cause neuralgic

pains severe enough to demand medical aid. As the parasites are found so frequently along large vessels it is not at all uncommon for pressure neuritis to develop.

Paralysis of the muscles of the upper extremity from pressure upon large nerve trunks has not been observed. Œdema from pressure upon the larger veins occurs and considerable atrophy of the affected muscle may develop.

The cysts are usually round or oval. Lobulated forms resembling lipomas do, however, occur. The consistency varies. Small cysts may be so tense that they resemble solid growths. Definite fluctuation can usually be elicited in large cysts. When the cyst is deeply situated and covered by muscles, it may be difficult to elicit fluctuation.

The cysts vary greatly in size. They may be as large as a pigeon's egg and cysts the size of a man's head have been described. It is only exceptionally that echinococcus cysts have a slow, continuous growth. Usually the growth is intermittent, the cyst increasing rather rapidly in size after remaining stationary for some time. Rapid growth may be determined by any one of a number of factors, such as trauma, violent muscular effort or intercurrent infections. In infection of the cyst, rupture (this is accompanied by a general reaction and urticaria) or spontaneous healing may occur. Marked and extensive muscular atrophy after rupture of the cyst has been observed.

The extent to which the cyst may be moved depends largely upon whether the muscle is contracted or relaxed. When the muscle is contracted, the cyst is fixed; when relaxed, the cyst can be moved about very readily.

Echinococcus disease of muscle is not often correctly diagnosed. Tavel's statistics dealing with 107 cases show that the diagnosis was not definite or was not made in 52; that a wrong diagnosis was made in 28 and that in 4 cases the disease was only recognized at autopsy; that in 7 cases the lesion was considered as probably echinococcus, and that in only 16 cases (15 per cent.) was a positive diagnosis made. The lesion has been regarded as a muscle hernia, a cold abscess, gumma, lipoma, hemangioma, sarcoma, etc. There are no characteristic signs. The nationality of the patient might give a clue, for if a patient from a country where echinococcus disease is common has a peculiar cyst formation in the muscle, especially if the peculiar echinococcus fremitus can be elicited and there is an eosinophilia, echinococcus disease should be seriously considered in making a diagnosis. Complement fixation is extremely valuable and should, if present, enable one to make a positive diagnosis.

Total extirpation of the cyst is the only line of treatment to be considered. Occasionally part of the cyst may be so adherent to structures which cannot be sacrificed, that part must be left *in situ*. The wound may be left partially open in such cases and packed. As irregular, open spaces are usually left after extirpation of the cyst, it is generally well not to attempt immediate closure of the wound, but to either drain or pack the cavity and permit it to close by granulations.

Cysticercus Disease.—Cysticercus disease of the muscle in man occurs as solitary or multiple lesions. Multiple cysticercus of the muscles is more common than solitary. It is usually combined with cysticercus disease of the viscera. The infection in man occurs as the result of the migrating of the embryos discharged from another or from the same patient. The thick shell of the embryos is digested when they reach the stomach and liberated embryos then bore their way into the stomach or intestinal wall. They are then carried by the blood or lymph stream, or proceed by active migration into the muscles. It may not be necessary for infection that the embryos be discharged and then migrated for they are found in the intestinal canal of patients harboring tapeworms, and antiperistalsis may carry them back into the stomach where the shell would be digested.

After wandering into the muscle the embryo undergoes various metamorphoses and changes. In two or three months it forms a cyst filled with serum, from the walls of which there develops toward the interior scolices. Focal inflammatory changes, localized fatty degeneration, degeneration of the vessel walls, with capillary hemorrhages, have been ob-

served in muscles harboring the cysticercus. After remaining alive for from three to six years, the cysticercus dies, the fluid becomes cloudy and the cyst either shrinks or becomes calcified. Surgically, the main significance lies in the difficulties offered in diagnosis. X-ray examination is of great aid in making a diagnosis in these cases.

Solitary cysticercus is observed most frequently in the pectoralis major and biceps. The solitary is of much more surgical interest than the multiple cysticercus. Infection occurs in the same way as just described for multiple cysticercus, but it is also probable that infection with the embryo occurs directly in small wounds, the shell having been destroyed by some putrefactive process and that the liberated embryo then passes through the tissues by active motion to reach the muscle.

The diagnosis is usually not made with certainty. Mild inflammatory processes may occur in the cyst and suppuration develop, but the inflammatory processes occurring in the diseases are not progressive in character.

Treatment consists of extirpation of the cyst.

Myositis Ossificans.—Both the circumscribed and diffuse forms of myositis ossificans are observed in the muscles of the upper extremity. In the diffuse form, the involvement of the muscles of the upper extremity is but a part of a general process and has but little surgical interest.

Etiologically, three forms of circumscribed myositis ossificans are recognized; the traumatic, non-traumatic, and neuropathic.

Traumatic Myositis Ossificans—The drill bone which develops in the deltoid muscle after trauma caused by the rifle is rare at the present time. Circumscribed forms of myositis ossificans developing after dislocations are of considerable surgical interest. They have been observed after dislocations of the clavicle, shoulder- and elbow-joints. Strausz has observed ossification of the subclavian muscle after dislocation of the clavicle, and Regneir ossification of the subscapular after dislocation of the shoulder. This type of myositis is observed most frequently in the brachialis anticus after dislocation of the elbow-joint. Almost all of the cases reported in French literature—Frangenheim's six cases; 19 of the 20 cases collected by Schulz and 16 cases reported by Machols—occurred in the brachialis anticus and were secondary to a dislocation of the elbow.

In all of the cases the dislocation has been backward. Machols has made the statement that myositis ossificans never occurs in cases in which the dislocation has not been reduced. This observation is not correct for Frangenheim has reported two cases of ossifying myositis of the brachialis anticus in which an open reduction of an old dislocation has been attempted.

The myositis usually begins within the first four weeks after reduction, but usually does not cause any pronounced symptoms until the second four weeks. During this time the tissues about the elbow become swollen and painful and the motions of the joint are restricted.

The symptoms usually become most pronounced at the end of the third month. Then follows a period of improvement, during which the swelling becomes smaller and harder. There may be a gradual improvement for some months.

The point at which the bone develops varies as the brachialis has a wide origin and attachment, spreading out over the anterior surface of the lower half of the humerus and the capsule of the joint and being

FIG. 243.—Myositis ossificans shows the plaque of bone which has developed in the brachialis anticus. (*Kultner.*)

attached to the tubercle of the ulna. Upon the basis of X-ray examination Machols has differentiated three groups of cases, depending upon the point at which the bone forms (Fig. 243). In the first group, the shadow lies in the soft parts in front of the diaphysis of the humerus. Processes pass from this shadow to the shaft which they approach quite closely. In the second group, the shadow lies opposite the joint space and the ends of the bones of the forearm. Narrow processes extend

from the main shadow, mostly toward the ulna. In the third group, the shadow lies in the soft parts in front of the diaphysis of the humerus. The shadow rapidly reduces in size and in a short while becomes circumscribed and highly differentiated and at no time are any processes found which indicate any connection with the bony skeleton.

That myositis ossificans of brachialis anticus occurs often in this type of injury is due to the fact that the muscle is not only traumatized by direct force but that its fibers are also stretched and lacerated when the bones are forced backward. The brachialis contains fibers which arise from the capsule of the elbow-joint and occasionally ossification extends to the capsular ligament of the joint.

The non-traumatic form of ossifying myositis is rare. In the neuropathic form which may occur in spina bifida, tabes dorsalis, syringomyelia, transverse myelitis and paralytic dementia, the ossifying process is usually associated with marked destructive changes in the neighboring joints. This form has already been discussed in the section dealing with the arthropathies occurring in tabes, syringomyelia, etc. Even when there are no joint lesions, ossifying myositis may develop in these diseases and often a number of different muscles are affected. Schwarz has observed ossification of the biceps brachii, vastus lateralis and semimembranosus in a tabetic and Raskowski, extensive ossification of the flexors and extensors of the forearm in a patient with syringomyelia.

Clinical History and Picture of the Traumatic Form.—There are cases in which ossification of the muscle occurs without symptoms. The bone is discovered accidentally, but careful questioning often reveals a forgotten injury. In recent cases there is found at the point of injury and in the tissues immediately adjacent, more or less of a swelling which usually is quite hard. Subcutaneous hemorrhages are also present when the injury is due to direct violence but may be wanting when due to indirect violence. Following the symptoms due to the contusion or rupture of the muscle is a period of progressive improvement. Under the simplest treatment improvement begins and the swelling due to the extravasation of blood subsides. The arm remains weak and the patient is often surprised that power does not return even when the objective improvement is marked. The amount of limitation of motion in the neighboring joint remains about the same and pain is still felt at the site of the contusion. The amount of tenderness present during the development of the bone varies. It may be quite marked or wanting. Sometimes the pain is extremely severe and radiating. The latter is probably caused by pressure of the developing bone on adjacent nerves.

The bone may form rapidly. Oriou has reported a case in which, eight days after an injury, the deeper part of the swelling had a sugges-

tive hardness, and on the eleventh day was so firm that a needle could not be forced into it.

The degree to which the newly formed bone can be moved upon adjacent tissues varies. In some cases it is so closely adherent to the underlying bone that it cannot be displaced. Usually it can be displaced upon the subjacent structures without any difficulty.

Diagnosis.—In the typical cases the diagnosis can be made without much difficulty. If after an injury to a muscle which is predisposed to the development of ossifying myositis, the hematoma on becoming smaller becomes as hard as bone and later enlarges, but still can be easily separated from the underlying bone, there is no difficulty in making the diagnosis. If the mass cannot be displaced upon the underlying tissues, excessive callus, exostasis and periosteal sarcoma must be considered. Gummata and tumors of muscles must also be considered in diagnosis. It is most important to differentiate between myositis ossificans and periosteal sarcoma in the early stages and this is often difficult. Central giant-cell sarcomas offer no difficulties in differential diagnosis. Both periosteal sarcoma and myositis ossificans occur in young people and trauma plays an etiological rôle in the development of each. The consistency of each may be about the same and each may have a fairly rapid growth, but the swelling associated with myositis ossificans remains stationary or recedes after a time, while the growth of the sarcoma is steady and progressive. Coley, in a comprehensive article on traumatic myositis ossificans, states that in many cases there is a striking similarity between myositis ossificans and periosteal sarcoma. The X-ray plates of his first case had been examined by several X-ray experts and all pronounced the lesion sarcoma. The X-ray is of great value because in many cases the other data will not enable one to make a differential diagnosis. In myositis ossificans there is usually a sharp line at the junction of the newly formed bony mass with the bone, while in periosteal sarcoma this line is less distinct and the cortex of the bone appears irregular, ragged and eroded except very early in the disease. Fusiform shadows at either extremity of the mass, which become continuous with the shaft of the underlying bone, are indicative of a sarcoma. Coley believes that the mass developing in myositis ossificans is harder than the periosteal sarcoma, and furthermore, that the mass is of uniform consistency, while a sarcoma is very apt to be soft in some places and hard in others. A sarcoma never has the bony hardness which is typical of myositis ossificans.

The early pain associated with myositis ossificans and the early impairment or loss of function of the joint related to the muscle involved are but rarely met with in periosteal sarcoma except in the late stages of the disease, when there should be no difficulty in differentiation.

The frequency with which circumscribed myositis ossificans is observed in the muscles of the upper extremity is indicated by the statistics compiled by Strausz. He collected 127 of circumscribed myositis ossificans. In 64 of these the flexors of the upper arm were involved, in 43 the quadriceps femoris, and in 13 the adductors of the thigh. Various other muscles of the body were involved in the remaining cases.

Jones believes that in most cases the bone develops from displaced pieces of periosteum. This belief is based upon the frequency with which myositis ossificans follows dislocations; the frequent attachment of the newly formed mass to the underlying bone; the occasional attachment of the bone below the origin of the muscle which has been subject to a violent strain; and upon the observation that in fracture shreds of periosteum may give rise to the development of bone which is independent of the callus and takes no part in the reparative process.

Treatment.—No general rules can be laid down regarding treatment. Each case must be treated according to the indications as they arise. If there is a dislocation it should be carefully reduced and any added injury by excessive traction or direct pressure should be avoided. Makins makes the following statement: "As to the general line of treatment to be adopted, a period of some weeks complete rest should be maintained during the continuance of the active progress of ossification. When it is judged by clinical observation and X-ray examination that progress has ceased or the process is retrogressive, massage and exercise should follow. Operative treatment should be considered only when the process has come to a definite standstill and the patient suffers from functional disability which there is a chance of relieving."

Finney states that there is an unfavorable, as well as favorable time for operation. It should never be recommended early in the development of the bony tumor, even for diagnostic purposes, since, if we have to deal with a subperiosteal hematoma it is of doubtful efficacy and in this condition the tendency to recur is very great. If the operation is performed, when increase in the size of the tumor is no longer present and its consistency has become harder, the chances

of recurrence are very materially lessened. The operation should consist in a thorough excision, passing well outside the osteoid tissue, including some healthy muscle. The underlying periosteum should be thoroughly excised and the shaft of the bone cleaned off until a smooth surface remains. Cauterization, with the actual cautery of the denuded bone surface, has been recommended. Operation is not to be recommended in every case, as many recover under rest followed later by massage and active and passive motion.

Considerable care must be exercised regarding active and passive motion and immobilization. Active and passive motion at an early stage may increase the reaction, while immobilization may result in marked limitation of motion if carried to the extreme during the formation of the bony mass.

Ischemic Myositis (*Ischemic Palsy, Volkmann's Contracture*).—Interference with the flow of arterial or venous blood may cause marked changes in muscles. The most common causes of ischemic myositis are fractures in which there is compression of the artery or rupture of its intima, associated with a subfascial hematoma which retards or prevents the development of a collateral circulation; improperly applied, tight plaster-of-Paris dressings; too long-continued constriction for artificial ischemia; and the long-continued action of cold.

Ischemic myositis and gangrene should be regarded as different stages of the same process. For the development of ischemic myositis a sudden ischemia of a certain intensity is necessary. The first stage is venous stasis associated with a serosanguinolent infiltration of the muscles. If the venous stasis increases or is not relieved, the muscle fibers degenerate and the contractile substance of the muscle is replaced by scar tissue. If the stasis becomes more marked or continues longer, gangrene may develop and the dead muscles are eventually extruded.

The muscles of the forearm are most frequently involved in ischemic myositis. The structures are affected in the following order when the ischemia is continued long enough to produce changes: (1) The long flexors of the wrist and digits at the origin of their fibers are involved earliest and to the greatest extent. (2) The extensor muscles when the venous stasis is marked. (3) The skin. (4) Peripheral parts of the extremity become gangrenous. (5) Nerves become involved. (6) The skeletal and supporting tissues. Hildebrand believes that the nerves are also involved in cases of ischemic myositis, a view formerly held to be incorrect. Distinct sensory disturbances are frequent in

advanced cases of Volkmann's contracture, especially in those which have just missed the terminal stage of gangrene.

Ischemic myositis is observed almost exclusively after fractures, as many as 80 per cent. of the cases following this form of injury. It may follow interference with the circulation from any cause, provided that the interference is not complete enough to cause gangrene. Interference with the venous outflow is probably more important as an etiological factor than interference with the arterial circulation. Bardenheuer mentions four cases of ischemic myositis which developed after marked venous congestion, in which the pulse at the wrist was never lost.

Ischemic palsy is commonest after fractures about the elbow-joint, especially after the extension supracondylar fracture. This is because the principal vessel of the arm and the collaterals are most easily injured or compressed in this type of fracture. Bardenheuer believes that interference with the circulation through the principal vessel is not enough to cause the myositis, but that the collateral circulation must be affected at the same time. In supracondylar fracture of the humerus the circulation through the collaterals is impeded by the pressure of the lower end of the upper fragment, or by a hematoma which forms beneath the firm, resistant fascia covering the antecubital fossa.

In 52 of the 55 cases collected by Hildebrand, the ischemic myositis followed a fracture. It should, however, be remembered in this connection that only those cases are reported in which a complete, decided contracture has developed. A large number of contractures which have improved or disappeared after massage, baths and exercises, have not been reported and others have been regarded as cases of atrophy from disuse.

It is often stated that ischemic myositis is due to a tight dressing, most often the circular plaster-of-Paris cast. The plaster cast is but rarely the only and determining cause of ischemic myositis, the essential etiological factor being in almost all cases, intimal rupture or compression of the main vessel and its collaterals by the projecting lower end of the upper fragment and a retrofascial hematoma. The nerves are not much involved in the simple, uncomplicated forms of ischemic contractures. They may be injured by direct violence, by the ends of the bony fragments, and in advanced cases they may be compressed by the scar tissue which has formed. As has already been stated this

is most frequently observed in those cases which have just missed the terminal stage of gangrene.

Symptoms.—When the circulation is seriously interfered with the parts becomes swollen, the skin cyanotic, and the muscles painful and of board-like hardness. Passive motion is painful and no longer free. The amount of pain apparently varies in different cases. Dudgeon states that pain is absent unless there is a neuritis, while others state that pain is an early and important symptom. If there is no pain, the myositis may not be recognized until the damage done is irreparable. When a circular plaster-of-Paris bandage has been applied too tightly, an area of necrotic skin at the site of the constricting fold may be found. Frequently when examining cases of ischemic contractures, the scar resulting from the healing of such an ulcer is found.

When fully developed, the deformity resulting from such a contracture is quite characteristic. The phalanges are flexed upon each other but the metacarpo-phalangeal joints are extended. When the wrist is extended the phalanges cannot be extended, when the wrist is flexed the fingers can be straightened out.

Treatment.—The treatment in the first place should be prophylactic. In fractures about the elbow, especially supracondylar fractures, reduction should be made early for pressure of the lower end of the upper fragment may interfere with the circulation of the forearm. It may be advisable or necessary in some cases to incise the fascia covering the antecubital fossa to relieve the pressure upon the principal vessel or its collaterals by the retrofascial hematoma.

Dressings which exert pressure should be avoided, and for this reason the circular plaster-of-Paris cast should not be applied directly after the injury is sustained. After reduction of the fracture, if there are signs of pressure, a non-constricting temporary dressing should be employed.

In mild cases the contractures may be prevented or relieved by massage, by active and passive motions and by dressing the fingers in extension.

If the myositis has advanced to the stage of marked fibrous degeneration resulting in the typical deformity the tendons or muscles must be relatively or absolutely lengthened. In the Mikuliez-Henle procedure 3 cm. of the radius and ulna are resected, producing a relative lengthening of the tendons. Diehmann and Bardenheuer advise myotomy. In a boy aged seven, Diehmann divided the affected muscles

transversely and obtained extension of the fingers. The flexor profundus was found to be comparatively healthy and he sutured this to the peripheral stump of the divided muscles. Six weeks after the operation the fingers could be flexed and extended voluntarily. I believe that in most cases tendon lengthening is the operation of choice, although in advanced cases but little is to be expected from any type of operation, for so much of the contractile substance of the muscle has been destroyed that function cannot be restored.

Snapping or Trigger Finger.—Small nodules or fusiform enlargements may develop in the flexor tendons of the fingers. They are the cause of the condition known as trigger finger. When the patient attempts to open the hand, the affected finger cannot be extended simultaneously with the others, but when the small nodules on the tendon dilate the sheath enough to permit it to pass, the finger becomes extended suddenly with a jerk. The reverse of this may happen, the finger affected not being flexed simultaneously with the other fingers but later and with a snap. Palpation usually reveals the nodule upon the tendon or the fusiform enlargement. Lexer, in operating for the relief of trigger finger has frequently found a limited fibrous thickening of the tendon or a small round nodule resembling a fibroma within a fusiform enlargement. In one case he found a small cyst. Cysts have also been described in trigger finger by Thom and Franz.

Traumatic Tenosynovitis, Tenalgia, Tendovaginitis Crepitans.—When a tendon is injured or torn small hemorrhages occur in the sheath. A layer of fibrin is then deposited upon both the visceral and parietal layers of the tendon sheath. Tenalgia crepitans occurs in people in certain occupations and is more apt to develop in novices than in those accustomed to their work. The extensor tendons of the thumbs may be injured in laundresses while wringing the clothes. This form of tenosynovitis is most frequently observed in blacksmiths, drummers and piano players, especially if the work is heavy or if practice is long continued. Motions involving the affected tendons become painful and there is more or less swelling of the skin. When the tendons are thrown into action a peculiar grating or rubbing sensation, or crepitation is experienced. Later, when an effusion is poured out, the layers of the sheath are separated and the crepitation disappears. The effusion causes a swelling which corresponds in shape and position to the sheath affected. If the tension is considerable pain and discomfort may be quite marked. The diagnosis is usually readily made. When the cause is removed the inflammatory process usually subsides rapidly with complete anatomic and functional restoration. If adhesions form which limit the motion of the tendon these should be broken up and active motion should then be begun early to prevent adhesions developing again. If the cause is not removed the condition may become chronic. Traumatic tenosynovitis is a frequent accompaniment of fractures, but recovery usually occurs during the treatment of the fracture.

INFECTIVE TENOSYNOVITIS AND WHITLOW OR FELON

These will be considered together for felons have a definite etiological relationship to infective tenosynovitis. Before discussing these subjects it will be necessary to review the anatomical arrangement of the structures of the terminal phalanges and the disposition of the sheaths of the flexor tendons, for the arrangement of the subcutaneous

fibrous bands in the skin of the terminal phalanges, determines to some extent the clinical forms of felons, and the extension of the inflammation along the synovial sheaths, when these are involved, is quite typical.

The terminal phalanges are most frequently infected because exposed so often to trauma. After an injury, which lowers the resistance of the part or introduces infection, the inflammatory process may run a rather definite course and present symptoms which are in part determined, as was first shown by Hueter, upon the anatomical arrangement of the structures entering into the formation of the terminal phalanx. The subcutaneous tissue of the volar surface of the terminal phalanges is relatively thick, contains heavy connective-tissue fibers which pass vertically from the papillary layer of the skin to the periosteum. Between these heavy vertical connective-tissue bundles are found small masses of fat, small blood-vessels and nerves. Glands which may pass down almost to the periosteum are found in the part and may afford the point of entrance to pathogenic bacteria. Inflammatory processes are thus confined in relatively narrow limits when they involve the tissues of the terminal phalanx. The tension which develops within these septa in infections accounts for the pain associated with felons and also for the amount of necrosis which not uncommonly accompanies them. On either side of the closed space and running parallel to it, is a blood-vessel which supplies the diaphysis of the terminal phalanx, the epiphysis being supplied by a branch which is given off before the main vessel enters. When tension becomes high in this closed space of the terminal phalanx these nutrient vessels may be occluded, leading to sequestration of the diaphysis of the terminal phalanx, a condition quite frequently observed when felons which have gone on to pus formation are operated upon.

When an infection develops in the fat between the septa, it does not extend through the skin readily because that covering the volar surface is so thick and resistant; but, following the paths of least resistance, it is apt to spread between the connective-tissue septa, to involve bone, joint, or synovial membranes.

Arrangement of the Synovial Sheaths of the Flexor Tendons.—The arrangements of the synovial sheaths of the flexors of the index, middle, and ring fingers differ from those of the thumb and little finger. The synovial sheaths of all have a parietal and visceral layer, the parietal layer lining the osteoaponeurotic canal and being reflected at either extremity of the sheath upon the tendon to form the visceral layer.

The proximal ends of the sheaths of the tendons of the index, middle and ring fingers, extend from 10 to 15 mm. above the meta-carpo-phalangeal line. The distal ends of the sheaths correspond to the base of the last phalanx.

The proximal end of the sheath of the index-finger is related to the thenar spaces, while that of the middle finger is most often related to the middle palmar space, although at times inflammatory processes involving the sheath may rupture into the thenar space. The tendon sheaths of the ring and little finger are related to the middle palmar space. The relations of the synovial sheaths to the palmar spaces have been especially emphasized by Kanavel. Their relation to palmar abscesses and the most advantageous points of incision, will be discussed later.

The synovial sheath of the flexor longus pollicis is often, especially by the French, referred to as the radial bursa. This term should be limited to the sheath in the palm of the hand which extends into the forearm beneath the annular ligament. The sheath of the long flexor tendon of the thumb extends into the palm and passing beneath the annular ligament, forms the radial bursa. The total length of this sheath is from 5 to 5½ in. At its insertion into the ungual phalanx the sheath ends in an annular *cul-de-sac* which has on each side a small falciform fold. The radial bursa lies upon the radiocarpal articulation and the lower end of the radius. It is covered by the pronator quadratus and is related to the deep median sheath when such is present.

Synovial Sheath of the Little Finger and the Ulnar Bursa.—The ulnar bursa, attached to the flexor sublimis and profundus tendons, ordinarily communicates with the sheath of the little fingers. Poirier states that frequently there is no communication between the two, he having been unable to demonstrate a communication in 23 out of 52 cases. When the two communicate, the sheath measures 13 or 14 cm. in length. When they do not communicate the separation varies from a simple narrowing to a complete occlusion, measuring some millimeters in length. The sheath does not surround the tendon but lies to the ulnar side, the tendons apparently being invaginated into the sheath much in the same way that the lung has been invaginated into the pleural sac. Space does not permit of the description of the pre-, inter- and retrotendinous pockets formed by this arrangement, a detailed account of which may be found in Poirier and Charpey's anatomy.

The upper extremity of the ulnar bursa passes above the annular ligament, lying upon the lower extremity of the ulna. The different

arrangements of the sheath are shown in the accompanying figures (Fig. 244). Variations from these types have been described but they are too few to demand consideration.

Six types of felon are recognized: the cutaneous, subcutaneous, osteal, arthritic, synovial and subungual (paronychia, run-around). In neglected cases two or more types are frequently combined, no matter what the site of the primary lesion may have been. A subcutaneous felon may be accompanied by an inflammation of the terminal phalanx, and the synovial membrane may be infected as a result of extension from the bone.

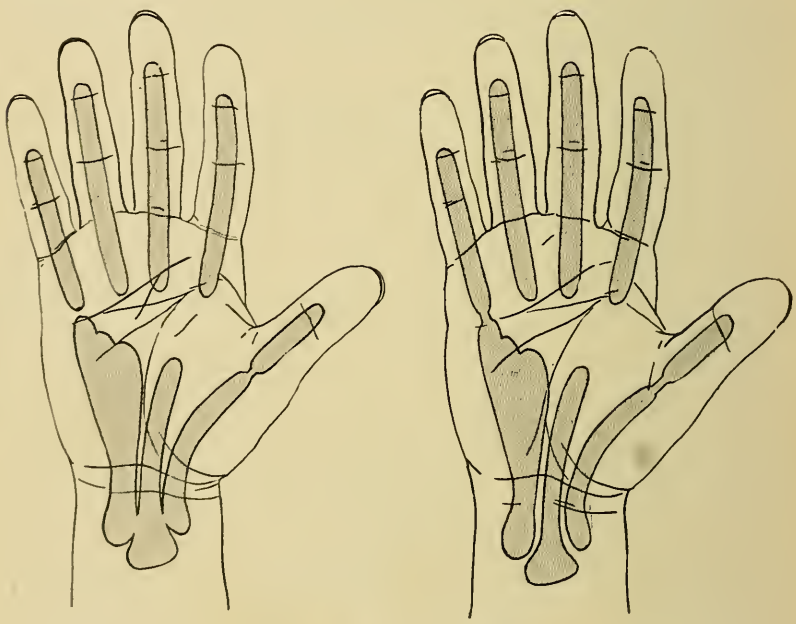

FIG. 244.—Indicating the arrangement of the synovial sheaths of the flexor tendons (*Poirier and Charpy.*)

Cutaneous Felon.—The cutaneous felon usually appears clinically as a bullous inflammation of the skin. A vesicle filled with cloudy serum develops beneath the raised epidermis. This type of felon follows superficial injuries, infections, and the action of chemicals, and is usually circumscribed, but in children the process may extend to involve a considerable part of the finger.

After removal of the raised epidermis with scissors and evacuation of the serum or pus the reddened corium is exposed. Healing usually takes place readily if a simple protective dressing is applied. It may

be necessary to keep on a dressing for a time in order to protect the delicate newly formed epithelium from injury.

Subcutaneous Felon.—Infections of the distal phalanges are common.

Subcutaneous felons are more common in men than women. Vogt's statistics dealing with 274 acute subcutaneous felons, show that 183 cases were observed in men and 89 in women. The right hand was affected 120 times and the left 82. The felon developed upon the thumb 85 times, upon the index-finger 81, upon the middle finger 58, upon the ring finger 36 and upon the little finger 8.

The infection in the subcutaneous felon gains access through punctured or incised wounds, through the glands or the blood, a contusion often providing the locus minoris resistentiæ.

As the inflammatory process develops, the terminal phalanx of the finger affected becomes hard and rigid, a small amount of swelling causing much tension because of the character of the anatomical elements entering into the formation of the terminal phalanx, previously described. Sloughing of tissues is apt to occur early.

The most prominent symptom is pain, often throbbing in character, and severe enough to keep the patient awake. Redness of the skin of the part involved may not be noted for some time after the pain has developed. Because of the tension, absorption begins early and is pronounced. There is, therefore, considerable general reaction. In the early stage fluctuation cannot be elicited. In the later stages after softening has occurred, the terminal phalanx on the volar surface may be converted into a pus pocket and if spontaneous opening occurs, one or more sinuses which discharge pus will be found. Because of the tension, the two arteries running on either side of the closed space, may be occluded, leading to necrosis of the diaphysis of the terminal phalanx (Fig. 245). The subcutaneous felon then assumes the characteristics of the osteal felon as far as treatment and prognosis are concerned.

The indications in the treatment of felons are (1) to relieve the tension in order to lessen the amount of necrosis and (2) to control the pain and general reaction. An early incision should, therefore, be made into the inflamed area. The incision should be lateral to avoid leaving a scar over the site of the tactile portion of the finger and so possibly impairing the delicate functions of the part. A lateral incision also gives better drainage because it divides the connective-tissue septa.

When the inflamed part is incised early recovery usually ensues without much loss of tissue or impairment of function.

In neglected cases with discharging sinus, dilatation of the sinuses or their union by incision will be required. Separation of the necrotic tissue takes place rather slowly and from time to time removal of small masses of necrotic tissue may be required. The removal of dead bone will be discussed under osteal felon.

After incision a hot dressing of boric acid or acetate of aluminum should be applied and the hand elevated to lessen the œdema. When the acute process has subsided a vaseline dressing may be applied.

Fig. 245.—Secondary osteal felon-infection of the tendon sheath through needle wound followed by extension of bone. (*De Quervain.*)

Osteal Felon.—Clinically an osteal felon is an acute pyogenic osteomyelitis of the terminal phalanx. Infection of the bone may take place through the blood, by extension along the spaces between the connective-tissue trabeculæ of the subcutaneous tissues or the diaphysis of the terminal phalanx may become necrotic as the result of occlusion of the vessels lying on each side of the subcutaneous compartment of the distal phalanx.

The symptoms are those associated with osteomyelitis. The pain is intense, often throbbing in character, and the local tenderness is marked. The temperature may be high and the terminal phalanx becomes red and hard. If an incision is not made, pus soon collects in the subcutaneous tissue. The abscess then ruptures through the skin, leaving a sinus lined by exuberant granulation tissue which leads down to denuded, dead bone. In the presence of dead bone the sinus will discharge until the sequestrum is removed.

The treatment consists of early incision. Lessening of the tension may save a considerable part of the phalanx. If the diaphysis is separated, as it often is in neglected cases, it may be removed by bone-cutting forceps and heavy scissors. In young children the diaphysis is often separated when the finger is incised and can be easily removed. In adults the terminal phalanx will usually be somewhat

shortened and deformed, but motion at the joint remains good, unless the latter has been involved in the inflammatory process.

Infective Tenosynovitis, Synovial Felon, Suppurative Tenovaginitis.—Infection may reach the tendon sheath through punctured or infected incised wounds, or by any of the ordinary routes. The most common sources of infection are, however, neglected felons from which the inflammatory process extends to the tendon sheaths. As has been previously stated the anatomical arrangements of the tendon sheaths favor the extension of the inflammatory process. The flexor tendons of the thumb and little finger communicate with those of the palm and wrist, while the sheaths of the tendons of the remaining flexors have no such connection. As a result of this arrangement infections of the sheaths of the flexor tendons of the thumb and little finger can spread unopposed beneath the annular ligament, and when rupture through the bursa occurs may spread over the entire forearm between the muscle planes.

Kanavel states that the three cardinal symptoms and signs are:

1. Excessive tenderness over the course of the sheath and limited to the sheath. This symptom is by all odds the most important.

2. Flexion of the fingers.

3. Excruciating pain on extending the finger most marked at the proximal end.

It is sometimes difficult to diagnose infective tenosynovitis, but if the sheath is involved, pressure upon it throughout its course causes an immediate and involuntary expression of pain. If the tenderness is outlined by the extent of the sheath, a positive diagnosis can be made, according to Kanavel. When the synovial sheaths of the wrist are affected the resistant annular ligament gives the swelling a dumb-bell-shaped appearance and the skin above the ligament becomes reddened, tense, œdematous, and pressure elicits marked tenderness. The wrist is usually slightly flexed. Lymphangitis is not an infrequent accompaniment and the lymphatic nodes into which the inflamed lymphatics drain, become enlarged and tender. The constitutional symptoms may be severe. This is especially true in streptococcic infections which spread rapidly and often break through the sheaths when those of the thumb and little finger are infected to spread along the intermuscular septa of the forearm. The temperature may reach 103° or 104°F., the pulse is rapid and the patient may be delirious or stuporous. These symptoms may continue for some hours.

The accompanying description and figures of incisions employed

in tendon-sheath infections are taken from Kanavel's book on Infections of the Hand.

"The first incision is made at the site of known infection, opening the sheath at the side and not in the median line, cutting the length of the shaft of the proximal or middle phalanx, leaving the part over the articulation uncut, unless there is doubt as to the freedom of drainage, so that the tendon does not prolapse (Fig. 246). Make the incision too free rather than too small. In those cases where it has seemed advisable to incise the length of the sheath, and I do this in case of doubt, I have bound the finger out in an extended position to prevent prolapse of the tendons. After having opened the sheath at one point, pressure upon its various parts will give some idea of the extent of the invasion. If it is complete, as is generally the case, a similar incision is made over the uncut proximal or middle phalanx. No incision is necessary, as a rule, over the distal phalanx. Over the proximal end of the sheath,

Fig. 246.—Lines of incision to be employed in treating felons, palmar abscesses and synovial sheath infections. (*Kanavel.*)

at the base of the palm, the technique will vary according to the extent of the invasion. If early, the incision is made over the middle of the sheath, at its end in the palm, carrying it from the flexion crease at the base of the proximal phalanx for about ¾ in. into the palm. If, however, there is some question whether the lumbricular spaces at the sides have begun to become involved, the incision is made upon the side most affected, opening the space at the tendon sheath at the same time. If both sides are involved, two incisions are made. If the amount of pus is great, a second line of incisions is made upon the opposite side of the finger, over the two proximal phalanges, by inserting the knife blade through from the incision already made on the one side. If there is much involvement of the synovial surfaces, or if there is much œdema of the finger, which would tend to close the incisions, I connect the first two incisions made, thus making one

incision the length of the finger, rather than multiple incisions on both sides of the finger."

The incisions to be employed when the ulnar and radial bursa are involved are indicated by the accompanying figures.

Lack of space forbids extensive discussion, but the following is deemed necessary. Kanavel states that when the continuation of the sheath of the little finger in the hand is involved, that the palmar portion should be opened by an incision extending from the base of the finger at the distal flexion crease of the palm and passing toward the base of the palm. It is his custom to insert a grooved director in the sheath at this point and follow along this, cutting the tissues between the sheath and the surface, having in mind to avoid the tendon and cut as far to the ulnar side of the sheath as possible, since there will be better drainage, particularly at the wrist, if this is done. After the annular ligament is reached, pressure above over the prolongation of the sheath in the forearm will pour pus downward into the sheath below the ligament if the infection has extended here, as it generally has.

If a diagnosis of involvement of the prolongation of the sheaths above the annular ligament or of the intermuscular spaces of the forearm is made, Kanavel proceeds as follows: At a point about 1½ in. above the tip of the ulna an incision is made directly down on this bone on its flexor surface; an artery forceps is now thrust across the flexor surface of the ulna and radius until it impinges on the skin of the radial side, where it is cut down upon. The incisions in the skin are now enlarged to the length of 1½ in. or more and the artery forceps opens the subtendinous area to the same extent. Make the incision too long rather than too short, since a large incision with free drainage will heal more quickly than a small incision without adequate drainage. Special care should be used here to make the incision neither too far upon the flexor surface nor dorsally, since in the first instance, especially upon the radial side, the artery may be injured either by the incision or subsequent necrosis. Having opened this area, the finger is now inserted under the flexor profundus tendons, and if there is any infection of the sheath it bulges and can be opened easily.

When these incisions are made no drainage material is necessary in a majority of cases. At times small strips of gauze saturated with vaseline are used. Rubber drainage tubes should be dispensed with for they are apt to interfere with the integrity of the tendon.

In treating inflammation of the tendon sheath of the long flexor

of the thumb, Kanavel dissects down to the tendon upon the flexor surface of the proximal phalanx; after entering the sheath the incision is enlarged along the sac through the thenar eminence, separating the muscular mass (heads of the flexor brevis pollicis). It should be remembered that the tendon lies nearer the palm than one would think and that the mass of thenar muscles lies to the radial side of the incision, which should be carried up to within a thumb's breadth of the lower border of the annular ligament. The incision is ended at this point to avoid the motor nerve to the muscles of the thenar eminence which passes across the sheath between this point and the lower edge of the anterior annular ligament. Drainage of the upper end of the radial bursa is best carried out by the methods described above when discussing drainage of the upper end of the ulnar bursa.

In cases in which drainage has not been established early necrosis of the tendon is apt to occur. The sinus continues to discharge until the swollen, soft tendon, which has lost its luster, is removed. Space does not permit of a discussion of the Bier hyperemia treatment and the after-treatment to be employed in these cases. Bier's hyperemia may be used to advantage after the sheath has been incised, but the first indication in treatment is free incision to provide good drainage.

Subungual Felon, Paronychia, Run-around.—Subungual felon begins as an inflammation of the skin surrounding the nail. The infection usually takes place in a fissure, scratch or hangnail, often developing after manicuring. The skin at the edge of the nail becomes reddened, swollen and painful. The inflammation may then spread around the base of the nail, forming the typical "run-around." Pus collects beneath the skin and when the infection spreads beneath the nail, the latter becomes raised from the subjacent matrix and pus can be expressed by pressure over the base. The discharge of pus continues until the dead portion of the nail is removed.

The infected areas should be incised. If the nail base is not yet infected, recovery will take place. When pus has accumulated beneath the nail, free drainage must be established. A hole in the nail does not usually permit of free enough drainage to control the infection quickly.

Kanavel gives the following description of the method to be employed in these cases. This method provides free drainage and does not interfere with the regeneration of the nail.

A longitudinal incision is made along the outer edge of the nail, going back to the base as far as the sulcus, exercising special care to

cut to the outer side of the nail so as not to cut the nail bed or the overhanging cuticle which may result in a permanently split nail when the new one develops. The eponychium is now pushed back with a sponge and the point of a sharp scissors inserted under the detached edge of the nail and this is cut off together with as much of the root of the nail as has become separated from the matrix by pus. After removing this portion of the nail the elevated flap of overhanging cuticle is packed up and out of the field by a small strip of gauze saturated with vaseline for a few days to favor drainage.

In those cases in which more than half of the base is involved a second incision should be made upon the opposite side, which should avoid the nail bed and the overhanging cuticle. The eponychium should now be pressed back and elevated to expose the entire sulcus. In these cases the entire root of the nail will often be found to be necrotic. The necrotic portion should be removed but it is not necessary to remove the distal part which remains attached to the matrix. The new nail usually forms rapidly and pushes out the old nail in front of it.

Exuberant granulations develop in neglected cases in which insufficient drainage has been provided and the necrotic part of the nail has not been removed. This rapidly disappears as a rule after adequate treatment has been instituted.

Palmar Abscess.—Palmar abscesses are most often secondary to neglected suppurative tenosynovitis. They also follow punctured wounds, lymphangitis and contusions, the last reducing the resistance of the tissues and thus favoring the growth of bacteria. The palmar fascia is so firm that there is always considerable tension with a palmar abscess and the pain is usually severe. There is usually considerable œdema of the loose tissues of the back of the hand, and in some cases one may be misled as to the seat of the focus, because the signs are so pronounced upon the back of the hand. If not recognized and opened, the signs of an inflammatory process become marked, the pus gradually reaches the surface, and ruptures externally between the fingers. Often free discharge of the abscess is prevented by pieces of necrotic tissue.

In early cases when the symptoms are not urgent, hot dressings may be applied. When pus has formed incision should not be delayed. In opening palmar abscesses the incision should be made in the long axis of the hand in order to avoid injury of the tendons. The palmar arch may be avoided by making the incision distal to a horizontal line drawn across the palm at the level of the web of the thumb. After the incision

has been made into the abscess, the opening may be increased in size by passing an artery forceps into the abscess and withdrawing it with opened blades. Twisted pieces of gutta-percha, vaselinized gauze, or split tubes, may be used for drainage. Hard tubular drains should not be used. Hot boric acid dressings may be used to advantage at first, but as the purulent discharge becomes less, a dry or vaseline dressing may be applied.

Bier's passive hyperemia may be used to advantage after the abscess has been evacuated. There has been considerable discussion as to the value of this method in the treatment of infections, and it is the opinion of many surgeons that it is of distinct value after an incision has been made to evacuate the pus and relieve tension, but that it should not be employed without the preliminary incision.

If the tendons are effected, great care must be exercised to prevent adhesions and contractures. Each joint involved must be moved either actively or passively at frequent intervals after the acute symptoms have subsided.

Gonorrhœal Tenosynovitis.—An acute metastatic inflammation of the tendon sheaths may develop during gonorrhœa. It may occur at any time from the third week to the third month of the disease. Instrumentation of the urethra or injury caused by the injection of strong astringents or by local applications are usually the predisposing factors, as they provide the atrium by which the bacteria gain access to the blood.

The symptoms of gonorrheal tenosynovitis are usually acute, the pain being severe and the œdema extending to the adjacent soft parts and even to the muscles. One or more joints may be affected at the same time. The diagnosis is usually easily made, as this type of acute tenosynovitis frequently develops in healthy young males having gonorrhœa or giving a history of the same. Examination often reveals a urethral discharge.

Aspiration of the sheath followed by injection of 2 per cent. formalin in glycerin gives brilliant results in many of these cases. The fingers should be immobilized in extension during the acute process and from a week to 10 days following the injection. When the acute symptoms have subsided the immobilizing dressings should be removed and active and passive motions instituted in order to prevent adhesions.

Tuberculous Tenosynovitis.—Infection of the tendon sheaths may occur by way of extension from a tuberculous focus in neighboring bones or through the blood. The synovial sheaths of the flexor tendons of the hand, especially the sheaths of the flexor sublimis and profundus digitorum, are more frequently involved than are those of the extensor tendons; of the latter the sheath of the long extensor of the thumb is most frequently affected.

Single tuberculous hydrops is rare. Usually there is but a small

amount of fluid in the sheath, or it is marked only in the early stages of the disease. The greater part of the swelling is made up of tuberculous granulation tissue and rice bodies which may be free in the sheath or attached to the synovial sheath or the fibrillated tendon. The free bodies are formed by coagulation of the effusion which has a high albuminous content. The coagula as they are moved about by the motions of the tendons become oval and assume peculiar shapes. They vary in size from a millet to a melon seed. Any of the types of tuberculosis which have been mentioned in discussing tuberculosis of the joints may occur in tendon sheaths. In some cases there is considerable fluid with little fibrin, while in others tuberculous granulation tissue, rice bodies and villus-like growths predominate. The tendency of the exudate to coagulate and form rice bodies is peculiar to a tuberculous process.

FIG. 247.—Tuberculosis of the flexor tendon sheaths. Hour glass swelling with distention of ulnar bursa. (*De Quervain.*)

As the inflammation in the sheath progresses an hour-glass swelling forms, the constriction being caused by the annular ligament. If there is hydrops or considerable fluid the latter can be found by pressure from the swelling in the palm into that above the wrist and *vice versa.*

The swelling is of doughy consistency and a peculiar grating or creaking sensation is imparted by palpation or when the tendons are brought into play. The disease ordinarily pursues a long clinical course with but few symptoms. The power of the hand is usually somewhat reduced. At times nervous disturbances occur due to pressure, especially upon the median.

Secondary pus infections may occur which add to the gravity of the prognosis. Tuberculosis of the sheath of the flexor tendons is

easily diagnosed. The hour-glass swelling (Fig. 247), doughy consistency and peculiar grating or creaking sensation imparted to the palpating hand are quite characteristic. The fingers are usually slightly flexed, but the hand is not in volar flexion as is the case when the wrist-joint is involved.

If hydrops predominates, the sheath may be aspirated and injected with 2 per cent. formalin in glycerin or iodoform and glycerin emulsion. Hydrops is rare in this type of tuberculosis and incision of the bursa with removal of the rice bodies and tuberculous granulation tissue, followed by iodoform glycerin emulsion, or total excision of the diseased sheath, are the procedures that are usually required. Left alone, tuberculous tenosynovitis has but little tendency to undergo spontaneous cure and the swelling increases and the functional disturbances become more marked. If the process extends to the skin and ruptures externally, the swelling decreases in size, and the patient may be perfectly contented to live with discharging sinuses. The connective-tissue proliferation in adults is not marked and the results obtained by iodoform glycerin are not to be depended upon. Total excision of the tuberculous sheath is necessary in some of these cases. Complete restoration of function occurs in many cases even after complete removal of the sheath.

There is still some doubt as to the nature of an interesting lesion which is occasionally found in the tendon sheaths of the fingers. This has been regarded as a myeloma or giant-cell sarcoma, but in all probability it is a granuloma. The lesion is most frequently observed in the tendon sheaths of the fingers, the flexor being more frequently affected than the extensor sheaths.

The masses which develop vary in size within wide limits. In the sheaths of the fingers they vary in size from a pea to a hazelnut. In the palm of the hand they may become larger and sometimes extend into the forearm, occupying the lower half of the same, without presenting any evidences of malignancy.

The surface of the mass is usually lobulated and when cut it has a characteristic color which is imparted to it by the lipoid contents of the cells. The mass is usually ovoid (it may be round) and is elastic. As pseudo-fluctuation may be elicited, errors in diagnosis are common, the lesion being often regarded as a ganglion.

Clinically this lesion is benign. The mass enlarges slowly and after years may be no larger than a hazelnut or pea. The surrounding tissues are never infiltrated. The mass may lie beneath the skin and in these cases the sheath is usually so thinned that it is recognized with difficulty and the mass may have prolapsed between its bundles. Glandular enlargements do not occur.

The masses are lobulated and often multiple and there have been many so-called recurrences after operation. These are probably not true recurrences but due to isolated pieces of tissue left at the operation that have continued to grow.

Concerning the pathogenesis but little is known. In many cases there is a definite history of trauma. This seems to play the most important part etiologically.

This lesion is benign, and there are no cases recorded in which the process has extended

to surrounding tissues. Neither glandular nor visceral metastases are observed. The treatment consists of extirpation of the tissue. Amputation should never be performed for these granulomas.

MALHERBE: Revue de Chir., 1896.
STIEVE: H. Ziegler's Beitrage, 1912.
FREE: Bull. de la Soc. Anat de Paris, 1888.
PELHIT: Bull. de la Soc. Anat. de Paris, 1893.
CZERNY: Arch. f. klin. Chir., Vol. X, p. 904.

Aneurisms.—Spontaneous aneurisms of the vessels of the upper extremity are relatively rare, as is indicated by the various statistics which have been published.

Holcombe, at the suggestion of Matas, compiled the statistics of aneurism as recorded at the Charity Hospital of New Orleans during the decade from 1896–1905 inclusive. During this period 81,242 patients were treated, of whom approximately 30 per cent. were colored. One hundred and seventy-two cases of aneurism were observed. They were distributed over the various arteries of the body as follows: thoracic aorta, 70; abdominal aorta, 36; popliteal, 21; femoral, 10; innominate, 9; subclavian, 8; common carotid, 5; external iliac, 2; brachial, 2; axillary, 2; vertebral, 1; ulnar, 1; radial, 1; cœliac axis, 1; splenic, 1; occipital, 1; temporal, 1. Statistics published from other hospitals and clinics, show the same relative involvement of the different vessels, and indicate the relative infrequency with which the vessels of the upper extremity are affected.

Aneurism is essentially a disease of adult life, the greatest incidence occurring between the fortieth and fiftieth years but it has been observed in young children. Schmidt observed an aneurism of the radial artery in an infant eight weeks old, and aneurisms of other vessels in children aged seven and 10 years have been published. In the discussion of mycotic aneurisms it will be shown that aneurisms of this type may occur at an early age, and it is possible that some of the aneurisms observed in young children should be placed in this group, the source of the infected embolus having been overlooked. Arterial aneurisms are much more frequently observed in the male than female sex. According to Matas 78 per cent. of arterial aneurisms are observed in men who are addicted to the use of alcohol or tobacco, or are suffering with syphilis or some other infection or toxemia, all of which tend to produce arterial degeneration, the precursor of aneurism formation. The fact that men are more frequently subjected than women to those conditions which cause arterial degeneration, accounts for the much greater frequency of arterial aneurism in the former. Loss of elasticity of the arterial wall, induced by infectious diseases or toxemias which cause degeneration of the middle coat of the vessel, is the important factor in aneurism formation. Increased sudden muscular effort may cause rupture of the vessel wall. Aneurism is, therefore, most often found in persons whose muscular system is still vigorous, but in whom arterial degeneration has occurred. They are most common in day laborers, soldiers, porters and in men whose occupations demand sudden and vigorous muscular movements.

Fusiform, saccular and cylindrical aneurisms are described, the classification being based upon the form of the dilatation. Cirsoid aneurisms or aneurisms by anastomosis will be considered in the section dealing with angiomas.

The wall of a saccular aneurism is composed of fibrous tissue, derived from the adventitia and the adjacent connective tissues, which have become condensed and fused together. Lining the sac is a layer of flat endothelial cells formed by a proliferation of the endothelium of the parent vessel. The middle coat of the vessel does not form a part of the sac, and while in the early cases remnants of the middle coat may be found, they soon disappear.

The diagnosis of aneurisms of the arteries of the extremities can usually be made without much difficulty, unless they are very small and deeply situated. The swelling is elastic, soft and compressible. When the fingers are placed upon such a swelling, an expansile pulsation can be made out. This is characteristic and an important point in differential diagnosis, for enlarged glands and inflammatory foci lying closely adjacent to a vessel are raised with the systole, but undergo no symmetrical distention. A peculiar purring sensation is elicited when the fingers are placed upon the sac. Upon auscultation a murmur synchronous with the arterial pulse is heard. This aneurismal bruît is usually hard, rather than soft, and is rarely transmitted along the affected artery. When pressure is made upon the principal vessel proximal to the aneurism, the tumor decreases in size and the peculiar purr and the bruît disappear. The reduction in the size of the swelling, with disappearance of expansible pulsation, purr and bruît, is the most characteristic of all the signs of aneurism and is pathognomonic. In spite of the fact that the signs associated with aneurism are so definite and characteristic, difficulties are sometimes experienced in differential diagnosis. If the sac is filled with clots the pulsation may be wanting or insignificant and the mass may be regarded as an abscess, but in such cases there is no fluctuation. Soft sarcomas of bone, which are spoken of as bone aneurisma, are well supplied with arteries, have distinct pulsation and increase in size with systole. These so-called bone aneurisma are soft, rapidly growing sarcomas, rich in arterial blood supply, and their position, together with the X-ray findings, should enable one to differentiate without much difficulty between them and true aneurisms.

Traumatic Aneurism.—In punctured, gunshot or lacerated wounds of arteries, in which the cutaneous wound is small, the tract tortuous, or the skin remains intact, a hematoma forms in the tissues adjacent to the opening in the vessel wall. Soon the blood upon the periphery of the hematoma coagulates and the surrounding tissues proliferate and become thickened to form the sac of the aneurism which is composed of none of the tunics of the vessel wall. Eventually, however, the blood clot, forming part of the sac in the early stages, becomes covered by endothelium from the vessel. This type of aneurism is called the false traumatic. The sac composed of thickened connective tissue lined with clots becomes continuous with the adventitia of the parent vessel at the opening caused by the injury. A true traumatic aneurism is formed when the walls of a vessel are but partially destroyed.

An injury (stab, gunshot or crushing wound) may destroy the adventitia and media and thus the endothelial coat may bulge out and aneurism result.

Axillary aneurisms constitute 3 per cent. of arterial aneurisms. They are frequently of traumatic origin and may follow stab and gunshot wounds, efforts at reduction of old dislocations, or complicated fractures of the clavicle, shoulder blades or ribs. The aneurism that forms usually occupies the upper or lower part of the axillary fossa, encroaching above upon the subclavian artery, or being found below at the edge of the pectoralis major at the beginning of the brachial artery. The middle segment of the axillary artery is rarely involved. An aneurism occasionally develops upon the branches of the vessel. Aneurisms of the brachial, radial and ulnar occur but are rare. They are more often traumatic than spontaneous and present the symptoms already mentioned.

If after a punctured wound of the axilla, large hematoma forms, an injury of the artery is probable. If the artery has been completely divided no pulse or bruit will be heard, while if but part of the vessel wall has been involved the pulse can be felt, but its character will be altered and a bruit will be heard.

Axillary aneurisms may give rise to marked symptoms, for as they enlarge they may press upon the brachial plexus, causing severe radiating pains down the arm. An axillary aneurism may also compress the axillary vein causing swelling and cyanosis of the arm. As the sac enlarges it may erode ribs or clavicle and fatal hemorrhage into the pleura after erosion of the ribs is possible from rupture of an axillary aneurism.

No difficulty is experienced as a rule in making a diagnosis of traumatic aneurisms. The development of a pulsating or arterial hematoma, following a wound adjacent to a vessel or subcutaneous injury is suggestive enough to warrant a positive diagnosis.

Collateral Circulation.—There are usually given off from an aneurismal sac a number of vessels which vary in size. These correspond to the vessels which normally arise from the segment of the parent trunk from which the aneurism has developed. If the aneurism is old and filled with clots the vessels may be occluded at their points of communication with the sac. These vessels usually, however, communicate freely with each other, with the parent vessel above and below the point of dilatation, and with the vessels of the tissues bordering upon the sac, and form a perianeurismal network. This network is

of great importance, for it may carry on the circulation after occlusion of the main vessel, thus preventing gangrene. It also may be the cause of recurrence of the aneurism after ligation of the main vessel, for the blood may come back into the sac through the vessels entering into the formation of this plexus.

Medical treatment is rarely employed to any extent in handling spontaneous aneurisms of the extremities. Potassium iodide may be given to advantage in some cases, especially in those in which a history of a syphilitic infection is given. The risks of ligation of the principal vessel are hemorrhage and gangrene. The former is rare at the present time, because refinements in surgical technique have greatly reduced the number and severity of infections. As a collateral circulation is readily established in the upper extremity, gangrene rarely follows ligation of the principal vessel, providing a careful, clean dissection, which avoids the vessels entering into the collateral circulation, is made when the vessel is exposed.

The operations usually employed at the present time are proximal ligation (Hunter), the ligature being placed at a distance from the sac, one branch at least existing between the point at which the ligature is applied and the sac; endo-aneurismorrhaphy (Matas) (obliterative or reconstructive); and excision of the sac. In small aneurisms excision is followed by circular suture of the vessel or transplantation of a segment of a vein to fill in the defect.

Arterio-venous Aneurisms.—Arterio-venous aneurisms are usually the result of direct simultaneous injury of an artery and vein lying adjacent to each other. Occasionally the formation of an arterio-venous aneurism occurs without a preceding injury, as when a saccular aneurism erodes the wall of a vein adjacent to it and a communication is established between the artery and veins by means of a pre-existing aneurismal sac.

There are two forms of arterio-venous aneurism: (1) the aneurismal varix in which there is a direct communication between the vein and artery without an intervening sac; (2) the varicose aneurism in which there is an intervening sac, usually a false one. The condition in which the wall of the vein opposite the point of communication with the artery is forced out by the arterial pressure to form a sac is spoken of as a varix aneurismaticus.

Bramann's statistics dealing with 159 cases of arterio-venous aneurism, show that 108 were due to injury; that 56 followed phlebotomy; that 29 were caused by gunshot wounds; that 5 followed contusions in which there were no external wounds, and that 9 were spon-

taneous. Bramann's and Delbet's statistics show that the vessels are involved in arterio-venous aneurism in the following order of frequency; brachial; femoral; popliteal; carotid arteries of the head, especially the temporal; subclavian and axillary.

In earlier times the bend of the elbow was the favorite site for the development of arterio-venous aneurism, a communication being established between the brachial artery and median basilic vein during phlebotomy. This type of aneurism is not so common now, for bleeding is not so frequently practised when it is and the vein is usually carefully isolated and thus injury of the artery avoided.

As a result of a communication being established between an artery and a vein, the arterial blood is poured into the latter. The vein become dilated, elongated and varicosed. Pulsation occurs in the vein and a distinct bruît is transmitted which is heard, in some cases, over the entire extremity on both sides of the point of communication. In an arterio-venous aneurism at the bend of the elbow the bruît may be heard over the arm or in the axilla. The extremity may be more or less swollen as the venous return is interfered with.

An aneurismal varix is not especially dangerous, but the enlarged veins, the disagreeable bruît and imperfect nutrition of the part may demand some surgical interference. The sac of a varicose aneurism may rupture, although this danger is not as great as in spontaneous aneurism.

As aneurismal varix has no tendency to rupture, it is not a source of danger and in many cases causes the patient little or no annoyance. As there is some risk associated with surgical interference, especially when the varix is situated about the upper parts of the extremity, a conservative treatment is indicated.

When an arterio-venous wound is received, it should be treated conservatively unless there are symptoms suggestive of progressive hemorrhage, when surgical interference is indicated. The tendency of these wounds is to undergo involution rather than evolution and after the wound in the skin has been properly attended to an immobilizing dressing should be applied and firm pressure carefully made over the point of communication.

If surgical interference is later indicated, the procedures vary according to circumstances. Treatment recently has changed considerably as the result of refinements in arterial suture. The earlier treatment advised for aneurismal varix was ligation of both artery and vein just above and below the point of communication. When a larger vein was involved, as for instance the axillary, it was advised

to tie the artery above and below the point of communication, with any branches arising from the main trunk between the points at which the ligatures were placed, and to leave the vein alone, as interference with both the large artery and vein of an extremity might lead to a distressing œdema or gangrene.

When hemostasis can be obtained, the ideal operation for aneurismal varix is exposure of the vessels at the point of communication, with division of the connecting channel, followed by suture of the opening in the vessels, thus restoring the lumina. A simpler operation is ligation of the connecting channel after the varix has been carefully exposed.

A varicose aneurism may rupture, although this tendency is not so marked as in spontaneous aneurism. Progressive enlargements of the aneurism, development of marked varicosities, œdema, or nutritional disturbances, constitute an indication for operation.

The earlier operations advocated for varicose aneurisms consisted of quadruple ligature with extirpation of the sac. This operation was attended with considerable danger to the limb as both vascular channels were interrupted. The operations which preserve one of the vessels are to be given preference and the plan of procedure will vary according to the case.

Matas, in his article appearing in Keen's Surgery, summarizes the treatment of arterio-venous aneurism as follows:

"1. Arterio-venous varices (simple aneurismal varices), more especially of the neck and upper extremity, should not be disturbed or interfered with surgically as long as they do not cause annoying or menacing symptoms or functional disability.

"2. Shortly after injury efforts should be made to favor spontaneous cure by gentle pressure over the anastomosis and on the main artery on the proximal side of the anastomosis (Vanzetti's method), or by simple digital compression of the main artery on the proximal side, rest and immobilization.

"3. When signs of progressive enlargement of the tumor (in varicose aneurisms) and other objective and subjective evidences indicate that operative interference is required to arrest its progress, that procedure should be preferred as the method of election which will obliterate the arterio-venous anastomosis without interrupting the continuity of the parent vessel, endo-aneurismorrhaphy for varicose aneurisms; incision with lateral arteriorrhaphy and phleborrhaphy for the simple aneurismal varices.

"4. When the damage done to the vessels is so great that restoration of the lumen is impossible by any of the methods of intrasaccular suture (restorative and reconstructive endo-aneurismorrhaphy), obliterative aneurismorrhaphy is to be preferred for old well-formed sacs; the intrasaccular ligature on each side of the vascular orifices (Syme, Annandale, Kikuzi) for recent, thin and ill-defined sacs and traumatic pulsating hematomata.

"5. In some aneurismal varices, which are embedded in masses of cicatricial or fibrous tissue too dense to permit of a clean dissection of the vessels entering into the anastomosis, resection of the anastomosis may be necessary, with ligation of the afferent and efferent trunks. In such cases an effort should always be made to restore the continuity of the vessels or of the artery, at least, by circular or end-to-end suture."

The technique of the Matas operation will be found in books devoted to operative surgery (Binnie, Bryant, Cheyne, Burghard).

Mycotic Aneurisms.—During the course of endocarditis or some of the infectious diseases, aneurisms may develop. These aneurisms are usually due to the lodgment of infected emboli at the point of bifurcation of the vessel or in the vasa vasorum. Aneurisms of this type are most common in the cerebral and mesenteric vessels, where they are often unrecognized until the symptoms of hemorrhage into the brain or abdominal cavity develop. Lewis and Schrager have analyzed the reports of 97 cases of embolic aneurism. The arteries of the upper extremity were involved in 12 cases. Eight of these aneurisms occurred in the brachial artery, two in the ulnar, one in the axillary and one in the radial. The aneurism usually develops at the point of bifurcation of the vessel or at the point where a large branch is given off. The embolus lodges on the intima, and there is gradual erosion of the wall with the formation of an aneurism occurring as the inflammatory process extends outward. In one instance a sharp calcified embolus was found in such an aneurism, the latter probably being caused by injury to the intima from the sharp point of the calcified embolus.

Mycotic aneurisms usually develop suddenly in patients suffering from endocarditis or some infectious disease and are but incidents in the general course of the disease. The prognosis is bad, as most of the cases terminate fatally, death being due to the original disease.

Operative interference is necessary in most cases to relieve pressure symptoms or to prevent hemorrhage. Proximal ligation is the operation of choice as in aneurism of the peripheral arteries it can generally

be performed away from the infected area and under local anæsthesia which is necessary because of the poor general condition of patients with mycotic aneurism.

Surgical Treatment.—Formerly one of the main dangers of ligation of arteries for aneurism was secondary hemorrhage. Since the introduction of asepsis, secondary hemorrhage is rarely encountered. Whether or not gangrene will develop depends upon whether a collateral circulation has already been established or whether the circulation can be established rapidly enough after the ligature is applied to supply nutrition to the tissues. Disease of the smaller arteries, pressure upon or injury of the vessels arising from the artery near the aneurism during the operation, œdema of the limb and interference with the venous return may prevent or retard development of collateral circulation and cause gangrene. In those cases, therefore, in which the aneurism is very large, or in which the smaller vessels are extensively diseased, an attempt should be made to prevent the formation of large clots which form after ligation. In cases in which the circulation can be controlled readily the Matas operation is the one of choice. The reader is referred to operative surgeries for a discussion of the different methods employed in the treatment of aneurism. The Hunter and Matas operations will be described.

The Hunter operation of proximal ligation at a distance from the sac can usually be employed to advantage in the treatment of aneurisms of arteries of the upper extremity. The main trunk is ligated proximal to the sac, and an attempt is made to allow one branch of the vessel to remain between the ligature and the sac. When the vessel is ligated, pulsation usually ceases in the sac and as the blood stagnates clots form which eventually organize and result in obliteration of the aneurism. This operation does not always cure, especially when there is an extensive collateral circulation, because under these circumstances the blood enters the artery again below the point of ligation and leads to a recurrence.

There are two types of the Matas operation, viz., obliterative and reconstructive endo-aneurismorrhaphy. In the performance of either operation the circulation of blood through the aneurism must be controlled by one of the methods used in the production of an artificial ischæmia. In fusiform aneurisms the obliterative operation is indicated. Open the aneurismal sac widely; peel out of it all blood clot; with catgut stitches close the openings of all the branches arising from the sac; beginning at the bottom of the sac introduce sutures in layers

in such a manner that the walls are brought into contact and the sac is obliterated. Close the superficial wound. In the saccular aneurism the sac is opened, blood clots are removed and the edges of the opening between the vessel and sac are approximated without obliterating the lumen of the vessel. Chromicized catgut may be used for this purpose. The needle, introduced at a little distance from the margin of the opening, passes through one edge and then, grasping the opposite edge, is brought out at a little distance from the margin. A firm grasp of the tissues about the orifice is thus obtained. Another layer of sutures is then applied over the first line to fortify it. The separate vessels entering into the sac are closed and, as a final step, the sac is obliterated so that no dead space is left.

After an operation for aneurism, the limb should be wrapped in cotton or some other material to prevent loss of heat, thus favoring the development of a collateral circulation. The limb should be elevated to form the return venous flow and prevent œdema.

Gangrene.—Moist gangrene of the different parts of the upper extremity occurs in severe infections, especially those due to putrefactive bacteria. It occurs in infections with the gas bacillus and in mixed infections with different germs associated with putrefactive infections. The moist type occurs in diseases such as diabetes, in which the resistance to infection is greatly reduced. Gangrene of the upper extremity is not nearly so common as that of the lower extremity.

Dry gangrene of the upper extremity develops after exposures to high or low temperature, after injuries causing rupture of the intima and thrombosis or embolism of the main vessel. Arteriosclerotic gangrene of the fingers is not nearly so common as gangrene of the toes and foot. Dry gangrene, occurring in Raynaud's disease, will be discussed later.

Dry gangrene developing after exposure to extreme degrees of heat or cold, is secondary to changes in the intima of the arteries, accompanied by thrombus formation. The patient usually complains of more or less pain in the affected part and paræsthesias and anæsthesia may be noted as the part dries, becomes greenish black in color and shrivels.

Carbolic acid applied as a dressing, even in weak solutions, may cause dry gangrene of the part to which applied. Gangrene of the finger has developed after the application for a short while of a 1 per cent. solution of carbolic acid in the form of a compress. The idea is still quite prevalent that a dressing of from a 1 to a 5 per cent. solution of carbolic acid is a prophylactic against infection, and consequently cases of carbolic acid gangrene are still seen.

The gangrene which follows the application of carbolic acid in the form of a compress is due to an interference with the circulation of the part and is not the result of direct death of the tissue. Lysol and alcohol may have the same effect but the gangrene which follows the application of compresses containing solutions of these chemicals does not develop so rapidly or extend so deeply as that caused by carbolic acid. Alcohol compresses are often applied in the treatment of acute inflammatory processes of the fingers. Such a dressing, especially if evaporation is prevented by rubber tissue, may convert the part to which applied into a hard, dry crust. Carbolic acid when applied, extracts water from the epithelium and superficial tissues. It then passes to the blood-vessels, which, after a transitory contraction, become dilated. The blood-stream becomes slowed, the nutrition of the tissue is interfered with and, as there is no absorption, the acid collects in the tissues. Thrombosis of the vessels is probably the result and not the cause of the necrosis which occurs.

Symmetrical Gangrene (*Raynaud's Disease*).—Symmetrical gangrene occurs as an independent clinical entity or as a complication or sequela of some other disease. In some instances Raynaud's disease seems to follow exposure to cold, while in others there seems to be a definite relation between the disease and some preceding infection, such as erysipelas, scarlet fever, influenza or diphtheria, etc.

Three stages of Raynaud's disease are usually recognized: (1) local syncope; (2) local asphyxia; (3) gangrene. The changes begin with paræsthesias, formication and numbness of the fingers, the terminal phalanges of which become pale and cold. The attacks are usually paroxysmal. Pain, affecting especially the distal parts of the extremity, is at times quite severe and may precede by some days the local syncope. The changes associated with this first stage may pass off without leaving any trace, or there may develop within a variable time a local asphyxia. Occasionally the asphyxia develops without any preceding stage of syncope. As the asphyxia develops, a bluish red discoloration of the skin confined almost entirely to the distal phalanges, appears. This discoloration finally becomes deep blue or bluish black and finally black. Gangrene follows local asphyxia if spontaneous recovery does not occur. Sometimes a local redness follows the asphyxia or it may follow the local syncope. When gangrene develops, small black spots or vesicles, filled with serum, appear upon the terminal phalanges. These may extend from the skin to the deeper tissues. When the dry crust separates, an ulcer, which heals slowly, is found. The dry gangrene may extend deeper until the entire distal phalanx or a part of the same, is mummified. A line of demarcation gradually forms and the gangrenous tissue sloughs, often leaving an ulcer, which heals slowly, unless removed by operation.

Disturbances of vision and hearing, albuminuria, glycosuria and hemaglobinuria, are sometimes noted during the different paroxysms associated with the disease.

The etiology of the disease is not definitely known. An endarteritis and endophlebitis involving the small vessels have been demonstrated in some cases. Changes in the blood-vessels and nerves, alone or combined, are usually found, but they are by no means constant.

The prognosis as regards life is good. Recurrent paroxysmal attacks may impair the general health of the patient. If the disease passes on to the terminal stages of gangrene the terminal phalanges will slough off or must be removed.

General hygienic measures should be instituted to improve the general condition of the patient. Foci of infection should be removed and any condition which might be an etiological factor should receive appropriate treatment. The affected part should be protected from cold and irritation of all forms. Dry warm air should be employed to dilate the vessels and mild massage may be indicated. During the paroxysms, when the pain is severe, morphine or some other drug may be required. When gangrene supervenes, the development of a good line of demarcation should be awaited in order to determine the degree and extent to which surgical procedures should be carried.

Phlebitis.—Inflammation of the veins of the upper extremity is relatively uncommon and occurs most frequently as a complication of infections about the hand. During the course of some of the infectious diseases, particularly typhoid, the veins may become involved. This involvement is indicated by pain in the extremity, tenderness along the course of the vein which feels cord-like, infiltration of the tissues surrounding the vein and œdema of the extremity. In all these cases thrombosis occurs and as the thrombus becomes organized the lumen of the vessel is obliterated.

Suppurative phlebitis, which is often associated with infections occurring about the hand usually begins as a periphlebitis, the inflammatory process extending to the vein from the accompanying lymphatics or from the loose cellular tissues in which it lies. If the infection is mild, suppuration does not occur and the process ends with obliteration of the vein. Inflammation of the vein may develop from within, a thrombus becoming infected. When this happens, if suppuration occurs, an abscess forms after the process has extended through the vein wall. Hemorrhage does not take place in these cases a rule for the thrombus extends to either side of the point of perforation closing the lumen of the vessel.

Inflammation of the veins of the upper extremity occurring as it commonly does as a complication of infections about the hand is usually

readily recognized. The hard painful cord which corresponds to a vein, covered by reddened skin, the infiltration of surrounding tissues and œdema of the extremity are quite characteristic.

Separation of particles of the suppurating thrombus leading to a general infection with metastases is the chief danger of suppurative thrombophlebitis. Injury to the vein, as muscular effort favors the separation. When this happens the clinical picture changes to that of pyæmia.

The inflamed vein should be protected from injury. This is best accomplished by immobilization of the extremity, which should be continued until all signs of inflammation have subsided. The extremity should be elevated to favor the return flow of blood. Hot dressings of boric acid or acetate of aluminum may be used to advantage. If the thrombus extends or the clinical picture changes to that of general infection, as indicated by repeated chills, step-like temperature and lung involvement, the vein should be divided high up between ligatures, in order to prevent more infected emboli from entering the circulation.

Brachial Neuralgia.—Neuralgia may affect all of the roots of the brachial plexus or a part of the same. It may be due to injuries, anæmia cachexia, infections, and poisonings. In many cases of brachial neuralgia there is a history of trauma. They are commonly associated with pressure from excessive callous formations, a splinter of bone, or scar, or foreign body.

When the pain is limited to or occurs over the distribution of the ulnar nerve, it may be due to a cervical rib pressing upon the inner cord of the plexus, as it passes up over the rib. In these cases there are usually muscular atrophies, the interossei being most involved and there are also sensory and vasomotor disturbances.

The pain is paroxysmal, although some slight degree of pain may be complained of continuously. The pain is usually spoken of as lightning-like, burning, boring or cutting. When the paroxysm comes on, the patient instinctively grasps the arm and holds it in a position which relieves any pressure or tension. Sensory and vasomotor disturbances usually accompany the neuralgia. Hyperæsthesia of the skin is usually noted in the early stages, later there may be hyperæsthesia. Pallor or redness of the skin as well as sweating and herpes may be noted.

Painful points over the plexus, where the nerves rest upon bones or where the sensory nerves leave fascial canals, are usually present.

Pressure over these points elicits pain and usually paræsthesia over the area of distribution of the nerve pressed upon. These are so distinct that the patient is often able to define rather accurately the area of distribution of the nerve affected.

In differential diagnosis especial care must be taken to exclude lesions of the cord and its roots.

The most important of the partial paralyses of the brachial plexus is the combined shoulder and arm type, known as Erb's palsy. The muscles constantly involved in this type of paralysis are the deltoid, biceps, coracobrachialis and brachialis anticus. Frequently the supinator brevis, at times the infraspinatus, and more rarely the subscapular are affected. This type of paralysis is due to a lesion of the fourth and sixth cervical roots or to the outer trunks of the plexus which is formed by the union of these roots.

Direct trauma is a frequent cause of this paralysis. This type of paralysis may also follow forced abduction of the arms, combined with extension and outward rotation. By this motion the plexus is pinched between the clavicle and the first rib, although it was thought at one time that the plexus was compressed between the clavicle and the transverse processes of the vertebra.

Undoubtedly in some of the cases which come under the head of Erb's palsy the roots are torn off from the cord within the spinal canal, the nerves being stretched by a fall upon the shoulder. The same type occurs in birth palsy, during anæsthesia, and in laborers who carry weights upon the shoulders.

The arm cannot be abducted. At times it can be carried forward somewhat. This is apparently due to a partial innervation by the anterior thoracic nerves. The forearm is extended because of loss of function of the biceps, brachialis, and brachialis anticus.

The sensory disturbances vary. In many cases sensation is intact even in the territory supplied by the circumflex nerve, or if there has been an anæsthesia it has been overcome by the overlapping of sensory fields.

Attempts have been made to differentiate between radicular and plexus palsies even between intra- and extravertebral radicular palsies. In the intravertebral upper radicular palsies, the levator anguli scapulæ, the rhomboids and serratus anticus are involved, while in extravertebral lesions they are not. According to Oppenheim this differentiation is not practicable.

The prognosis naturally depends upon the lesion, whether lacera-

tion or contusion of the nerve trunks. The prognosis seems to be much more unfavorable than in peripheral lesions. Nerve suture and nerve transplantation have been attempted without much success. Muscle transplantation in persistent paralyses has been attempted with fair success, the triceps being transferred to the biceps and the trapezius to the deltoid. In paralysis of the deltoid the pectoralis major, if intact, may be detached from the sternum and clavicle as far as the point at which the anterior thoracic nerves enter. The muscle thus freed may then be sutured into the spine of the scapula so that it has an origin corresponding to that of the deltoid.

Lower radicular brachial palsy (Klumpke's palsy) is less common than that just described. This type of palsy is due to involvement of the eighth cervical and first dorsal nerves or to the part of the plexus formed by them. It is caused by tumors of the first rib compressing the roots, by gunshot wounds, laceration of the roots, syphilitic meningitis, etc.

The small muscles of the hands are paralyzed and a part of the muscles of the forearm, mostly the flexors. The extensors are affected only when the seventh cervical root is affected. Sensory changes, on the inner side of the arm and along the course of the ulnar nerve are usually noted. If the roots are injured proximal to the point at which the rami communicantes are given off, changes in the pupil and motor disturbances of the neck and face on the side of the lesion will be found.

Traumatic Epithelial Cysts.—These cysts are found most frequently upon the flexor surface of the fingers and palm, lying upon the sheath of the flexor tendons or upon the palmar fascia. (Figs. 248 and 249.) They are small, never becoming larger than a cherry. They are not firmly attached to the surrounding tissues and can be easily displaced. They present all the physical properties of cysts, being smooth, easily displaced and fluctuate. Experimentally similar cysts have been produced by transplanting small pieces of skin into the subcutaneous tissues. This transplanted skin becomes surrounded by connective tissue which cannot become fused with the epithelium; a small space forms between the connective tissue and squamous epithelium and becomes filled with desquamated cells. This space is later surrounded by proliferating epithelium so that the resultant cyst has in many cases a complete epithelial lining.

There is not much difficulty in making a diagnosis. The occurrence of this cyst in the palm is quite characteristic and often, the scar resulting from the injury which displaced the epithelium, can

be found directly over the cyst. In some cases the penetrating foreign body which has displaced the epithelium is found in the wall of the cyst. The contents are similar to those found in dermoids. These cysts require complete extirpation. The operation can easily be performed under local anæsthesia.

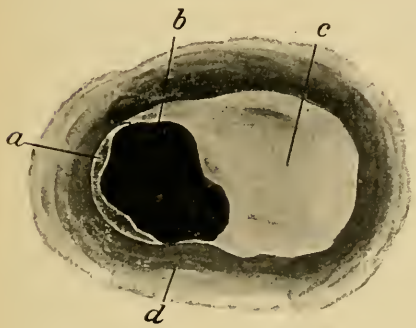

FIG. 248.

FIG. 249.

FIG. 248.—Traumatic epithelial cyst of palm of hand. *a*, Germinal cutaneous tissue; *b*, bullet; *c*, cheesy contents of cyst; *d*, connective tissue capsule with epithelial lining. (*Lexer-Bevan.*)

FIG. 249.—Traumatic epithelial cyst of index finger. (*Lexer-Bevan.*)

REFERENCES

GARIE: Ueber traumatische epithel cysten der Finger, Beit. z. Klin. Chir., 1894, XI, 524.

BENIGN TUMORS

New Growths of the Skin.—*Warts and Moles.*—A wart is a papilloma of the skin. Warts may occur singly or in groups. Groups of warts are frequently seen upon the skin of the hand where they may develop suddenly. The tumor consists of a central supporting mass of connective tissue carrying blood-vessels and a covering of stratified epithelium. These papillomatous growths are probably due to irritation as they are frequenlty found in young people, especially when the skin of the extremities is exposed to constant irritation through dirt and moisture. There are certain facts which would seem to indicate that warts are contagious for they may be transferred from one to another part of the same individual, as has been shown by Jadassohn and Lanz. Papillomas or warts are characterized by a hypertrophy of the papillæ

of the skin and, depending upon the condition of the epidermis, the surface is smooth, rough or fissured. If the veins are markedly developed or there is venous congestion, the wart may have a bluish character.

The dorsum of the hand is the favorite site for the development of warts. In some instances they are so numerous as to appear to be packed together. The ordinary wart is often single and is formed by an enlarged papilla from which projects a number of filiform processes. Groups of warts, such as are seen in young people, may disappear spontaneously. In some cases they remain for a long time without showing any tendency to disappear. In these cases they may be touched with fuming nitric acid, after which they become black, dry up and drop off, leaving a small ulcerated surface which heals rapidly.

The dark color of warts is usually due to dirt, for when cleaned the hypertrophied papillæ usually have a lemon, pink or even white color.

Senile Warts.—The senile wart is frequently a precancerous lesion. It occurs frequently upon the dorsum of the hand and appears as a small flat lesion which often becomes fissured and bleeds. A small seborrhœic crust may form upon the surface and when this is removed a bleeding surface remains. Senile warts may at any time take on active growth and develop into large pedunculated, mushroom-like growths, or the epithelial proliferation may predominate and give rise to a cutaneous horn. Any evidence of proliferative or degenerative changes in a senile wart should arouse suspicion of malignancy. If continually fissured or enlarging rapidly, senile warts should be excised together with the surrounding skin, for they are often a precancerous lesion. As they can readily be excised under local anæsthesia this is the operation of choice. Any treatment which but partially removes the growth and results in irritation of the remaining portion, is to be avoided because of the dangers of malignant degeneration.

Hemangiomas.—Telangiectases, cavernous hemangioma and the plexiform angioma may occur upon the upper extremity. They present the same features that hemangiomas present upon other parts of the body.

A diffuse dilatation of the vessels of the hand and forearm is occasionally observed which interferes seriously with function and may necessitate amputation. This type of diffuse dilatation of the vessels should probably be classified as a plexiform angioma or "aneurism by anastomosis." The vessels composing such a growth are often very

tortuous. They may be arranged more or less parallel to each other. A history of trauma can usually be elicited. A patient observed by Krause gave a history of being bitten upon the hand some years before the vascular changes were noted. The veins pulsate as the arterial wave is transmitted to them directly through the dilated capillaries. Aneurismal dilatations may develop close together upon the affected vessel so that they present the appearance of a rosary. The veins may also present varicosities but in these cases there is no abnormal communication between a large artery and vein, so that the condition is not at all comparable to an aneurismal varix.

If the dilatation remains limited to a small segment of the vessel the functional disturbance is not marked. If, however, the involvement is marked, sensory, motor and vasomotor disturbances arise and in some instances result in painful ulceration of the tips of the fingers. Cases have been noted in which the lesion resembled a malignant growth developing from blood-vessels, being characterized by rapid growth and destruction of adjacent structures. Removal of the affected vessels may be required. In some cases the dilatation is progressive, recurring after operation. Sometimes amputation has been required due to involvement of the blood-vessels of the muscles, nerves and bones. In one case the lower end of the radius was expanded, as if the seat of the tumor.

Hemangiomas of the muscles are rare. Among the 95 cases collected by Kolaczek in 1897, 27 occurred in the muscles of the upper extremity. These tumors are more common in the female than male. It is a well-established fact that cutaneous angiomas are more common in the female and the sex seems to be predisposed to angioma formation. Concerning the age incidence there seems to be no definite limits. They have been observed in children two years of age and in people of 70. They are most common in young adults. Of the 60 cases in which the age is mentioned, only seven were over 30 years of age. Half of the cases were observed during the second decennium.

These tumors are probably all congenital and they are not observed earlier because they are so deep that they attract little or no attention. The causes which excite a latent hemangioma to rapid growth are not known but mechanical irritation may play an important rôle. The involvement of the muscles of the upper extremity was as follows: pectoralis, once; latissimus dorsi and deltoid, once; teres major, once; deltoid, twice; triceps, five times; biceps, twice; supinator longus, three times; pronator teres, once; pronator quad-

ratus, once; flexors of the forearm, five times; brachialis anticus, once; muscles of the ball of thumb, three times.

It is difficult to determine the size of an angioma of the muscles, for the tumor may be situated so deeply that accurate palpation is impossible (Fig. 250). The size of an encapsulated angioma may be determined with a fair degree of accuracy, but it is impossible to determine much regarding the size of the diffuse. The smallest tumors which have been observed were the size of an almond or bean; the largest the size of a fist, goose egg or orange.

Usually an angioma of a muscle is solitary; only occasionally have multiple tumors been observed. Reboul has reported multiple angiomas in the muscles of the ball of the thumb.

Fig. 250.—Cavernous hemagioma of the flexor profundus digitorum as seen at operation. (*Kultner.*)

The symptomatology is variable and it is rarely that a correct diagnosis has been made. The initial symptoms are more frequently objective than subjective. In the majority of cases the patient notices first a small swelling. Pain is usually not present. When the tumor is so situated that it is not easily felt or seen, the symptoms will naturally be subjective. Pain, when noted, may be radiating in character, the radiation corresponding to the distribution of the nerves supplying the tissue involved. The skin covering the tumor is in most cases normal. Sometimes, especially in large, rapidly growing, diffuse muscle angiomas, the cutaneous veins may be dilated to form rather

heavy, cord-like formations in the skin. This enlargement is probably compensatory in character, permitting of increased circulation of the blood through the superficial veins, the deeper ones having been more or less compressed by the growth in the muscle.

An angioma in muscle is not sharply delimited, because of the deep situation and the consistency, which is about the same as that of the muscle. The softest angiomas have a doughy, elastic feel. All grades of consistency, from the softness of butter to the hardness of bone, have been observed and for that reason the diagnosis of cold abscess, cysts, lipomas and osteomas has been made in different instances.

Compressibility is the exception in angiomas of muscle. It is well-marked in but few cases. Careful examination may reveal some slight degree of compressibility and when found it is an important diagnostic aid. Phleboliths are of common occurrence. They appear as hard isolated nodules to the palpating finger and when present in large numbers they may give rise to a peculiar crepitation. X-ray examination may be of value for it may reveal phleboliths or calcification of the vessel walls. A correct diagnosis is exceptional. The relation of the growth to muscle can usually be determined but it is difficult to determine the nature of the growth and most often it is regarded as a lipoma, myoma or fibroma of muscle, and in some cases it has been regarded as a cold abscess.

The prognosis as regards life is good; an angioma, even if left alone, would not terminate fatally. Some angiomas, especially the diffuse forms, as previously mentioned, exhibit what might be called a local malignancy. The circumscribed forms have a capsule from which they can be enucleated or dissected out. The diffuse form infiltrates and replaces muscle, so that the muscle must be sacrificed when an attempt is made to remove the growth. In some cases the greater part of the extremity has been converted into angiomatous tissue by one of these growths.

Statistics indicate that recurrences after operation are rare except in those cases in which there are multiple anlage. Attempts to cause coagulation of blood within angiomas by the injection of different substances is not to be advised. Hemorrhage and infection, which deterred the surgeon from attempting their removal in earlier days, are no longer dreaded. An artificial ischæmia is induced and the tumor is dissected out of the muscle. If the dissection is carried wide it may

be necessary to perform some plastic operation to restore the function of the muscle.

Pigmented Nævi.—Pigmented nævi are classified differently by different pathologists. Ziegler and von Recklinghausen regard them as pigmented forms of lymph-angiomas. Borst regards them as melanotic fibromas, Unna as epithelial tumors and Ribbert classifies them as melanomas, a view concurred in by Lexer (Fig. 251).

Pigmented moles are not infrequently found upon the upper extremity, occurring most commonly on the flexor surfaces, where they appear as the flat, hairy or warty growths. They are congenital and enlarge gradually but slowly until the patient attains growth when

FIG. 251.—Melanoma of the tip of finger. (*Lexer-Bevan.*)

they remain stationary. Warty growths may develop upon a flat or hairy mole at any time. Nævi may develop along the course of cutaneous nerves, in which cases they are usually associated with fibromas and soft warts of the skin and different forms of lobulated elephantiasis. In these combined types they may be found in skin lying over plexiform neuromas and neurofibromas.

In nævi there is a proliferation of both the epithelial and connective-tissue elements, so that pigmented growths are closely allied to fibroepithelial tumors. The pigment, which is usually finely granular, brown in color and in small masses, is distributed in the cylindrical cells of the germinal layer and in large chromatophores. Groups

of nævus cells are found in the proliferated connective tissue of the mole. The origin of the nævus cells is still a matter of discussion. They are regarded by some as proliferating lymphatic endothelium, by others as connective-tissue cells, and by still others as derivatives of the basal cells of the epidermis.

There is a close relationship between pigmented moles and malignant pigmented tumors. The fact that both contain pigment and that exceedingly malignant tumors develop from pigmented moles, when often or continuously irritated, indicate a definite relationship.

When malignant, pigmented tumors are characterized by extreme malignancy, lymphatic involvement occurs early and the tumors have many more of the clinical features of carcinoma than of sarcoma. The cells forming them are probably of epithelial origin and the malignant tumors should be regarded as melanocarcinomas, rather than melanosarcomas, a term usually applied to them in surgical literature.

Melanocarcinomas have the same distribution as pigmented nævi, which form their precancerous lesion. They are not as common upon the hands as upon the feet, where they are not of infrequent occurrence upon the sole, heel and about the nails.

Malignant changes in a pigmented mole are characterized by rapid growth, ulceration and bleeding. Surrounding a pigmented mole which has undergone malignant degeneration, there are frequently found beneath the skin a number of small pigmented spots resembling those which are caused by ink when the skin is pricked with a pen. The development of these small spots about a mole which has commenced to enlarge is indicative of malignancy.

Early lymphatic involvement is one of the characteristics of pigmented malignant tumors. Pigment is usually found in the secondary growth, although in some cases the power to form pigment is apparently lost. Visceral metastases are not so common in cases of melanocarcinoma of the extremities as when the tumor develops about the eye.

Melanocarcinomas usually run a rapid course. Non-operated cases die in a short time of metastases, cachexia or general infection developing from the ulcerating new growth. Sometimes the lymphatic metastases develop late, years after the primary growth has been removed. Visceral metastases contraindicate operation unless the patient may be relieved of suffering by removing an ulcerating primary growth.

Pigmented moles are removed for cosmetic reasons and for fear

of malignant degeneration when they are so situated that they are irritated or begin to enlarge. The growth should be excised under local anæsthesia, the incision being carried well into healthy skin. Removal by electrolysis, freezing or caustics is dangerous, because partial removal associated with irritation may result in malignant changes.

In view of the fact that melanocarcinomas are so malignant the tumor should be removed as soon as any evidence of malignant changes occurs and the removal should be as thorough as possible. Lymphatic metastases are so constant that in all cases of suspected malignancy

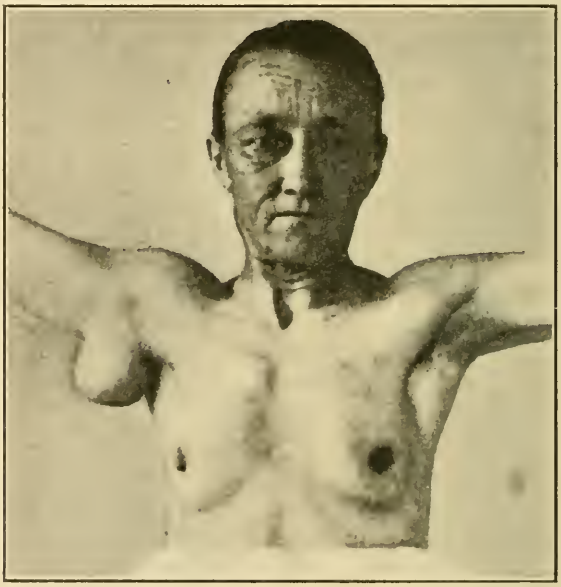

FIG. 252.—Pendulous lipoma of axilla. (*De Quervain.*)

the lymphatic modes draining the affected area should be radically removed.

Lipomas are frequently found in the subcutaneous tissues about the shoulder. While they may occur upon the lower arm or forearm they are much less common in these positions. Subcutaneous lipomas appear as small, flat, nodular or lobulated growths of varying sizes. The small ones may be no larger than an English walnut or even smaller, while the larger may be the size of a man's head. Occasionally a lipoma becomes pendulous and is so heavy that the broad base is drawn out to form a narrow pedicle (Fig. 252). Circulatory disturbances are often noted in the pendulous lipoma and the skin covering it is often traversed by dilated vessels and is thick and œdematous.

The skin covering a lipoma usually can be moved easily over it and can be raised in folds. In cases in which the skin has been irritated for some time, for instance by a suspender strap, it may be somewhat adherent. When the skin is made tense, the lobulation, one of the characteristics of fatty tumors, may be seen and upon palpation a peculiar pseudo-fluctuation can be elicited. The lobulation and pseudo-fluctuation are so characteristic of lipomas that the diagnosis usually rests upon these two findings.

Lipomas are independent of general metabolism. When a patient having a lipoma emaciates rapidly, the size of the tumor does not decrease.

Small symmetrical lipomas are occasionally found upon the upper extremities, but when lipomas occur with this symmetrical distribution they form but a part of a number of small lipomas situated in different parts of the body. These small symmetrically placed lipomas are often related to cutaneous nerves and removal may be indicated because of the pain associated with them. They do not differ in their clinical aspects from the single subcutaneous lipomas found in other parts of the body except that they are quite frequently accompanied by some pain.

The diagnosis of superficial subcutaneous lipomas is based upon the position of the growth, slow growth, lobulation and pseudo-fluctuation. Lobulation and pseudo-fluctuation are so characteristic that a lipoma situated superficially can hardly be mistaken for any other lesion. The diagnosis of intramuscular and fascial lipomas on the other hand is often difficult because the overlying muscle renders lobulation indistinct and the pseudo-fluctuation is so increased that a diagnosis of a cyst or cold abscess may be made. In doubtful cases aspiration may be resorted to in order to determine whether or not fluid is present.

A fatty tumor usually can be removed without difficulty. The tumor is seized between the index-finger and thumb and the skin made tense. When the incision is made down to the capsule, the tumor fairly pops out. If the tumor cannot be easily removed it may be grasped by forceps or traction may be made with a sharp hook, and as the trabeculæ which attach it to neighboring structures are made tense, they may be cut. Occasionally considerable difficulty is experienced in removing tumors related to nerve trunks or vessels and a careful dissection will be required. It is often necessary to insert a small drain into the cavity which remains following the removal of a lipoma.

Intramuscular lipomas are rare. There were reported in surgical literature up to 1910 but 27 cases. In 15 instances the growth had been observed in the muscles of the upper extremity. One had been found in the infraspinatus; one in the subscapularis; one in the deltoid; one in the triceps; five in the biceps; two in the brachialis anticus (Fig. 253); one in the extensor digitorum; one in the muscles of the thenar eminence. Of the muscles of the upper extremity the biceps is most frequently affected. In these statistics only the muscles of the extremity are considered. By far the greater number of intramuscular lipomas have been observed in the muscles of the tongue.

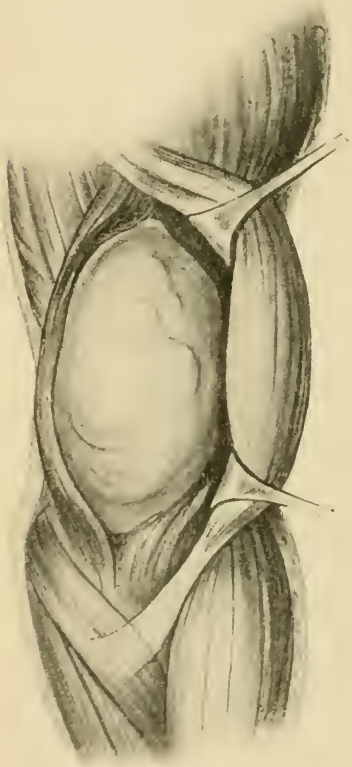

Fig. 253.—Lipoma of the brachialis anticus. (*Kuttner and Landois.*)

The diagnosis of intramuscular lipomas is rarely made, as the characteristic lobulation cannot be determined because the site of the tumor does not permit of accurate palpation. In some instances the pseudo-fluctuation of the lipoma is increased by the elastic feel of the overlying muscle, so that a diagnosis of cold abscess or cyst is often made. I have seen a lipoma lying beneath the infraspinatus which was regarded as a cold abscess, because of the history of rather rapid enlargement and because apparent fluctuation could be elicited.

In some instances the growth has caused a pressure neuritis necessitating removal. Often the suspicion or fear of a malignant new growth or malignant degeneration of a pre-existing one directs the patient to a physician. The growths can usually be easily removed. In some cases, however, in which the growth is deeply situated, an accurate dissection is required in order to avoid important nerves or tendons with which the growth lies in intimate contact.

Molluscum Fibrosum.—Small sessile or pedunculated fibromas, which have little or no clinical significance and often pass unnoticed by the patient, are common. Occasionally the tumors reach such a size or are so situated that they may cause considerable trouble.

They are usually scattered diffusely over the body, so that the fibromas appearing upon the arms are merely incidental to the general affection. A pedunculated growth, if circulation is hindered at the base, may become œdematous or ulcerate, causing considerable annoyance. According to von Recklinghausen these multiple tumors develop from cutaneous nerves and should, therefore, be classified as neurofibromas. Not uncommonly they contain within themselves very delicate plexiform neuromas.

Plexiform Neuromas.—These neuromas may have no symptoms at all or may be associated with neuralgic pains. They may remain latent, being discovered only when a general examination is made. On the other hand they may be associated with pain, radiating to the peripheral distribution of the nerve involved or there may be local tenderness. Hyperæsthesias or paræsthesias may be present in the area of distribution of the nerve.

If these growths give rise to much inconvenience, they should be removed and in most instances, as they are fibromas, they can be enucleated from the nerve as the nerve fibers proper are either spread over the growth or pass to one side.

Malignant tumors of nerves are characterized by rapid enlargement of the growth, by increased symptoms of irritation of the nerve involved and its finer branches of distribution, and by infiltration of neighboring structures. If still confined to the nerve, resection with end to end anastomosis or reunion of the nerve by prosthesis should be considered.

Different forms of tumors occur in the nerves, such as neuromas, fibromas, myomas, gliomas and sarcomas. It is probable that true neuromas do not exist. Most of those classified as such spring from the peri or epineurium and should, therefore, be classified as neurofibromas, neurosarcomas and neuromyomas. Such tumors may occur singly or in groups. They may be limited to one part of the nervous system, for example, the brachial plexus, the radial nerve, or the cauda equina, or may be distributed diffusely over peripheral nerves. At times they appear like a string of beads scattered over the peripheral nerves. They are usually the size of a pea or hazelnut, while in other instances they may become as large as a bantam's egg or larger. The consistency varies: a neurofibroma may be exceedingly hard, resembling cartilage; in other instances it may be soft, often almost cystic.

Von Recklinghausen has described what is sometimes called a general fibromatosis or fibroma multiplex, in which numerous fibromas are found upon the peripheral nerves, usually having a symmetrical

disposition and being associated with pigmented nevi, soft fibromas and lobulated elephantiasis. Associated with neurofibromas there may be different forms of fibromas of the skin. The soft fibromas usually appear as small, round, pigmented growths with a broad base and smooth or wrinkled surface. They are either present at birth or develop from pigmented moles; they may reach a fairly large size and later become pedunculated. If associated with a general neurofibromatosis these growths may appear upon the extremities, otherwise they are most common upon the head and face. Soft fibromas are usually quite cellular and if pedunculated may be œdematous.

Enchondromas and Cartilaginous Exostoses.—Chondromas may develop in the marrow of bone or from the periosteum. They develop particularly in the phalanges and metacarpal bones, and appear often as multiple tumors of hard consistency which grow slowly and finally cause marked deformities of the fingers and hands.

There is a family predisposition to the development of enchondromas and exostoses. Reinecke has collected statistics regarding 30 families with exostoses in which the lesions were transmitted to the second, third, fourth and even fifth generation. Teissier and Benard report a case in which a man with exostoses had children by two wives and the children of each wife subsequently developed exostoses. Stendel reports multiple enchondromas in a patient whose brother had tumors of the same type upon the toes. The children of a patient with exostoses may develop enchondromas. A. O. Weber cites an interesting case of predisposition in which a man with numerous exostoses had a son in whom enchondromas of the pelvis, vertebræ, ribs and scapula, developed in addition to numerous exostoses. These growths are more common in the male than in the female. Statistics compiled by Reinecke show that the tumors occurred in males 121 times and in females 47 times.

It has been suggested that rickets is an etiological factor in the development of enchondromas and exostoses, islands of epiphyseal cartilage becoming separated and displaced during the disease and later developing to form these growths. The shortening of the bones and the deformity which occurs with multiple tumors of this kind are suggestive of the deformities sometimes associated with rickets. Histologically the arrangement of the cartilage cells in exostoses is different from that in rickets and it is quite probable that the rickets in some of the cases in which it has been observed, was an accidental finding rather than an etiological factor. According to von Bergmann multiple cartilaginous exostoses is a distinct entity due to an imperfect development

of the epiphyseal cartilage, resulting from defects in the original anlage.

Marked growth disturbances may be associated with multiple exostoses and enchondromas. In addition to shortening of the bones due to failure of proper development at the epiphyseal line, abnormal curving and bending of the affected bones also occur. The growth disturbances are usually proportionate to the number of exostoses. This statement does not, however, apply to all cases, for bones with few exostoses may present considerable growth changes and deformities and shortening may occur in bones which are not the seat of tumor formations (Fig. 254). The growths may have a unilateral distribution.

The bones are involved in the following order of frequency: lower end of femur, lower ends of tibia and fibula, upper end of femur, lower end of radius and ulna and upper ends of tibia and huimerus. The lower end of the humerus is most infrequently affected. Enchondromas develop most frequently upon the short bones, especially upon the phalanges. C. O. Weber's statistics dealing with 126 multiple enchondromas show the following distribution:

77 upon the bones of the hands.
18 upon the bones of the feet.
8 upon the tibia.
4 upon the humerus.
3 upon the scapula (Fig. 255) and ribs.
2 upon the femur.
1 upon the maxilla, frontal bone, vertebra, pelvis and clavicle.

Exostoses upon the bones of the extremity may have a symmetrical distribution, the corresponding lesions being quite similar in form and arrangement. They are found upon the metaphyses of long bones which in many cases are doubled in thickness. The exostoses appear as warty, knotty or cord-like formations, as spinous or hooked out-growths. They are frequently

FIG. 254.—The head is normal in size and shape. Marked deformity of the upper extremities, particularly the left forearm and shoulders with relative shortening of the arms; more marked on the left. Small tumors scattered over the ribs; larger ones in the region of the hips, especially the right. Legs normal in length. In general, the distribution of the tumors is fairly symmetrical. (*Dean Lewis.*)

present in large numbers, some being found in the epiphysis, others in the diaphysis. The latter represent the oldest exostoses. They may become very large. Frequently they form a synostosis between neighboring bones.

A characteristic deformity of the forearm not infrequently occurs with exostosis (Fig. 256). As a result of imperfect ossification there is a defect in the lower end and the adjacent part of the diaphysis of the ulna. The ulna is shortened, the radius becomes secondarily bent, and its head is deformed and dislocated.

Fig. 255.—Osteoma of scapula. (*Potter.*)

Upon the free extremity of an exostosis there may develop a bursa filled with fluid. Exostosis bursata is the term applied to this type of new growth. Such an exostosis is most frequently seen about the lower end of the femur.

Multiple chrondromas of the phalanges may produce marked deformities of the fingers which may appear as gnarled and knotted masses. These are often combined with multiple growths on other bones which result in marked deformities of the entire skeleton. The

central enchondromas usually produce a fusiform expansion of the bone, so that a phalanx or metacarpal bone, when the seat of such a growth may present the appearance of spina ventosa. This fusiform appearance

Fig. 256.—The left forearm. The bones are greatly shortened and deformed. The ulna is the larger bone; its upper end shows little change. The shaft is short and stout, while the lower third is spread out into a large mushroom growth, displacing the radius inward. The enlargement shows trabeculæ with minute cysts. The shaft of the radius is very thin and twisted around the lower ulna and its upper end is deformed by a bony overgrowth. Stereoscopic plates show these bones to be distinctly separated from one another. The lower end of the radius is somewhat deformed but its articular surface is little changed. The elbow joint is negative.

is not caused entirely by the expansion of the cortical bone by the tumor for a new layer of bone is formed by the periosteum after the compact bone has been destroyed (Fig. 257).

Enchondromas may undergo liquefactive changes (Fig. 258). The relation of liquefactive changes in enchondromas and cyst formation in bone have already been discussed in the section dealing with bone

Fig. 257.—The right hand. The bones of this hand are more uniformly thickened and clubbed than those of the left hand. The distal ends of all of them, almost without exception, bear small exostoses. There is also evidence of early degeneration in the ends of some of them. The thickening of the shafts is very well shown in the phalanges of the first, second and third fingers.

cysts. Malignant degeneration may occur in a chrondroma, this being indicated usually by rapid growth in a pre-existing stationary tumor.

Multiple exostoses and enchondromas are easily recognized. En-

chondromas are so common upon the fingers that they should be considered first in differential diagnosis when tumors of hard consistency and slow growth develop upon the bones of the hand. The X-ray findings are usually quite characteristic.

FIG. 258.—The left shoulder. The inner end of the clavicle is normal. At the outer end there is a large irregular mass which contains cystic cavities and involves the entire outer end of the acromion. The inner border of the scapula is irregular, and on the outer border at the junction of the middle and lower third is a large rectangular exostosis. The upper border is obscured. The upper third of the humerus is enlarged and club-shaped and shows a large single cavity with bony partitions. The cortex is irregularly thinned out, and in places seems to be broken through particularly on the inner border. The lower two-thirds of the humerus is normal, except for one small exostosis on the inner condyle.

In those cases in which the exostoses do not press upon adjacent structures, such as nerves, or do not interfere with the function of muscles or joints, they should be left alone. In cases in which they do

interfere, they can be easily removed. Cortical enchondromas can be easily removed with a chisel or gouge, the removal being carried down to normal bone. In cases of central enchondromas, the cortical bone covering or the new bone which has formed from the periosteum should be chiseled through and then the tumor should be removed by chiseling along the line at which the new growth lies in contact with normal bone. In the cases in which removal by gouge or chisel is impossible, the greater part of the new growth may be removed with a curette.

In treating enchondromas of the phalanges and metacarpal bones, resection in continuity may be required. In this case bone transplantation should be employed to repair the defect resulting from resection.

In cases in which malignant degeneration of the enchondroma has occurred, amputation is indicated. In the early stages, however, resection with bone transplantation may be attempted.

MALIGNANT TUMORS

Carcinoma.—Carcinomas of the skin of the upper extremity usually develop upon some precancerous lesions such as warts, senile

FIG. 259.—Carcinoma of the skin upon back of wrist which developed upon a dermatitis in a worker in paraffin. (*Davis.*)

hyperkeratoses, cicatrices following burns or ulcers, or from chronic inflammatory changes induced by arsenic, paraffin or tar.

One of the most interesting malignant lesions of the skin is that which develops in people who work in paraffin or tar (Fig. 259). It is probable that the changes in the skin which precede the carcinoma are due to irritating substances in crude paraffin, the greater part of which are separated from the paraffin with the thick heavy oils which are similar to the pressed distillate.

Volkmann distinguished an acute and chronic stage of paraffin dermatitis. The acute stage is characterized by the formation of acne-

like pustules and at times of broad papules. In some cases confluent nodules and boils develop. The acute stage may last for many months and then the epidermis becomes thickened and there is an increased secretion from the oil glands. The papules, boils and nodules decrease in size, and flattened areas, resembling psoriasis, appear. Brownish pigmented spots form. The skin becomes parchment-like, dry and fissured. As the secretion of the glands is increased, seborrhœic patches form. As the lesions increase, multiple warty growths develop, one or more of which may undergo malignant transformation.

Exposed surfaces are most frequently the site of the changes just mentioned. In an old workman Volkmann found 15 warty growths covered with thick crusts on his pigmented and fissured forearm and three on the scrotum. This clinical picture resembles very closely that of "verruca cancerosa" observed in old people.

Schamberg states that a noteworthy feature of tar cancers is their frequent tendency to undergo spontaneous involution. Many of the lesions ulcerate and then cure spontaneously. Some of the patients have removed the warty and epithelial growths themselves. As the patients often cure these lesions themselves they exhibit a marked indifference to the skin trouble. Only one of five patients observed by him sought treatment for the condition, although one of the others had a painful growth on the wrist. Other lesions on this patient had disappeared spontaneously or after the application of simple home remedies. Schamberg believes that the proliferative energy transmitted from one generation of epithelial cells to another in lesions of this character is not great.

According to Davis the source of the tar seems to be of great importance in determining its effect upon the skin. In Great Britain it is usually gas works tar which produces the dermatitis which is apt to be followed by malignant changes, while the blast-furnace tar has no such effect. Davis recently investigated an oil company's plant near Chicago, from which a patient with paraffin carcinoma had come under observation. He found that skin lesions attributable to their occupation were found only in men employed in the press rooms, in which the crude paraffin is run into large presses and the oils, "pressed distillate," are expressed. The paraffin remaining in the press (so-called slack wax) is scraped off by men who use spade-like instruments and usually work with bare hands, the shirt sleeves being rolled up above the elbows. During their work the arms of the men become pretty thoroughly covered with the pressed distillate. During the first few months when

working in this department, most of the men develop the so-called "wax boils" which may affect the skin of any part of the body but are most common on the arms and neck. The susceptibility to these boils disappears after a time in most cases. A certain proportion of the workmen, however, develop other lesions. After a number of years pigmented spots form. Some of these scales resemble psoriasis, while others resemble more closely pityriasis rubra. These lesions may be followed by wart-like growths which develop slowly and are amenable to common therapeutic measures. Finally true epitheliomas may develop, but these are found only in those workers who come into close and long-continued contact with the "pressed distillate." "Wax boils" and the other skin lesions mentioned above, are unknown among the workers in finished paraffin and among those handling crude oil.

According to von Bergmann, a carcinoma of the skin of the extremity always develops upon some precancerous lesion. In recent years several cases of X-ray dermatitis have been observed and this lesion has in many cases preceded the development of a carcinoma. In 1909 Coenen could find in the literature reports of 33 carcinomas of the skin which probably followed exposure to the X-ray. These were observed upon the skin of different parts of the body but mostly upon the skin of the hands and face. The mortality of this type of carcinoma seemed to be about 24 per cent. but it was difficult to determine exactly the mortality for many of the cases had developed only a short time before the report was made.

The typical X-ray dermatitis precedes the development of carcinoma. The skin, not the seat of carcinoma, is dry, covered with hyperkeratotic areas, in and around which are dilated cutaneous blood-vessels.

X-ray dermatitis occurring in technicians is naturally most frequently observed upon the hands and X-ray carcinoma belongs to the small group of carcinoma of the extremities. It is closely allied to paraffin and tar carcinoma, which has just been discussed.

Histologically, X-ray carcinoma belongs to the cornifying type, the basal cell carcinoma having not been observed. In the dry characteristics and the hyperkeratoses X-ray dermatitis is not unlike seborrhœic eczema which is a precursor of cancer of the skin in old people.

Wyss has demonstrated quite constantly in the vessels of the skin adjacent to X-ray carcinoma, an obliterative endarteritis. X-rays apparently have an injurious effect upon blood-vessels, resulting in the formation of telangiectases which are found regularly in X-ray derma-

titis and are recognized at first glance in the scars which follow the healing of X-ray burns. Coenen believes that X-ray carcinoma follows a primary injury of the epithelium which becomes chemically altered as it does in paraffin and tar dermatitis and in seborrhœic eczema. In half of the cases which have been reported, the carcinoma developed upon a lupus which was being treated by X-ray.

The carcinoma does not differ in appearance from the cornifying carcinomas of the skin. The history of repeated exposures and the rather characteristic dermatitis which surrounds the developing carcinoma enables one to make the diagnosis without difficulty. Multiple carcinomata may develop upon an X-ray dermatitis. In the early

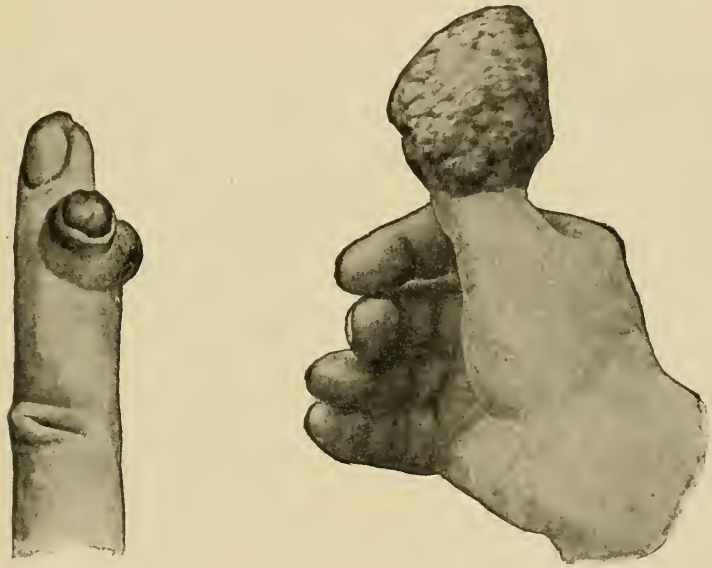

A *B*

FIG. 260.—*A*, Very vascular sarcoma of the skin. The tumor has broken through the skin which surrounds it like a collar. (*Lexer-Bevan.*) *B*, Round-cell sarcoma of the skin. (*Lexer-Bevan.*)

stages of carcinoma formation the skin affected may be excised and the area grafted. Eventually amputation and removal of the axillary lymph nodes may be necessary. In some instances carcinoma has developed upon several fingers, necessitating partial or complete removal. As previously stated the mortality at the time Coenen's paper was published was 24 per cent., but it is probably higher than this for many of the cases collected by him had been observed but a short while.

Sarcoma.—Primary sarcoma of the skin is exceedingly rare and in some cases in which the tumor has been thought to originate within

the skin, it is quite probable that it developed primarily in the fascia and then extended to the skin. The lesions appear as firm nodules or as bluish masses often with a depressed center (Fig. 260). A considerable area of skin may be involved. The tension resembles in appearance somewhat a keloid. Some of these tumors are probably identical with what were formerly called recurrent fibroid tumors.

The treatment consists in removal of the tumor with a wide area of skin surrounding it. In some of the cases, however, the tumor has recurred rapidly and in a more malignant form after extirpation. In these cases it is probable that the incision was not carried wide enough.

Fascial Sarcomas.—Fascial sarcomas, composed of small round or spindle cells, are usually very malignant. It is difficult to determine

Fig. 261.—Small round-cell fascial sarcoma of the hand. Amputation was soon followed by symptoms indicating involvement of the lungs. A piece of tissue was expectorated which resembled histologically the primary tumor. (*Bevan.*)

the frequency with which they occur in the upper extremity. They form large tumors which rapidly invade the skin and surrounding structures. When the skin becomes involved ulceration occurs and finally large fungus masses form which bleed easily. Clinically these growths are quite characteristic and few difficulties are encountered in making a diagnosis (Fig. 261). In doubtful cases a microscopic examination may be required. Metastases in the lungs are formed early and a careful examination of the chest should be made before an operation is performed.

In the treatment of these tumors, amputation is the only procedure to be considered and this should be made above the point of origin of the muscles related to the tumor.

Sarcoma is the most common primary tumor of muscle, but it is relatively rare. Lorenz in 1904 collected 103 cases of primary muscle sarcoma. This does not indicate anything regarding the number of cases, for probably many are observed and are not regarded as of sufficient interest to warrant reporting.

Primary sarcomas of muscle are more common in men than women. They may occur at any age, but are more frequently seen in the young than in the old. They occur even in children; one has been reported in a child 10 months old. Of the 103 cases collected by Lorenz, 2 occurred in the musculature of the head, 23 in that of the neck and trunk, 34 in the upper extremity and 41 in the lower. The muscles of the upper extremity alone were involved in 22, those of the thigh in 37. The triceps is the muscle of the upper extremity which is most frequently involved. The muscles of the forearm are fourth in order of frequency.

Trauma seems to be an etiological factor and repeated traumata seems less of a factor than a single rather severe trauma from blunt force.

The primary muscle sarcoma may be a circumscribed well-encapsulated tumor or a diffuse infiltrating growth. Multiple sarcomatous nodules at some distance from the primary growth may be noted, especially if recurrence has taken place.

Circumscribed are more common than diffuse infiltrating tumors. They lie either in the substance of the muscle, or may be loosely or firmly attached to the fascia surrounding it, so that in some instances it is difficult to say whether we are dealing with a tumor which has been primarily in the muscle or fascia.

The surface of the growth is usually somewhat nodular. The diffuse infiltrating growth appears as a fusiform thickening of the muscle rather than a true tumor. Nearly all varieties of consistency are met with, varying from the almost cheesy tumor to the hard, fibrous form. Degenerative changes ending in cyst formation are not uncommon.

Histologically the round and spindle-cell sarcomas predominate (Fig. 262). Combined types have been described. Giant-cell sarcomas of muscle have also been described.

Sarcomas of muscle develop insidiously. Only when the muscles are superficial, are the tumors observed early. The onset may not be so insidious if a rather severe trauma has immediately preceded the development of the tumor. If the tumor has followed directly upon the injury, it may be difficult to differentiate it from myositis ossificans. Even without a preceding trauma pain which is usually described as

rheumatic, or neuralgic, may be present. In some cases of extremely malignant tumors, the symptoms may be very acute and simulate an intermuscular phlegmon, severe pain, fever, œdema, etc., entering into the clinical picture.

The cause naturally depends upon whether or not the tumor is encapsulated. The growth appears first as a more or less deeply situated mass which as it enlarges approaches the surface, the aponeurosis and finally the skin being involved. In the cellular spindle-cell and round-cell sarcomas the aponeurosis is soon infiltrated and perforated; the skin is next affected and finally the growth ulcerates; as the growth

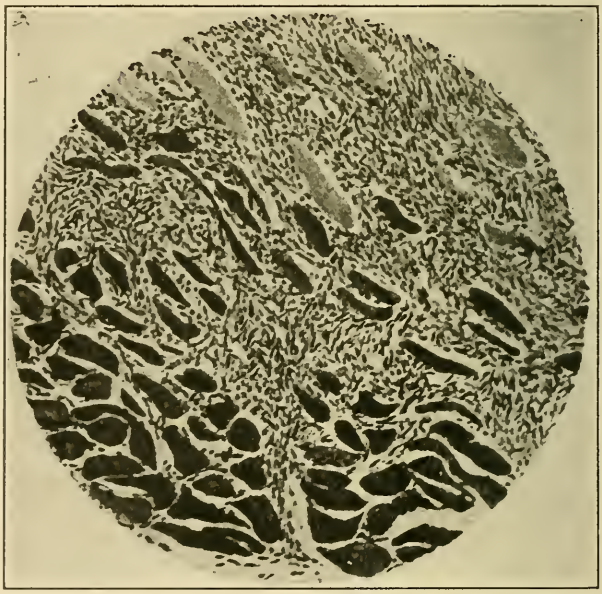

FIG. 262.—Spindle-cell sacroma of the brachialis anticus. (*Kuttner and Landois.*)

approaches the skin there may be a very decided reaction, resembling an inflammatory process and leading to considerable confusion in diagnosis.

Prognosis.—The muscle sarcomas as far as prognosis is concerned are most unfavorable. Landois, in the Breslau clinic, recently examined nine cases which had been operated upon. Four of these were round-cell sarcomas, four spindle-cell sarcomas and one a myxosarcoma. Four of these died in from one to two years after the operation. Of the five who are living, three have had recurrences.

Early diagnosis is often difficult. The sarcoma may be confused with gummatous myositis. If there is a suspicion, a Wassermann test

should be made, and if positive, antisyphilitic treatment should be instituted, but the patient should be kept under observation. In the beginning the sarcoma has no characteristic symptoms so that other errors in diagnosis are possible. It may be confused with echinococcus, lipomas or other tumors. The diagnosis may be especially difficult if the sarcoma has developed very rapidly and is accompanied by inflammatory symptoms. If myositis ossificans develops, a differential diagnosis may be difficult because of the X-ray findings. If a diagnosis cannot be made clinically a piece of tissue should be removed for histological examination. In some instances of very rapidly growing sarcoma of muscle, it may be difficult to differentiate between a sarcoma of muscle and granulation tissue.

If the growth is apparently limited to the muscle, removal of the entire muscle should be attempted. In rapidly growing infiltrating sarcomas amputation is indicated as well as in these cases in which the tumor has recurred rapidly after a conservative procedure. Naturally lung or other diffuse metastases are contraindications to operation.

Where a radical operation is contraindicated, Coley's toxins and the X-ray should be tried.

Statistics show that the bones of the upper extremity are less frequently the seat of sarcomatous growths than are those of the lower. Statistics published by Ruckert in 1904, dealing with 221 cases of sarcomas of bone, show that the femur was affected 87 times, the tibia 67, the jaw 22, the bones of the pelvis 15, the humerus 8, the ulna 5, the ribs 4, the radius, clavicle and vertebræ 3 times each, the frontal bone, sternum and os calcis, once each. Gross' statistics, published some years ago, based upon a study of 165 cases, show that the femur was affected 67 times, the tibia 46, the humerus 25, the fibula 13, the ulna 7, the radius 6, ulna and radius together once. Other statistics dealing with bone sarcomas, such as those of Koch and Altschul show that the different bones were involved in about the order of frequency given above. The humerus is more frequently the seat of malignant growths than are the other bones of the upper extremity, but statistics differ as to the relative frequency with which the radius and ulna are affected. The lower end of the radius is one of the favorite sites for the development of central giant-cell sarcomas.

Central Giant-cell Sarcomas.—The upper end of the humerus and the lower end of the radius are favorite sites for the development of these growths. The frequency with which this type of tumor occurs in the lower end of the radius is indicated by Bloodgood's statistics, for among

18 cases of central giant-cell sarcoma observed by him, the lower end of the radius was affected 10 times, or in over 50 per cent. of the cases.

Bloodgood's statistics show that the ages of the patients affected with giant-cell sarcoma ranged all the way from 20 to 66 years. In discussing the etiology of fibrous osteitis it was stated that this disease

FIG. 263.—Central giant-cell sarcoma upper end humerus. This differs from fibrous ostitis in being more closely limited to the upper end of the shaft, in enlarging more symmetrically and in being hemispherical instead of fusiform. Extension through the thinned cortex of bone into surrounding tissues also occurs in central giant-cell sarcoma. (*Phemisber.*)

was most common in the young, 84 per cent. of the cases occurring between the first and thirtieth years of life. Central giant-cell sarcoma is rare in patients under 20 years of age. The male sex is apparently more commonly affected than the female, but there is not much difference.

In many cases there seems to be a direct relationship between trauma and the development of these new growths. In some cases the trauma has been quite severe, while in others it has been so slight that the patient attached little or no importance to it. The trauma may have been forgotten until called to mind while the history is being taken. Ziegler, in 1895, stated unreservedly that trauma was an etiological factor in the development of these new growths, believing that the necrosis consecutive to the injury was followed in some cases by an atypical cell proliferation leading to tumor formation.

FIG. 264.—Early central giant-cell scarcoma of lower end radius, developing shortly after a baseball injury. (*Lewis.*)

The symptoms associated with sarcomas of the upper extremity present no special features. Pain is usually noted early. It varies in intensity. It may be quite severe, but in the slowly growing tumors the pain is more apt to be dull and boring than sharp. There is more or less tenderness over the bone which is the seat of the new growth. Expansion of the affected bone takes place slowly and may not be noted for some months after the pain begins. When the tumor has expanded the bone to a considerable extent, nothing but a thin layer of the cortex,

often of egg-shell thinness, remains, and when palpated a parchment-like crackling may be elicited.

In making a differential diagnosis between central giant-cell sarcomas, bone cysts, chronic osteomyelitic foci and periosteal sarcoma, the X-ray renders invaluable service. A diagnosis can, I believe, be made in most cases upon the X-ray findings, although Bloodgood states that the shadow cast by a central giant-cell sarcoma does not differ from that of fibrous osteitis. In a giant-cell sarcoma the shadow, as a

Fig. 265.—Giant-cell sarcoma of lower end of radius. X-ray picture of tumor showing perforation of cortex of bone. Tumor had invaded some of the soft tissue necessitating removal of some of the extensor tendons. (*Phemister.*)

rule, does not extend as far into the shaft as in fibrous osteitis. The shadow ends more abruptly and is more circumscribed. The part involved becomes more expanded and the shadow is hemispherical rather than fusiform as it is in fibrous osteitis (Figs. 263 and 264). Trabeculæ are found separating different parts of the shadow as in fibrous osteitis. Extension through the thinned cortical bone, perforation or involvement of the epiphyseal cartilage indicates the sarcomatous nature of the

FIG. 266.—Giant-cell sarcoma of lower end of radius. Tumor removed by resection. Specimen divided longitutionally. (*Phemister.*)

FIG. 267.—Giant-cell sarcoma of lower end of radius. Lower end of radius reconstructed by a bone graft. (*Phemister.*)

lesion. There are malignant types of giant-cell sarcoma but these enlarge asymmetrically and rapidly destroy the cortical bone, invading soft tissues and resulting in pathological fracture (Fig. 265, 266, 267). There is usually no difficulty in differentiating by X-rays findings periosteal sarcomas, chronic pyogenic and tuberculous between osteomyelitis.

It is important for the surgeon to be able to recognize a central giant-cell sarcoma by the gross appearance of the tissue. The tissue composing such a sarcoma is friable and although X-ray findings would indicate that bony trabeculæ occur between different parts of the tumor, the tissue can usually be broken up into small bits by the finger.

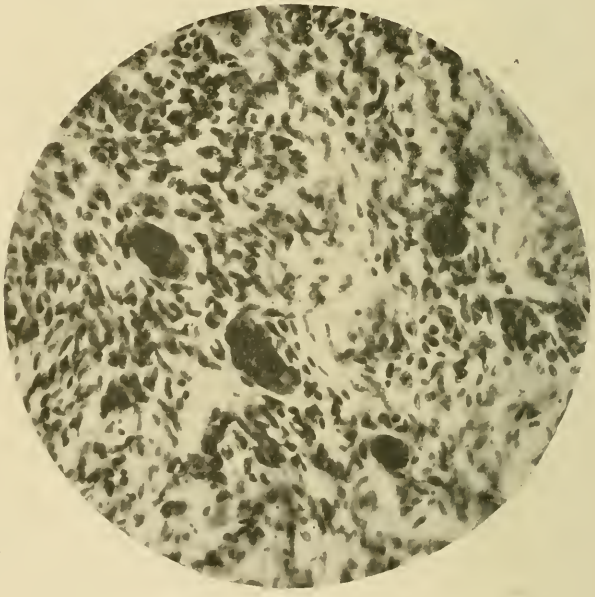

Fig. 268.—Section of a central giant-cell sarcoma. (*Phemister.*)

It is often difficult to remove the tissue from the thinned cortical bone surrounding it because it breaks up so easily. The tissue is usually very vascular, resembling somewhat in appearance currant jelly. White areas may be intermingled with red. In some cases operated on by me, areas composed of red tissue have been intermingled with areas of white tissue of firmer consistency, which resemble very closely the tissue removed from cases of fibrous osteitis.

Central giant-cell sarcomas differ from other sarcomas of bone so far as the prognosis is concerned. So long as they are surrounded by a bony capsule they rarely form metastases. They first assume malig-

nant characteristics after perforation of the bony capsule, and even after this has occurred local operations have resulted in permanent cures. The favorable results which may be obtained in cases of central giant-cell sarcoma is indicated by Bloodgood's statistics. All of the 18 cases of giant-cell sarcoma observed or reported by him have remained well and in many of these conservative operations were performed. That favorable results may be obtained by conservative operation, even after the growth has broken through the thinned cortical bone and invaded the soft tissue, is indicated by a case operated upon by Halsted. Halsted resected the lower ends of the radius and ulna for a pulsating tumor surrounding the latter. The tissue removed had the characteristic appearance of a giant-cell neoplasm. In this case Bloodgood demonstrated microscopically that the zone of uninvolved muscle removed beyond the tumor was so narrow that all of it could be seen in one field under the low power of the microscope. This patient remained well 12 years after the operation and died of some other disease.

As these tumors are in the majority of cases clinically benign, forming metastases late or not at all, conservative treatment is indicated even in advanced cases. Curettage is the operation of choice, for the risk of metastasis is apparently not increased by such an operation, and besides the articular ends of the bones are spared. This is an important consideration in view of the fact that these tumors are most common in the lower end of the radius and the upper end of the humerus, often encroaching upon the articular cartilage.

Before curetting away the tumor mass, an artificial ischemia should be produced. A piece of the thinned cortex of bone overlying the tumor is chiselled away and the exposed tumor mass is removed with a curette. The mass should all be removed down to the thin layer of cortical bone. The cavity is then carbolized. The carbolic acid is neutralized with alcohol, some of which is left in the cavity and ignited with the cautery. The actual cautery is then applied to the walls of the cavity. The constrictor should then be removed. In many cases one or more large spurting vessels will be found in the walls of the cavity. Hemorrhage from these may be controlled with Horsley's wax.

In cases in which the tumor is small the cavity may be filled with Beck's paste or a Mosetig-Moorhoff plug. If the cavity is large a bone graft may be inserted for this hastens bone repair and at the same time preserves the contour of the bone and the articular surfaces. If currettage cannot be attempted because of the extent of the tumor, resection, followed by bone transplantation is indicated. Invasion of

the soft tissues is no contraindication to resection, provided that removal of the soft tissue, with extirpation of the tumor growth, is possible. If the tumor is very large and the adjacent soft tissues and neighboring joint involved, amputation may be required, but the amputation may be carried close to the site of the tumor. I have amputated for recurrence after curettage, within ½ in. of the tumor and the patient has remained well for about five years. Many similar cases are recorded

FIG. 269.—Periosteal sarcoma of the upper end of the humerus. Showing erosion of the cortex of bone and contour of tumor extending beneath deltoid muscle. (*Potter.*)

in surgical literature. The favorable prognosis after conservative treatment is indicated by Bloodgood's statistics quoted above.

It is difficult to determine the frequency with which periosteal sarcomas occur in the bones of the upper extremity. The humerus is more frequently the seat of those growths than the radius or ulna.

The tumor may develop from the fibrous layer or germinal layer of the periosteum. The tumors arising from the fibrous layers are usually composed of small around or spindle cells and are exceedingly malig-

nant. Those developing from the germinal layer form bone, and in the X-ray picture of these growths irregular deposits of bone are seen. After the newly formed bone has a stalactite-like arrangement.

Both these types of sarcomas are malignant, differing in clinical course and prognosis from central giant-cell sarcomas. They form metastases early and grow rapidly. In their clinical features, they do

FIG. 270.—Chondro sarcoma of the upper end of the humerus. (*Potter.*)

not differ from sarcomas developing from the periosteum in other parts. The rapidly growing tumors may be accompanied by fever, and I have recently operated upon a patient with a sarcoma of the humerus which closely resembled in its symptoms an osteomyelitis.

The X-ray enables one to make a positive diagnosis in most cases as

the findings are usually quite characteristic. In the tumor developing from the fibrous layer of the periosteum, the cortical bone is usually eroded, the bone seems to have melted away, and there are no evidences of proliferation. The outline of the tumor can usually be traced. This X-ray appearance of periosteal sarcoma is well indicated in Fig. 269. The ossifying forms are characterized by irregular deposits of bone, associated with more or less definite changes in the cortical bone.

Chondrosarcomas occur most frequently in the upper extremity of the humerus (Fig. 270) and probably next most frequently in the phalanges and metacarpal bones. Their malignancy is not great. The clinical course is relatively long and the prognosis, even after conservative operations is good.

Bone Aneurism.—This term is applied to certain obscure, pulsating, markedly hemorrhagic tumors of bone. These tumors may present certain of the clinical features associated with aneurisms, in that they may have a distinct pulsation, but in the mechanism of development and etiology they have nothing in common with aneurisms. Gaylord, in 1905, collected nine cases of so-called bone aneurism and but one of these occurred in the humerus. He suggested that tumors of this type might properly be called pulsating sarcomatous hematomas of bone. Most of these tumors are very malignant spindle- or round-cell sarcomas, which are exceedingly vascular and into which hemorrhages have occurred. They should be treated as are the more malignant types of bone sarcomata.

Nasse has determined by examining tissues removed at operation in the treatment of osteosarcomas, that the sarcoma cells early extend along the blood-vessels of the muscles. An early operation should, therefore, be performed to prevent this extension and the muscles attached to the bone involved should be removed even to or above their points of origin; that means usually an amputation above the adjacent joint. In sarcomas involving the bones of the forearm (the periosteal types of sarcoma are under discussion) an amputation through the arm is indicated, and in tumors involving the humerus an interscapulo-thoracic amputation should be performed.

In cases in which an early diagnosis is possible, resection followed by bone transplantation might be attempted, for Mikulicz and Haberer have shown that the results obtained by amputation do not differ materially from those following resection in cases where a fairly early diagnosis has been possible. Reinhardt estimates that there are but 18 per cent. of permanent cures following operations for malignant

tumors arising from bone. The central giant-cell sarcomas are not usually considered in these statistics, for, as has been previously stated, the prognosis after operation upon these tumors is good, even when very conservative operations have been performed.

The statistics following interscapulo-thoracic amputation show that the immediate mortality is not high. Berger, in 1905, collected statistics dealing with 129 amputations of this type. Sixty-four of these had been performed for malignant tumors of the upper end of the humerus. Two of these patients died, giving a mortality of 3.12 per cent. for this operation. The tumor recurred or the patient succumbed to metastases after a few months in 48.38 per cent. of the cases, while 38.70 per cent. of the cases survived some time or could not be traced. As many of the patients could not be traced, the number which remained well any length of time following the operation was considerably reduced.

FIG. 271.—Ganglion. (*De Quervain.*)

Ganglion.—A ganglion is a cystic formation which occurs in the capsular ligament in the dorsal surface of the wrist-joint. The etiology is not known, but they are supposed to follow strains and injuries about the wrist and are quite common in piano players. At one time they were supposed to be hernias of the synovial sheaths of the extensor tendons. This explanation was first suggested by Gosselin. The ganglia on the dorsal surface usually are found in the depression between the tendons of the extensor carpi radialis brevis and the extensor indicis. Ganglia are less common on the volar surface, but when found here they usually lie beneath the radial artery beside the tendon of the flexor carpi radialis.

Parkson and Riedel have shown that these cysts develop within the capsular ligament of the wrist-joint and not in the sheath. They are the result of degenerative changes in the capsular and paraarticular tissues, as a result of which a gelatinous substance, the contents of the cyst,

develops. An obliterating endarteritis of traumatic origin is probably the cause of the nutritional disturbances which precede the degenerative changes. At first several small cysts are formed which later unite and form a larger one. Similar changes occur in the fatty and connective tissue surrounding a bursa which is chronically inflamed. Ganglia frequently communicate with the wrist-joint. They may be unaccompanied by symptoms. Weakness of the wrist, and in some instances quite severe neuralgia pains are often associated with them. They are so characteristic in appearance that there is no difficulty in making a diagnosis (Fig. 271).

Injection of the cyst with iodine or carbolic acid is an uncertain procedure and should be abandoned. The cyst may be ruptured by pressure of the thumbs or by a blow with a wooden hammer or book. Recurrences are common after this method of treatment.

If removal is attempted the strictest asepsis should be observed as they may communicate with the cavity of the joint. They may be readily removed under local anæsthesia. The dissection should be clean, so that none of the compartments of the cyst may be overlooked. For this reason the operation would be performed under local ischemia.

SECTION V

DEFORMITIES AND PARALYSES OF THE UPPER EXTREMITY

By

E. H. BRADFORD, M.D., F.A.C.S.

and His Associate,

ROBERT SOUTTER, A.B., M.D., F.A.C.S.

PARALYSES OF THE UPPER EXTREMITY

These can be separated into three groups, according to their origin:

I. Those resulting from poliomyelitis.

II. Those due to cerebral paralysis.

III. Those due to trauma, including injuries at birth (ischæmic palsy, Volkmann's paralysis).

As the pathological nature of the paralysis in the upper extremity induced by poliomyelitis resembles that elsewhere its discussion will not be included here. The affection is, however, modified to an extent in its effect by the anatomical and functional conditions of the upper extremity.

In the early stage following the attack, the arm is helpless but as a rule is free from pain. Gradual recovery of power is first seen in movement of the fingers, with a slow recovery, in the majority of cases, of the other muscles except the deltoid, which in almost all severe attacks with delayed improvement, remains paralyzed permanently; the constant drag of the weight of the arm hanging upon the deltoid apparently impairing its recuperative power.

In many instances an actual recovery from the motor palsy takes place in all the muscles of the arm except the deltoid, but the disability resulting from the deltoid paralysis produces a partial muscular weakness of the arm due to limited use. In some instances an arrest of growth takes place with the result that the affected arm is shorter than the other (Fig. 272). This arrest is not seen in milder cases with early

complete or nearly complete recovery but may be seen in the more severe cases. It results either from the disuse or partial disuse of the arm or as a consequence of the original destruction of the nerve centers of the spinal cord which, as in the lower extremity, causes shortening from limited growth of the long bones. This arrest or limitation must be of a temporary character, as the resulting shortening, even when

FIG. 272.—Poliomyelitis of arm and forearm.

the original attack developed in early childhood, is never great. The diminution in length of the limb is general and not confined to the upper and lower arm alone; it affects the hand also.

Atrophy always results in the affected muscles (Fig. 273). Besides the atrophy which is directly proportioned to the extent of nerve-cell destruction in the spinal cord, there is added that due to disuse and over-stretching (see Fig. 274). The surface temperature is always lowered.

Not uncommonly the muscles originally attacked recover function as the upper extremity is not for weight bearing.

Spastic Paralysis of the Upper Extremity.—This term is applied to a condition of disability of the upper extremity characterized by a spastic condition of certain muscles, the result of lesion of the cortical substance of the brain and not, as in poliomyelitis, from the destruction of the nerve

FIG. 273.—Poliomyelitis of fingers, forearm, arm and shoulder.

cells of the anterior portions of the cord. The muscles are never flaccid, but although originally in constant spasm and not paralyzed they may in time undergo the structural changes of fibrous degeneration; in children they are of normal muscular fiber but under a condition of hypertonicity, overpowering the opposing muscles which may in turn become weakened by over-stretching. This cerebral paralysis is usually not limited to the upper extremity but also involves the lower extremity or extremities. In some cases, however, the condition is limited to

a few muscles of the upper extremity, disabling the patient because of inability to use the arm freely. As the trouble is congenital the symptoms are seen in infancy. In the more extensive cases there may be athetosis and impairment of intelligence.

A condition of spastic paralysis of the upper extremity is also seen after difficult birth and forceps delivery, where the head has been injured or the arm forcibly pulled upon, causing injury to the cortical substance or to the brachial plexus (Fig. 275). Pott's disease may also be a cause

FIG. 274.—Paralysis of forearm.

of spastic paralysis. It is not possible in some cases to distinguish between localized cerebral paralysis and the pure type of obstetrical paralysis and for purposes of early treatment this is not always necessary. It is simply important to determine that the condition of the affected muscles is one of contracture and not of flaccidity. Later, muscle training may be carried on so as to weaken the contracted muscles to such a degree that some use can be made of the limb by overcoming or diminishing the contraction which furnished the chief obstacle to function.

Nerve anastomosis or nerve grafting has not as yet proved itself a procedure of value in spastic paralysis of the upper extremity.

Induced paralysis of the nerve supply of the contracted muscles

has, however, been of some service but while injections of alcohol into the nerve trunks has been of use in the lower extremity its value is much less in the arm. Laminectomy with section of the nerve roots, is too dangerous a procedure to be used in brachial paralysis. The surgeon is, therefore, left to consider myotomy, myotenotomy.

Fig. 275.—Obstetrical paralysis.

These procedures will be found of much service in all cases except where at the elbow there is a partially flexed position. A spasmodic contracture of the biceps alone is seldom observed. The condition is usually due to the greater strength of the biceps or its mechanical advantage, and may be overcome, as far as that is desirable, or by other means than tenotomy. Spasmodic contracture of the deltoid apparently does not occur, perhaps because such spasm is overcome by the dragging weight of the arm. Triceps spasm is seldom marked. This

may be explained by the constant attempt to correct a stiffened elbow by the aid of the other arm.

In the forearm the usual spasmodic position is that of pronation, either complete or partial, with great difficulty in supination.

At the wrist, the limb is held in a position of flexion (Fig. 276). The fingers are semi-flexed but are capable of extension if the wrist is strongly flexed. If the hand is extended the fingers immediately become flexed, this being due to a shortening of the flexors of the fingers. There may, however, be an irregularity in these contractures of the fingers, some digits being more affected than others. In some instances the first two phalanges may be straight while the terminal phalanx is flexed. The thumb is adducted and flexed. In many instances these positions of deformity are not constant but are developed when any attempt is made to use the arm or when the patient is under any nervous excitement, the limb being thus rendered practically useless. The muscles may become relaxed at times and the limb rest in a comparatively normal position, the deformity reappearing on any attempt at exertion. The patient may be able to open the contracted fingers by the aid of the other hand and insert a light implement, spoon, knife or fork, which can be held with difficulty, but accurate control of such an implement is not possible.

Fig. 276.—Characteristic attitude of hand and arm in spastic paralysis.

A similar condition is sometimes seen in the upper arm in adults recovering from an apoplectic shock.

The treatment of these deformities of the upper extremity depends upon the age of the patient, the extent and site of the disability. The condition being primarily one not of paralysis but of unbalanced muscular tonicity, the treatment consists in an attempt to restore the muscular balance either by weakening the over-tense muscles or by strengthening the over-powered muscle. Where no cerebral irritation exists and no muscular degeneration has taken place, improvement can be

gained in the milder cases by training in muscular coördination. Simple exercises, *i.e.*, the rolling or the handling of dumb-bells, the symmetrical use of wands or bars, persistently and sensibly carried out will develop improved use of the hand and arm, the child being trained with different and slow motions such as a new-born infant learns with comparative rapidity. The amount of progress depends not only upon the will power of the child but also upon the difficulty in overcoming the obstacle of constant muscular spasm in certain groups of muscles. As far as is practicable such exercises should be employed as will develop the stretched muscles. Mechanical devices can be used for such exercises, the arm being so supported that further contracture is checked while motion in the direction which corrects the deformity is possible or aided. Splints for overcoming the deformity by a stretching force, such as are often useful in the deformities of poliomyelitis, are of but little use in these spastic deformities. Where muscle training or education in coördination fails, the surgeon will be able to give benefit by weakening the over-strong muscles either temporarily or permanently. In the first instance the object is to make proper muscle training possible, in the last to overcome an obstacle to proper muscular function. Where impaired intelligence exists, the results of treatment are not satisfactory. Myotomy is easily performed when the pectoral muscle is the one to be attacked. The patient is placed flat upon the operating table. The arm is strongly extended and somewhat raised. An incision through the skin is made over the lower border of the large pectoral muscle and this muscle is cut across near its insertion in the humerus. The division should be free, permitting, as in myotomy of the sterno-cleidomastoid in torticollis, a thorough gaping of the divided muscle. The free incision into the muscle and muscle tendon can be made readily and without danger if a director is passed completely under the muscle so as to protect the axillary vessels. The skin wound is closed and healing of the gap in the muscle through blood clot is to be expected. The arm during the healing period is to be kept stretched to prevent re-contraction of the healed muscle and to promote lengthening of the shortened muscle. No fear of destruction of the function of the muscle need be entertained, a return of the previous condition of contracture being the chief result to be averted. The treatment is to conclude with daily systematic exercises, continued for months after thorough healing of the incision. Contracture of the biceps may be treated in a similar way by muscular lengthening through myotomy, the division being made near the lower insertion of the biceps.

Contraction or constant flexed position of the wrist and hand may be treated by muscle or tendon lengthening. The writer prefers muscle lengthening through a long median incision in the forearm with cross division of the intramuscular tendinous fibers in the bellies of the flexor groups of muscles, combined with forcible stretching or tearing of the muscle tissue. The hand and fingers are to be kept in an over-extended position during the healing process. It is essential that over-correction be obtained and thus a free division of all contracted tendinous tissues or tendons should be made. Where this division is accomplished at a distance from the tendon sheaths and from the tendons proper, there is less danger of a permanent impairment of the function of the fingers.

Muscle and tendon transference of the strong into the weaker, of benefit in the paralyses of the foot and leg, is of less advantage in contracture of the hand, but an exception to this statement is to be made in the case of the pronation deformity of the forearm due to contracture of the pronator radii teres. Mr. Tubby's operation of muscle transference, if followed by systematic after-treatment, is capable of giving satisfactory results.

The muscle transference may be accomplished by separating the tendon with its periosteal attachment from the radius, passing the mobilized tendon through the interosseous membrane close to the radius and reinserting it on the outer side of the radius, if possible at the site of its former insertion.

The writer has found it advantageous to lengthen the pronator by means of silk strands quilted into it and secured by being passed through a hole drilled in the bone from the outside inward.

Tenotomy of the finger tendons and myotenotomy of the adductor muscles of the thumb may be needed, but here even more than elsewhere in muscle and tendon transference, the surgeon should endeavor to attain over-correction with the least possible amount of dissection, because scar tissue impedes the reestablishment of the delicate function of finger movements.

Ischæmic Paralysis of the Arm.—*Volkmann's Paralysis.*—This affection is characterized by a diminution or loss of function in the forearm and hand due to fibrous degeneration of the forearm muscles. The cause of the degeneration is prolonged anæmia of the arm usually from the too tight application of bandages for the retention of splints in elbow fractures. In some instances the condition seems to be the result of injury sustained by the muscles at the time of the original trauma. Occasionally improvement may follow such muscle and tendon length-

ening as is useful in other muscular contractures of the forearm but where degeneration is so great that there is little hope of the functional recovery of the lengthened muscle some benefit may be obtained by removing a section of the middle of the radius and ulna, and so shortening the forearm.

The mechanical means of exercising and so treating muscular paralyses and contractures are very numerous.

The Zandler appliances are a type of the elaborate mechanisms suitable to large institutions. Simple lever weights, weight and pulley apparatus, or cords attached to rubber elastic bands or to springs are less complicated means to the same end. Whatever method of exercise is adopted, intelligent supervision is essential. The limb must be relaxed as much as possible, its weight must be supported, and such active or aided movements must be carried out as would result from the normal contraction of the muscle or group of muscles affected. When the mechanism is adjusted so as to render the necessary amount of aid, the affected muscle is exercised to the extent of its power. Normal muscles so exercised daily gain power, and the same is true of muscles weakened by disease. Progress is necessarily slow, but except when the power is entirely lost, improvement may be expected. When disease has affected only a few of the muscles of a limb or when some of the weakened muscles have recovered much more rapidly than others, muscular balance may be so disturbed that groups of muscles may undergo contracture and give rise to serious deformity.

When this is the case, daily passive motions are needed not to develop the stronger muscles but to so stretch them that they may not develop contractures. These exercises should be carefully and judiciously employed. When mechanical means are used there should be definitely stretching straps or apparatus and no developing exercises should be practised.

Where contractures have already developed, the condition is one which needs either mechanical stretching or surgical interference.

In the slighter cases mechanical stretching of the muscles is accomplished by bandaging the limb to a light brace which when first applied nearly fits the deformity but is straightened daily so that as soon as possible a position of correction or over-correction is attained. Complicated apparatus is not necessary.

Operative treatment may be necessary where long-lasting shortening of ligaments and muscles has given rise to a stubborn contracture. In

the upper extremity this usually consists in forcible rectification with the aid of an anæsthetic.

In straightening a contracted wrist or shoulder or where the fingers are held constantly flexed, tenotomy is sometimes needed or tendon lengthening, with, in some cases, the lengthening of fascial bands.

The methods of treatment here described are applicable to the stages first, of muscular flaccidity, second, of beginning contracture and third, of rigid contracture. In all three stages there is hope of spontaneous improvement of muscular strength. Improvement is the usual history of the disease in the year or even the two years following the original attack. The surgeon's efforts are more frequently demanded for relief in what may be termed the fourth stage, or the stage of permanent disability.

It is in this stage that surgical treatment is particularly gratifying, because while the relief given is never as great as could be desired, yet very much improvement may be obtained by the exercise of surgical skill and judgment, and without treatment no improvement can be expected.

A greater or less amount of spontaneous recovery is the rule in early cases of muscular paralysis and even in later stages, muscles which have been apparently paralyzed may have only been weakened through inaction and on being exercised, especially in occupational activities, regain their strength to a notable extent.

Such considerations necessarily temper the enthusiasm of the surgeon when judging the results of treatment but nevertheless it is certain that great benefit may be obtained by surgical intervention. The results in paralytic affections of the upper extremity are less gratifying than in those of the lower. The function of the lower extremity is that of locomotion or of furnishing a balanced support in standing, while the upper extremity is used in handicraft where a greater or less degree of skill and precision is requisite. To button clothing requires a more delicately complicated movement than does walking across a room. The surgical measures for the treatment of paralytic affections of the upper extremity are similar to those used for other paralytic deformities and may be described as muscle, tendon and ligament shortening; muscle, ligament and tendon lengthening; muscle transference or grafting and arthrodesis.

A detailed description of the technique of these operations is unnecessary as it is the same as when applied to other paralytic deformities but as these are differently indicated in different joints a

statement of the procedure most serviceable in each special joint may be of interest.

Shoulder-joint.—When the shoulder is affected in infantile paralysis there is either a flail joint or sufficient power is retained to enable the patient to move the limb in certain directions but *not* in others. The power of abducting and of raising the abducted arm upward is usually lost. Nerve grafting or nerve transference are of no avail as more power is needed than can be furnished by these procedures.

Power may be given to the arm by the scapular muscles; this is rendered possible by stiffening the shoulder-joint by some method of arthrodesis. The lost power of the deltoid may be restored by transferring to it part of the trapezius or pectoral muscles.

When arthrodesis is accomplished, a certain amount of motion is transmitted to the arm from the scapula, the scapula itself being moved by the action of the trapezius, pectorales, rhomboidei and latissimus dorsi.

Arthrodesis is the treatment of choice where the paralysis is great and the trapezius itself is weakened. The arm ought to be fixed in a somewhat abducted position in order to furnish as much play to the scapula as is possible in the upward movement of the arm.

The procedure is without difficulty as the joint is easily opened by a straight incision along the inner border of the deltoid. The incision should be free, the head of the humerus should be turned out as for excision and the cartilaginous surface removed by a strong knife. The cartilaginous surfaces of the portions of the scapula forming the joint should be removed by means of a gouge, and the arm secured in a position of abduction (50 deg. or more). Fixation is most readily accomplished by means of a plaster-of-Paris bandage. It is advisable in abducting the limb to allow for a certain amount of subsequent loss of abduction.

In young children where the amount of cartilage in the upper humeral epiphysis is great, it is so difficult to secure a proper degree of joint fixation after arthrodesis that transplantation of a periosteal flap may be of service in securing the requisite amount of joint stiffening. The periosteum can be stripped from the acromion and stitched to the upper portion of the humerus.

Where the paralysis is chiefly limited to the deltoid and the trapezius is relatively strong and large, muscle transference can be strongly recommended. The details of the procedure must be carefully planned and adapted to the needs of the individual case.

An incision is made upon the upper border of the trapezius in the neck, and a strong bundle of fibers freed by means of a blunt dissector, from the middle of the muscle down to its attachment along the ridge of the scapula. As much of the tendinous insertion of the muscle as is possible should be free and threaded by strong silk strands, care being taken to quilt the silk strands securely into the free ends of the bands of muscle and into the intramuscular fascia. These silk strands should be pushed by means of a carrier subcutaneously forward and drawn out through an incision made on the upper part of the arm near the shoulder, and sewed firmly into the deltoid humeral insertion or secured firmly in a hole drilled through the bone. This insertion should be to the side or to the front, according as it is desired to give more power to abduction or to a forward motion. A separately freed muscular bundle of the trapezius may be passed under the clavicle to reinforce the supraspinatus muscle in its function of abducting or raising the arm, but in many instances this is unnecessary as the supraspinatus is often unaffected. In some instances a portion of the pectoralis minor can be used if a strong bundle of that muscle is freed and divided a short distance from the coracoid process. The free end is secured to the humerus. This transference is chiefly useful to aid in the forward movement of the upper arm. The silk strands connecting the muscle bundles to the humerus should be as short as possible and should not be subjected to tension. For this purpose during the operation the arm ought to be raised so that the elbow is higher than the shoulder and it should be rotated outward. After operation the arm, extended straight upward, should be fixed by means of a plaster-of-Paris bandage for several weeks. After this lapse of time it is gradually lowered, but it is advisable to retain it for several months in a raised position and to follow this by systematic exercises.

Operative interference by muscle transference should never be undertaken in very recent cases and never in children before three years after the initial attack.

In adults, spontaneous recovery of deltoid paralysis is so rare that so long a delay is not necessary and either arthrodesis or muscle transference may be wisely performed a year after the initial attack.

In some instances of deltoid paralysis very satisfactory results have followed muscle transference, with half or three-quarter restoration of the lost function. The result is dependent on the strength of the transferred muscle, provided there is no failure in the operator's technique.

In some cases there is paralysis of the biceps, while the function of the triceps is intact; under these circumstances a transference of a portion of

the triceps into the biceps is a procedure of possible benefit as flexion is more important than extension in the ordinary use of an upper extremity.

The Elbow-joint.—In cases of "dangle arm," arthrodesis in a flexed position is to be considered. If there is objection to converting a flexible joint into a stiff one there are several substitute procedures:

(*a*) Limitation of extension by the removal of a skin flap from the anterior surface as practised by Jones of Liverpool.

(*b*) The dissection of a flap of fascia to be inserted into the anterior surface of the joint.

(*c*) The insertion of strands of silk to form an artificial ligament which will permit flexion but check extension at any point thought desirable.

Palsies of the Wrist and Hand.—The treatment of paralysis of the wrist and hand presents a difficult problem as delicate movements of the fingers and wrist are needed.

It is perhaps to be hoped that eventually the technique of nerve transference may be developed so that more practical results may be gained but hitherto the results obtained are not markedly beneficial to the patient, although they are of much surgical interest.

When there is complete palsy of all muscles of the forearm and hand, it is evident that there is no room for any surgical interference other than nerve grafting and, as has been said, this is of doubtful value. Usually, however, the paralysis is incomplete, certain muscular groups regain more or less power and the surgical question is whether in the stage of flaccid muscles the treatment should not be protective with local stimulation to the muscles.

For protection the limb should, as far as possible, be kept in the position of muscular equipoise, halfway between flexion and extension in a position favoring the evidently paralyzed muscles, when that can be determined. This position can be secured by plaster-of-Paris supports or by apparatus. The lightest and simplest supports are to be preferred and they should be arranged in such a way that the desired position of the limb is maintained with little or no bandage constriction which would limit the free circulation of blood in the arm and increase the tendency to atrophy. Wire support can be easily made, bent in any direction, and the limb secured to the support by means of tapes or adhesive straps; the hand should rest half opened, the forearm in a position midway between pronation and supination flexed at the elbow to a moderate degree and abducted from the thorax (Fig. 277 *a*, *b*, and *c*).

For stimulation of the circulation, massage and electricity are

standard remedies but simpler means may also be employed which are also effective. Heat applied either in the form of hot air or by means of hot water followed by cold applications may be used as an effective stimulant to the circulation. Hyperæmia by suction is also useful.

As soon as any power of motion has returned to any of the muscles, revitalization of the tissues should be attempted by means of active exercises of the muscles. Revitalization is not accomplished by passive movements, the effect of which is more in the joints, periarticular tissues and ligamentous bands, but by muscular action in active exercises.

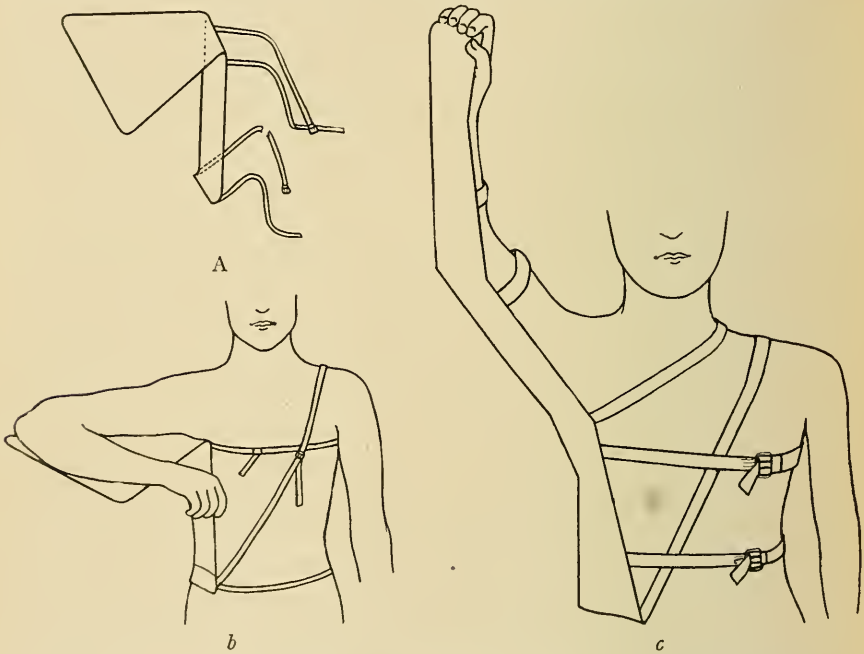

Fig. 277.—*a*, Covered wire splint for shoulder; *b*, wire splint applied; *c*, wire splint applied with arm extended.

It is evident that this treatment cannot be left to the patient's unaided efforts and in many cases it would be impossible owing to the slight amount of returning muscular power. While the muscles permanently paralyzed are not improved by gymnastic exercises those which are partially paralyzed and weakened may recover by being used under proper direction.

Where, as is usually the case, only certain groups of muscles remain permanently paralyzed, while others regain their function, the unbalanced muscular activity may produce deformity, the active muscles undergoing shortening because their activity is not resisted by their

opponents. Deformities of this character are common in paralytic affections of the lower extremity and in the upper extremity are chiefly seen in the hands and wrist.

Static influences, so important in developing deformities in paralytic affections of the lower extremity, are of comparatively little importance in the upper extremity.

Early Surgical Treatment.—The surgical treatment of paralytic affections of the upper extremity due to anterior poliomyelitis should be begun as soon as it is evident that a permanent paralysis is threatened.

After the first onset of the causal disease there is usually a stage of gradual improvement due probably to a recession of the congestion around the nerve centers in the spinal cord. When recovery is slow the indications for treatment are:

(*a*) To protect the flaccid muscles against over-strain or tension which would result in degeneration.

(*b*) To protect the active muscles from the changes of adaptive shortening due to the position of constant flexion assumed by the limb. This danger must not be overlooked, although it is of much less importance in the upper than the lower limb.

(*c*) To provide artificial vitalization for the flaccid muscles deprived as they are of the stimulus of exercise and normal function.

Physicians whose attention is turned especially to the patient's general condition or to the seat of the primary pathological lesion, *i.e.*, the spinal cord, often disregard the importance of protecting the patient from the peripheral muscular degeneration due to disuse of the limb and independent of trophic changes resulting from central nerve-cell destruction.

If it be remembered that a muscle unused is a muscle harmed, it will be evident that the muscles of a limb, the nerves of which are affected by poliomyelitis are in danger and are in need of treatment.

Deformities of the Upper Extremities.—Deformities of the upper extremity are either congenital or result from trauma or from destruction of tissues by disease. The present article will treat only of the congenital deformities. Those deformities following tuberculous or rheumatoid affections will be considered later.

Sprengel's Deformity.—*High Scapula—Congenital Elevation of Scapula.*—This deformity, first scientifically described by Sprengel, consists in a disturbed position of the scapula. The scapula appears prominent, lies obliquely and its inner border forms an unusual angle with the line of the vertebral spines. When the arm is at rest the bone

does not fall into its natural position, but its upper and inner angle projects. There is also an irregularity in the shape of the scapula both at its upper inner angle and at the acromion process. The deformity is usually unilateral. In the simplest cases the trouble seems due to shortening of the scapular muscles, *e.g.*, the trapezius. It is probable that the deformity is due to a delayed development rather than to muscular contraction or an abnormality in the nerve supply. Early in fœtal life the scapula occupies a high position; failure of the bone to descend results in deformity (Fig. 278, *a* and *b*).

The function of the arm is not severely impaired, but may be less strong and more awkward in use. The usual operative treatment of

a

b

FIG. 278.—*a* and *b*, Congenital elevation of scapula.

this deformity consists in an attempt to lower the scapula by lengthening any shortened muscles which seem to hold it in an elevated position. On palpation the shortened muscle or portion of muscle can be determined, freed by blunt dissection from its scapular attachment and the scapula placed in as low a position as possible. Later, muscular exercises are to be instituted. Satisfactory results from this procedure are not always obtained because the abnormal position of the bone is often maintained not simply by shortened muscle but by an abnormality in the shape of the scapula particularly in the ridge and at its articulation with the acromial end of the clavicle. In such a case no operation for muscle lengthening will be sufficient to correct deformity. The simplest bone operation consists in removing the prominent inner and

upper corner of the scapula, first freeing the attached muscles and sparing the periosteum.

Attempts have been made to relieve the deformity by correcting the faulty alignment of the scapula and clavicle by means of linear osteotomy of the acromion. During the healing of the bone, after osteotomy, the arm should be fixed in a raised position and the scapula held as exactly as possible in its normal position.

Angel-wing Paralysis. Scapula Alata. Serratus Paralysis.—Projecting scapulæ are not uncommon in muscularly weak, growing chil-

FIG. 279.—Winged scapular.

dren. The weight of the arms drags the scapulæ forward when they are not held by the action of the strong trapezius muscles. An asymmetrical distortion is due to abnormal muscular weakness or paralysis of certain muscles (the serratus being commonly involved) allowing the inner edge and lower angle of the scapula to project markedly from the back (Fig. 279). Muscle training and the use of a shoulder strap are

valuable palliative measures. Muscle shortening offers a possible operative treatment, but is of doubtful utility.

Bone Distortion of the Upper Extremity.—Variations in the shape of the scapula are common and are of little surgical importance, the same being true of variations in the curves of the clavicle. In some rigid types of round shoulder of rachitic nature, the forward position of the shoulder is fixed, owing to the exaggerated curves of the clavicle, a condition which can only be corrected by lengthening of the clavicle or by simple osteotomy.

Fig. 280.—Deformity of the upper arm due to rickets.

Rachitic curves of the humerus, at the elbow and of the forearm, though less common than rachitic curves of the lower extremity, are by no means uncommon (Fig. 280). In the humerus the curve is usually in the upper portion, in the elbow the deformity presents itself as outward or inward curves at the lower end of the humerus so that a condition analogous to knock knee or bow legs is developed. In

all these, correction is as easily obtained by means of linear osteotomy as in the curves of rickets of the lower extremity. In the majority of cases these curves are not of sufficient importance to justify operation, especially as the tendency is toward straightening by the process of bone growth, which for some reason, tends toward the normal type.

Madelung's Deformity.—A condition at the wrist is occasionally observed, the pathology of which is not yet entirely known. The wrist is distorted, presenting an appearance resembling somewhat that seen in the silver fork deformity of fracture, but to a less degree and with less lateral projection of the end of the ulna. The condition is not traumatic and in all probability is due to a distortion of growth, changing the plane of the facets of the articulation. There is usually some laxity of the ligaments; the distortion may involve both the carpal end of the ulna and radius or may be more marked in one bone. The deformity is not accompanied by pain and the symptoms rarely justify operative treatment by linear osteotomy. In children, during the developmental stage of the affection, mechanical treatment, *i.e.*, a supporting splint worn for a time, may be worthy of consideration.

Slipping Shoulder.—*Habitual Dislocation of Shoulder.*—A relaxed condition of the capsule holding the head of the humerus in place is often the occasion of much discomfort, from the frequent recurrence of dislocation of the shoulder. In some cases the condition results from a severe dislocation with resultant stretching of the retaining ligaments: in other cases the affection seems to be due to a relaxed condition of the capsule, either congenital or acquired. The operative treatment is simple, consisting of shortening of the ligaments and stitching a fold in the joint capsule.

Absence of Bones of the Forearm and Club Hand.—A congenital absence of the radius or its rudimentary development with malposition of the hand in a most unsightly deformity. The hand is placed at an angle with the forearm projecting inward, the fingers move normally and the hand and arm are serviceable, although usually shorter and weaker than normal (Fig. 281). The deformity may be double, but is usually single.

A skiagram of the deformity shows an absence of the shaft of the radius with the presence of the epiphysis, the ulna being slightly bent. In some instances there is an absence of a digit; in others the hand is perfect and the carpal bones and the wrist-joint are normal, as are also the muscles of the forearm and hand.

The usual operation for this deformity is that of replacing the carpus

so that the hand is in line with the arm instead of at an angle with it. The wrist-joint is opened and after division of the ulna near the wrist and twisting of the hand the carpus can be brought into a more normal position. The lower rudimentary epiphysis of the radius can be brought down and stitched to the ulna, making the articulation transverse instead of oblique to the long axis of the arm. It is probably that bone grafting can be used to fill the gap in the radius but as the operation of bone grafting is still young, it is impossible to say how large a gap can

Fig. 281.—Club hand and absence of the radius and thumb.

be filled to the practical advantage of the patient. As a matter of fact the deformed arm with the hand turned inward and the palm facing backward is sometimes very serviceable. If operation is performed, it is important that the hand should be placed upon the ulna in a position midway between pronation and supination or perhaps better in a position of extreme pronation. Where the lower epiphysis of the radius is wanting, the operation indicated consists of splitting the terminal end

of the ulna, inserting the carpus between the two halves. There is, however, danger of stiffness of the wrist as a terminal result. The chief reasons for the operation for the correction of this deformity are cosmetic rather than utilitarian, as the resulting hand is not more and may be less serviceable after than before the operation. The deformity is, however, a conspicuous and therefore a distressing one.

Synostosis of the Bone of the Forearm.—Analogous to club hand as a surgical problem is a rare deformity, viz., a partial congenital synostosis of the radius to the ulna with the arm in a fixed position of half pronation. The deformity is not disfiguring and the arm is useful and

Fig. 282.—Congenital deformity of the hand, supernumerary thumb.

operative interference separating the two bones is of doubtful utility.

Fusion or Reduplication of Digits.—An adequate study of these defects would exceed the limits of this article but certain deformities of surgical importance will be mentioned as their relief demands surgical interference. The reduplications of the thumbs or little fingers (*i.e.*, on the outer or inner side of the hand) may be and usually are partial, the finger being either a pedunculated excrescence or a broadened and unsightly thumb, two phalanges projecting from one metacarpal and covered by the same skin, or the supernumerary finger may be complete (Fig. 282). In some instances the thumb is absent and in its place a supernumerary finger is present. The surgical treatment of these defects is simple. Removal of the digit offers no difficulty and gives excellent cosmetic results. In some of the reduplications a most unsightly arm exists for which no treatment is possible, except amputa-

tion or such removal of distorted parts as materially impairs the serviceableness of the limb.

FIG. 283.—Congenital deformity of hand.

Webbed Fingers.—In certain cases the congenital deformity of fusion is presented in the form of a lack of division of the skin covering two

FIG. 284.—Congenital deformity of the hand. Notice deformity and peculiar position of the first and fifth fingers and webbed second, third and fourth fingers. (*Bradford.*)

or more fingers (Fig. 283). In extreme instances the whole hand, including the thumb, is covered by one piece of skin like a bag, there being no evidence of fingers except in the flexion of the different parts

(Fig. 284). In the milder cases only the bases of the fingers are united by a common band of skin. More commonly only two of the fingers are covered by a common skin covering; on palpation and by skiagram it is seen that phalanges are normal and from previous experience it may be assumed that the muscles are normal so that if the skin uniting the two fingers is divided their normal usefulness may be gained.

If the band of skin uniting the fingers is small as in the rare cases where only the finger tips are united, a simple incision is all that is necessary but in all other cases simple division is practically certain to be followed by recurrence or disabling scar formation. Flap operations are, therefore, chosen and may be done by dissecting the skin freely from the dorsum of one finger and from the palmar surface of the other annex finger. The freed flap is folded around the uncovered surface of each finger. If any remaining tissue still unites the fingers after the dissection of the skin flaps, it should be divided and if the incisions are properly made the whole bared surface can be covered and should heal under suitable after-treatment.

Trigger Finger.—Normally the tendons play smoothly in their sheaths which, at the finer articulations, are reinforced by strong ligamentous bands which keep the tendon in place when the finger is bent. Any inequality in the section of the tendon interferes with this neat mechanism, the movement being checked until the enlarged portion of the tendon is squeezed through the constricted portion of the sheath. The characteristic snapping sensation gives the name to this affection.

Surgical relief can be given by cutting down on the tendon sheath and dividing the constricted reinforcing band. When the enlargement of the tendon is pedunculated, it should be removed. Where it is a fusiform thickening there is danger of injury to the tendon or of the formation of adhesions between tendon and sheath, and the treatment is usually limited to division of the transverse bands.

Dupuytren's Contracture.—"The palmar fascia forms a common sheath which invests the muscles of the hand. It consists of a central and two lateral portions.

"The central portion occupies the middle of the palm, is triangular in shape, of great strength and thickness, and binds down the tendons in this situation. It is narrow above, being attached to the lower margin of the annular ligament, and receives the expanded tendon of the palmaris longus muscle. Below it is broad and expanded and opposite the heads of the metacarpal bones divides into four slips for the four fingers. Each slip subdivides into two processes which inclose the

tendons of the flexor muscles and are attached to the sides of the first phalanx and to the anterior ligament; by this arrangement four arches are formed, under which the flexor tendons pass. The intervals left in the fascia between the four fibrous slips transmit the digital vessels and nerves and the tendons of the lumbricales. At the points of division of the palmar fascia into the slips above mentioned, numerous strong transverse fibers bind the separate processes together. The palmar fascia is intimately adherent to integument by numerous fibrous bands and gives origin by its inner margin to the palmaris brevis; it covers the superficial palmar arch, the tendons of the flexor muscles, and the branches of the median and ulnar nerves; and on each side it gives off a vertical septum which is continuous with the interosseous aponeurosis and separates the lateral from the middle palmar group of muscles" (Gray's Anatomy).

As a result of repeated traumata, *e.g.*, from the handling of tools, from some diathesis such as gout or from unknown causes, there may arise a thickening, hardening and contraction of the palmar fascia. Dupuytren's contracture rarely appears under 30 years of age and is more common in males. It almost invariably affects the fourth or ring finger first and later the little finger. Any or all the fingers including the thumb may be involved. The first sign of trouble is a nodular callosity in the palm over the metacarpo-phalangeal articulation of the ring finger. As the nodule grows, the finger is gradually and permanently flexed at the proximal joint. The skin over the affected area is thin, adherent to the underlying fascia and dimpled. In severe cases the tip of the flexed finger may be forced against the palm. The tendons are unaffected, the lesion being entirely limited to the palmar fascia. The only deformities with which Dupuytren's contracture could be confused are those following acute infections of the hand and the history prevents such a mistake being made. Disability and annoyance from the deformity call for treatment.

In the early stages of the trouble it is possible that the use of posterior splints at night may hinder the appearance of deformity but few if any patients would have the preseverance to carry out the treatment. When contracture is present it is said that injections of fibrolysin lead to improvement or even cure. The most satisfactory treatment is operative. It is easy, under local anæsthesia, to overcome the contraction by multiple, subcutaneous section of the tense bands of fascia. After operation the fingers must be kept extended by a suitable splint for at least a week and after that time a simple splint should be applied

every night for several weeks. Subcutaneous section is usually followed by recurrence but the recurrence may be so delayed and the operation is so trivial that many patients prefer repeated section to a more formidable radical operation.

Radical operation consists in the systematic excision of the whole of the contracted palmar fascia with its prolongations. The operation is very satisfactory.

Tuberculosis of the bones and joints will be treated elsewhere. A word as to the peculiarities of tuberculosis of the upper extremity may, however, not be out of place in this chapter on orthopedics.

Tuberculosis of the Shoulder.—The disease is usually in the head of the humerus, rarely in the scapula. Abscess occurs frequently. Sometimes the disease may be dry (caries sicca) with increased tendency to ankylosis.

Symptoms.—There is a gradually increasing disability, atrophy, pain, tenderness, limitation of motion, spasm of the muscles; the pain is not intense in character and it may be accompanied by shooting pains along the nerves, upward and downward; sometimes there is local heat; swelling is common early, to be replaced later by atrophy.

The treatment should be protection from jar and motion by means of plaster-of-Paris dressings or of a wire splint to maintain the arm in an abducted position. In extreme cases partial excision may be necessary but should be avoided in children on account of injury to the epiphysis. It may be done in adults, though rarely.

Tuberculosis of the Elbow.—The ulna or the external condyle is more frequently affected than the radius. There is gradual increasing disability, atrophy, limitation of motion, spasm of the muscles and a dull pain with sensitiveness to pressure. Fluctuation is absent unless there is abscess.

Treatment.—It is possible here to immobilize very perfectly by a plaster, leather or celluloid splint, maintaining the elbow at right angles with the forearm and in a position midway between pronation and supination. In early cases extremely good results are obtained with almost perfect return of motion. Operative interference is to be avoided, except in extreme cases, even when the skiagram shows a distinct focus. Excision should not be done in children. It is, however, advisable in adults when the disease is extremely bad.

Tuberculosis of the Wrist.—Tuberculosis of the wrist is not one of the common forms of tuberculosis and occurs more frequently in adults than in children. One or more of the carpal bones may be involved.

Treatment.—Absolute rest in a plaster-of-Paris, celluloid or leather splint is often the best treatment. Where prolonged conservative methods are not sufficient or when there is a discharging sinus, excision of the whole carpus may give a good result as to function but as Ollier points out it is important for this purpose to remove all the bones of the carpus. This may be done by an anterior and posterior incision. Removing simply the diseased portion of the bone alone is not sufficient. In the metacarpals and phalanges, excision of the focus is often of distinct advantage where conservative treatment has failed.

Spina ventosa or tuberculosis or low-grade disease of the long bones of the fingers or metacarpals is more common in infants or small children than in older subjects. The symptoms are pain, sensitiveness on pressure, spindle-shape swelling. It should be treated by absolute rest to the finger and hand. Where an abscess or a sinus demands operative interference, simple incision is not sufficient but a cut should be made slightly to the side of the median line, the tendons retracted and the bone opened by means of an osteotome so that its cavity may be wiped out thoroughly. This is the treatment of choice. The ends of the bone should be avoided in order not to injure the epiphyses. Where incision of the soft tissues without the opening and wiping out of the bone is done further infection is the rule and palmar abscess may occur. Absolute immobilization with tubular drainage for 10 days should follow the operation, after which immobilization should be kept up until all inflammatory signs have subsided. In some cases there is a return of motion of the joints above and below the diseased bone.

Arthritis.—The proliferative or degenerative processes occurring in the various forms of arthritis are the same in the upper extremity as elsewhere. There are certain points in arthritis of the upper extremity which will be considered briefly.

There is a form which follows exposure to cold or tonsillitis. Sometimes the actual irritating cause may be difficult to find.

Arthritis of the Shoulder.—In acute arthritis of the shoulder there is pain, limitation of motion and tenderness often at the bicipital groove just below the acromion. The limitations of motion and pain on attempted motion are more marked in abduction and outward rotation; sensitiveness to jar and pressure are felt, especially at night. Weakness and numbness are often present. There is marked atrophy. During the acute stage immobilization is indicated, generally in an abducted position. As sensitiveness to jars and motion grow less, gentle exercises are indicated.

Acute or Chronic Bursitis of the Shoulder.—The bursæ most commonly involved are the subcoracoid, subscapular and subdeltoid. There is often intense pain and swelling in the region of the bursa. Heat or extreme cold is often of benefit, together with liniments.

In the elbow, wrist and hand the joints may be more easily exercised to advantage and are very much improved by hyperæmia treatment such as is recommended by Professor Bier. Stasis by vacuum or by a carefully applied Esmarch bandage is beneficial when applied loosely as prescribed by Bier. Massage and irritation of the joints should be avoided. Massage of the soft tissues and unaffected parts of the limb is often beneficial. Exercises are of value in preventing the deformities, contractures and partial dislocations which may occur later. They are often of benefit, even when these deformities are present. The periarticular thickening and general swelling of the soft tissues is sometimes markedly decreased by hyperæmia treatment.

SECTION VI

OPERATIONS UPON THE UPPER EXTREMITY

By

J. F. BINNIE, A.M., C.M., F.A.C.S.

AMPUTATIONS AND DISARTICULATIONS

Amputations of the Fingers.—When amputating a finger one ought to sacrifice as little of the finger as possible as long as the retained part is sufficiently provided with properly inserted tendons. In the event that symmetry of the hand is to be considered rather than usefulness, the above rule need not apply.

Disarticulation of Distal or Middle Phalanx.—Flex the phalanx completely. Make a transverse, dorsal incision opening the joint from one side to the other. Divide the lateral ligaments. From each end of the transverse incision make lateral incisions penetrating to the bone of the phalanx to be removed. Separate the phalanx from the soft parts on its palmar aspect so as to form a palmar flap long enough to cover the stump (Fig. 285).

Remove the phalanx. Trim the palmar flap if necessary. Attend to hemostasis. Suture. The resultant scar is dorsal.

Amputation through the Proximal Phalanx.—Reflect the soft parts by a circular incision or by flaps. Divide the bone, preferably with a Gigli saw. Suture the divided tendons to the contiguous theca. Attend to hemostasis. Close the wound.

Disarticulation at the Metacarpo-phalangeal or at the Metacarpo-carpal Joints.—Figures 286, 287, 288, 289, 290, 291 sufficiently describe these operations. Note that none of the longitudinal incisions are made in the palm. In metacarpo-phalangeal disarticulations the head of the metacarpus should be excised (Fig. 287) to avoid a deforming and disabling protuberance. "When removing the metacarpus of the thumb or of the little finger it is very important to preserve intact the short muscles of the thenar and hypothenar eminences, because by so doing a very useful and movable stump is obtained, especially if the bone is removed subperiosteally" (Kocher).

Amputation or Disarticulation at the Wrist.—Do not perform a typical amputation if it is at all possible to save a portion of the hand or a movable finger.

Amputation of the Forearm.—Form an anterior and a posterior flap of skin and deep fascia. The combined length of the flaps should equal one and one-half times the diameter of the limb at the point of bone section. Reflect the flaps. Divide the muscles and deep structures by a circular incision and retract them to the site chosen for division of the bones. Divide the periosteum at a level about 2 in. *above* the line of bone section and separate it from the bones downward. Saw through the radius and ulna. With a curette remove the marrow for a depth of about ⅓ in. Depriving the end of the bone of its periosteum and of its marrow favors the formation of a non-tender stump (Hirsch and Bunge).

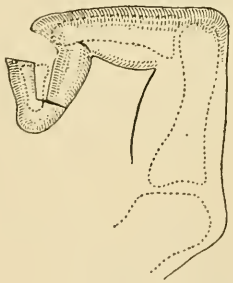

Fig. 285.

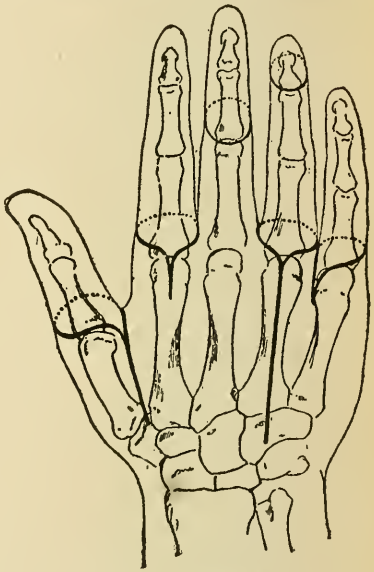

Fig. 286.—(*Kocher.*)

Pull the divided nerve trunks out of their sheaths for a short distance and divide them as high up as possible. This is done to avoid the formation of painful neuromata. Attend to hemostasis. Suture the flexor to the extensor muscles and tendons. Unite the flaps by suturing the deep fascia and the skin.

A typical operation such as described is rarely performed. The surgeon must make his flaps out of any available material left by the disease or the trauma which has demanded the amputation.

Cinematic or Plastic Amputations.—Vanghetti has devised methods by which the tendons of the forearm (left long during the amputation) are formed into loops covered by skin. To these loops cords are later applied and connected with an artificial hand. Contractions of the muscles are communicated to the artificial fingers through the

cords. Recent improvements in the manufacture of artificial hands and arms have rendered cinematic amputations unnecessary.

Disarticulation at the Elbow.—Make a circular incision through the skin and deep fascia about 2 in. below the condyles of the humerus. Reflect the skin and fascia upward until the joint is exposed. Strongly extend the joint and open it by an anterior transverse incision. Divide the lateral ligaments. Hyperextend the joint until the olecranon projects into the wound. Divide the triceps tendon at its insertion. Attend to hemostasis. Close the wound.

Amputation of the Arm.—The method of operating requires no

FIG. 287.—(*Vean.*)

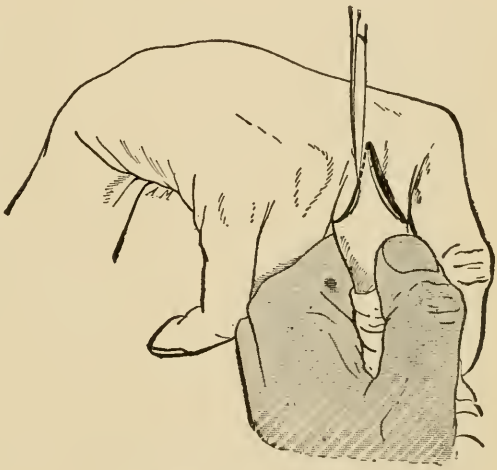

FIG. 288.—(*Vean.*)

special mention. For the efficient use of a good artificial arm a stump *at least* 4 in. long is necessary. The longer the stump the better. It is a great advantage if part of the inferior expansion of the humerus can be retained.

Disarticulation at the Shoulder.—Methods of preventive hemostasis.

(*a*) Preliminary ligation of the subclavian artery. This is valuable in case of large vascular tumors about the head of the humerus.

(*b*) Application of an elastic constrictor tightly round the shoulder proximal to the coracoid and acromion process. To prevent slipping, a loop of bandage may be passed under the constrictor and pulled toward the opposite shoulder by an assistant.

Method A.—Spence's Operation.—Slightly abduct the arm and rotate it outward. Make an incision downward from a point just external to the coracoid process to the insertion of the pectoralis major. Divide the clavicular fibers of the deltoid and the pectoralis major. From the lower end of this incision cut across the front and outer side of the arm in a horizontal curve (convex below) until the posterior or axillary fold is reached. This horizontal incision penetrates to the bone.

Continue the horizontal incision across the inner or axillary side of the arm until the arm is completely encircled. The axillary cut penetrates only the skin and superficial fat. Separate the outer flap from the bone and joint, being careful to avoid injuring the posterior

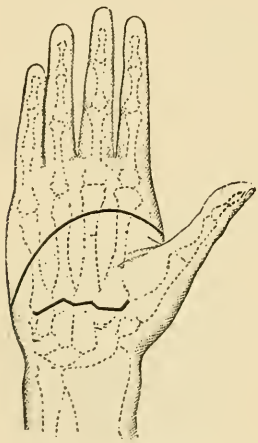

FIG. 289.—(*Esmarch and Kowalzig.*)

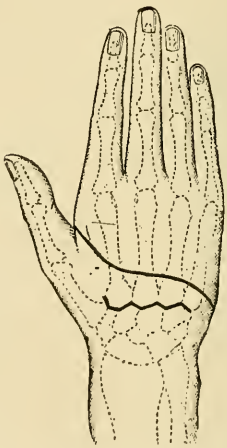

FIG. 290.—(*Esmarch and Kowalzig.*)

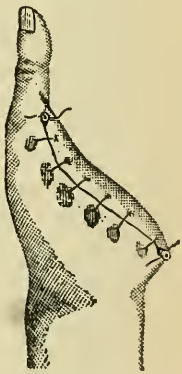

FIG. 291.—(*Esmarch and Kowalzig.*)

circumflex vessels; otherwise the nutrition of the flap is jeopardized. Divide the tendons inserted into the tuberosities of the humerus. Dislocate the head of the humerus by dissection and manipulation. The arm is now attached to the body by the axillary tissues alone which are easily grasped by an assistant or in the jaws of a strong gastroenterostomy clamp. This secures temporary hemostasis. Complete the amputation by dividing the axillary tissues. Attend to hemostasis. Close the wound.

Method B.—Flap Operation.—Place the patient with his shoulder over the edge of the table. Relax the deltoid by elevating the arm. Lift the deltoid with the left hand. Introduce a long, narrow, strong knife at a point immediately below the coracoid and pass it under the deltoid, close to the anatomical neck of the humerus, to emerge through

the skin at a point a little below the most prominent part of the acromion. Cut downward and then outward so as to construct a flap consisting of the deltoid (down to its insertion) and the skin covering it. Reflect the flap so as to expose the joint. Divide the muscles inserted into the tuberosities as well as the long head of the biceps. By dissection or manipulation, dislocate the head of the humerus. Divide the joint capsule behind the humeral head. Grasp the undivided tissues (containing the axillary vessels) with the hand or a suitable clamp. Slip the knife behind the head of the bone and cut an axillary flap half the length of the deltoid flap. Attend to hemostasis. Close the wound.

Method C.—Crile's Method.—Under infiltration anæsthesia (novocaine ½ per cent.) expose the trunks of the brachial plexus and the subclavian artery. Inject the nerve trunks with ½ per cent. cocaine or 1 per cent. quinine and urea solution. This blocking causes complete anæsthesia in the parts supplied by the plexus. Apply Crile's clamp to the subclavian artery. The arm may now be amputated by any method, provided that the cuts on the outer and posterior aspects over the deltoid are made at a low level to avoid skin supplied by the non-anæsthetized cervical plexus.

Interscapulo-thoracic Amputation.—*Le Conte's Method.*—Beginning at its sternal end, make an incision along the clavicle. When the middle of the bone is reached, continue the cut downward in a curve to the anterior axillary fold. Expose the inner two-thirds of the clavicle and disarticulate it at its sternal end. Divide the clavicular attachment of the sterno-mastoid close to the bone. With the finger separate the clavicular from the costal fibers of the pectoralis major down to the anterior axillary fold. Pull the clavicle upward and forward and divide the attachment of the subclavius muscle at the first rib. Expose and divide the pectoralis minor; retract its coracoid portion upward.

This exposes the axillary vessels and nerves very thoroughly. Open the sheath of the vessels high up. Doubly ligate and divide the artery. Elevate the arm to drain it of blood and then doubly ligate and divide the vein. Inject the exposed trunks of the brachial plexus of nerves with ½ per cent. novocaine or 1 per cent. quinine and urea solution. This nerve blocking lessens the amount of general anæsthetic required and diminishes shock markedly.

From a suitable point on the anterior incision make a cut backward and downward to the inferior angle of the scapula and then upward to the posterior axillary fold. Dissect up the skin and superficial fascia for a short distance. Divide the trapezius and clamp the transversalis

colli or posterior scapular artery. Divide the muscles attached to the vertebral border of the scapula close to the bone. Divide the serratus magnus and the latissimus dorsi, the latter at the posterior axillary fold. If there is sufficient flap to cover the huge wound, complete the amputation by joining the anterior and posterior incisions through the axilla; if more skin is required, form a flap from the under surface of the arm.

Attend to hemostasis. Close the wound after providing for drainage.

OPERATIONS ON THE SHOULDER-JOINT

Aspiration or injection of the shoulder-joint is very easy when the joint is distended with fluid, as it is in cases suitable for the operation. The trocar must be introduced either just external to the coracoid process or external to the angle formed by the junction of the acromion process with the spine of the scapula.

Arthrotomy for Exploration or Drainage.—From the posterior prominence of the acromion process make an incision downward along the posterior border of the deltoid. Open and penetrate the subdeltoid bursa. Retract the edges of the wound so as to demonstrate the infraspinatus and teres minor crossing the capsule of the joint. Open and explore the joint if the latter is necessary. Efficient tubular drainage may be easily provided through the above incision or the joint may be closed by sutures.

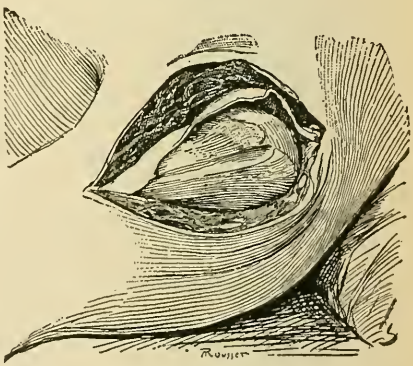

FIG. 292.—Excision of shoulder. (*Schwartz.*)

Before closing the wound it is sometimes good to fill the articulation with iodoform emulsion (or its equivalent).

Arthrectomy.—*Subperiosteal Method of Ollier.*—The arm being abducted, make an incision from a point external to the coracoid and about ½ in. below the clavicle, downward and outward for about 5 in. parallel to the fibers of the deltoid. Penetrate the deltoid a little external to its inner border. Rotate the arm until the bicipital groove is recognized. Incise the articular capsule freely parallel and external to the tendon of the biceps (Fig. 292). With a sharp elevator scrape the periosteum and tendinous insertions from the internal and external tuberosities of the humerus. If the structures have not been softened by disease this separation is so difficult that it is well

to save time and trauma by chiselling off a shell of bone along with the tendons and periosteum. With the elevator separate the posterior and lateral fibrous attachments from the bone. Dislocate the head of the bone through the wound. Saw off as much of the upper end of the humerus as is necessary. In children it is wise to remove foci of disease by means of chisel and sharp spoon rather than to typically resect. Avoidance of injury to the epiphyseal cartilage in the young is of great importance to prevent interference with subsequent growth. After treating the head of the humerus, examine the glenoid cavity and remove any disease which may be present in it. Carefully dissect away all diseased synovialis and any sinuses which may be present. If the lesion present is tuberculous and there is no secondary infection, fill the wound cavity with iodoform emulsion or its equivalent and close without drainage. If secondary infection is present provide tubular drainage through an appropriate posterior incision and partially close the main wound with sutures. Apply dressings. It is necessary to apply a large axillary pad and to bandage the elbow and forearm to the chest in order to prevent the upper end of the humerus from becoming displaced inward. No passive movements must be attempted for at least eight weeks in order to permit the bone to become somewhat fixed in its new position; otherwise a "flail joint" may result.

If the excision of the upper end of the humerus is necessitated by malignant disease the periosteum and tendinous insertions ought to be removed along with the bone. If so much bone has been removed that a "flail joint" is certain to result, one may expose and resect a suitable segment of the fibula, including its head, insert the cut end of the fibula like a peg into the medullary cavity of the shaft of the humerus, place the head of the fibula against the glenoid cavity and fix it by sutures to the remnants of the articular capsule of the shoulder. In excising the fibula it is convenient, for suturing purposes, to leave some of the soft structures attached to the bone.

When a "flail joint" results from an extensive resection for tuberculous or other infective disease, a similar transplantation of bone may be valuable even if it should be necessary to nail or otherwise fix the upper end of the transplant to one of the scapular processes and obtain anchylosis.

Injuries to the Supraspinatus Tendon.—Codman has shown that the deltoid can act efficiently as an abductor only after the supraspinatus has pulled the head of the humerus firmly against the scapular

portions of the articulation. Injury to the supraspinatus tendon thus is capable of causing much disability.

Usually such a rupture of the tendon may be exposed and repaired through an incision such as is made for the treatment of subacromial bursitis.

Operation for Subacromial Bursitis.—Split the deltoid through an incision near its anterior margin running downward for about 2½ in. from a point midway between the coracoid and acromion processes. This exposes the bursa and permits the excision of its thickened and adherent portions (Fig. 293). Motion may be begun in about 10 days after operation. Occasionally the above method does not suffice and

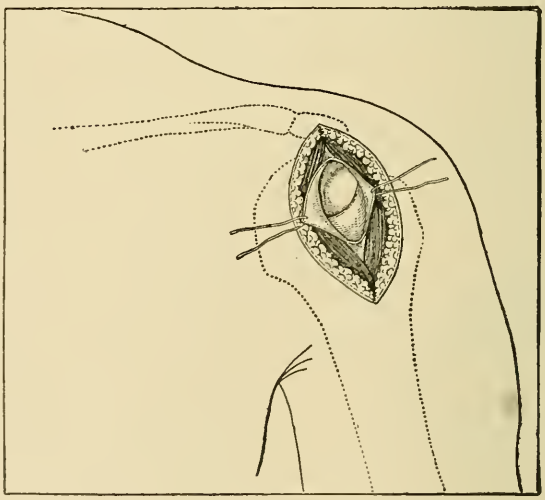

FIG. 293.—Codman's bursitis. (*Codman.*)

Codman has devised what he calls a "sabre-cut" incision by means of which very free access is obtained to the injured parts. The incision is specially valuable for exploration of the joint and for the treatment of fracture dislocations or of irreducible dislocations.

Codman's Sabre-cut Arthrotomy.—Prolong the bursal incision (see preceding paragraph) directly back over the shoulder at the root of the acromion process. Divide the acromioclavicular joint. With a Gigli saw divide the base of the acromion process being careful not to injure the suprascapular nerve as it winds through the great scapular notch. After division of a few fibers of the trapezius, retract outward the acromion process and with it the deltoid and the whole outer half of the wound just as if one opened the upper part of the seam of a coat

sleeve and looked in at the top of the shoulder. If the supraspinatus has been torn, the articular surface of the joint is visible; otherwise that muscle must be divided before proper exposure is obtained. When the active operation has been completed it is easy to suture the acromio-clavicular joint because there is firm fibrous tissue all about it. The acromion may be united either by wiring or by suture of the surrounding soft parts. The operation is not suitable for tuberculous or inflammatory conditions.

Arthroplasty.—Expose the joint through Ollier's incision. Thoroughly mobilize the joint by dissecting away all obstructing scar tissue and, in bony anchylosis, by resecting and modelling the head of the humerus. It is essential that very free mobility be obtained. To prevent reformation of the anchylosis it is necessary to completely cover the head of the humerus with some animal tissue. This may be done in several ways: (1) by means of a pedunculated flap of fat and fascia obtained from the chest wall; (2) by means of a pedunculated flap of the pectoralis major muscle, the pedicle of the flap being formed by part of the humeral insertion of the muscle; (3) by a free, *i.e.*, not pedunculated, flap of fat or fascia taken from the patient himself; (4) by some prepared animal membrane such as that prepared by Baer (Johns Hopkins Bulletin, Sept., 1909) from the bladder of a pig, or by Schmerz (Zent. f. Chir., Oct. 14, 1911) from hernial sac or amnion.

Arthrodesis.—When a "flail joint" has resulted from paralysis but there is no paralysis of the muscles uniting the scapula to the trunk or of those of the elbow and hand, the patient may largely regain the use of his arm if the shoulder-joint is put in a condition of stable anchylosis. If the elbow muscles are also paralyzed by those serving the hand are intact, the elbow may also be subjected to the operation of arthrodesis.

The Operation.—Owing to degeneration of the deltoid muscle and of the circumflex nerve in cases suitable for operation, access to the joint is very easy and the incision may be made in any convenient place. When the joint is freely opened, its synovialis should be excised and all the cartilage should be removed from the head of the humerus and the glenoid fossa. The under-surface of the acromion process must also by vivified with knife or chisel. The head of the humerus is now placed in contact with the vivified surfaces of the glenoid and acromion processes and held firmly by wires passed through appropriate holes drilled in the humerus and the glenoid and acromion processes. The humerus ought to be in a position of slight internal rotation and at an angle of about 45° to the outer border of the scapula.

Immobilization must be kept up by means of splints until bony union has been secured.

OPERATIONS ON THE ELBOW-JOINT

Intra-articular Injections.—It is easy to penetrate the joint by introducing a trocar immediately above the head of the radius and at right angles to the long axis of the limb.

Arthrotomy for Drainage.—Occasionally a small incision into the elbow-joint is useful for purposes of drainage. The arm being flexed to an angle of about 150°, one may make a short incision posteriorly between the olecranon and the humero-radial articulation and through this enter the joint. If a counter-opening is necessary a forceps may be passed through the joint to the base of the internal epicondyle anteriorly and an incision made through the skin so as to expose the end of the forceps.

Arthrectomy; Resection; Excision.—Many incisions have been devised for the exposure of the elbow-joint—median, lateral, bayonet-shaped, transverse, etc. Of these only the median longitudinal and the transverse will be described.

Median Incision. Classical Method.—The arm being held steadily in a position of partial flexion, a median longitudinal incision is made from a point 2 in. above to one 2 in. below the tip of the olecranon. This cut penetrates to the bone and opens the posterior part of the joint. With periosteal elevator and knife the periosteum and soft parts are separated from the olecranon and the lower end of the humerus until the internal epicondyle can project into the wound. If the edge of the knife is constantly kept directed against the bone and the soft parts are well retracted as soon as mobilized, the ulnar nerve ought to escape all danger of injury and in fact be retracted along with the other tissues without being recognized. When the structures on the outer side of the elbow have been treated in the same way as those on the inner side the result is complete decortication of the posterior and lateral surfaces of the bones forming the elbow. If the elbow be now completely flexed, it is easy to push the lower end of the humerus out of the wound, to separate it from the soft structures in front and to saw off as much of the bone as seems desirable. After the humerus has been divided the articular ends of the ulna and radius are similarly made to protrude through the wound and are removed with a saw.

Any diseased synovialis must be removed by dissection and if any

foci of disease are discovered in the bones, such must be removed by the chisel or sharp spoon.

In dividing the bones, where ought the lines of section to be situated? Along with the olecranon process the two sigmoid cavities of the ulna ought to be removed and the radius divided at the same level just below its head. From the humerus it is common to remove too little bone. Jacobson considers that the saw ought to be used above the level of the epicondyle and through the highest part of the epitrochlea, removing the lower two-thirds of this process.

After bleeding has been attended to, the skin wound is closed with or without drainage by means of rubber tissue, and dressings are applied. The limb should be immobilized in a moulded plaster-of-Paris splint applied either anteriorly or posteriorly. As soon as the wound has healed, passive and later active movements should be instituted.

If the operation has been performed for anchylosis, a flap of fat and fascia, obtained from the forearm, may be carefully wrapped around the lower end of the humerus after the joint has been excised. The presence of this flap prevents recurrence of the anchylosis and provides material suitable for the formation of a new synovialis.

Posterior or Transverse Incision.—Rutherford Morison makes an incision about 2 in. in length from the tip of the internal condyle upward along the intermuscular septum. Through this cut it is easy to expose and protect the ulnar nerve. He then makes a similar incision on the outer side of the elbow and joins the two by a curved transverse cut. After turning down the skin flap thus outlined for about 1 in., he divides the triceps transversely and reflects the skin flap and the triceps tendon downward. This gives good access to the joint. After the necessary resection has been completed the triceps tendon is carefully sutured and the wound closed.

Instead of dividing the tendon of the triceps, some surgeons saw through the olecranon process and reflect the mobilized bone upward with the triceps. Subsequently the olecranon must be replaced and secured by wire or a nail.

EXCISION OF THE WRIST

Typical or complete excision of the wrist means section of the radius and ulna above the joint and removal of all the carpal bones. Such extensive work is comparatively rarely required and when disease is so extensive as to call for it, then the question of amputation as a really

more conservative and desirable treatment must be seriously considered. As a rule operation is demanded because of tuberculosis, and commonly evidement of the evidently diseased bones by means of sharp spoons and chisels through any convenient incision is all that is required. Ollier's subperiosteal method may be taken as typical. Make an incision from the middle of the second metacarpal bone upward and inward along the radial side of the tendon of the extensor indicis (Fig. 294).

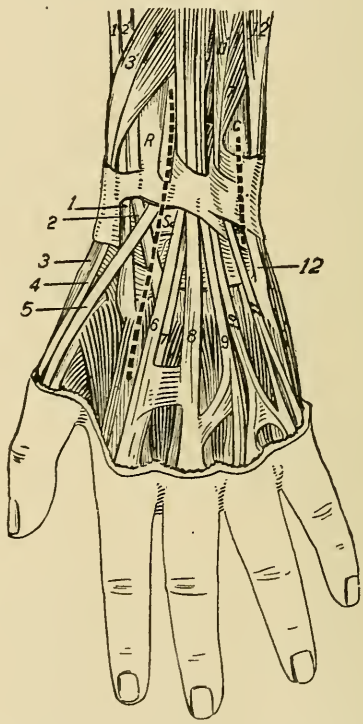

FIG. 294.—Ollier's operation. (*After Farabeuf.*)

R', Radius; *C*, ulna; *Sc.*, scaphoid; *t*, trapezoid· 1-1', tendon ext. carpi radialis long.; 2-2', ext. carpi radialis brevior; 3-3', ext. ossis metacarpi pollicis; 4-4', ext. brevis pollicis; 5-5', ext. longus pollicis; 6-8-9-10, ext. communis; 7-7', ext. indicis; 11-11', ext. minim. dig.; 12-12', ext. carpi ulnaris.

This oblique incision extends to the interstyloid line and is then carried up in the axis of the forearm for a short distance. Retract the tendon of the extensor indicis *without* opening its sheath and so expose the insertion of the extensor carpi radialis brevior. Incise the periosteum over the head of the third metacarpal and continue this incision upward through the joint capsule and the posterior annular ligament between the extensor indicis and the long extensor of the thumb. On the ulnar side of the wrist make an incision from a point 1¼ in. above the point

of the styloid process to a point close to the base of the fifth metacarpal. This incision penetrates to the bone along the radial side of the extensor carpi ulnaris. Through the two incisions separate the ligamentous investment from the bones and joints. With forceps seize the individual carpal bones and remove them by dissection. The pisiform bone and the unciform process need not be removed. With a saw remove the lower end of the radius and ulna and with them the triangular cartilage. Excise the carpal ends of the metacarpal bones with rongeur forceps. Excise any diseased tissue which may remain after extirpation of the bones. Unite by sutures the divided annular ligament. Close the wound after providing for drainage. It is sometimes wise, especially in tuberculous cases, to fill the cavity with a powder consisting of one part iodoform and three or four parts boracic acid. It is best to use the iodoform and boracic acid in coarse crystals. After dressings have been applied the dorsiflexed hand and forearm should be immobilized on a suitable splint. A moulded plaster-of-Paris palmar splint is convenient and inexpensive. As soon as possible after operation passive and active motions should be instituted. The wrist itself must be kept immobilized until there is good consolidation, except that after the wound has healed the splint ought to be removed daily and gentle passive motion practised.

Arthroplasty of Wrist.—In cases of bony anchylosis the joint may be mobilized and bone resected through a longitudinal incision on the radial side. By continuing this incision upward and undermining the skin it is easy to obtain a flap of fat and fascia which can be made to envelop the articular surface of the radius. Motion must be begun as soon as the wound has healed.

SECTION VII

THE LOWER EXTREMITY

By

W. J. FRICK, M.D., F.A.C.S.

TRAUMATA

Cuts, bruises and burns of the lower extremity differ little from the same lesions inflicted on other parts of the body. Their consideration belongs essentially to works on general rather than on regional surgery. One must remember, however, that the accident of location may demand an unusual amount of immobilization; *e.g.*, a transverse incised wound involving the plantar fascia ought to be kept at rest for a long time after the skin wound has healed, otherwise stretching of the scar in the fascia may lead to crippling deformity.

Injuries of Muscles.—Incised and punctured wounds of the muscles of the lower extremity are of special importance, principally because of their influence on locomotion and because of the difficulty and annoyance in securing immobilization sufficient to permit of thorough repair. In all wounds hemostasis must be secured and absolute cleanliness attained as nearly as possible. In punctures it may be necessary to enlarge the wound so as to secure hemostasis and asepsis. In small clean punctures the treatment recommended for a limited rupture of muscle may be adopted after the skin wound has healed. Simple contusions, while they cause temporary inconvenience and disability owing to pain and swelling, recover rapidly under almost any or no treatment. Massage hastens recovery. Occasionally a contused muscle forms a *locus minoris resistentiæ* where infection may settle and flourish. The symptoms are similar to those of foci of infection in any of the soft parts except that the disability is often out of proportion to the size of the lesion. If seen early, resolution may be favored by rest and hyperæmia. The application of hot fomentations or of Bier's obstructive bandage are the best means of securing hyperæmia.

Surround the affected limb, well above the lesion, with an elastic bandage. The bandage must be tight enough to cause a little swelling and a little increase of temperature in the limb, but *must never* cause coldness, pain or the slightest paræsthesia. Leave the bandage in position for about 18 or 20 hours out of the 24 and in the interval elevate the limb.

If the site of the lesion is such that the application of a bandage is inconvenient or impossible, the same effects may be obtained by applying a cupping glass (Klapp). The rim of the cup must surround the *whole* infected area and the suction should be gentle. There must be *no pain* and the skin bulging into the cup should turn red or bluish red, *never white.* The cup ought to be applied for six periods of five minutes each with an interval of three minutes between each application. Thus about 45 minutes per day are consumed in the treatment.

If resolution does not take place incision and drainage are in order, and here again hyperæmia is well calculated to hasten recovery.

When recovery ensues, scar tissue takes the place of any muscle which may have been destroyed and the contraction of this scar tissue may cause a greater or less amount of deformity and disability. During the healing process the limb should, therefore, be placed and kept in position to avoid contraction.

If the nerve supply of the muscle is injured either by the primary trauma or by inclusion in the resulting scar tissue, paresis or paralysis with atrophy may result.

Subcutaneous Rupture of a Muscle or of Its Sheath.—When a muscle is firmly contracted, any blow upon it may cause it to rupture. The rupture may be complete or only a varying number of the fibers may be torn. Similarly, when a muscle is tense, any extra strain put upon it may cause partial or complete rupture. For example, a man is playing tennis or hurriedly trying to get onto a street car; he suddenly feels as if he had been hit on his calf by a bullet or a whip. The pain is great. He may fall to the ground, and he certainly is unable to walk for a time. *What has happened?*

The gastrocnemius muscle being on tension, a slight twist of the foot or leg has caused some of its fibers to be subjected to a little extra strain and they have been ruptured. Various names have been given to this injury, *e.g.*, lawn tennis leg, *coup de fouet*, etc. The thigh and calf muscles are those most commonly affected. Rupture of the plantaris is often the diagnosis when the calf is the seat of the injury, but its rupture has never been demonstrated. Besides the sharp, sudden pain and loss of function, swelling and, later, ecchymosis appear. If the rupture is extensive, a gap may be palpated in the muscle.

Rupture of the adductors of the thigh is occasionally seen in riders and may also result from accidental over-abduction of the thighs. The rectus and the vasti may be ruptured in an effort to avoid falling after slipping.

When the rupture of a muscle is extensive or complete, the torn proximal fibers contract and form a swelling, and the distal fibers being deprived of their nerve supply, degenerate.

The muscular swelling may be hidden by a hematoma soon after the accident or may become evident only after some weeks. When the muscle is at rest the swelling is soft and movable from side to side, but not up and down. When the muscle is passively extended the tumor may lessen in volume, but when the muscle actively contracts the tumor moves toward the origin of the muscle and becomes at the same time larger and harder.

Sometimes, though rarely, the sheath of the muscle is torn and a hernia of the flaccid muscle takes place through the rent. The tumor disappears when the muscle is passively extended or actively contracted.

Treatment.—In cases of partial rupture like "tennis leg," by far the best treatment is to elevate the limb and stroke it upward with the hands so as to milk the swelling away, if any swelling is present. After a few minutes of elevation, the whole muscle should be supported by strips of adhesive plaster surrounding the limb. These strips must be applied snugly enough to support the muscle when it is in use but not tightly enough to press upon it when it is relaxed. The patient should be encouraged to use the limb freely *and not to limp.* It is usually necessary to replace the strapping daily for a time. Wharton Hood used the above treatment extensively even in rupture of the adductors. When a muscle is extensively injured and the above treatment appears or has proved to be unsuitable, then rest followed by massage and electrical stimulation of the muscle and later by cautious active motion gives good results. Regarding "rider's rupture" of the adductors König advises that riding be given up for at least six months, that the patient at first should lie with his legs together and that later massage and gradually increasing exercise be prescribed. Wharton Hood's treatment when it can be applied gives the best and promptest results. Rupture of the lower end of the quadriceps will be considered along with the injuries of tendons.

When a muscle is completely ruptured the only means of obtaining union is early suture. Mattress sutures of catgut are very suitable and the muscle must be kept at rest for several weeks. Late suture of ruptured muscle is not very satisfactory.

When a muscle sheath is torn and a hernia of the muscle causes disability, the only logical treatment is operative repair of the rent in the sheath. Before suturing the sheath it may be necessary to excise the protruding portion of muscle.

Injuries to Tendons.—*Incised and Punctured Wounds.*—Punctured wounds of tendons are of little importance (apart from the dangers of

infection) unless they divide the tendons. Incised wounds of the foot owe their particular importance to the damage they may inflict upon the tendons.

Treatment consists in thorough cleansing, hemostasis and accurate suture of the divided tendons. When such a tendon as the Achilles is divided it is easy to find and suture the stumps, but when some of the long extensors of the toes are cut, their proximal ends are retracted for a long distance into their sheaths and may be difficult to secure. Sometimes the retracted segment of tendon may be pushed down within reach by bandaging the leg firmly from the knee downward; at other times it may be necessary to split the tendon sheath upward. To avoid unnecessary cutting, pass an eyed probe from the wound up the tendon sheath, open the sheath through a small incision made on the end of the probe, secure the end of the tendon with a stitch, pull the stitch down through the sheath to the original wound by means of the probe and with the thread pull the tendon into position. Immediate suture of tendons gives excellent results if asepsis is secured.

When from any cause it is impossible to approximate segments of a divided tendon, one of the numerous plastic methods may be used to secure the *desired* union, or both the proximal and distal segments may be united to the side of a neighboring tendon having a similar function.

If infection supervenes, it must be treated by thorough drainage, etc. Repair after infection commonly leaves extensive crippling adhesions between the tendon and the surrounding structures.

The after-treatment consists in immobilization and the avoidance of tension on the line of suture. Usually gentle motion may be begun three to four weeks after the operation.

Rupture of Tendons.—When a tendon is rigid from muscular effort, any extra strain exerted on it, either directly by a blow or indirectly by a sudden movement or twist of the limb, may cause it to become ruptured. The rupture may be at any point of the tendon from its muscular origin to its bony insertion. A healthy tendon is rarely ruptured; usually the accident occurs to tendons which have been weakened by pre-existing disease.

The symptoms are usually very evident, viz., loss of function, pain, tenderness, swelling, ecchymosis. A gap may be palpable at the site of rupture. Sometimes a neighboring joint may be involved in the disturbance; *e.g.*, when the quadriceps femoris tendon is ruptured there is invariably effusion of blood into the knee.

Treatment.—When it is easy to keep the divided ends of a ruptured tendon in apposition or nearly in apposition it may be proper to treat it without operation. For example, in rupture of the tendo Achillis a good result may sometimes be obtained by immobilizing the foot in a position of extreme plantar flexion by means of a strap extending from the heel of a slipper to a band around the thigh immediately above the knee. Such non-operative treatment is rarely justified, as the results from properly executed operations are so much better. If there is much bruising and swelling it is wise to delay operation for a few days until the excess of exudates is absorbed. During the delay the skin may be prepared for operation, and if a joint (*e.g.*, the knee in rupture of the quadriceps) will be opened during the operation it may be subjected to preliminary treatment by aspiration and the injection of a 2 per cent. solution of formalin in glycerine (J. B. Murphy).

Operation consists in free exposure of the tendon, removal of blood clot and of irreparably injured tissues, approximation and suture of the tendon. In some cases it is wise to cover the line of suture with a flap (free or pedunculated) of fat and fascia to aid in the prevention of crippling adhesions.

In rupture of the quadriceps tendon the best exposure is obtained by a free transverse incision, after which union may be secured by passing a strong stitch transversely through the proximal segment of muscle or tendon and transversely through the distal stump or, if the stump is too short, through a hole drilled in the patella. When the tendon is torn from its bony insertion it may be united to its old site by means of a nail driven through it into the bone or by suturing it to the periosteum or to the bone itself.

The after-treatment consists in immobilization without tension on the sutures and, after a few weeks, in gentle mobilization and exercise.

Displacement or Dislocations of Tendons.—The tendons most commonly displaced are the peroneus longus and the tibialis posticus.

When the foot is inverted or pointed straight forward the tendon of the peroneus longus lies in the groove at the back of the external malleolus but if the foot is everted the tendon can leave its bony groove and is kept from slipping forward only by the external annular ligament (superior peroneal retinaculum). If a severe strain is put on the tendon during eversion of the foot the annular ligament may be torn and the tendon slip in front of the malleolus.

The tendon of the tibialis posticus, occupying a very similar position on the inner side of the foot, is liable to dislocation on forcible inversion

of the foot. The symptoms of displacement of the tendons of the peroneus longus and tibialis anticus are obvious and the tendons themselves are readily palpable. Sometimes when the internal annular ligament is lax, either congenitally or from an old trauma, the patient may, by voluntary effort, make the peroneus longus slip back and forth over the malleolus with an audible and painless snap. When the tendons are displaced, the retaining ligament being torn, it is easy to reduce the dislocation but treatment is required to prevent recurrence. In the case of the peroneus longus after reducing the dislocation, immobilize the slightly inverted foot at a right angle to the leg. Immobilization should be kept up for at least three weeks. Treatment for dislocation of the tibialis posticus is identical with the above except that the foot must be kept everted.

If non-operative treatment fails to prevent recurrence and the lesion is disabling, operation becomes obligatory. Often time will be saved by resorting to operation soon after the dislocation has occurred.

The annular ligament should be exposed by a 2-in. incision over the external or internal malleolus, according to whether the peroneus or tibialis is at fault, and expose the torn ligament. If sufficient ligament is present, repair the rupture with sutures. If the ligament is defective, reflect downward a flap of periosteum from the malleolus and suture its end to the remnants of the annular ligament or to the periosteum of the os calcis. Instead of the periosteal flap, one may use a slip of tendon obtained from the rectus femoris or the tendo Achillis. The ends of this implant may be sutured either to the remnants of the annular ligament or to the periosteum of the malleolus and os calcis or they may be nailed into gutters cut in these two bones (Lexer).

Sprains.—From a sudden strain or twist the tendons or tendon sheaths, especially about the ankle, are very often injured and traumatic thecitis results. There is an acute, non-infective inflammation of the tendon sheaths with effusion. Pain, tenderness, swelling and disability are present along the course of the affected tendons. If the effusion is not great or has been absorbed, crepitation is often palpable or even audible when the tendon moves in its sheath. There is great variety in the degree of injury; it may be so trivial as to be negligible or it may be very severe. The dangers consist in the occurrence of secondary infection (pyogenic, tuberculous, etc.), or in the formation of adhesions between the tendons and their sheaths. In severe cases the injury to the tendons is overshadowed by the more evident concomitant injury to the joint. One of the most common sequels of "sprained

ankle" (*i.e.*, laceration of articular ligaments and injury to the synovialis) is stiffness largely due to adhesion of the tendons following the traumatic thecitis. Following continued over-use of muscles and tendons, a chronic condition similar to the above is very common.

Treatment.—If the symptoms are very severe, the limb should be kept at rest and elevated. Alternating hot and cold applications are useful to stimulate the circulation. After the swelling has gone down it is commonly advised to give rest by immobilizing in plaster of Paris or some suitable splint. Wharton Hood long ago recommended a more active treatment which gives excellent and rapid results. If the patient is seen very soon after the accident and before swelling has occurred "the only treatment necessary is the application of strapping, by which swelling will be prevented and encouragement given to move and use the limb as if nothing had befallen it." If some slight swelling has occurred, the same treatment is proper but the strapping must be re-applied in about 24 hours having become loose owing to diminution of the swelling brought about by the combined effects of muscular activity and of external support.

Hood advises that the adhesive strapping be applied as follows: "The strips for the ankle should be 18 in. in length, and about 2 in. wide. The leg should rest on a horizontal bar, with the ankle-joint in a position of complete flexion. The middle of the first strip should be applied to the sole of the foot, in front of the heel, and the two ends should be carried upward over the tarsus to cross in front and terminate over the ankle. The middle of the second strip should be placed at the back of the ankle-joint, and the ends brought down over the foot to cross in front, thus partially covering the first strip and making a figure-of-eight. The third strip should reinforce the second and be placed a little below it, the ends crossing over the instep, a notch being first cut out of the lower margin of the strip at its center, to remove any impediment to upward movement of the heel. A fourth strip should be placed above and overlapping the second; and then all four should be retained in accurate position by the application outside them of one or two narrow strips of adhesive plaster, used merely as a retaining agent. The original strips should not be drawn tight, but applied smoothly to the actual contour of the skin, great care being taken that no one of them is tighter or slacker than the rest. The general result is to enclose the joint in a case which offers no impediment to its mobility, but which places an insuperable obstacle in the way of swelling. The patient walks about, and the action of his muscles upon the veins not only soon

squeezes away any small amount of obstruction to the circulation, or any effusion which may have begun to find its way among tissues, but the movements of the articular surfaces upon one another exert the same effect upon any effusion into the joint cavity, which is too deeply situated and too protected to be influenced by rubbing. For this reason, whenever the stage is reached at which rubbing is desirable, the rubber should be careful to flex and extend the joint in the course of his manipulations.

"Unfortunately, the opportunity for treatment of this kind is seldom afforded, and the surgeon usually does not see the patient until some time has elapsed, and until swelling of a pronounced character has already occurred.

"In such circumstances, the first indication is to reduce the swelling by careful rubbing, conducted in the manner already described, that is to say by commencing near the proximal boundary of the swelling, and rubbing always in the direction toward the trunk, commencing the impulse of the hand farther and farther back as the natural mechanical effect is produced, and the retarded blood passes onward upon its natural course. Three or even four days, with two rubbings each day, may be so employed; and during the whole of this time the patient may remain in bed, and may abstain from voluntary effort."

As soon as the swelling goes down, treat by strapping in the same manner as recommended when the patient is seen immediately after the accident. Massage should be continued daily through the strapping, and the latter must be renewed as often as it is rendered loose by the continued subsidence of swelling.

This treatment of Wharton Hood is the best insurance against subsequent crippling adhesions and is applicable to sprains of almost any kind. The best treatment of crippling adhesions of the tendons is *not* to *tease and irritate* them by partial motion, but frankly to rupture them under an anæsthetic and then treat as a sprain. If *one* immobilizes after rupturing the adhesions, it is logical to expect them to re-form promptly.

Injuries to Bursæ.—Bursæ are *of course* exposed to such injuries as may affect any soft structures similarly placed. The fact that they are situated over bony prominences or between tendons, as protecting cushions, renders them peculiarly subject to trauma, but as their function is protective their resistance to injury from blows or strain is considerable. To infection they are not very resistant and this must be taken into account when punctures or other wounds of bursæ are being treated. A severe blow on a bursa often leads to hemor-

rhage and effusion into it and a simple or non-infective bursitis results. This is particularly common in the prepatellar bursa. Under appropriate treatment recovery ensues in a few days. Treatment consists in coaxing away as much of the effused fluid as possible by means of gentle rubbing with the fingers or thumbs and then applying elastic pressure by covering the part with a liberal supply of cotton, secured by a snug bandage. Elevation and rest for a few days complete the cure. As good or better results may be obtained by strapping the injured part with strips of adhesive plaster after preliminary massage. The strapping must *not* be applied tightly; in fact when the limb is at rest no pressure ought to be felt but when in motion there ought to be a feeling of support. If the effusion fails to be absorbed in a few days, aspiration may be practised but this is very rarely required.

The lesions produced by repeated slight traumata are considered elsewhere.

Injuries to the blood-vessels of the lower extremity do not differ sufficiently from similar injuries in other portions of the body to require special discussion.

Injuries to the Nerves of the Lower Extremity.—Because of their well-protected situation the nerves of the lower extremity are not often injured except in very extensive traumata. The external popliteal nerve is more frequently injured than is any other because as it winds around the upper end of the fibula it is superficial and lies against unyielding bone. It may be bruised, lacerated or ruptured during forcible flexion of the knee in ankylosis or by the fragments of the bone in fractures of the fibula. It may be divided during the operation of tenotomy of the biceps. It may be injuriously pressed upon by improperly applied splints, or it may be injured by any wound whether incised, punctured or gunshot.

As the external popliteal nerve supplies the peronei muscles and the extensor muscles of the foot as well as the integument of the front of the leg and dorsum of the foot, the symptoms of its division or serious injury are very evident. The foot assumes the position of talipes equinovarus because of paralysis of the peronei and extensors of the toes. Voluntary flexion and eversion of the foot and extension of the toes are impossible.

"Deep sensibility is unaffected, and the patient may be able to appreciate and to localize the slightest pressure causing deformation of the skin. Just before the nerve passes around the neck of the fibula, it gives off a large lateral cutaneous branch; it is most often

injured below this point. The loss of sensibility which results from this lesion is absolute only on the dorsum of the foot and lower third of the leg. The anterior boundary of the area insensitive to light touch is as well defined as after division of the whole nerve, but its posterior border and that on the outer margin of the foot merge gradually into parts of normal sensibility. Sensibility to prick is abolished over a triangular area on the dorsum of the foot, but is defective over an area almost as large as that anæsthetic to cotton wool. After division of the nerve in this situation, similar phenomena may be observed to those seen after division of the ulnar below its dorsal branch.

"Division above the lateral cutaneous branch produces an area of loss of sensibility on the outer side of the leg and dorsum of the foot with well-defined boundaries, except at its external border in the lower third of the leg and outer surface of the foot, which territory it supplies in common with the external saphenous nerve. The boundaries of the loss of light touch and of prick are almost coterminous.

"It is essential to remember the difference in the loss of sensibility that results from division above and below this branch. The small loss of sensibility that results from division in the latter situation is not sufficiently well recognized, and has lately led to the report of two cases of "immediate sensory recovery" after suture. Delbet, in a discussion on the results which follow division of the external popliteal nerve, pointed out the slight loss which arises when the nerve is divided in this situation" ("Injuries of Nerves," Sherren, p. 298).

In diagnosing injury to the external popliteal nerve one must remember that the fibers of this nerve pass up by themselves in the great sciatic nerve to the sacral plexus, and that in partial division of the great sciatic they are, for some reason, more prone to injury than are the fibers belonging to the internal popliteal nerve.

Sherren writes, "Injury to the fifth lumbar root in the spinal canal, or to the fifth anterior primary division as it crosses the brim of the pelvis, will give rise to symptoms resembling those of division of the external popliteal.

"The seat of injury must be settled, whether with the great sciatic or below the point at which its lateral branch is given off. A consideration of the nature of the accident will lead to the correct diagnosis in most cases, but the symptoms will also point out the correct seat. Injury to the fifth anterior root or anterior primary division usually leaves the tibialis anticus muscle unaffected; in an injury to the lumbo-sacral cord or external popliteal nerve this muscle is paralyzed. An injury

of the fifth anterior root leaves sensibility unaffected; if the posterior root is affected in addition, the loss of light touch is less extensive than the loss of sensibility to prick. This was beautifully shown in a patient with involvement of these roots in a cauda equina injury, on whom I divided the external popliteal nerve for purposes of anastomosis. Before his operation the loss of sensibility was of the root type; after, it showed the typical features of the loss of sensibility resulting from division of a peripheral nerve."

Injuries to the great sciatic nerve are rare except in war. Partial solution of continuity is more common than complete. As remarked before, the fibers destined for the peroneal nerve are more often and severely injured than are those for the internal popliteal. Makins in gunshot wounds of the sciatic nerve found that in 90 per cent. the internal popliteal nerve elements escaped while the external popliteal elements were evidently injured. The muscles of the leg are all paralyzed after section of the sciatic nerve; if the section is in the upper part of the thigh the ham-string muscles are also paralyzed, but as the gracilis escapes this may lead to error in diagnosis as it, especially if hypertrophied, can flex the knee. Besides the motor symptoms there is loss of sensation below the knee except along the course of the internal saphenous nerve on the inner side of the leg. Sherren states that sensibility to deep touch is only lost over a comparatively small area of the foot.

Treatment.—Bruises and such injuries of the nerves usually recover spontaneously but during the course of their recovery the muscles temporarily paralyzed may become so stretched that they are unable to do their work. If such a muscle is put on the stretch, *e.g.*, by passively flexing the foot, and the patient can now, even to the most minute degree, extend the foot, then recovery is certain to take place if a brace is so applied that the affected structures are completely and continuously relaxed for weeks or months. The brace should be such that access to the affected muscles is easy and massage and muscle stimulation can be carried out. The posture of relaxation (dorsal flexion of the foot in peroneal paralysis) must be kept up continuously until the patient is able voluntarily to make further dorsal flexion. When he can do this a cure is assured in time but too much tension must not be put upon the newly contracted tissues.

Partial or complete division of the external popliteal nerve should be immediately repaired by suture. In case of fracture of the fibula with evidences of nerve injury the fracture should be submitted to open

operation and the nerve relieved from all possibility of pressure. After complete division of the sciatic nerve, no matter how carefully and successfully it is sutured, months must elapse before recovery. In from three to six months sensibility to deep touch may be expected. No delicate appreciation of touch may be expected under 18 months. Some motor power may return within a year but complete muscular recovery is not likely under two years or more. The dorsal flexors of the foot are the last to recover.

"In dealing with instances of incomplete interruption of continuity in the great sciatic nerve we must be prepared to treat complete division of its external popliteal portion. This must be dealt with as complete division elsewhere; if, after an injury to the great sciatic, the reaction of degeneration develops in the external popliteal group of muscles, even although those supplied by the internal popliteal are unaffected, the nerve should be exposed, the damaged portion of the external popliteal found by tracing it up from below, separated from the internal, excised and reunited. During the early stages of recovery the weight of the body must not be allowed to rest on the paralyzed foot; perforating ulcers are liable to develop and may necessitate amputation. The foot and leg should be fitted with a light, well-padded poroplastic splint to prevent deformity and the patient allowed to get about with the limb flexed.

"No time after the injury is too long to attempt operation; amputation should not be advised as a routine measure even in old cases. The tendency to the formation of perforating ulcers ceases with the restoration of protopathic sensibility, and this is to be expected in every case in which the wound heals without suppuration. At the end of the first stage of recovery the whole of the sole of the foot is in that condition of sensibility found in the intermediate zone. All stimuli have an unpleasant tingling radiating character, and for this reason the limb may be useless, the patient being unable to bear any weight on it. This will, in most cases, be only a stage, and as epicritic sensibility is restored the tenderness gradually diminishes. If sensory recovery fails at this stage, amputation may be necessary on account of the tenderness and pain; if this is done care should be taken to obtain the flap from the inner side of the leg, from skin supplied with normal sensibility by the internal saphenous.

"If complete motor recovery fails a suitable surgical boot should be worn, or arthrodesis of the ankle carried out" ("Injuries of Nerves," Sherren, pp. 295, 296).

SECTION VIII

FRACTURES OF THE LOWER EXTREMITY

By

SIR W. ARBUTHNOT LANE, BART.

It would be well to consider in the first instance how far it is necessary to restore broken bones to their original form and whether the bones of the lower extremity call for any treatment other than that required in the case of the upper extremity. While investigating in the dissecting room the remarkable evolutionary changes which the skeleton undergoes in quite a short period in consequence of the habitual assumption of attitudes of activity and of rest, I examined many subjects who had sustained fractures and was able to observe the several changes in the articulations which took place because of the alterations in the mode of transmission of force through them resulting from an alteration in the axes of the fragments.

The changes which the skeleton undergoes in consequence of a specialization of functions afford most striking evidence of evolution since the alteration in the forms of the bones and joints are perfectly characteristic and the skeleton which is evolved in this manner differs altogether from the normal in some instances much more than the latter does from that of the higher ape. I would refer the reader to the following papers[1] which will supply all the evidence he requires on this subject. The evolutionary changes which develop in the joints in laborers, etc., are of great importance to us in the consideration of the treatment of fractures. At the time I described them they were regarded as evidence of the presence of a disease commonly called "rheumatoid arthritis" or "osteoarthritis."

They consisted of destructive changes in the cartilages, both articular and interarticular, in lipping of the edges of the bone in order to render the articular surfaces more extensive and the joint more

[1] Causation and Pathology of the so-called disease Rheumatoid Arthritis or Rheumatic Gout and of Senile Changes, Transactions Pathological Society, 1885–1886. Some changes in the form of the acetabular cavities, spinal column and joints of the hand illustrated by the anatomy of the charwoman, Guy's Hosp. Report, 1886. A remarkable example of the manner in which pressure changes may reveal the labor history of the individual, Journal of Anatomy and Physiology, 1886. The Anatomy and Physiology of the Shoemaker, Journ. Anat. and Phys., 1887.

secure till finally ankylosis of the bones ensues. On the other hand, a new joint might be developed where previously there was none whatever. I found, when there was axial displacement of the fragments in a broken bone, that precisely the same changes took place in joints whose mechanics were affected by the alteration in the axes of the fragments; that these changes were greater in the lower than in the upper extremity because of the transmission of the superjacent weight of the trunk through the former; that these changes were still further exaggerated in the lower limb if, besides the weight of the trunk, they transmitted the additional weight of a load borne upon the trunk; and that these changes were more marked and more progressive as age advanced. In young life while the growing lines were still active there was more change in the form of the bone and less in the articular sur-

FIG. 295.

faces. This ensued in accordance with a law I formulated, namely, that "the rates of bone formation in the several portions of a growing line vary inversely as the pressure transmitted through them." Again, as "the skeleton represents the crystallization of the lines of force" an alteration in the axes of the fragments in young life is met by the formation of an entirely new shaft which extends along the whole length of the bone, any portion of the old shaft that is not included within the area of the lines of force disappearing. This adaptability of the skeleton whose outline is altered by injury is more marked the younger the subject. It may be produced quite late in life by gorging the limb with blood.

The following radiograms illustrate the change that takes place in young life very well:

FIG. 296.

FIG. 297.

Figure 295 represents a fracture about the lower epiphysis of the humerus with backward displacement of the fragment. Six weeks had elapsed since the injury. A dark zone extending vertically upward from the epiphysis behind the shaft indicates the commencement of the crystallization of the lines of force.

Figure 296 represents the condition three months after the injury. The perceptible layer of callus extends a greater distance up the

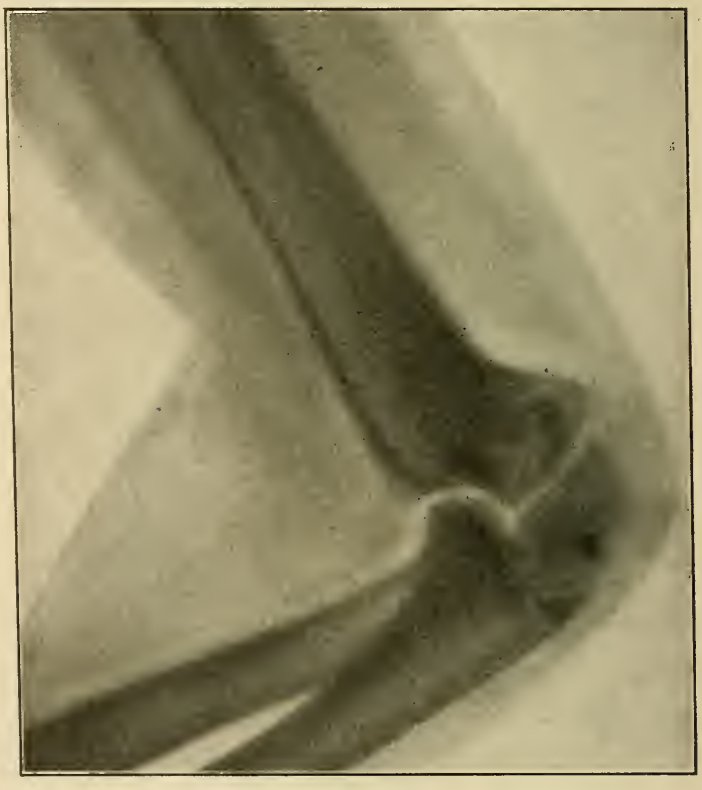

Fig. 298.

back of the shaft. The shadow formed by it is much darker, equalling that produced by the original shaft.

Figure 297 shows the part six months after the injury. The range of flexion has increased partly by the absorption of the end of the shaft and partly by that of the coronoid process. The layer of new material, which is extending much farther up the shaft, is denser, while the shaft is relatively lighter.

Figure 298, taken 16 months after the fracture, shows that flexion

is still further increased by progressive absorption, while the changes already noted in the original shaft and in the new formation are much more marked.

Figure 299, taken three years after the injury, shows that a new shaft connecting the extremities of the bones has been laid down, while the original one has almost completely disappeared. The range of flexion is still further increased.

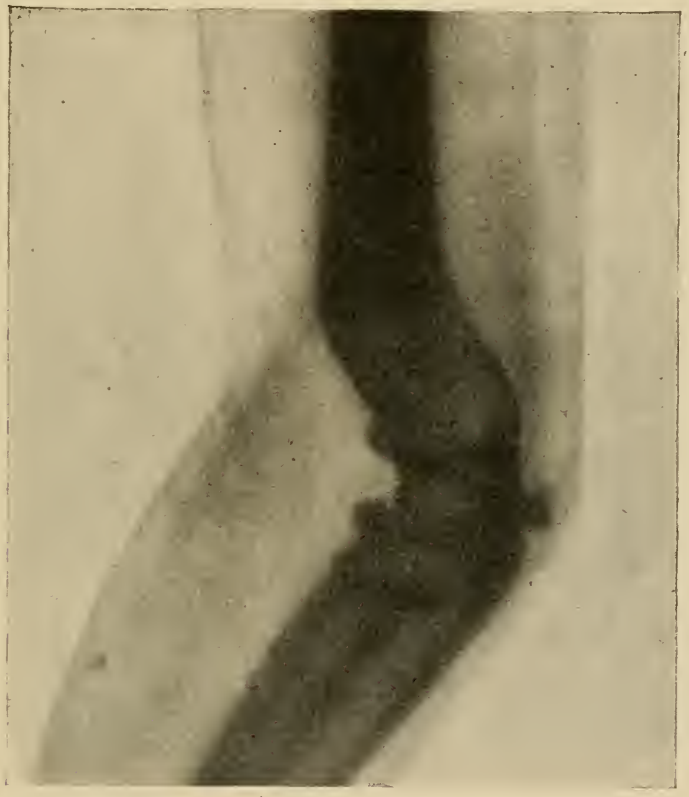

Fig. 299.

On general principles we see that the necessity or the importance of effecting a complete restoration of the form of the fractured bone varies directly with the age of the individual. At the same time I am strongly opposed to the view held by many surgeons that the necessity of restoring fractured bones to their normal form is not as important in young life as at any other period. This fallacy has been completely exploded by Mr. Sampson in his paper on fractures in the Lancet for which I would refer you to the Lancet, August 17, 1912.

The following shows the changes which can be developed artificially late in life. The case was that of a well-built man, aged 56 years. He had sustained a severe comminuted fracture of the left tibia and fibula in December, 1910. The fractures were produced by direct injury, and there was much damage to the soft parts. The tibia and fibula were each broken in two places, so that there were six separate large

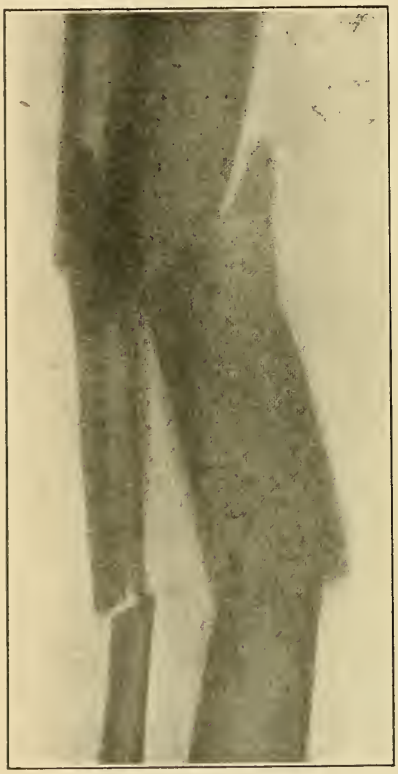

FIG. 300.—Case 2. Skiagram taken Feb. 5, 1911, showing condition of tibia and fibula before operation.

FIG. 301.—Case 2. Skiagram taken April 26, 1911, showing reposition of parts two months after operation. The formation of new bone is indicated but faintly.

fragments of bone. Besides this there were several smaller pieces. The fragments had been so displaced that their several axes differed very greatly in direction and there was much overlapping, so that at none of the four fractures was there anything approaching apposition of the broken parts. The operation was performed on February 19, 1911. The imperfect junctions between the tibial fragments were

cleared, and their opposing surfaces were sawn so as to enable us to restore the bone to its original form; the cut surfaces were placed and secured in accurate apposition. To retain the fragments in position it was necessary to use six steel plates of varying sizes and strengths. No attempt was made to unite the fibular fragments. This would have increased the risks of the operation very much, while it would

FIG. 302.—Case 2. Skiagram taken Sept. 11, 1911, showing later results of operation and the further development of bone along the line of pressure.

FIG. 303.—Three years after operation.

have afforded no sufficient compensation, as the fibular fragments would unite as soon as the tibia was functionally secure.

The patient made an uninterrupted recovery. His ambulatory splint was fitted by Mr. Hoefftcke on May 8, 1911, and the patient soon learned to use it.

Figure 300 represents the fragments on Feb. 5, 1911, about three months after the receipt of the injury when the leg was absolutely use-

less, while Figs. 301 and 302 show the condition of the bone at intervals of about two and seven months after the operation. The amount of new bone that continued to form even after the fragments of the tibia had become firmly united and while the patient was leading a normal life. This is shown very well in Fig. 303 which was taken in June, 1914, more than three years after the operation.

Fig. 304.—Skiagram taken July 4, 1910, showing condition of femur before operation.

Fig. 305.—Skiagram taken Aug. 22, 1910, showing early results of operation.

Again, Fig. 304 represents a badly united comminuted fracture of the left femur with complete incapacity to walk five months after the receipt of the injury. Figure 305 shows the condition a month after the operation, a considerable interval existing between the fragments which are in contact only over a small area. The patient was got up in a Hoefftcke's splint. After an interval of nine months the callous formation is shown in Fig. 306. The function of the leg was then

normal. This condition could not have been obtained without great engorgement.

I will refer more fully later to the mode in which this law can be applied with great advantage to the treatment of such fractures as could not be dealt with effectually in any other way. From a careful consideration of their general principles it is obvious that it is of great advantage to the individual that when the fragments of broken bones

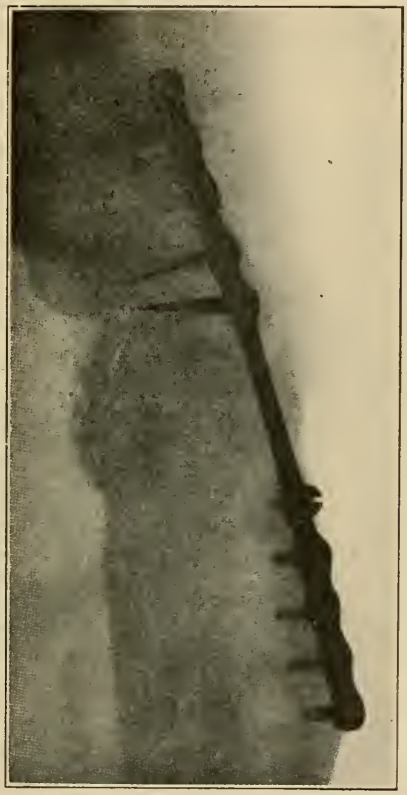

FIG. 306.—Skiagram taken May 25, 1911, showing firm bony union.

are no longer in apposition they should be restored to their normal form, that the more the mechanics of the skeleton are impaired by the displacement the more urgently is reconstruction required and that as in the lower extremity, joint changes consequent on the displacement are much greater than in the case of the upper limb, the necessity of effecting restoration of form and function is still greater.

Now I propose to consider the mechanics of a fracture of a long bone. It may be broken in two ways, one is by indirect violence as in a fall

on the foot when the long bone or bones are broken spirally and the fragments are forced upward and downward on one another, the spikes of bone perforating the soft parts. Because of their chisel shape, when the fragments overlap they tend to separate, the degree of separation varying directly with the amount of overlapping. In this variety of fracture the soft parts about the break are damaged only by the plunging of the sharp spiked ends of the fragments into them (see Fig. 307).

The bone may be broken by a blow applied directly to the seat of fracture. This fracture is commonly spoken of as "direct" as opposed to the other which is called "indirect."

Fig. 307.

The point of importance in the direct fracture is that the soft parts about the fracture are damaged not only by the forcible displacement of the large blunt ends of the fragments from one another but are also lacerated and bruised by the force which broke the bone. Consequently in a fracture produced by direct injury there is much more laceration of the soft parts, more hemorrhage following immediately on the fracture and a greater degree of subsequent inflammation than in the case of a fracture produced by force applied indirectly or, in other words, as the result of excessive torsion.

When I first interested myself in the treatment of these injuries I found that the knowledge of the surgeon of the mechanics of fractures

and the results of his treatment were of the vaguest and most erroneous description. He was of opinion that the replacement of fragments was opposed by a spasmodic contraction of the muscles. Various views were held as to the time of onset of the spasm, its duration and the manner in which it should be overcome. Instead of quoting the fossilized reproductions in surgical textbooks of that time, I prefer to extract from the teachings of surgeons of the highest reputation in England their teaching on this subject.

The following appeared in a lecture on the treatment of fractures published in the Clinical Journal, May 15, 1895, in response to a preceding article of mine in the same Journal:

"In the first place, I long ago learned from the practice of a distinguished surgical baronet the folly of attempting at once to fix a bad fracture in accurate position. The setting, as the public persist in calling it, should be postponed until the inflammatory effusion has to some extent subsided and the blood is beginning to be absorbed. The spasmodic contraction of muscles, so marked when they are at first irritated and partially lacerated, subsides markedly in a week or 10 days.

"Mr. Lane's second point, that the shortening is due to hemorrhagic effusion and inflammation rather than to muscular contraction, seems to me hardly proved. Indeed, I cannot but hold that the contrary is the case, seeing the remarkable manner in which great shortening and deformity can be reduced under deep ether anæsthesia. This I have witnessed so often that I cannot be mistaken. Should the parts be left displaced for weeks or months until structural softening of the muscles occurs from the organization of inflammatory material, I could then understand the immense resistance encountered by Mr. Lane; but this with ordinary careful treatment should not occur. Though muscular contraction may have been over-rated in producing the deformity in fractures, I feel sure that the consideration and treatment of it in practice is of the greatest importance." That they were not unmindful of the necessity for the accurate restoration of the form of the broken bone is shown by the following teaching of another eminent surgeon taken from the Lancet, January 4, 1896:

"I would remind you how important it is, in fractures of the leg particularly, that the fracture should be set thoroughly and accurately. Of course I know well that there are many difficulties. Immediately after the accident all the muscles of the limb are more or less in a state of spasm, and tend, therefore, to pull the bones into abnormal positions;

but that state of spasm passes off in the course of a few hours, and you can generally manage, with care and patience, to put the limb into a proper position; and unless that is done, and done accurately, the surgeon has not treated the case properly.

"In the average case, however, you can set the fracture in the way I have described without much trouble, and in compound fractures you can manage it with greater ease; and, moreover, you can insert your finger and feel if the two ends are in accurate apposition.

"But I cannot perceive how anybody can believe that it is justifiable to convert a simple into a compound fracture; and of this I am quite certain, that the majority of surgeons for the present will remain content with the usual methods of treatment."

These two surgeons appear to have very different views about the manner in which the same cause acts. They both assert that spasmodic muscular contraction is the important obstacle to reconstitution of the fractured bone. How does this knowledge guide them in their treatment? The one considers that "this spasmodic muscular contraction passes off in a few hours," and presumably he postpones placing the fragments in accurate apposition till such time has elapsed, and then does it, as he supposes, effectually and at once.

The other states that "the spasmodic contraction of muscles subsides markedly in a week or ten days," when he proceeds "to get the fracture into good position."

I have extracted the following from an address by another leading surgeon on the "Treatment of Fractures," published in the "Lancet," June 12, 1897:

"Having arrived at a full and correct diagnosis, the next point to attend to is to reduce the fragments at once, at the earliest possible moment, remembering that lapse of time always increases the difficulties in doing this, never lessens them, and even makes them insuperable. This reduction of the fragments must be complete or perfect at once; we must not rest in any halfway house, content with improvement today in the hope of still further correction tomorrow."

Also: "The causes of this displacement (of the fragments) are either the fracturing force, the action of gravity, or the pull of muscles."

These three factors would appear to constitute the "difficulties" previously referred to, but how they are exaggerated by delay is not very clearly stated. Contrast this with "the folly of attempting at once to fix a bad fracture in accurate position," as stated in the first lecture quoted from the "Clinical Journal."

I call your attention to these statements to show that while surgeons held very similar views as to the mechanical factors that oppose the reduction and retention of the fragments of a broken bone in accurate apposition, yet they appeared to obtain equally good, in fact, if one can interpret their language according to its usually accepted signification, perfect results by methods which to the ordinary mind are mechanically absolutely antagonistic both in practice and in principle.

I expected to experience opposition in two directions. I believed that many surgeons would say that the statements I had made as to the bad results obtained by the treatment of fractures by manipulation and splinting were very much exaggerated, and that they were able to restore the broken bone to its original form, and that the mechanics of their patients and their wage-earning capacity were but slightly, if at all, affected in consequence of the accident; also that they would substantiate this by the production of the subsequent history of cases that had been under their care, and which I presumed could be obtained with little difficulty. In order to meet this objection I made very extensive inquiries of medical men practising largely among the laboring classes, of instrument-makers, of large employers of many kinds of labor, of the laborers themselves, and of those who have to do with assisting the poor both inside and outside our infirmaries. In consequence of them I was satisfied that the teachings contained in the textbooks as to the possibility of restoring the form of broken bones and the satisfactory results of their treatment were absolutely false.

The discovery and application of the X-rays some years later verified my opinion as to the impossibility of putting displaced fragments of broken bones in accurate apposition without operative interference.

The factor which opposes the replacement of the fragments of a long bone in accurate apposition is the shortening of all the soft parts about the bone which form ties in the length of the limb. The muscles and soft parts which have been lacerated, contused, filled with extravasated blood and which later become firm and brawny from inflammation are practically inextensile by force exerted on any single occasion. By that I mean that any traction which can be exerted on a single occasion on the limb is insufficient to bring the fractured ends of the bone into apposition and to retain them in position.

Before resorting to operative measures I made many attempts to bring the fragments into apposition by the exercise of very great strain

[1] "A Method of Treating Simple Oblique Fractures of the Tibia and Fibula More Efficient than Those in Common Use," read April 13, 1894, and published in the "Clinical Society's Transactions," Vol. XXVII.

till all the inflammation had subsided and till the soft parts had become normal. We were not able at that time to avail ourselves of the use of radiography since it had not then been discovered. I found this method of extension so uncertain that I determined to cut down on the fragments to replace and secure them in accurate apposition. This was in 1893. Since that time I have operated on a very large number of patients at all ages from a few hours after birth up to extreme old age with uniform success. This was only done when it was not possible to restore the bone to its original form and to retain the fragments in apposition by some mechanical means.

At the present day the treatment which I originally employed namely forcible and continual traction is much used on the Continent. It is rendered more effectual by the use of X-rays. Some surgeons exert traction more efficiently by transfixing the lower fragment with a steel bar. This seems to me to be a very painful, tedious, inefficient and unscientific means of obtaining in an uncertain manner a doubtful result. This, like many other treatments of fractures, rather suggests the fable of the mountain in labor which brought forth a mouse. I do not for a moment consider that a very fair result may not be arrived at in certain cases of fractures of the long bones of the leg by extension efficiently carried out and controlled by X-rays.

My objection to those methods is that in the majority of cases they are very uncertain, they require very great care over a considerable period of time and they demand much more skill and familiarity with the use of apparatus than is possessed by most surgeons.

Operative treatment or, as it is called, the open method of treatment of fractures requires but little skill on the part of the operator and entails no risk whatever if the surgeon takes the aseptic precaution which the burial of a large quantity of metal in the tissues necessarily demands. It offers to the patient the following advantages:

(*a*) He is at once relieved from the pain of any movement of the fragments upon one another.

(*b*) He is freed from the tension and discomfort due to the extensive extravasation of blood between and into the tissues.

(*c*) The duration of the period during which he is incapacitated from work is shortened, since union is practically by first intention, and consequently very rapid and perfect.

(*d*) Lastly, and by far the most important, his skeletal mechanics

are left in the condition in which they were before he sustained the injury.

Much trouble and disappointment have arisen from the fact that the operator has not made himself familiar with the mode by which the fragments can be brought into apposition, that his technique has been faulty and that he had not the instruments requisite for such an operative procedure.

On the last occasion in which the British Medical Association met in London I opened the discussion on the "Operative Treatment of Simple Fractures." It was decided to appoint a Committee to investigate the results of the various forms of treatment of simple fractures. The Committee was a strong one embracing many of the leading surgeons in Great Britain. The following are the conclusions of that committee. They were embodied in a report which was issued separately with the British Medical Journal, November 30, 1912.

The following are the main conclusions deduced from an analysis and full consideration by the Committee of the material collected by the Committee's Investigators:

I. The statistics relative to the non-operative treatment of fractures of the shafts of the long bones in children (under the age of 15 years), with the exception of fractures of both bones of the forearm, show as a rule a high percentage of good results. These are unlikely to be improved upon materially by any other method of treatment. Operative results in children, expressed in percentages, are approximately the same as the non-operative. The relative figures are:

NON-OPERATIVE CASES (cases, 1017) 90.5 per cent. good functional results.

OPERATIVE CASES (cases, 64) 93.6 per cent. good functional results.

II. It is possible either by non-operative or by operative treatment to obtain a high percentage of good results in children.

III. In comparison with the non-operative results in children, the aggregate results of non-operative treatment in those past childhood (*i.e.*, over the age of 15 years) are not satisfactory.

IV. From the analysis of the age groups it is clear that there is a progressive depreciation of the functional result of non-operative treatment as age advances, that is to say, the older the patient the worse the result.

V. In cases by immediate operation, the deleterious influence of age upon the functional result is less marked.

VI. In nearly all age groups, operative cases show a higher percentage of good results than non-operative cases.

VII. Although the functional result may be good with an indifferent anatomical result, the most certain way to obtain a good functional result is to secure a good anatomical result.

VIII. No method, whether non-operative or operative, which does not definitely promise a good anatomical result, should be accepted as the method of choice. For this reason mobilization and massage by themselves have not been found to secure a high percentage of good

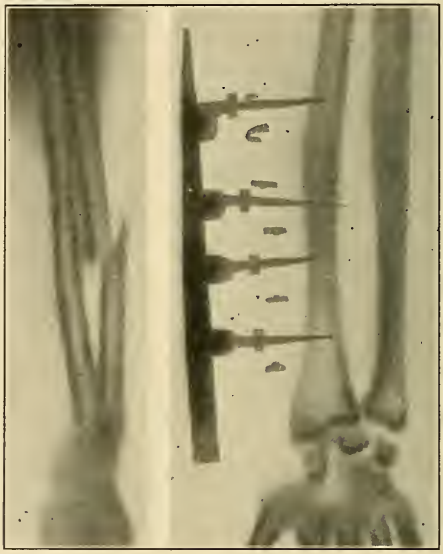

Fig. 308.—Fixateur. (*Lambotte.*)

results. They are, however, valuable supplementary methods of treatment.

Similarly, of operative methods, those which secure reposition and absolute fixation of the fragments yield better results than methods which fall short of this; imperfect fixation of the fragments by wire or other suture has been found to be an unsatisfactory procedure in the treatment of fractures of the long bones, with the exception of the olecranon process of the ulna.

IX. Operative treatment should not be regarded as a method to be employed in consequence of the failure of non-operative measures, as the results of secondary operations (Classes B and C) compare very unfavorably with those of immediate operations (Class A).

In order to secure the most satisfactory results from operative treatment, it should be resorted to as soon after the accident as practicable.

X. It is necessary to insist that the operative treatment of fractures requires special skilll and experience, and such facilities and surroundings as will ensure asepsis. It is, therefore, not a method to be undertaken except by those who have constant practice and experience in such surgical procedures.

XI. A considerable proportion of the failures of operative treatment are due to infection of the wound, a possibility which may occur even with the best technique.

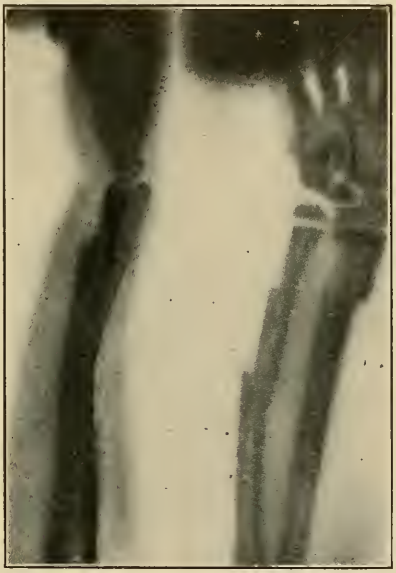

FIG. 309.—Plates. (*Lambotte.*)

XII. The mortality directly due to the operative treatment of simple fractures of the long bones has been found to be so small that it cannot be urged as a sufficient reason against operative treatment.

XIII. For surgeons and practitioners who are unable to avail themselves of the operative method, the non-operative procedures are likely to remain for some time yet the more safe and serviceable.

Those conclusions were based on an examination of the results of various forms of treatment adopted in Europe. A very large number of cases were examined and these results will be found carefully classified in that report. Included in that report are full descriptions of the methods adopted by such well-known surgeons as Mons. A. Lambotte of

Antwerp, Mons. J. Lucas-Championniere of Paris, Dr. F. Steinmann of Bern, Geheimrat Prof. Dr. Bardenheur and Stabsarzt Dr. Gräfsner of Cologne, and Oberarzt Dr. Shrecker of Cologne.

Lambotte describes his method of holding the fragments in position by what he calls a fixateur. For the lower limb he employs a traction apparatus, based on the principle of a lever, which allows him to obtain traction of 150 kg. with the hand. The fixateur is a steel bar which lies outside the incision and which retains the fragments in position by means of drills threaded as screws which perforate the

Fig. 310.—Plates. (*Lambotte.*)

fragments and are fixed securely to the steel bar. These are removed when union has taken place. Besides this form of treatment he employs buried plates and screws which are modifications of those devised and employed by myself. Fig. 308 illustrates the mode of employment of the fixateur, while Figs. 309 and 310 show the manner in which he uses bone plates.

The late Mons. Lucas-Championniere dealt with the massage treatment of fractures.

In reference to indiscriminate massage of fractures I would call attention here to the disastrous conditions which result from its employment, as for instance in fractures about the elbow-joint. I have seen a very large number of elbow-joints permanently ankylosed by the

use of massage when the coracoid process of the ulna or the head of the radius has been broken.

Figure 311 represents a fracture of the head of the radius which had been treated by massage. This radiogram was taken three days after the receipt of the injury. Fig. 312 was taken twenty-seven days after the receipt of the injury. It shows exceedingly well the method by means of which nature locks the joint and renders it permanently useless. The mass of bone extends upward from the fragment in the direction of the shaft to which it ultimately becomes attached.

Fig. 311.

Figure 313 illustrates this process in a later stage when the joint has become completely ankylosed.

Steinmann described and illustrated the "nail extension" treatment of fractures, which is based upon the same principles as is that of continuous plastic extension. The following illustrations (Figs. 314, 315, 316, 317 and 318 demonstrate the method of its application more fully than any verbal description.

Bardenheur and Gräfaner describe their method of treatment by extension bandages, which is so familiar to us all that I do no more than

Fig. 312.

Fig. 313.

refer to it here, except to say that the account of it contained in the Report of the Fractures Committee is very clear and instructive.

Schrecker describes an elaboration of Bardenheur's technique which will well repay its perusal.

Should it appear desirable or possible to attempt to restore the broken bone of the leg by means other than operative, I prefer to employ Hoefftcke's splint, the fragments having been previously restored as near as possible to their normal relationship on an extension table. Figs. 319 and 320 illustrate very well the result that can be obtained in certain cases by this form of treatment.

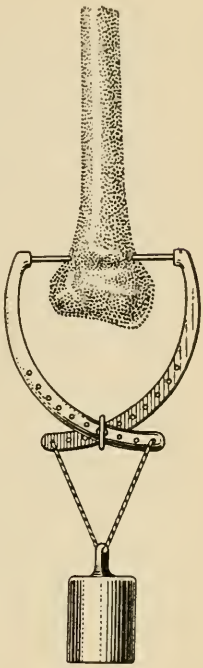

Fig. 314.

Figures 321, 322 and 323 represent Hœfftcke's splint. Traction is exerted on the foot, counterpressure being obtained by the impact of the splint against the tuber ischii through which the patient transmits his weight.

I will now describe in detail the means by which the fragments are brought into apposition in the case of fracture of the long bones of the leg, how they are retained in position and how all risk of sepsis is avoided.

In operations on fractures of the leg the procedure is much more

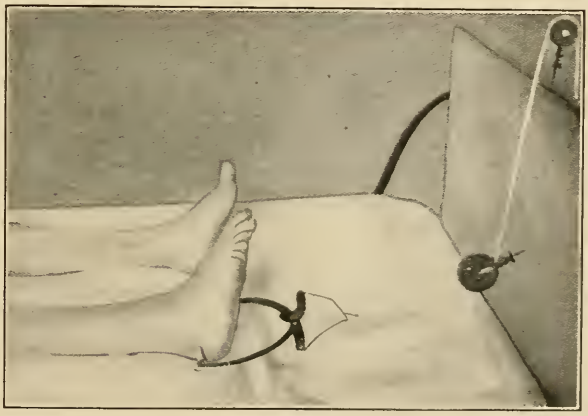

Fig. 315.

simple than in fractures of the arm since in the former there is not the same risk of damage to nerves, vessels and tendons that there is in the

latter. An incision of a length sufficient to expose the fragments most freely is made in a convenient situation. In fractures of the femur the incision is usually made on the outer side of the thigh and the extensor

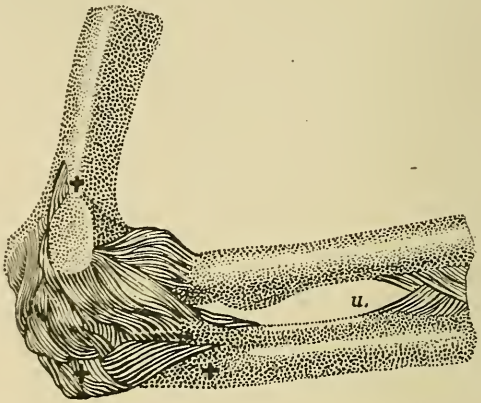

Fig. 316.

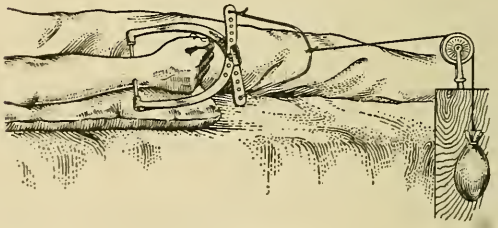

Fig. 317.—Site of selection (lower end of radius) for fractures of elbow and forearm.

Fig. 318.

muscles are divided at their origin. In this way there is no possible risk of damage to any important structure and there is practically no limit to the length of the incision and to the facility with which the fragments can be exposed and handled. An incision should not be made

through the belly of a muscle if it can possibly be avoided as, for instance, through the muscles of the part of the thigh, since this results in

FIG. 319.

FIG. 320.

anchoring of the muscle at the seat of incision and a shortening with consequent fixation of the knee-joint. The edges of the skin incision are covered by the margin of a sterile towel which is secured in position

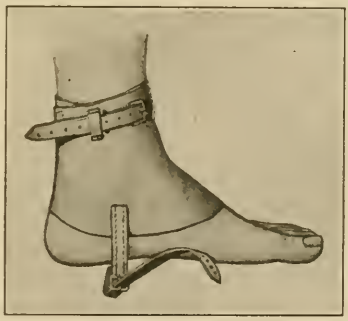

FIG. 321.—Hoeffitcke's anklet strap.

by means of the clip forceps illustrated in Fig. 324. These are held by two assistants who retract the skin by pulling on the forceps. The

muscles being divided, the fragments are freely exposed and freed from the surrounding soft parts and blood clot.

If the fracture has been produced by direct injury, each fragment is grasped in the jaws of a pair of long powerful forceps such as those illustrated in Figs. 325 and 326. The limb is adducted to a right angle so that the ends of the fragments are made to protrude from the wound. This is indicated in Fig. 327. The arrows *AA* represent the force exerted by the forceps upon the fragments, the arrows *BB*, the strain exerted on the fragments by pulling the leg straight. The adjacent edges of the ends of the fragments are placed in

FIG. 322.—Hoefftcke's splint.

FIG. 323.—Hoefftcke's splint.

apposition and are so held while the limb is gradually extended. The difficulty experienced in replacing the fragments varies with the shape of the broken surfaces. The more oblique the face, the greater is the obstacle to retaining them in position while the leg is being extended. However much the overlapping, extravasation, lacerations, etc., by this simple means the fragments are put accurately in position with the greatest facility and with the expenditure of a minimum of energy. To attempt to effect the same purpose by traction on the limb alone would be as ridiculous as it is unnecessary, while the employment of a sufficiently great force (by means of cumbersome apparatus) would materially increase the risk of sepsis.

number of powerful *instruments have been devised* for this purpose. They are not only unnecessary, but they are also a source of danger. If the fracture is spiral in form, being produced by indirect violence,



Fig. 324.

accurate apposition is readily effected on the principle of the double inclined plane. The fragments are retained forcibly in apposition by means of strong gripping forceps of which there are various kinds to

Fig. 325.

meet the different shapes of the long bones. By rotating these forceps on their long axes, the fragments are readily moved on one another. Should this not be sufficient, a flat elevator with sharp edges is intro-

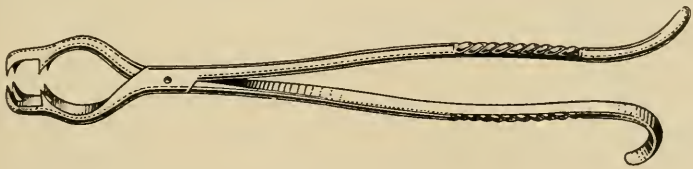

Fig. 326.

duced between the opposing surfaces held in apposition by the forceps. By rotating the elevator on its own axis the surfaces of the bone can be moved on each other with great facility, the rotating lever affording a force that is practically irresistible.

The fragments having been placed in accurate apposition, nothing short of perfect restoration of the form of the bone should satisfy the surgeon. A plate of sufficient strength and length to hold the fragments securely should be placed in position. This can be best done by grasping the plate in a forceps constructed for the purpose (Fig. 328). Some judgment is required as to the exact position of the plate in order to minimize the risk of splitting of the fragments which may result during the introduction of the screws or subsequently when strain is thrown on the junction of the subsequent movements of the adjacent joints necessary to avoid stiffness or limited movement. The earlier movement is effected in the joints in the vicinity of the fracture the better, and this is particularly true of the knee-joint; indeed the stiffness in this articulation may take more time and require much more care and treatment than the fracture.

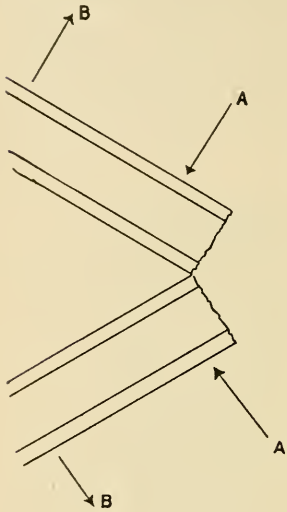

Fig. 327.

Therefore, in choosing a plate or plates and determining the number of screws and the situation of the plate the surgeon has to bear in mind their behavior under perhaps considerable strain subsequent to the completion of the operation. This is a comparatively simple matter in the case of the femur in a vigorous adult, but it requires much more judgment and

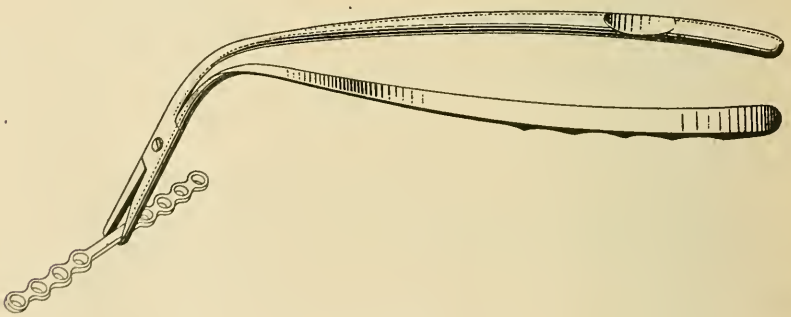
Fig. 328.

skill in an abduction fracture of the ankle, commonly called Pott's fracture, particularly when the texture of the lower fragment is by no means dense.

The screws which are most generally useful are what are commonly

called wood screws in the trade. These are threaded up to the head, since, the proximal compact tissue alone being employed, the barrel of the screw no longer serves any useful purpose. For convenience the screws are made up in several gauges—3, 5 and 7 being those

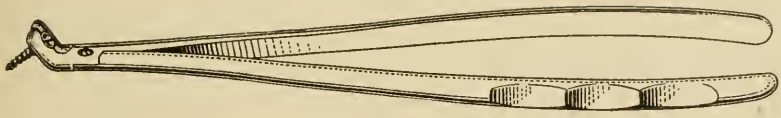

Fig. 329.

which meet most cases—and they vary in length from ⅜ to ⅞ in. They are readily held in the forceps which are represented in Fig. 329, and the form of screw driver shown in Fig. 330 is a useful one. I

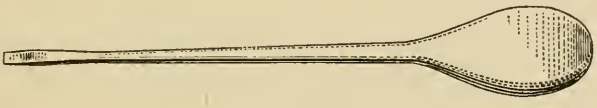

Fig. 330.

have found these simple means more useful than the more complicated instruments which have recently been put on the market.

During the performance of the operation any bleeding point is at once secured in by powerful hemostatic forceps. The most suitable

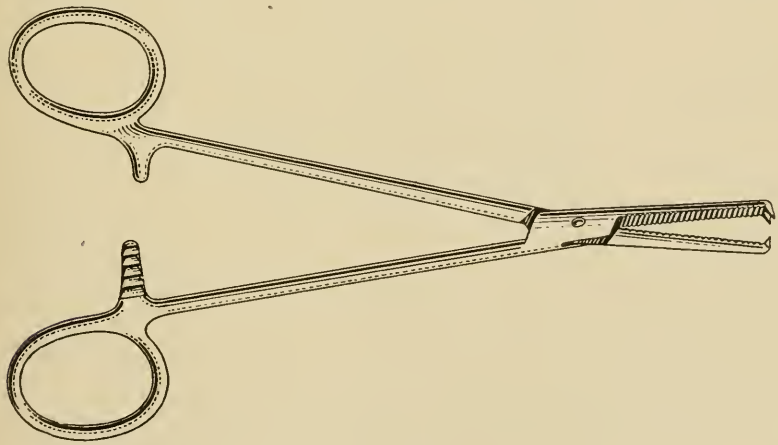

Fig. 331.

variety is that called Kocher's on the Continent and Ochsner's in the States (Fig. 331). These forceps are left in position till the operation is complete. Their removal is not followed by any hemorrhage. No

sutures either for ligating vessels or for bringing together soft parts are employed in order to avoid any chance of sepsis by the introduction of the gloved hand into the wound. The fascia is not sewn together in order that any extravasated blood may escape into the loose subcutaneous tissue by which it is readily absorbed. If it is shut up in and beneath the muscle it may remain unchanged for a long period of time and become a source of inconvenience and perhaps anxiety.

The edges of the skin incisions are held in accurate apposition by dissecting forceps while they are secured by means of Michel's clips placed as closely together as tension on the skin requires. The closing of the skin wound may be a very simple process, but if there is much swelling of the soft parts it may be the most troublesome part of the operation. If there is much difficulty it is better in the first instance to secure apposition by placing a number of tissue forceps at frequent intervals on the edges brought together by toothed dissecting forceps. It is essential that the forceps used for this purpose should have sharp terminal teeth to hold the skin edge securely. When this is done the clips can be fixed between the forceps which can then be removed leaving a perfect apposition of the skin edges, a matter of enormous importance in operations on simple fractures.

While the use of plates and screws affords the most simple means for retaining the fragments immovably in accurate apposition, the same may be effected as perfectly, though perhaps with more difficulty, by screws or by wire or by both in combination. This is well illustrated in Fig. 332. The surgeon should be ready to employ any means to effect his purpose.

Perhaps the two chief obstacles to the restoration of a bone to its normal form are excessive comminution and such a loss of density of the bone as renders it unable to hold a screw. The latter condition may exist in feeble old age but is present quite early in life in alcoholic subjects. Alcohol seems to possess the peculiar quality of reducing the density of the skeleton. This symptom may be the only evidence of excessive use of alcohol that the several tissues of the body show.

No surgeon possessed of an atom of sense would ever imagine that the removal of a spike or portion of a fragment could possibly facilitate the restoration of the bone to its normal form. I mention this as I have known large portions of spiral fractures of the femur removed and very considerable shortening and disability result from the incapacity of the surgeon.

If much comminution of fragments exists it is best to secure a long

steel plate with continuous holes to the stronger and stouter fragment, which is usually the lower, and then to connect up the intervening fragments to the plate, finally fastening the plate to the upper fragment. In some cases it may be necessary to employ a number of small plates in addition, in order to fasten the smaller fragments together.

Sometimes the bone may be too thin to hold screws, when the surgeon must employ such other methods as he can devise in the circumstances. For instance, Fig. 332 shows the result of an operation in a comminuted fracture of the femur in an old woman. Owing to hip disease in early life, the hip-joint was fixed in a position of considerable

FIG. 332.—Femur four months after operation for comminuted spiral fracture.

flexion and adduction. The bone was so wasted from want of use that the compact layer was not sufficiently thick to hold a screw. I was able by means of silver wire to restore the femur to its normal form and to its acquired function by suturing the fragments to one another by loops which perforated them and held them sufficiently securely to obtain a perfect anatomical result.

Loss of density of the bone is particularly noticeable about fractures with displacement of fragments in which some time has elasped since the receipt of the accident. It is always more marked in the distal than in the proximal fragments and develops with greater rapidity in-

versely as the age of the patient. In infancy the change takes place within a very few days. On this account fractures taking place at birth and those occurring in very young life should be operated on as soon after the receipt of the injury as possible. The earlier the operation the more perfect is the result.

Before proceeding to consider the several fractures of the lower extremity it would be well in the first instance to review some points in the function or business of the several bones and joints, since the descriptions in anatomical and surgical works are frequently inaccurate or misleading. As pointed out previously, the skeleton represents the crystallization of lines of force which are laid down as compact tissue when that force is exerted in one direction and as cancellous tissue when in many directions. The chief function of the femur is to transmit weight from the innominate bone to the tibia.

In its relationship to the innominate bone it acts as a lever, the fulcrum of which corresponds to the center of the head and the point through which the weight is transmitted to that portion of the front of the neck which impacts on the margin of the acetabulum in flexion. It was owing to the want of knowledge of this fact that the dislocations and fractures of the upper end of the femur have been so incorrectly described. In order to know how to deal with fractures of the femoral neck and dislocations of the hip-joint it is necessary to be thoroughly familiar with the mechanics of this articulation. The degree of extension and outward rotation of the hip is controlled by the very powerful anterior ligament. Flexion of the hip is limited by the impact of the neck of the femur against the acetabular margin.

In vigorous adult life it extends through about 90 deg., is greater in young life as the parts are softer, and less in old age when they are more rigid. The range varies directly with abduction and inversely with adduction. Indeed in extreme adduction the range of flexion is very small while in extreme abduction it is very great. When the laborer carries a heavy load on his shoulder or back he walks with his hip-joint adducted and flexed sufficiently to lock this articulation so that he economizes enormously his expenditure of nerve and muscle energy. The result of this habitual fixation is the formation of a facet on this part of the neck of the femur, the form and locality of which varies with different occupations.

One would have imagined that such a well-defined and common facet shown on the neck of the femur in Fig. 333, could not have escaped the eye of the anatomist who takes a pleasure in tracing minute fila-

ments of nerves through bone, but here as always it is the obvious that escapes everyone's observation. What is the result of flexion by a force greater than the structures of the body are able to sustain? The leverage exerted through the femur may be enormous and may be still further increased if the force be exerted on a fully extended limb. The lower or posterior portion of the capsule may yield and the head may slip through the rent, a dislocation resulting. The further dis-

FIG. 333.—Anterior aspect of upper extremity of right femur of coal-trimmer.

placement of the head varies as the femur is adducted or abducted at the time. Or the lever may yield at its weakest spot which usually corresponds to the neighborhood of the point of impact of the neck upon the acetabular margin.

In young life this corresponds to the junction of the neck of the femur with the epiphyseal line, and late in life the neck is weakest at this point and breaks accordingly. In vigorous adult life the situation of the fracture which is of comparatively rare occurrence is not so fixed, but varies within wider limits. The so-called extracapsular

fracture is quite distinct from the fracture of the neck just described and usually called intracapsular.

It is produced by a fall or blow on the outer surface of the great trochanter and the mechanics of the joint is such that while the base of the neck is driven downward and outward into the upper extremity of the shaft, the shaft is rotated outward on a vertical axis so that the back of the base of the neck is more deeply embedded than the anterior portion.

While this fracture takes place in vigorous life the bone is usually much denser than is commonly the case in intracapsular fracture but,

Fig. 334.

on the other hand, in the former the great trochanter and upper part of the shaft are very liable to be comminuted.

Should the surgeon consider that the requirements of the individual call for a mechanism as perfect as possible in any of these varieties of fracture and should the texture of the bone in the intracapsular fracture be sufficiently dense to hold a screw, operative interference should be undertaken.

In this case the upper end of the femur is exposed freely through a vertical external incision and the head and neck are secured in perfect apposition by long screws in the case of the intracapsular (Fig. 334) and usually by an anterior plate in the extracapsular variety. While

these operations are comparatively easy in the recent fracture of the neck they are rendered much more complicated in old-standing ununited fractures in which a perfect result can never be obtained because of the shortening of the neck which ensues so rapidly on the injury. The freshening of the opposing surfaces of neck calls for a consideradle amount of manipulative skill.

Fig. 335.

Great care must be taken to obtain perfect radiograms in order that the operator may be able to arrange beforehand the exact length of screws, and the situation and direction in which they can be introduced to greatest advantage and to avoid any risk of perforating the articular surfaces of the head of the femur and of the acetabular cavity (Fig. 334).

It is unusual for a separation of this epiphysis of the head of the

femur to be recognized at the time, chiefly I fancy because of the smoothness of the opposing surfaces which permits of the patient walking without much pain. In consequence attention is called to these cases subsequently either because of an excessive outward rotation of the thigh or a limited flexion due to the impact of the stump of the neck against the anterior inferior spine or to both these conditions.

The excessive outward rotation can be met by exposing the anterior ligament and rotating the thigh inward and by shortening up the ligament while the range of flexion may be materially increased by chiseling off the portion of neck which projects forward.

Figure 335 shows an old fracture through the epiphyseal line of the neck associated with considerable outward rotation of the thigh. This was controlled by suturing up the capsule by means of silver wire as illustrated in the radiogram.

When the shaft of the femur is broken by indirect violence, the character of the fracture and the form of the fragments are similar to those which exist in a spiral fracture of the tibia and fibula, while the displacement is usually in the same direction, the lower fragment being displaced upward, backward, and outward, and the upper fragment downward, forward, and inward. The torsion of the femur in these cases usually results from a fall upon the abducted foot, the trunk rotating on its axis in the opposite direction upon the abducted femur.

That torsion of the femur may be exerted in various directions is obvious, and the displacement of fragments must vary in consequence.

The force required to break a femur by direct violence is often very considerable, so that in this variety of fracture the laceration of the soft parts may be very great.

The treatment of fractures of the femur is based on precisely the same principles as those of the tibia.

In both varieties the fragments are exposed by incisions, extending, in some cases, along the whole length of the outer aspect of the thigh.

If the fracture be the result of direct injury the fragments are held in forceps and are withdrawn from the wound, the lower leg being carried simultaneously over the other leg till the fragments of the femur form an angle of 90 deg. or less with one another in a horizontal plane. The inner edges of the fragments are held in apposition by the forceps. The leg is straightened, while the fragments are forced back into the wound, so that the broken surfaces are brought into accurate apposition, and the bone is restored to its normal form and function. This has already been indicated diagrammatically in Fig. 327. In this manner

coaptation is effected with the use of a minimum of force and a maximum of skill, in the simplest and easiest manner possible. The frag-

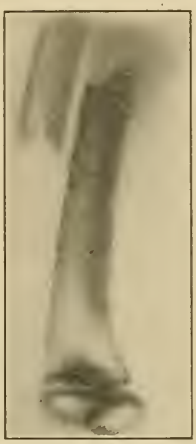

FIG. 336.—Fracture of the shaft of the femur in a child, about its center, produced by direct injury.

FIG. 337.—After operation.

ments are then retained in position by means of a stout steel plate and screws (see Figs. 336 and 337).

FIG. 338.

Figure 338 shows the displacement of fragments in an antero-posterior plane in an old badly united fracture, the result of direct injury. The influence of the malposition of the fragments on the mechanics of

the knee-joints was disastrous to its functions. The nearer the extremity of a long bone the fracture takes place the greater are the alterations in the mechanics and functions of the adjacent joint.

I do not hesitate to operate and to ensure a perfect result even when the displacement is inconsiderable. It is obvious that the only way in



Fig. 339.

which a perfect functional result can be obtained for certain is by accurately restoring the bone to its normal form. This can be done only by operation. Operative treatment not only ensures a perfect anatomical and functional result, but it telescopes the period of disability by enabling the patient to use the muscles and joints of the

damaged limb from the date of operation. It also frees the surgeon from any anxiety as to the result, and it relieves the patient from all pain subsequent to this operation.

Figure 339 shows a recent spiral or torsion fracture of the femur. When the femur is broken spirally the fragments are restored to their normal position by holding the lower leg in a condition of strain and by manipulating the fragments upon one another by means of a couple of long powerful forceps, which readily control them. The shorter the spiral fracture the more difficult is it to secure perfect coaptation, since one spike or one edge so readily gets beneath the other fragment. A

Fig. 340.

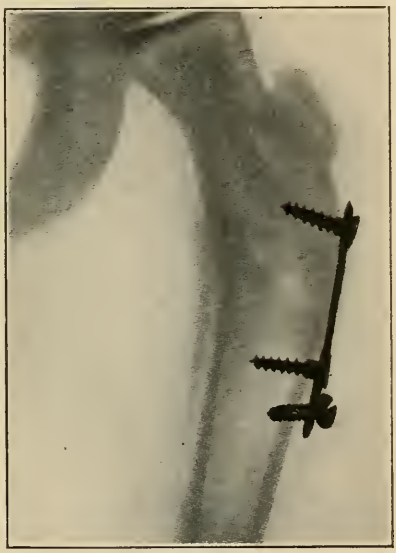

Fig. 341.

short spiral fracture of the femur in a young child may make great demands on the skill and patience of the surgeon and his assistants.

No surgeon possessed of an atom of sense would ever imagine that the removal of a spike or portion of a fragment could possibly facilitate the restoration of the bone to its normal form. I mention this as I have known large portions of spiral fractures of the femur removed and very considerable shortening and disability result from the incapacity of the surgeon.

If much comminution of fragments exists it is best to secure a long steel plate with continuous holes to the stronger and stouter fragment, which is usually the lower, and then to connect up the intervening fragments to the plate, finally fastening the plate to the upper frag-

ment. In some cases it may be necessary to employ a number of small plates in addition, in order to fasten the smaller fragments together.

In all fractures of the femur the surgeon should bear in mind the great importance of moving the knee-joint at the earliest possible moment. I have experienced far more trouble in dealing with ankylosis



FIG. 342.

of the knee consequent on the usual treatment of fracture of the femur by splints, etc., than I have in restoring the displacement of the fragments by operation.

Figure 340 shows a not uncommon variety of fracture of the upper limit of the shaft of the femur which results from direct violence or

from the impact of the bonnet of a motor car. This occurred in a young girl. The difficulties of effecting accurate apposition were very materially increased by the fact that it was impossible to grasp the fragile upper fragments in forceps.

The bone was restored to its normal form, the fragments being secured by a plate and screws as illustrated by Fig. 341.

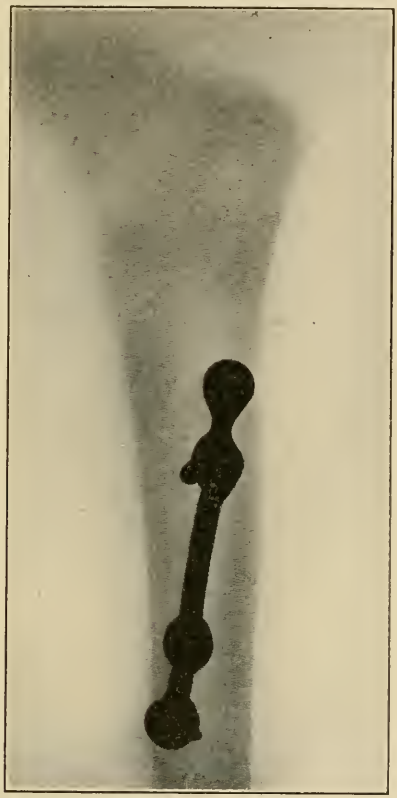

Fig. 343.

The child obtained a limb that was perfect anatomically and functionally.

Figure 342 shows a long spiral fracture of the femur in a child, while in Fig. 343 is depicted the result of operative interference. The fragments have been placed accurately in apposition and have been firmly reserved by means of a plate and four screws.

The surgeon should not control a growing line by a plate or other means. If he is obliged to do so in order to retain the fragments in position, he should remove the control when union has taken place.

As I pointed out, "the rate of growth in the several portions of a growing line varies inversely as the pressure transmitted," and a neglect to remove the controlling apparatus results in a cessation of growth over the area of the growing line that is affected.

Figure 344 shows a fracture partly through the inner part of the epiphyseal line, and partly through the shaft of the femur. The fragments could be replaced in apposition by force, but it was impossible to retain them without the use of some apparatus.

FIG. 344.—Fracture through lower epiphysis of femur.

Consequently, I introduced several staples, as they were more adaptable to the situation than a plate (see Fig. 345). I did so on the understanding that I was to be permitted to remove them when union had taken place. When the boy got well the parents refused to allow of their removal. When I saw him a year later he had developed a bowing of the leg, due to cessation of growth in the inner segment of the growing line.

FRACTURE OF THE PATELLA

Fracture of the patella is best treated by the use of a thin steel plate and two screws. In some cases it may be necessary to use two

plates, especially when the bone is comminuted. To apply a plate the fragments should be brought into accurate opposition and held securely

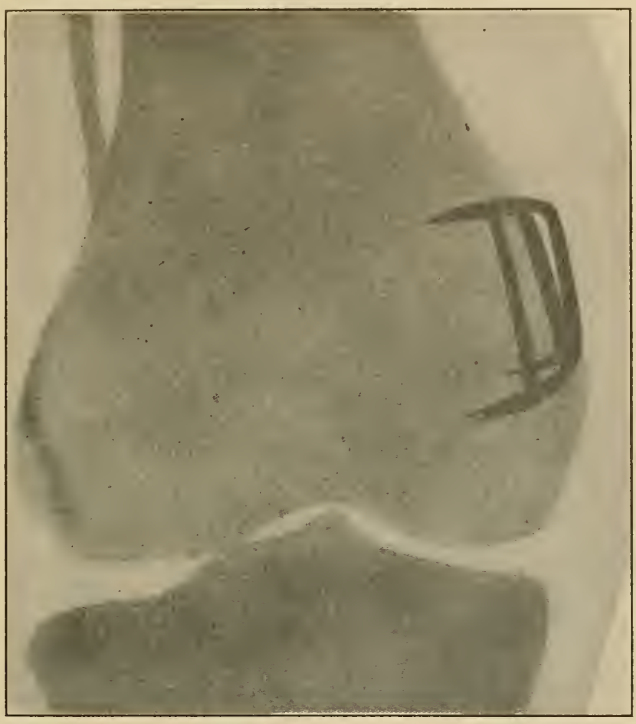

FIG. 345.

FIG. 346. FIG. 347.

in a powerful pair of forceps. For this purpose I employ a forceps with very long sharp curved teeth which, perforating the muscles and tendon above and below the patella, force and hold the broken surfaces together.

The front of the patella is cleared over an area of all fibrous tissue, and the plate is bent to fit the surface of the bone accurately. A couple of screws, usually No. 5 gauge and half an inch long, are introduced. By this means a coaptation of the fragments is secured, which is more accurate and more efficient than can be obtained in any other way (see Figs. 346 and 347), which show a fracture of the patella before and after operation.

SECTION IX

DISLOCATIONS OF THE JOINTS OF THE LOWER EXTREMITY

By

CHARLES HERBERT FAGGE, M.B., B.S., F.R.C.S.

Dislocation of the Sacro-Iliac Joint.—Complete uncomplicated dislocation or luxation of the sacro-iliac joint is so rare a result of injury that some authors doubt its occurrence. While diastasis of the articular surfaces, when it does occur, is usually incomplete, so that subluxation is a better definition of the condition, yet complete unilateral dislocation at this joint may occur as a result of crushing of the pelvis. It is, however, true that the results of such injuries are usually fractures of the ilium or lateral mass of the sacrum into the sacro-iliac joint, with subluxation, rather than a complete uncomplicated dislocation. Again, records show that, associated with other extensive injuries, dislocation of the sacro-iliac joint is met with in the post-mortem room. These cases have little clinical interest, as they are, owing to shock or visceral laceration, usually fatal before any attempt at diagnosis or treatment can be made.

Luxation of the sacro-iliac joint, when it occurs, is a result of direct application of force to the lateral aspects of the pelvis. The iliac bones being compressed, the sacrum is forced downward and forward so that the antero-posterior diameter of the pelvis is diminished. This must necessitate rupture of the posterior sacro-iliac ligament, and it is owing to the strength of this connection between the two bones that uncomplicated dislocation is rare. For here, as in similar injuries about the foot, there is less resistance in the bony structure adjacent to the joint than in the ligament itself, and dislocation is complicated by fracture.

Signs and Symptoms.—The history of severe trauma, associated with inability to walk or even to sit upright, and considerable pain down the lower extremity, from stretching or hemorrhage around the sacral nerves, will usually lead to suspicion of injury of this joint, if the hip-joint and the neck of the femur are found intact. But in the only case of this injury of which the writer has any knowledge, diagnosis

was proved correct only by an X-ray photograph (Fig. 348), when the first suspicion of displacement of the sacro-iliac joint had been aroused by undue prominence of the sacrum on rectal examination.

Treatment.—It is scarcely to be supposed that reduction of this dislocation could be brought about by temporary or continued extension, and though an effort should be made to reduce the deformity under an anæsthetic, as soon as diagnosis is arrived at, it is probable the treatment will be limited to rest on the back for four weeks. During this period, while the patient is in bed, comfort and accessibility for nursing purposes may be increased by fitting a double Bryant splint;

Fig. 348.

and it would be wise, for a second month, while the patient is convalescing, to apply a plaster spica to the thigh and pelvis of the side affected.

Results.—There are no statistics which can guide us as to the prognosis of this injury. Most writers surmise that some weakness and lameness usually result. In the case of which the X-ray was shown above, though a few weeks rest in bed was the only treatment, the patient's gait and development are apparently normal and she has no pain.

Dislocation of the Hip.—Dislocation, the result of the application of force upon a healthy hip-joint, is a rare injury, forming not more than 2 per cent. of all dislocations, and, while possible at any age, occurs usually between the ages of 20 and 50. Krönlein[1] in 400 recent traumatic cases, found that 2 per cent. were dislocations of the hip. It will be natural to contrast traumatic dislocation with (1) congenital dislocation, and (2) pathological dislocation, the result of diseases of the joint, the last-named being met with as a result of turbercle, infective arthritis of the hip, locomotor ataxia, in order of decreasing frequency. In the writer's experience, pathological dislocations of the hip have been less common than those resulting from traumatism, and congenital displacements still rarer than pathological ones, though 10 years' work at a children's hospital afforded far greater opportunities of meeting with the last than are met with in general surgical practice.

The kind of force which produces dislocation of the hip-joint is indirect, such as a heavy body falling on the shoulders with the thigh bent and adducted, or forcible abduction and flexion of the lower limb, when the subject is lying on his back. This application of force in a child will usually induce a separation of the epiphysis of the head of the femur, and in a person over fifty a fracture of the neck of the femur, of the so-called intracapsular type. Much controversy has raged about the questions (1) of the position of the head of the femur in which dislocation takes place, and (2) of the path taken by it to its varying ultimate positions. Anatomical knowledge that the weakest part of the capsule of the hip-joint is its inferior part at once suggests that it is here rupture is likely to take place, and this part of the capsule will clearly be stretched when the leg is abducted. Experiments on the cadaver, while their value must be received with caution, support this view, and since Morris[2] by a very careful examination of numerous specimens, added considerable confirmation to what was previously an unproved supposition, no important opinion has been expressed to the contrary. In his account of the mechanism by which dislocation of the hip is produced, it is clearly demonstrated that the head of the femur having, with the limb in the position of abduction, ruptured the capsule inferiorly, it will pass backward into the region of the obturator foramen; its further course will depend upon the position of the limb, and the direction and continuation of the force. If rotation inward of the femur be associated with the flexion and abduction, the head of the femur will pass backward and, assuming that the force is continued, will be driven upward on to the ilium, though, as Malgaigne pointed out, displacement of

the head actually on to the dorsum ilii cannot be said to occur. If this view, supported by Morris's evidence, is upheld, the classification of Bigelow[3] falls to the ground. According to this writer, posterior dislocations of the hip take place primarily above or below the tendon of the obturator internus, while, according to the view which clinical experience now supports, all displacements of the head of the femur are primarily below the obturator tendon.

Classification.—Whatever the position primarily occupied by the head of the femur may be, it ultimately comes to lie either in front of or behind a vertical line passing downward through the center of the hip-joint, and in the large majority of cases it will lie behind this line. Malgaigne introduced an elaborate subdivision of these displacements, but there seems no purpose in elaborating the simple classification of Astley Cooper[4] when he says, "I have seen the thigh bone dislocated in four directions:

First, upward or on to the dorsum of the ilium.

Secondly, downward or into the foramen ovale.

Thirdly, backward and upward, or into the ischiatic notch.

Fourthly, forward and upward, or upon the body of the pubes."

Thus, we should divide dislocations of the hip into

A. *Posterior.*—1. Dorsal, though bearing in mind Malgaigne's reservation, that in this variety the head of the femur does not actually reach the dorsum ilii, but lies above and behind the acetabulum, at the level of fusion of the iliac and ischiatic portions of the bone.

2 Sciatic, in which the head of the femur passes backward below the tendon of the obturator internus.

B. *Anterior.*—1. Thyroid or Obturator.

2. Pubic.

The posterior dislocations are the more common; thus, about 50 per cent. are dorsal, 25 per cent. sciatic, 13 per cent. obturator, and 10 per cent. pubic.

From a clinical point of view, and as a guide to treatment, there is little value in separating either the two posterior or the two anterior forms of dislocation from one another. It will, therefore, be easiest to consider the signs and symptoms common to posterior dislocations, and then those common to anterior dislocations, adding when necessary a few points in which the subvarieties differ from one another.

Signs and Symptoms of Posterior Dislocations.—The thigh will be fixed in a position of flexion, adduction and internal rotation. In the dorsal subvariety, flexion and adduction are slight, and suffice only to

bring the knee of the affected side across the inner half of the knee of the sound side; in the sciatic subvariety, flexion and adduction are more marked, so that the knee of the affected limb will cross the lower third of the femur of the opposite side (Fig. 349).

In the anterior subvariety in both forms, there is flexion, rotation outward, and abduction; in the obturator subvariety these are marked; in the pubic subvariety they are slight (Figs. 350 and 351).

FIG. 349.—Sciatic dislocation of the hip. (*Treves.*)

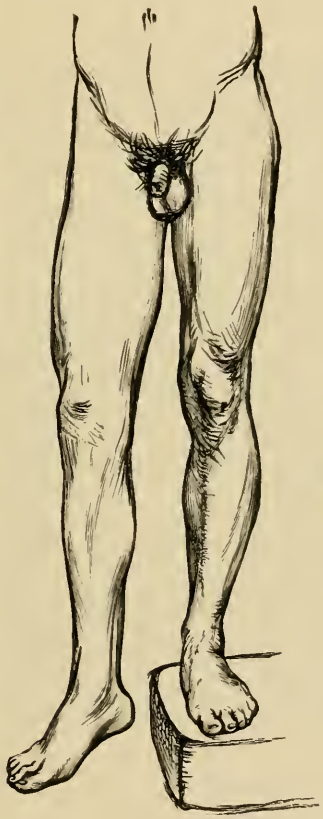

FIG. 350.—Obturator dislocation of the hip. (*Treves.*)

FIG. 351.—Pubic dislocation of the hip. (*Treves.*)

Signs Common to Both Forms.—In every form the classical signs of dislocation of any joint are present, namely, limitation of movement, alteration of the axis of the limb, abnormal situation of bony points around the affected articulation. It is evident that in the dorsal and pubic subvarieties shortening will be present, as in each case the head of the femur will be lying above the level of the acetabular cavity; and

though, theoretically, the limb should be lengthened in the sciatic and obturator subvarieties, this is masked by the degree of flexion present in both cases, and its estimation is rendered difficult and of little clinical value. When evidence of shortening has been obtained, it may be definitely located to the hip-joint or the neck of the femur by the use of Nelaton's line or Bryant's triangle.

Nelaton's Line.—If a line be drawn from the anterior-superior iliac spine to the most prominent part of the tuberosity of the ischium, the great trochanter will normally lie below this line. When the hip-joint is dislocated upward, or the great trochanter is drawn upward owing to a fracture through the neck of the femur, the great trochanter will lie above Nelaton's line.

Bryant's Triangle.—With the patient lying supine, a perpendicular is dropped from the anterior-superior spine on both sides toward the bed; a line drawn upward from the great trochanter to meet the first at right angles will be found shorter under the same conditions as when the great trochanter is above Nelaton's line.

In general use, measurement by Bryant's triangle is better than by Nelaton's line; for in fat subjects, or where there is much bruising, the tuberosity of the ischium is difficult to locate; moreover, measurement by Nelaton's line necessitates some turning of the patient. In either case, these lines are of diminished clinical value in fat subjects, owing to the difficulty of exactly locating the upper point of the great trochanter.

In all forms of dislocation of the hip, the X-ray examination is of great value. Interpretation of this examination is perhaps more difficult than the majority with small experience would admit. In the case of dislocations of the hip as noted by Shenton,[5] the unbroken arch (Fig. 352) which normally can be followed outward from the lower border of the horizontal ramus of the pubis to be continuous with the lower border of the neck of the femur, is interrupted; in those in which the head of the femur lies above the acetabulum, its outer segment will be too high, and the reverse is true when the head of the femur lies below the acetabulum.

Differential Diagnosis.—1. From congenital or pathological dislocations; by the history of recent onset, absence of former disease, and history of traumatism.

2. From other results of traumatism. By far the commonest difficulty in diagnosis likely to present itself is that from fracture of the neck of the femur, particularly of that variety where the line of fracture passes through the base of the neck. This difficulty is increased

by the fact that impaction is frequently a complication of this fracture, which usually results from direct violence applied laterally to the great trochanter. From any variety of fracture of the neck of the femur the usual variety of dislocation of the hip (dorsal) may be diagnosed by the position of the limb (see above), whereas in all fractures of the neck shortening is associated with rotation outward of the femur. This position will be somewhat similar to that which the limb acquires in pubic dislocation, but in the latter the head of the femur can be felt

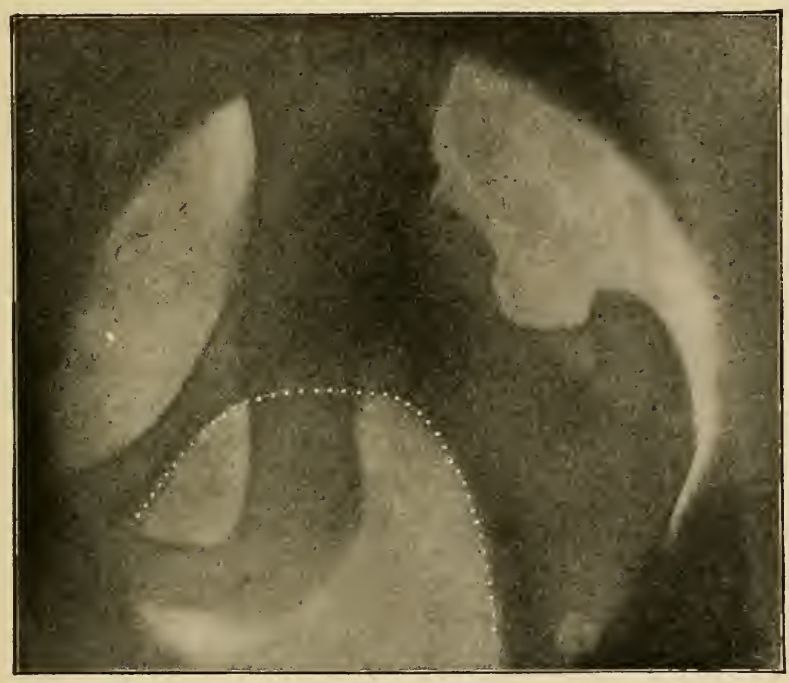

FIG. 352.

in the abnormal position; it is a much rarer injury than fracture through the base of the neck of the femur, and the presence of diminished mobility of the hip, characteristic of dislocation, should at once be noted in place of the increased mobility at the seat of fracture, met with in fractures of the neck of the femur. From an impacted fracture of the neck of the femur, the anterior type of dislocation may best be differentiated by an X-ray photograph. It is well to bear this in mind, and to obtain as much information as may be gained in any case in which this question arises, for an attempt to forcibly reduce a supposed dis-

location of the hip-joint may have unsatisfactory results if an impacted fracture of the neck of the femur is really being dealt with.

The association of dislocation of the hip with fracture of the neck of the femur is exceedingly rare, and has not occurred in the writer's experience, being in marked contrast to the fairly frequent association of dislocation of the shoulder with fracture of the neck of the humerus, as reported by Robert Jones,[6] but should this occur diagnosis is likely to be exact only from careful interpretation of good X-ray photographs.

3. Of the different forms of dislocation from one another. The position of the limb will at once separate anterior from posterior dislocations. It will probably be accurate to follow Morris in believing that the pubic type is merely a further stage of an obturator dislocation, and that dorsal dislocation has similarly resulted from a sciatic dislocation, owing to a continuation of the force producing them, or by the head of the femur being driven upward as the subject tried to bear his weight on the limb. In so far as treatment is concerned, there is nothing to be gained in further differentiating the two subvarieties of each type than can be done by a consideration of the signs given above, and by an examination of the X-ray plates.

Treatment.—(*a*) Of posterior dislocations. From the earliest times, the common method of reduction has been by traction, and in pre-anæsthetic days numerous contrivances were designed with the object of maintaining counter-extension upon the trunk while traction was made upon the lower part of the thigh. In more recent times these violent methods have been abandoned, and reduction by manipulation, which in England is known as Bigelow's method, has taken its place. Stimson[7] writing of Kocher's method, says, "the identity of this method with Bigelow's appears to me complete." In recommending it Bigelow ascribed priority of invention to Nathan Smith. The introduction of general anæsthesia was undoubtedly one of the factors which helped to make reduction by manipulation successful; and it can scarcely be too strongly insisted that, the diagnosis of dislocation of the hip having been made by physical examination, and confirmed by radiography, no manipulations for the reduction of the deformity should be undertaken until the patient is completely under the influence of a general anæsthetic, or the muscles relaxed by a spinal anæsthetic, for manipulations without an anæsthetic will be generally unsuccessful, and failure to replace the head of the femur can result only in further effusion of blood in and around the articulation and injury to tissues, which the experience of recent years has taught us is likely to account for

some permanent disability, and therefore no risk of causing it should be undertaken.

Bigelow's Method of Reduction of Posterior Dislocation of the Hip.—Under a general anæsthetic the patient is placed upon his back, the

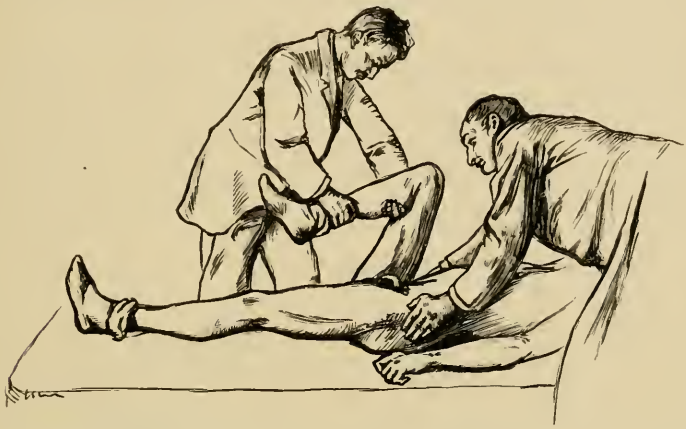

FIG. 353.—Flexion, abduction and rotation outwards in dorsal dislocation of the hip. (*Treves.*)

affected hip is flexed to a right angle, while the adduction resulting from the injury is maintained, and the thigh is rotated inward as far as pos-

FIG. 354.—Forcibly lifting the flexed femur in dorsal dislocation. (*Treves.*)

sible (Fig. 353). It is usually now necessary for one or more assistants to steady the pelvis. While this is being done traction is made upon the thigh (Fig. 354), the knee and hip still being flexed. This

traction brings the head of the femur down to the level of the acetabulum. When this has been carried out as fully as possible, the thigh is quickly and forcibly abducted, and then rotated outward, and owing to tension of the Y-shaped ligament the head of the femur is drawn forward into the acetabular cavity. The limb may then be laid down in extension.

Stimson[8] described an alternate method in which "the patient is placed face downward upon a table, with his legs projecting so far beyond the edge that the injured thigh hangs directly downward, while the surgeon grasps the ankle, the knee being flexed at a right angle; the weight of the limb now makes the needed traction in the desired

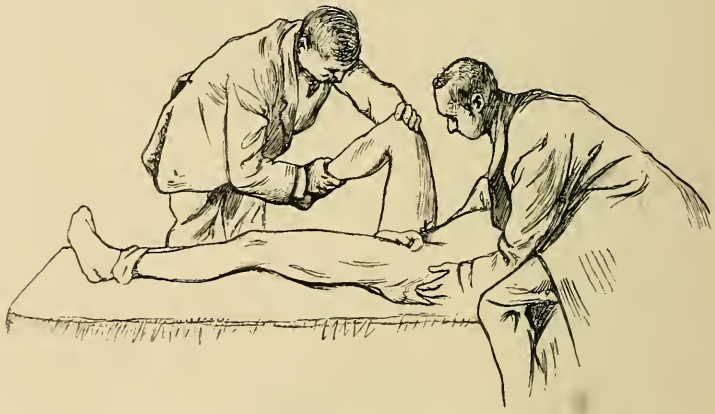

Fig. 355.—Flexion, abduction and rotation inwards in pubic or obturator dislocations. (*Treves.*)

direction. . . . Occasionally the weight of a small sandbag behind the knee, or the application of slight sudden pressure at the same spot is necessary. It will often succeed without anæsthesia, and has failed in only two cases in my hands."

Treatment.—(*b*) Of anterior dislocations. Bigelow's method reversed is applicable to these cases. The initial movement is an exaggeration of the abduction, the hip is flexed at a right angle and the thigh rotated outward (Fig. 355). By traction on the upper part of the thigh, the head of the femur is brought into the neighborhood of the acetabulum, when a smart adduction and rotation inward followed by extension will usually conduct it into the normal position.

After-treatment.—The sensation of the head of the femur passing into the acetabulum, with the restoration of smooth, free movement, will as a rule convince the operator that the dislocation has been reduced;

this may be confirmed by measurements, or by X-rays. In the writer's experience, manipulation under complete general anæsthesia has not failed in any case which has been treated within a day or two of the accident. When the dislocation has been reduced, it has been customary to apply a long outside splint (Liston's) to the affected limb, and the patient is placed flat on his back in bed, where he remains for two or three weeks. From the first, massage is of benefit and after three weeks, gentle passive movements may be instituted. It is not wise to allow the patient to begin to use the limb, nor to bear any weight upon it, until at least four weeks after the accident, though should there be any reason for getting him out of bed, he may be allowed to walk on crutches with a patten under the sound foot, and the affected hip encased in a plaster of Paris spica, as soon as the swelling resulting from the accident has subsided, which it usually will do within 10 days.

Prognosis.—Fortunately most likely to occur in healthy young male adults, this accident is not commonly followed by the very crippling progressive traumatic arthritis which is prone to follow injuries of joints in elderly people, but it is well to bear in mind that should a dislocation of the hip occur after 40, a certain degree of arthritis is probable, and the prognosis must be modified with this in view.

The writer has met with no case in which recurrence has taken place and it does not appear that those rare cases in which habitual voluntary dislocation can be produced in a hip-joint are usually sequelæ of this type of injury: in other words, a normal joint dislocated as the result of trauma, and reduced, is likely to remain cured and functionally perfect. Recurrent displacement may be usually regarded as a result of a congenital or other abnormality, apart from trauma, and is, therefore, not to be considered in this chapter.

Simultaneous Dislocation of Both Hip-joints.—This accident will naturally be considerably rarer than an isolated dislocation of one side. Most writers on the subject suggest that a backward dislocation on one side is likely to be associated with a forward dislocation on the other, but in the only case the writer has met with there resulted a dorsal dislocation of both hip-joints, while the subject was endeavoring to throw a horse.

Associated Injuries.—Injuries to nerves, vessels, or fractures of the adjacent bones may occur, but are relatively rare. Cases of fracture of the acetabulum associated with dislocation of the hip have been described, but inspection of a large series of X-ray photographs has not disclosed any instance of this complication. There is no association

between a fracture of the neck of the femur and dislocation of the hip, such as has been maintained by Robert Jones between dislocation of the shoulder and fracture in its vicinity; in fact the same injury which in a young healthy adult produces a dislocation of the hip, is likely in later life to produce a fracture of the neck of the femur and would in childhood probably separate the epiphyseal line of the femoral head, so that these injuries are in a sense antagonistic, and not likely to be associated. As a result of severe "run-over" accidents, compound dislocation of the hip-joint may be met; in the only case in the writer's experience, shock and other injuries produced an early fatal result. If treatment were called for in a similar case, it would be wise, while the dislocation was reduced by ordinary methods under a general anæsthetic, to disinfect the wound and surrounding skin, as far as possible, with a spirituous solution of iodine and to apply a sterile dressing and provided that sepsis did not result, and satisfactory healing were obtained, this complication should not interfere with the ordinary progress and after-treatment of dislocation of the hip. Should sepsis result, however, incision, drainage, or even amputation of the hip-joint may have to be considered, according to the severity of the constitutional and local disturbance.

Treatment of Old Unreduced Dislocations.—The first question that will arise is as to the interval which may have been allowed to elapse between the accident and the effort at reduction. In England this need never be more than a day or two, even under unfavorable circumstances, and it is probable that reduction could with as great certainty and safety be effected within a week of the accident, as immediately. Conversely, successful reduction after a fortnight becomes doubtful, and will be accomplished only with great difficulty, if at all, after a month. It is, of course, perfectly justifiable and safe to attempt manipulative reduction under an anæsthetic, in these cases, and this should without doubt be done, as a first measure, in cases of even longer duration, provided that the operator bears in mind that he is attempting to overcome a deformity by manipulation and not by force. It is in these old cases that damage is done for two reasons: firstly, manipulations of moderate force, which under ordinary circumstances would be successful, will in such cases be futile, and therefore the operator is tempted to try stronger methods; secondly, adhesions will have formed in and around the capsule, and muscles will have become tight and shortened to accommodate themselves to the altered mechanical conditions. Permanent disability and limited range of movement can result only from the injury and blood effusion which immoderate violence must entail

so that in all these cases it is well to bear in mind that the amount of benefit likely to result is inversely proportionate to the force used. Provided moderate manipulation, with a complete anæsthetic relaxation, does not attain the required end, it must be discontinued, and the question of operative reduction suggested to the patient, as an alternative to spending the rest of his life with an unreduced dislocation of the hip-joint. So many factors, such as age, occupation, habits, social position, duration of the dislocation, influence this question, that it is difficult in a short space to do more than generalize. However, the experience which many surgeons must have had, of the extremely satisfactory and painless progression, in spite of a marked limp, which is so commonly met with in dislocations of the hip, the result of tuberculosis and other diseases, must be borne in mind, and should warn the more heroic surgeon of the chance of failing to improve his patient's progression, even after prolonged and possibly painful treatment, by a hasty recourse to surgical interference.

It will be clear that dorsal displacement of the head of the femur is mechanically a greater disadvantage than either of the anterior displacements, and the line of treatment of the former—similar to that introduced by Lorenz in the treatment of intractable congenital dislocations of the hip, which are always of the dorsal type—will at once suggest itself, namely, the conversion, by forcible manipulation or by operation, of a dorsal into an anterior dislocation. This has been advocated, as a method of non-operative partial reduction, by Lorenz, under the name "transposition." Should the surgeon in charge decide that operative interference is desirable, he will have the choice of arthrotomy, resection of the head of the femur (which practically amounts to an excision), osteotomy through or below the head of the femur and possibly amputation. The last can conceivably only be called for in such rare conditions as compound dislocation of the hip-joint complicated by suppuration. It is impossible to enter into the details which may influence the choice of one of these different methods in any individual case; each case must be judged on its merits.

The following considerations must be borne in mind in coming to a reasonable conclusion.

1. The voluminous descriptions contained in textbooks and numberless papers even of recent date, upon the accidents which may occur in attempting to reduce a dislocation, particularly apply to forcible efforts at reduction of long-standing displacements. These are absolutely avoidable and therefore in the present day, when operative inter-

ference can be undertaken with less risk than formerly, there is undoubtedly a tendency to resort to it much more frequently. At the same time, though wound infection and suppuration after operative reduction of dislocations of the large joints is much less frequent than it was, owing to more rigid technique, yet an amount of reaction, which in many cases results in such a degree of fibrous ankylosis as to considerably prejudice the final result of the operation, must be peculiarly associated with this class of surgery, even in the best hands, and this possibility should ever be borne in mind.

2. When manipulative transposition has been found impossible, partial reduction by open operation may be undertaken, with the prospect of the same mechanical improvement, even though a fixed joint follows.

3. Excision of the head of the femur, unless it is undertaken as a means to the diminution of posterior deformity, is not to be recommended in the case of the hip-joint, where stability is required, unlike the joints of the upper extremity, where excision should be undertaken in order to increase the range of movement.

Dislocation of the Patella.—The patella may be displaced either in the transverse or vertical planes, or by rotation upon its vertical axis. Displacement upward must result from a rupture of the ligamentum patellæ, and displacement downward from injury to the rectus. It is very doubtful whether true inward dislocation ever occurs; so from the practical point of view there only remains to be described displacement of the patella outward, or the even rarer rotatory displacement, in which the patella lies edgewise against the femoral condyles (Fig. 356).

Outward Dislocation.—In this the patella is displaced outward on to (incomplete) or beyond (complete) the external prominent articular margin on the external femoral condyle. It will be remembered that this is more prominent anteriorly than the inner edge of the internal condyle, and by this means nature apparently provides against this displacement to which the normal angle outward at the knee-joint predisposes; it may, therefore, be that some congenital deficiency in the development of this ridge renders this accident possible, but undoubtedly a more common predisposing cause is some degree of genu valgum, hough in the writer's experience it has not occurred, as would be expected, disproportionately in women. Cotton notes that "it is rather apt to occur in stout non-muscular women, with some knock-knee and pronated feet" (Fig. 357). Though this is probably true of the recurrent habitual partial outward dislocations, the writer is inclined to think that

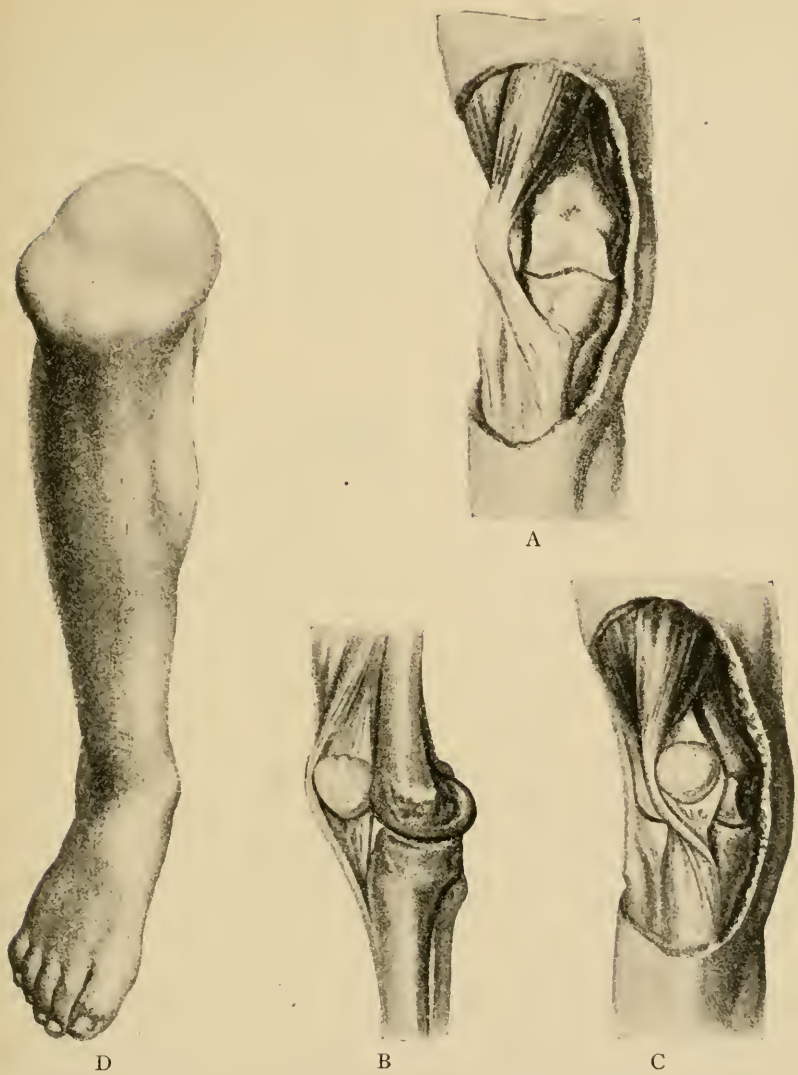

FIG. 356.—A, Specimen showing outward dislocation of the patella. The cartilaginous surface of the patella is in contact with the lateral surface of the external condyle. Anterior view. B, Preparation showing an internal vertical dislocation of the patella. The cartilaginous surface of the patella presents inwards or toward the median line of the body. Inner view of the right leg. C, Specimen showing complete, rotatory dislocation of the patella, produced by continuing the rotation from the position in figure B. Anterior view of the right knee-joint. D, Outward dislocation of the right patella in a man twenty-nine years of age (1880). The leg and region of the knee-joint are shown in marked flexion. The prominence of the patella to the outer side of the external condyle is very marked. (*Helferich.*)

the acute form is more common in men, and is usually the result of a direct blow on the inner side of the patella. The best example in his experience was that of a young muscular male adult, with a slight tendency to genu varum, in which the injury was the result of direct violence while playing football.

Symptoms.—With the knee semi-flexed, immovable and painful, the patella will be found to project subcutaneously considerably outside the anterior femoral articular surface, the inner portion of which can be plainly felt. Within a few hours, considerable effusion into the knee-

FIG. 357.—Reduction of dislocation of the patella by relaxing the quadriceps and direct pressure. (*Treves.*)

joint is likely to occur; the amount will depend upon the intensity of the original injury, and may best be inhibited by firm compression of the joint with a rubber bandage, over a thick layer of cottonwool.

Treatment.—Reduction in the acute cases may readily be obtained by passive extension of the knee with the hip fully flexed (Fig. 358). This, though painful, can be borne without the use of a general anæsthetic, and is perhaps easier within a few minutes of the occurrence of the accident than if effusion has been allowed to go on for some hours. It is probably right to assume that the fibrous expansion derived from the vastus internus and passing to the inner side of the patella as a reinforcement of the capsule of the knee, will in every case be injured, though to a varying degree, and therefore it is universally wise

to regard the ligamentous injury as the main reason for continued treatment. When after a week or two the effusion has been caused to absorb by compression and massage, the knee should be rigidly supported in a plaster-of-Paris cast, or with a rubber bandage, until the end of four weeks. If this is done, and no undue exercise is permitted until such time has elapsed as to allow the injury to the ligamentous tissues on the inner side of the patella time to heal, then further sequelæ are unlikely, and in the case quoted above complete freedom from any appreciable degree of disability has been enjoyed for 19 years, though the subject has played most games at will.

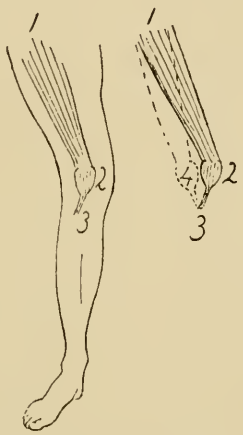

FIG. 358.—Shows the oblique pull of the quadriceps in cases of knock-knee, favored by excessive toeing out and consequent outward rotation of the tibia. If the quadriceps (1) with the insertion of its tendon on the tuberosity at (3) contracts, the obvious tendency is to pull the patella from its position at (2) to a point at (4) approximately in a line between the muscle belly, and the insertion of its tendon, *i. e.*, between 1 and 3. It is on account of this fact that the slipping of the patella is rather apt to happen in stout non-muscular women with some knock-knee and pronated feet. (*Cotton.*)

Rotatory Dislocation.—The writer has no personal experience of this injury, which apparently usually follows the type of the outer border of the patella passing forward and inward, so that the articular surface looks outward. Cases of the opposite displacement have been described, and probably are less common. It is curious that they should occur, for if simple displacement inward is doubtful or unknown, one would suppose that the factors which produce the one would also produce the other. If the rotation is carried through 90 deg., the outer or inner border of the patella will look forward; but if further rotation to 180 deg. takes place, so that the outer and inner borders of the patella are reversed, the articular surface will look forward.

Symptoms and Physical Signs.—The exciting causes are the same as those to outward displacement, and usually the diagnosis is made by feeling the smooth posterior articular surface of the patella, though this may be impossible if the joint is much distended. Cotton suggests that dimpling of the skin, owing to its close attachment, will identify the anterior subcutaneous surface. Reduction is obtained by forcible passive extension of the knee, if necessary under an anæsthetic, and the after-treatment and prognosis follow the lines of what has been said in the case of dislocation outward.

Recurrent Dislocations of the Patella.—These rarely result from the acute type spoken of above. They may be due to congenital defects, though not necessarily congenital in appearance, *e.g.*, the upward displacement which is met with in genu recurvatum. They may result from some former disease of the bones forming the knee-joint, such as tuberculosis, or, more commonly, they may gradually be acquired as the result of slow changes in the mechanics of the knee, which usually are due to rickets. An exaggeration of the normal genu valgum of women, scarcely sufficient to be regarded as pathological, is the commonest predisposing cause.

Treatment.—Should the displacements be frequent and painful, operative interference is usually required, though in slighter cases a knee-cap or a rubber bandage, to be worn when the patient is engaged in any unusual exertion, may give the necessary relief. When operation is being considered, it is important to decide whether the recurrent displacement of the patella is really due to an unusual degree of genu valgum, and if this is so, osteotomy after MacEwen's method, near the lower end of the femur, will be indicated. In the majority of cases, however, genu valgum is not the chief factor, and here the routine procedure has been plication of the inner side of the capsule with a rampart suture, so as to shorten the relaxed expansion which comes from the vastus internus to support the inner side of the patella. Goldthwait has modified this by splitting the ligamentum patellæ vertically, detaching the outer half, and carrying it under the inner half, fixing it to the inner margin of the tibial tubercle. As an alternative to this, the tubercle of the tibia, with the ligamentum patellæ attached, may be sawn off from its normal site, and transplanted inward; the credit for this operation is usually given to Roux. Krogius is quoted by Kocher as originating a method which promises better results. A long bridge-like strip of the vastus internus and its fascial insertion is raised up and transplanted to the outer side of the patella, to fill in a slit made in the

vastus externus; the margins of the elliptical gap left on the inner side are brought together.

Dislocation of the Knee.—As might be expected from the great strength of the ligaments connecting the bones forming the joint, these dislocations are of great rarity; Krönlein (*loc. supra cit.*) found that they formed less than 1 per cent. of all dislocations. They are peculiarly due to direct traumatism, and as in most cases this is caused by machinery or "run-over" accidents, are in an undue proportion of cases compound; only those in which the leg is displaced forward by hyper-extension of the knee are at all commonly due to indirect injury.

Displacement may occur in both directions of the antero-posterior or of the transverse planes, and any one of these four varieties may be complete or incomplete. It will be clear that complete separation of the articular surfaces forming this joint entails much more serious damage to the ligamentous structures supporting it than partial displacement or subluxation, and that the prognosis with regard to a useful joint is in the former class considerably less hopeful. Stimson collected 114 traumatic cases, and found that in 52 the tibia was displaced forward. Rose and Carless[9] are of opinion that lateral dislocation from trauma is the most frequent variety, and the writer's experience, though it has of course been extremely small, certainly agrees with this view. Perhaps the divergence of opinion, if not due to the smallness of any individual experience of rare injuries, may be put down to the inclusion among lateral displacements of the fairly frequent partial dislocations of the articular surfaces, whereas those in the antero-posterior plane are more likely to be complete. Dislocations in the antero-posterior plane may be forward or backward; of these two, displacement of the tibia forward is far the more frequent, when due to trauma, and is to be sharply contrasted with the backward displacement of the tibia, which not uncommonly results from chronic infective or tuberculous arthritis. As has been said, displacement forward may result from local trauma to the front of the thigh, or from extreme hyper-extension acting on the back of the calf or the foot. If complete, as it usually is, it entails rupture of the posterior ligament, of the anterior and posterior crucial ligaments, and usually of both lateral ligaments. The leg will lie in a plane anterior to the thigh, and the knee will remain fully extended; the skin will be stretched over the abnormally prominent bony points of the tibia, and this stretching will be enhanced by subcutaneous bruising; the posterior aspects of the femroal condyles will project into the popliteal space, and by abnormal pressure on the popliteal vessels

may jeopardize the vitality of the limb. In dislocation backward, the deformity is reversed. In traumatic cases it is usually caused by direct injury to the upper part of the tibia, or by the leg being caught in machinery. Probably owing to the tension of the quadriceps and the ligamentum patellæ, the knee is maintained in the extended position, with the head of the tibia lying behind and parallel to the lower end of the femur, and this posture may be contrasted with that seen in pathological displacements of this joint, resulting from chronic arthritis, which is always associated with some degree of flexion. Injury to the lateral ligaments is less severe than in displacements forward. The crucial ligaments, or at least the posterior one, are usually ruptured, and the posterior ligament is torn from its attachment to the femur; stretching of the popliteal vessels over the upper margin of the posterior surface of the tibia is likely to lead to their injury.

Lateral Dislocations.—It would appear that an incomplete lateral dislocation or subluxation at this joint is the commonest form of displacement met with in England. The tibia may be displaced outward or inward, and in either case injury to the lateral ligaments is probable. If displacement outward or inward is complete, the crucial ligaments are likely to share the strain with the lateral ligaments, and be torn; if the displacement is partial, the lateral ligaments will usually alone be injured. When the tibia is displaced outward, the external lateral ligament is liable to be torn from the femur, and the internal lateral ligament from the tibia, while the opposite is true when the displacement is inward.

Diagnosis.—In the absence of swelling, identification of the altered position of the bony points must be easy, and lead to the immediate realization of the true condition. In the presence of much swelling, it is possible, particularly if the displacement be incomplete, that confusion may arise with separation of the lower femoral or the upper tibial epiphyses. These latter injuries can occur only in those under 20 years of age, and if care is taken to accurately locate the level of the deformity, no confusion should be possible; in any case, X-ray photographs, taken in both the antero-posterior and transverse planes, must at once eliminate this difficulty.

Complications.—1. Of Stimson's 114 cases, in 21 the dislocation was compound. In these the possibility of obtaining a useful movable joint, or even of saving the limb, must be always in doubt; and, if there is any evidence of an associated injury to the popliteal vessels,

immediate amputation through the thigh is probably a safe line of treatment, in fact in these cases it has been largely adopted.

2. There is no other joint in the body of which the dislocation is more likely to interfere with the main vessels of the limb. Apart from the question of injury to these vessels by the original force, they will obviously be stretched over the lower end of the femur when the tibia is displaced forward, and over the upper end of the tibia when this bone is displaced backward. Interference with the circulation will be evidenced by the venous engorgement which results from pressure on the popliteal vein, and with the absence of pulsation in the posterior tibial artery, coldness and numbness of the foot will indicate obstruction to the popliteal artery. Until the bony deformity has been reduced it will at first be difficult to estimate how far the interference with the circulation is due to stretching of the vessels over one of the bones, or to associated blood effusion into the popliteal space pressing upon them directly.

3. While the nerves are less liable to injury from pressure, they may be bruised or torn by the original injury; thus, in one of the few dislocations of the knee-joint met with by the writer, there was a compound displacement forward of the tibia, with division of the external popliteal nerve, and this, in spite of immediate suture, was the chief factor which led to a bad result, and prevented the man from retaining his employment as a carman.

4. While it is usual for the crucial ligaments to be torn, the anterior crucial ligament may remain intact, and pull away the piece of bone to which it is normally attached in front of the tibial spine.

Prognosis.—In partial dislocations, which are usually in the transverse plane, prognosis is good; but in those which are complete, whether in the transverse or antero-posterior plane, the outlook, owing to the extreme ligamentous damage which is associated with the displacement, is less hopeful. A weak, unstable joint or a permanently deformed limb is more likely than any considerable limitation of movement. Thus, if either of the lateral ligaments be injured and treatment is not carried out with a view to its complete healing, permanent lateral flexion, either inward or outward, is probable, with consequent deformity and shortening. On the other hand, provided the joint has been fixed and immobilized for a sufficient period, in such a position as to remove all strain from the injured ligaments, healing will take place, and a mobile useful joint will result in unexpected frequency.

Treatment.—In any form of dislocation of the knee, reduction by

traction in the extended position, usually without an anæsthetic, is an easy matter. When this has been carried out, means must be taken to immobilize the joint; if there is much local bruising, or the vitality of the foot, owing to possible interference with the popliteal vessels, is in question, the immediate application of a plaster-of-Paris splint may be considered inadvisable; but complete immobilization in plaster of Paris, carried from the top of the thigh to the level of the ankle-joint, and well padded with cottonwool should be carried out as soon as possible. The plaster may be split up in front, so as to allow of frequent inspection of the skin, or removal of the cast to permit massage. For the first week or two the patient should be kept in complete rest, but after this he may walk on crutches with a patten under the sound foot. No weight should be borne on the affected limb for about two months after the accident, and for at least two months more the patient must not even stand on the affected leg without some form of support. When the plaster originally applied is worn out, it may be replaced by a leather support, strengthened with steel bands. At the end of eight weeks, active movements of the knee-joint may be begun, and should be persisted in until the patient is allowed to walk without any support, which in uncomplicated cases is likely to be permitted at the end of four to six months.

The frequency of dislocations of the knee-joint being complicated calls for a few remarks on the treatment of these cases. If compound, the wound must be washed out with spirituous solution of iodine, which is also applied to the surrounding skin, and is followed by the application of a sterile dry dressing. The degree of soiling of the wound and exposed joint cavity with dirt, the area of skin raised as a flap, the amount of muscular laceration, the probability of interference with the vitality of the foot, the question of serious interference with one of the large nerves, will severally influence the surgeon's decision as to amputation. It is well to bear in mind that when amputation at a later date seems probable, owing to chronic septic arthritis, a dangerous degree of infective gangrene, or a useless paralyzed leg, it is better to eliminate any risk to the patient's life, at the same time that these possibilities are avoided, by carrying out an early amputation through the thigh.

Dislocation of the Fibula.—*Dislocations of the Upper End.*—Complete dislocations of the upper end of the fibula are rare, and may be either (1) forward, probably produced by the effect of leverage when the patient has fallen with the foot bent under him and inverted; (2) posterior, said to be due to excessive contraction of the biceps; (3) upward, which may be associated with Pott's fracture of the ankle, and in any

case is due to forcible driving upward of the fibula from below. It is well to bear the last type in mind as a possible complication of ankle fractures; its presence will be detected by physical examination or by X-rays, and anatomical reposition of the parts involved in the ankle fracture will result in a reduction of this displacement, so that a tendency to recurrence may lead the surgeon to infer correctly that the associated ankle fracture is not accurately replaced.

Diagnosis.—As a rule, displacements of the upper end of the fibula are not noticed at the time of their causation, but come for treatment owing to persistence of pain, or extreme local tenderness. The head of the fibula is rarely movable from its abnormal to the normal position. Comparison of its relation to the outer tuberosity of the tibia on the affected side, with that of the sound side, will usually lead to a diagnosis, which may be confirmed by X-rays. In early cases reduction by direct pressure is easy, but owing to the flatness of the joint surfaces displacement is likely to recur, and must be prevented by continued immobilization of the leg. If the fibular head is displaced backward, recurrence from the pull of the biceps may be prevented by fixing the knee flexed to a right angle in plaster, or subcutaneous tenotomy of the biceps tendon may be necessary.

Dislocations of the Lower End of the Fibula.—These are unknown, except as part of one of the common fractures of the tibia and fibula in which the ankle-joint is involved, and of which it is a not infrequent complication.

Dislocation of the Ankle-joint.—Dislocation of the ankle-joint may be forward, backward, inward or outward (Fig. 359). All are rare without associated fracture; in fact, it is scarcely conceivable that either of the displacements in the transverse plane can occur without fracture of the malleoli, that is, of the inner malleolus with displacement inward, and of the outer malleolus with displacement outward. This is well seen in the subluxation outward with a fracture of the lower third of the fibula which is typical of the abduction variety of Pott's fracture.

Dislocation Backward.—Dislocation backward, though rare, is commoner than dislocation forward, and is likely to result when the subject falls from a height and lands on the balls of his toes. Some degree of this displacement is a common feature of Pott's fracture, and this association is not so generally recognized as is the subluxation outward to which I have previously referred. Too much importance cannot be attached to the reduction of this backward deformity in the treatment of

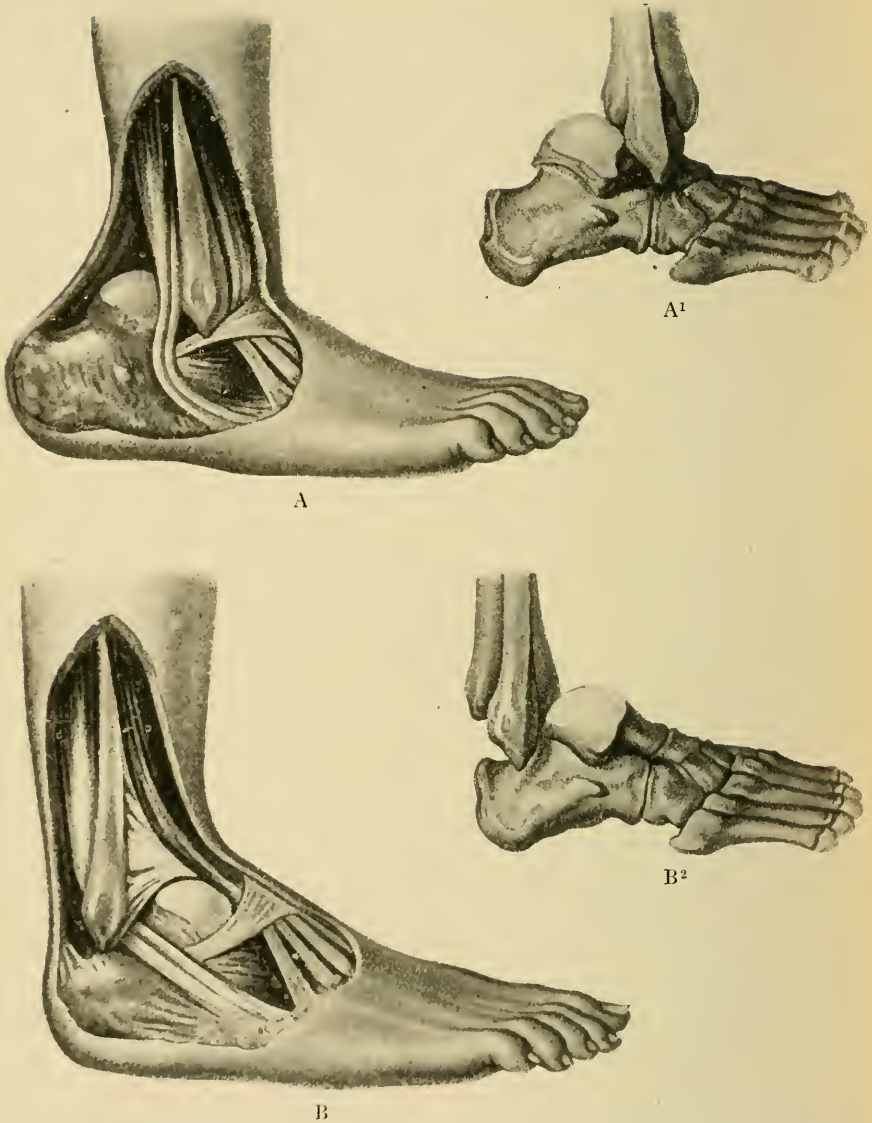

FIG. 359.—A and A¹, Specimen showing backward dislocation of the foot. The astragalus is observed behind the external malleolus, and between the two bones are the tendon of the peronei muscles. The foot is shortened, the posterior portion, corresponding to the heel, being lengthened. A¹ shows the appearance in the skeleton. B and B², specimen showing a forward dislocation of the foot. The astragalus is in front of the bones of the leg; the tendons of the peronei muscles are stretched; the foot is lengthened, the part corresponding to the heel being shortened. B² shows the condition in the skeleton. (*Helferich.*)

FIG. 360.—A, Normal epiphyseal lines at the lower end of the tibia and fibula. B^1 and B^2, Fracture of the ankle, healed with deformity, *i. e.*, severe traumatic pes planus, after a typical fracture of the ankle. Anterior and posterior views (Lohrke, male, thirty-nine years old, 1896). C^1 and C^2, Backward subluxation of the foot in typical fracture of the ankle. C^1 represents the living foot, C^2 the skeleton (Schön, male, twenty-eight years old, 1895). (*Helferich.*)

Pott's fracture, and much of the difficulty in attaining an anatomical restitution of the parts involved, and maintaining the normal relations of the joint, is due to this backward displacement of the foot, which is, in the writer's opinion, the most troublesome feature of these cases (Fig. 360).

Just as a variable degree of luxation of the ankle-joint outward is so frequently met with as to be regarded as an integral part of Pott's abduction fracture, so inward luxation at this joint is usually met with in the adduction type of Pott's fracture.[1]

Dislocation Upward.—The foot is displaced upward by separation of the tibia from the fibula, with laceration of the ligaments connecting their lower end, particularly of the interosseous ligament, in the fracture first described by Dupuytren, which bears his name.

Diagnosis.—In either displacement forward or backward, the relative length of the heel compared with the fore part of the foot is altered. In the commoner type of dislocation backward, the distance from the malleoli to the tip of the heel will be increased, and in association with this, owing to increased pull on the tendo Achillis, the heel is raised into a position of slight equinus. In the absence of lateral displacement, the exclusion of injury to the fibula or inner malleolus, thus converting the injury into a Pott's fracture, can be assured only by X-ray examination in two planes. Again, similar elongation of the heel is met with in subastragaloid dislocation, from which, in the presence of much swelling, diagnosis is difficult, and can usually be made with accuracy only after X-ray examination. The deviation of the axis of the foot inward or outward from the normal straight line of the leg will suggest some degree of luxation of the ankle-joint, which in the absence of crepitus may be supposed to be due to an uncomplicated dislocation, though many cases so regarded have been shown, on X-ray examination, to be typical Pott's fractures. The chief characteristic of Dupuytren's fracture is widening of the ankle-joint, owing to wedging of the inner or

[1] In strict accuracy, the first alone of these injuries can be called Pott's fracture. The lesion he described is due to forcible abduction of the foot by a force acting on its inner side; by this the ankle is dislocated outward, with rupture of the internal lateral ligament, and with fracture of the fibula just above the inferior tibiofibular joint, the upper end of the lower fragment of this bone being displaced inward. An exactly similar accident may result in similar lesions, except that a horizontal fracture of the inner malleolus replaces tearing of the internal lateral ligament, but this was not recognized by Pott, nor did he describe the converse, in which the foot is strongly adducted by a force applied to its outer side; here the ankle is dislocated inward, the inner malleolus is fractured obliquely, and the fibula is broken below its middle, with abduction of the upper end of the lower fragment. This in England is often spoken of as the adduction type of Pott's fracture, which term serves the useful purpose of comparison, though it is chiefly to Arbuthnot Lane that we owe our knowledge of its causation and treatment.

outer border of the articular upper surface of the astragalus between the lower articular extremities of the tibia and fibula.

Treatment.—In a large majority of cases of partial or complete luxation of the ankle-joint, the treatment of the dislocation is really the treatment of the fracture which it complicates. It is to be hoped that the writer will not be regarded as unduly laboring the point, if he insists that it is more important to treat the dislocation than the fracture. The inquiry instituted by the British Medical Association into the results of simple fractures[10] proved nothing more definitely than that the functional result depended directly upon the anatomical restitution of the parts. Accurate anatomical restitution is always a matter of difficulty in the vicinity of joints, and this is particularly true when, as in Pott's fracture, dislocation complicates the fracture. It is clear, therefore, that accurate reduction of the dislocation is an integral part of the treatment of the fracture, and in the writer's belief the most difficult and probably the most important part of it. For the reduction of all of these displacements of the ankle-joint, complete muscular relaxation under an anæsthetic is necessary; the knee is bent to a right angle, in order to relax the muscles controlling the tendo Achillis; the foot is then grasped with one hand upon the heel and the other upon the front of the foot, while counter-pressure or traction is made upon the lower part of the leg. If the foot is displaced backward, it is clear that pressure must be exerted upon the lower end of the tibia, while the heel is pulled forward, traction being at the same time maintained upon the foot, so as to allow its articular surface to pass under the prominent posterior margin of the inferior tibiofibular joint. Similarly, when the foot is displaced forward, it must be pushed backward while the ankle is extended, and the leg is pulled forward at the same time. In the absence of any fracture, the reduction of these displacements is usually easy; when, however, a portion of the articular surface is broken, the displaced fragment not only may become impacted and prevent easy reduction, but the normal adaptation of the articular surfaces is destroyed, so that recurrence of displacement is rendered easier and the maintenance of anatomical reposition is rendered impossible. For this reason, while expert X-ray examination is desirable in every case before treatment is undertaken, it is equally important to confirm the apparent restitution of the parts to their normal position by X-rays, before fixing the limb in a plaster-of-Paris casing. It has been too frequently one's experience to have to treat cases in which all the deformity has been found to have recurred after removal of the plaster at the end

of some weeks, and in most of them subsequent investigation has suggested that the reduction of the deformity has been more apparent than real. Should physical examination or investigation with X-rays show that the attempted reduction by manipulation has failed, open operation should be resorted to, as soon as the swelling and bruising due to manipulation have subsided. A second attempt at forcible reposition under an anæsthetic is unlikely to ensure a better result, and operative reduction will be less difficult the sooner it is undertaken. A free vertical incision in front of the outer malleolus will usually give good access to the joint, when, by the aid of bone elevators, the normal relation of parts may usually be restored with ease. If it is then found that the difficulties have been due to an associated fracture of the articular surface, it usually will be necessary to fix this fragment with a Lane's plate or screw, so as to prevent recurrence of the deformity.

Subastragaloid Dislocation.—The frequency with which injuries to the foot involve displacement of the astragalus is surprising, when we consider the strength and number of the ligaments anchoring this bone in position, and the complete arch enclosing the upper articular surface. Before subastragaloid dislocations of the foot can occur, the ligaments connecting the astragalus anteriorly with the scaphoid and inferiorly with the os calcis, must be torn away; of these ligaments, the strongest are probably the interosseous ligament running forward and outward in the groove separating the calcaneo-astragaloid articulations, and the fibers of the lateral ligament of the ankle, which pass from the tibia on the inner and outer side over the astragalus to their insertion in the os calcis. Cotton (*loc. supra cit.*) quotes records of Brun's Clinic which show that this is the rarest of the dislocations affecting the astragalus, but this is evidently not the opinion of Cotton himself, and the writer would suppose that, if dislocations of the ankle complicating fractures, *e.g.*, Pott's be excluded, it is commoner than simple displacements of the ankle, and is certainly more frequently met with than dislocations of the astragalus alone. Radiography has taught us that this apparent anomaly, of rupture of strong ligaments, does not take place so often as supposed, for in many cases it is not the ligament which gives way but the fragment of bone to which the ligament is attached. The appreciation of this fact is of value, for it influences not only the ease with which reposition is brought about, but also the physical maintenance of the normal position during the after-treatment. Either as the result of a fall from a height on to the balls of the toes, or more commonly still from a "run-over" accident, the anterior and inferior articular surfaces

of the astragalus are divorced from the concavity formed by the scaphoid and os calcis. This results in every case in the foot being driven backward, the tibia and fibula with the astragalus being carried forward (Figs. 361, 362 and 363) and the head of the astragalus will project either on the inner side of the foot, or on the outer side in front of the

Fig. 361.

sinus pedis, in accordance with the direction of the damaging force; in the first case, the foot will be everted, and appear unduly flat, and in the second the foot will be inverted, and may occupy a marked position of talipes varus.

Physical Signs.—The heel is drawn up, leading to pointing of the

toes; the distance from the malleoli to the tip of the heel is increased, and the foot is usually inverted or everted; in most cases a hard, prominent swelling is felt under the skin in front of the ankle, and this is easily recognized as the head of the astragalus. In the case from which the accompanying X-rays were taken (Fig. 361), pressure from the head of

Fig. 362.

the astragalus led to necrosis of the skin. Persistence of the normal relation of the malleoli to the astragalus reveals the diagnosis, and eliminates either dislocation of the ankle or of the astragalus alone. The association of afracture of the tibia and fibula may be usually eliminated by manipulation, but in the presence of much bruising or

swelling, or in a fat subject, it is difficult to be certain of the exact bony relations, or of the absence of a fracture, except after consideration of X-ray photographs taken both in the antero-posterior and transverse planes. If the foot be everted, the chief difficulty in diagnosis will be from the abduction type of Pott's fracture, and if inverted, from the adduction type; in the latter type of subastragaloid dislocation, the outer malleolus will be unduly prominent, and in the former the inner malleolus, and these, in either case, can in the absence of swelling be palpated and proved to be intact. It is of some diagnostic value that passive movements of the ankle-joint may in most cases be obtained, though dorsi-flexion is limited to some extent by the increased leverage obtained by the muscles controlling the tendo Achillis.

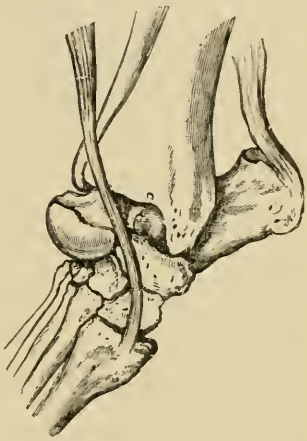

FIG. 363.—Subastragaloid dislocation of the foot backwards. (*Treves after Pick.*)

Treatment.—The diagnosis having been confirmed by X-ray photographs, reduction by manipulation under an anæsthetic should be undertaken as soon as possible (Figs. 364 and 365). Exactly the same methods which have been suggested for the treatment of dislocation of the ankle will here suffice, but it is probable that they will avail even less frequently than in the case of the ankle, for in spite of the views expressed in most text-books, the writer is of opinion that manipulative reduction of subastragaloid dislocations is the exception and not the rule. If this fail, open operation has to be undertaken, if other circumstances allow of it; it is well to postpone operative interference until the swelling and bruising of the foot have, as far as possible, subsided, but it must be borne in mind that much of the swelling may be due to interference with the circulation owing to the displacement, and that, therefore, it is not likely to subside until the displacement is reduced; and again, that persistence of pressure on the skin from the displaced head of the astragalus is likely to lead to necrosis, particularly if the skin has been further injured by one or more attempts at reduction. For this reason, operation may be hastened, as incision of the skin, and the relief of stretching by the pressure of the bone on its deep aspect, may save some weeks of convalescence by avoidance of sloughing. The writer has no doubt that, while operative interference is more frequently undertaken than for-

merly, it may with benefit be even more commonly used, for the ultimate result of such displacement depends largely on the use of massage and gentle movements, and these can be employed at an earlier date after

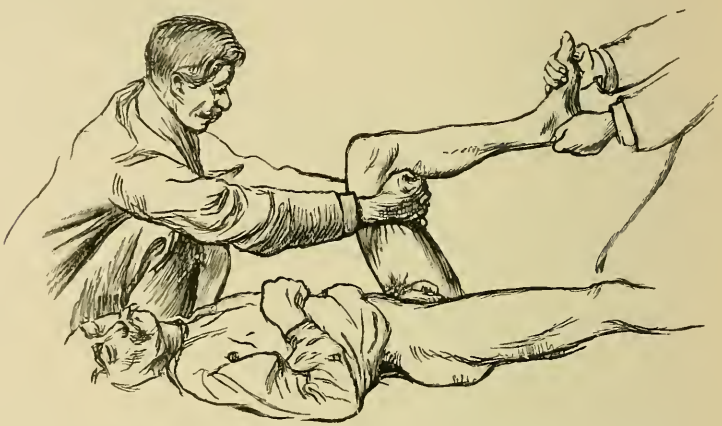

FIG. 364.—Manipulations for dislocation of the ankle. (*Treves.*)

an aseptic incision than if reduction has been brought about by repeated and forceful manipulation. The accompanying X-rays are typical of this injury, in that they show the fractures of the adjacent bones which

FIG. 365.—Pressing the tibia backwards and pulling upon the foot, in subastragaloid dislocation backwards. (*Treves.*)

are commonly associated with it, and the frequency of which has only been appreciated by the experience of radiography. Surgeons of much experience with these injuries agree that the fractures mentioned are

relatively common, and in the writer's experience they are of importance as being a most important factor in preventing manipulative reduction, and also in some cases in preventing the maintenance of the normal positions. It is exceedingly likely that manipulative reduction will crush these fragments, and as their maintenance must be of importance in obtaining a good functional result, their presence is an additional indication for operative interference. In the writer's case, manipulative reduction under an anæsthetic had been attempted on two occasions. Necrosis of the skin over the inner side of the foot, where the head of the astragalus pressed against it, was imminent; and open incision, with free exposure of the head of the astragalus allowed of reduction only with difficulty, after the apparently impacted fragments of bone had been levered out of the way.

When, as is fairly common in "run-over" injuries of the foot, this displacement is compound, operative interference will be called for as soon as the risk of acute septic infection has passed, and the wound is beginning to granulate. During this period, it should be frequently disinfected with spirituous solution of iodine, and covered with a sterile dressing. After operative reduction of a subastragaloid dislocation, the patient should not be allowed to bear any weight upon the foot for six weeks, and during this time it should be encased in plaster, which has to be removed daily for massage. If, as is probable, particularly in that variety where the foot is displaced outward and backward, some weakness of the arch of the foot results, owing to extensive laceration of the inferior calcaneo-navicular ligament, the possibility of a traumatic talipes valgus may be obviated by thickening the inner side of the sole of the patient's boot, and by the use of an additional support to the instep.

Individual Dislocation of the Tarsal Bones.—As a result of torsion associated with "run-over" accidents, it appears that displacement of any of the individual bones of the tarsus is possible, as isolated cases are recorded of luxations of the cuboid, cuneiforms and astragalus. The last alone is sufficiently frequent to merit a few words; it may be displaced backward, forward, inward, or outward, and the injury is peculiarly frequently compound. If complete, the convex saddle-shaped upper articular surface of the astragalus may be felt in an abnormal position. The malleoli maintain their normal relation to the foot and to the leg, and an X-ray picture will at once exclude a subastragaloid dislocation, with which this injury is likely to be confused. Reduction can, as a rule, be affected only by open incision, and in the majority of

cases it is better to remove part or the whole of the astragalus than to replace it, if doing so entails possible injury to the soft parts.

Dislocation of the Tarso-metatarsal Joints.—Dorsal displacement of the base of one, or the bases of all the metatarsal bones, is not an uncommon result of a fall on to the ball of the toes from a height; but partial luxation may result from much slighter injuries, such as stepping off a curb. Here the diagnosis of some abnormality in the region of the tarsometatarsal joints is rendered easy owing to the projection on the dorsum of the foot of the base or bases of the affected metatarsal or metatarsals. When luxation is complete, the associated tenderness and pain may prevent such an examination as would allow of the elimination of a fracture, owing to absence of crepitus, but the doubt will at once be cleared up by X-ray examination. It is much more difficult to decide whether a partial dislocation may be present, when pain and tenderness with very little bony deformity result from an accident, because some projection of the bases of the metatarsals upon the dorsum of the foot is not an uncommon anatomical abnormality, and these projections are likely to be bruised and rendered tender by any accident. X-ray examination both of the affected and of the sound foot will, as a rule, clear up this question.

Treatment.—Reduction of a tarsometatarsal dorsal displacement may, as a rule, be easily brought about by traction of the toe, with pressure over the base of the metatarsal. When replacement has been obtained, the deformity does not tend to recur, and after a few weeks' rest no unsatisfactory after-results are to be anticipated. When the whole metatarsus is displaced dorsally, a longer convalescence is likely to be necessary; but this is due rather to the associated bruising, and the rupture of ligaments, than to the bony displacement; in this case, it is well to put the foot up in plaster of Paris, and to allow no weight to be borne on it for at least four weeks.

REFERENCES

[1] Kronlein: Deutsche Chir. Lief, 26, p. 5.

[2] Morris: Med. Chir. Trans., 1892.

[3] Bigelow: Mechanism of Dislocation and Fracture of Hip, Philadelphia, 1869.

[4] Astley Cooper: Treatise on Dislocations and on Fractures of the Joints, 1824, p. 32.

[5] Shenton: Disease in Bone and Its Detection by the X-rays, p. 42.

[6] Robert Jones: On Fractures in the Neighborhood of Joints, Proc. Roy. Soc. Med., 1911, IV, Surg. Sect., 5.

[7] Stimson: Treatise on Fractures and Dislocations, 7th Ed., p. 815.

[8] Id.: New York Med. Jrnl., August, 1899.
[9] Rose and Carless: Manual of Surgery, 1905, p. 641.
[10] Brit. Med. Jrnl., Nov. 30, 1912, p. 1505.

DERANGEMENTS OF THE CARTILAGES OF THE KNEE-JOINT

Internal Derangement of the Knee-joint.—The symptom-complex, which is now regarded as indicative of injury to a semilunar cartilage, was first accurately described in its clinical aspect by Hey[1] in 1803 in his classical paper, "Practical Observations in Surgery." As Howard Marsh [2] points out, "The name was a good one; for without involving any theory as to the manner in which the condition was produced, it served as a clear heading for the group of cases. It exactly conveys what can be seen, and what the patients themselves describe, namely, that something has occurred in the joint which has reduced it to a condition that may be compared to that of a hampered lock, or, as some have said, to a gate with a stone in its hinge." It was not till many years later, when exploration of this joint by open incision became practicable, that this condition came to be closely identified with a lesion of the semilunar cartilages; and it is only quite recently that most surgeons with wide experience of this injury have realized that the term "detachment of the semilunar cartilage" must give place to "torn semilunar cartilage;" in other words, the idea that the semilunar cartilage might be detached, either from one of the fibrous bodies at its extremities, or in some part of its circumference, from the coronary ligament, cannot be upheld by operative findings, and in all, or nearly all, of such cases the initial lesion is found to be a tear in the substance of the cartilage, some part of its outer thick border retaining its normal circumferential attachment. In a very complete, and—because it relates a personal experience—most instructive paper by Albert M. Martin,[3] the author shows that in a series of 449 cases, 95.5 per cent. show definite splits or tears. The writer's smaller experience absolutely bears this out, and while, as will be shown later, several varieties of lacerations exist, it seems to him that all such terms as "loose cartilage" must be discarded as inaccurate, and that cases in which no definite tear can be identified, after free exposure of the knee-joint must be regarded as diagnostic errors. On the first examination of a patient suffering from a recent initial injury to the knee, it is often difficult, and even impossible, to allocate the disability to a torn cartilage; for a simple traumatic synovitis, the wedging of an enlarged synovial fringe, or of a loose body, between the articular surfaces, or the displacement of a popliteus ten-

don, will produce the pain and swelling of the joint, which are the initial symptoms of tearing the cartilage. At the same time, the subsequent history of the case, if carefully considered, will almost always lead to a right diagnosis. Rutherford Morison[4] stated his belief that in every case with a certain definite history, rupture of a semilunar cartilage had occurred; and in his most recent article[5] on this subject, he finds that increased experience has not led him to depart from this viewpoint.

Much discussion has recently taken place over the question as to the position of the limb, in which tearing of the cartilage is likely to take place. It has been the common belief that injury of the internal semilunar is most likely to occur when the knee is flexed, with the leg abducted, and rotated outward. There is a large volume of clinical evidence to support this view, such as the cases recorded by Rutherford Morison and Martin, from the Newcastle Royal Infirmary in which the large majority of patients were coal miners, working, as is the custom in the low seams of the Tyneside mines, in the sitting[1] or kneeling positions. When, as usually met with in London, injury of the internal semilunar occurs in playing a game, such as football, it is common to obtain the history that the patient, while standing on one leg, attempted to dodge or turn suddenly, when the accident to the knee occurred. Walton[6] records an anatomical investigation of the knee-joint, from which he argues that injury or displacement of the semilunar cartilage is brought about by full extension. He appears to the writer to properly insist upon one point, which is that rotation is the all-important factor in the production of this lesion, and, arguing that rotation normally takes place as extension is completed, he is of opinion that it is in this position that injury of the semilunar cartilage is mechanically likely to occur. It seems to the writer that the crux of the whole question is not whether the knee-joint is flexed or extended at the moment, but that there should be a forcible, perhaps extreme, rotation, of the inner condyle of the femur upon the internal tuberosity of the tibia, and that the concave thin border of the cartilage is thereby nipped between these two bony parts, while the convex circumference is being stretched, and therefore drawn away from the bone owing to its peripheral attachment to the capsule. It seems here, as in attempting to solve many other surgical problems, unwise to overthrow a large quantity of clinical evidence, accumulated by different surgeons, for the sake of experimental investigations on the cadaver.

[1] The majority working on the face of the seam sit with the buttocks resting on the right heel with both knees fully flexed. After a torn semilunar they usually give a history of a fall of coal on to the outer side of the knee-joint.

Further, there is no doubt that when this injury takes place in men participating in field sports, when the greater part of their weight is borne on one leg, with the foot flexed and the femur rotating inward at the time of the accident, there is commonly, with the knee in a variable position of flexion, an effort to extend the joint. The vertical capacity of the joint is greater in the flexed than in the extended position, owing to the flattening of the posterior part of the femoral condyle; mobility of the semilunar cartilages and rotatory movements of the femur on the tibia are, therefore, more likely and of greater extent with the knee flexed. Again, in flexion all parts of the circumference of the semilunar cartilages tend, owing to natural elasticity, to slide toward the center of the knee-joint. Having got into this position, the sudden effort at extension draws each cartilage toward the circumference of the joint, the pull being greater on the inner than on the outer, owing to the greater strength of its ligamentous attachments. One must assume that some portion of the thin free edge of the internal semilunar is pinned between the two bony surfaces, owing to excessive twisting, and that, as the circumference is dragged centrifugally by the antero-lateral parts of the capsule rendered taut by the sudden effort of extension, a tear of the cartilage takes place. The writer's effort to explain the occurrence of this lesion in teaching students has been on these lines, and seems best to fit in with the history of the class of case of which he has personal experience. Mr. Walton's hypothesis, that fracture takes place in complete extension, is a very different one, and appears to the writer to be quite untenable. It would seem, too, that the question of the rotation or twisting of the articular surfaces taking part in the knee-joint is probably the factor which determines the overwhelming proportion of injuries of the internal, as compared with the external semilunar cartilage. It has been sought to explain this marked difference (Martin in his series gave 92 per cent. injuries to the internal semilunar and only 8 per cent. those of the external semilunar) on anatomical grounds, by the suggestion that the firm attachment, throughout its whole circumference, of the internal semilunar to the capsule and to the internal lateral ligament, renders this structure less capable of being drawn into the joint without injury, when nipped, than is the case with the external semilunar, which, it will be remembered, is not attached to the capsule posteriorly where the popliteus tendon lies in contact with it, and has no attachment to the external lateral ligament. Martin upholds this view, having been led to give up, as the explanation of the prevalence of the injury to the internal semilunar

cartilage, the suggestion that in the accident the femur was rotated inward and the joint surfaces were separated on the inner side of the knee, because he has found that many patients assert that in the accident the knee was twisted outward. The writer's experience has been that, in the usual form of accident, with the foot fixed, the tibia is rotated outward, and therefore the femur inward. It would appear to him that this rotation at the knee-joint, about a vertical axis passing through the internal condyle, is a more important factor than any anatomical difference between the semilunar attachments, but he would agree that it is extremely difficult to place reliance upon the description of an accident given by a patient of the hospital class; so the difference of opinion upon this question must continue to exist. Denton[7] says it is common in Anglo-Saxons given to games, particularly football. Mayo Robson in a very early description of cases spoke of the condition as miner's knee. This accident, comparatively common in men during the active game-playing period of life (15 to 30), is rare in women, and according to Martin is more often met with on the right than on the left side.

Symptoms.—In many cases, the history of the injury, as Rutherford Morison has already been quoted as saying, is quite definite, viz.:

1. An injury of the knee-joint resulting from a force acting on the front or inner side of the foot. In the writer's experience this force has always been severe, *i.e.*, sufficient to be recollected, and the pain following it has been considerable. This is not due to the tearing of the cartilage, but to ligamentous injury or stretching.

2. Subsequent swelling of the knee-joint, owing to protective effusion of synovia as the result of the injury.

3. Locking. By locking is meant the abrupt painful checking of movement in one direction, while movement in the opposite direction is free and painless. It is commonly found that completion of extension is interfered with, and this is probably due to the common situation of the injury to the cartilage, *i.e.*, the anterior part. It is exceptional to find locking in flexion, and very rarely the joint is fixed owing to interference in both directions. In order for this to come about, one must suppose that the strip of cartilage hanging loose in the joint is sufficiently long to become nipped between the bones, both in flexion and in extension. By some, locking is regarded as pathognomonic of injury to the semilunar cartilages, but in the writer's experience this is not so. It has been found to be rare at the time of the initial accident, and, if the explanation of its causation is accurate, may clearly be caused by interference of the movements of the joint from other loose bodies.

4. By far the most important feature in the diagnosis of injury to the semilunar cartilage is the history of recurrence. These subsequent attacks of disability to the knee-joint may result from a mild trauma quite insufficient to produce the initial injury, such as catching the foot in the carpet, walking over rough ground, or slipping downstairs. The majority are characterized by swelling and some pain in the joint; in others, locking occurs; and when this has once happened, subsequent attacks are likely to have the same features. The pain is not due to pressure on the cartilage which is insensitive, but to stretching of the ligaments by the cartilage wedging the articular surfaces apart. Rutherford Morison draws attention to the fact that these attacks alternate with intervals of complete freedom[1] from all disability. Their causation may be best explained by supposing that the free end of the strip which has resulted from the initial injury has, by a second slighter accident, become displaced, and so probably interferes with the normal movements of the joint. Thus it comes about that these secondary attacks commonly result in locking of the joint. The nature of the first attack is laceration of the cartilage; the nature of all secondary attacks is displacement of the pedunculated strip and its impaction between the two articular surfaces.

Nature of the Injury to the Semilunar Cartilage.—All writers who have large personal experience of the operative findings in these cases (provided that the incision is adequate for reasonable inspection of the joint) agree that the commonest lesion is a tear of the cartilage. The view that the cartilage was bodily displaced or detached cannot be upheld. The majority of injuries affect the anterior half of the internal semilunar and are of the nature of a radial tear passing from the free border perhaps halfway toward the circumference, and from the outer end of this a longitudinal slit extends backward, running parallel with the outer border so that a flap is formed which has its base backward. If the posterior half of the cartilage is injured, the base of the flap is usually forward. Single or multiple radial tears, or isolated longitudinal tears, running for a variable distance parallel with the free border, are less commonly met with. When the inner margin of the cartilage, owing to an extensive longitudinal tear, is detached circumferentially, but retains its anterior and posterior connections, it may be displaced in secondary attacks so as to lie in the intercondylar notch, that is, be displaced outward in the case of the internal semilunar; and

[1] This is not the case often with "bucket-handle fractures." A recent typical bucket-handle fracture of the writer's showed no intervals of relief from attacks, for this reason the diagnosis of others was doubted until the joint was opened.

locking, sometimes both in extension and flexion, is characteristic of these cases. This variety, named by Rutherford Morison (*loc. supra cit.*) "bucket-handle rupture," is liable to be overlooked at operation unless

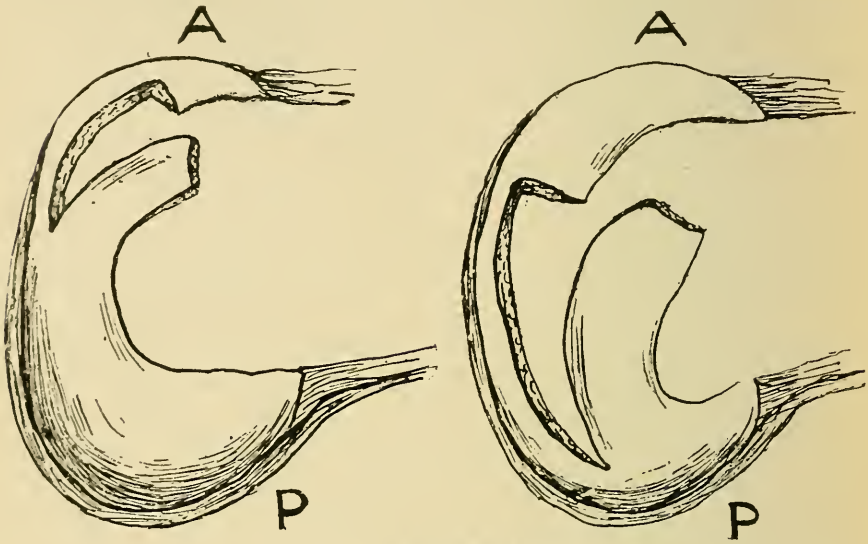

FIG. 366.—(*Rutherford Morison.*)

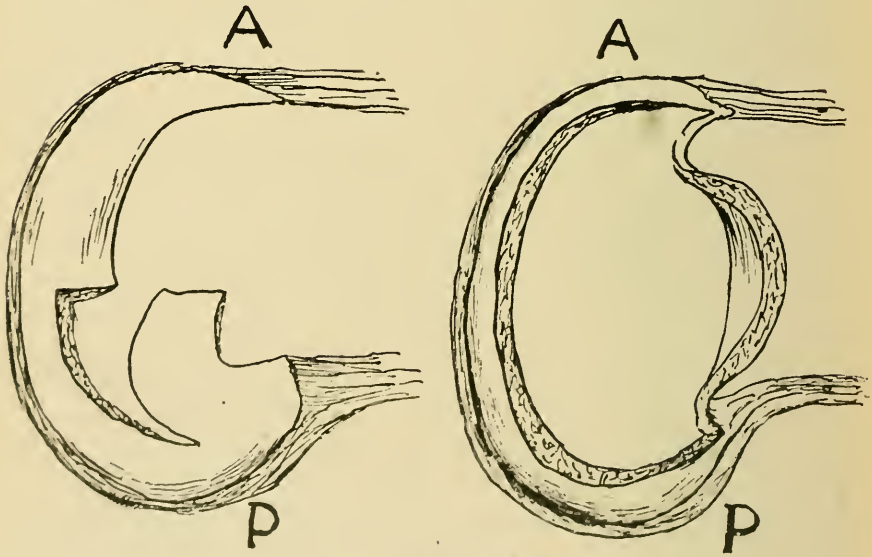

FIG. 367.—(*Rutherford Morison.*)

the intercondylar space is examined. Blood clot deposited upon the torn edges of the cartilage produces tags; partially detached flaps of

cartilage become distorted by friction or pressure, and thickened by inflammation; occasionally such a flap may become completely detached, and produce one of the varieties of loose body in the knee-joint. General experience shows that detachment of the extremities of the cartilages from their fibrous horns is unusual, though in a series of 52 cases at the London Hospital, Walton (*loc. supra cit.*) records it as the commonest type of lesion. Writing in 1899, Robert Jones[8] from anatomical evidence brought forward by Griffiths[9] was of opinion that displacement or fracture of the internal semilunar cartilage can only take place when the internal lateral ligament is stretched or ruptured. This opinion was no doubt based upon the idea of complete circumferential detachment of the cartilage. More recent clinical experience, obtained by those who operate through a transverse incision, has failed to demonstrate any evidence of injury to the internal lateral ligament.

Injury of the External Semilunar Cartilage.—It has been pointed out above that, in a very large majority of cases, the internal semilunar is the cartilage affected. It is stated by some writers that rotation inward of the tibia at the time of the accident is likely to result in injury to the external semilunar, though this seems to the writer doubtful, as Martin found that many patients with torn internal semilunar cartilages gave a history suggesting this rotation of the knee; and again, it is probable that few surgeons have sufficient personal experience of torn external semilunar cartilages to enable them to delineate an accurate clinical picture of the production of the injury. At one time the writer met with a series of some half dozen injured external semilunar cartilages, and was by them led to suppose that the injury was commoner than generally described, but since then only one further case has been met with, and consideration of the history of these cases would not suggest any very definite grounds for the belief that injury of either the internal or external semilunar is likely to result from any particular type of accident. When present, a tender spot is usually situated over the affected cartilage. Again, the patient may help by locating the interference to his joint to the inner or outer side of the articulation, but the practical inference to be drawn from this difficulty of exactly localizing the affected cartilage is, when in doubt, to assume that the internal semilunar is the one affected, because such injury is much the commoner, and so to plan the incision that this cartilage may be first of all explored. Should this be found healthy, a second incision over the external semilunar can do no harm, as the initial incision can only in exceptional cases give adequate access for removal of the external cartilage. The writer has

recently met with an interesting series of four or five cases, all occurring in children, which may be labelled "genou à ressort" (snapping knee), in all of which there was a painless, audible derangement of the knee-joint, due to displacement of the external semilunar cartilage in the region of the popliteus tendon, and its subsequent impaction between the articular surfaces. Robert Jones[10] refers to this condition as trigger-knee and says "it is ascribed to the external semilunar." One of this series came into the writer's hands for treatment, and caused considerable doubt as to exact diagnosis until attention was drawn to the operative findings in other similar cases. In this case a girl of 12, without any antecedent history of injury presented herself for investigation on account of an audible click in the right knee. All movements were complete and painless; either active or passive extension resulted in a loud clicking sound, when the movement was nearly completed. Similarly, flexion caused a similar sound soon after it had begun; at the moment of its production, the joint seemed to "stagger," yet the hand placed over it failed, on repeated occasions, to detect any sensation of dislodgment of a loose body. The audible and palpable sensation was clearly located to the outer side of the joint, and this was accordingly explored by a free vertical incision. The anterior half of the external semilunar was normal, but when this had been detached and forcible traction was made upon it the posterior convex border (over about the extent where it normally lies in contact with the popliteus tendon) could be drawn forward between the articular surfaces, with the production of a similar sensation and noise as had been experienced when the patient moved the joint. The cartilage was divided as far beyond the detached part as possible and was thus almost completely removed. Recovery was uneventful, and subsequent examination has shown that the patient has been completely relieved of her disability. Similar cases have been recorded by Howard Marsh.[11] In two of these, which occurred in children, it is not clear which cartilage was affected, and in the third, recorded by Lucas,[12] a similar condition, affecting the external semilunar cartilage, occurred in a laborer of 21.

Physical Examination.—If the patient's knee is examined immediately, or shortly after the initial or one of the secondary accidents, the joint outline will usually be obscured by synovial effusion; the lateral patellar sulci will be filled up; the joint will be held semiflexed, and both extension and flexion will usually be resisted. At this stage ill-defined tenderness is usually met with over the whole joint. When the effusion has subsided, a tender spot may be discovered on pressure to the inner

side of the ligamentum patellæ, but the patient often complains of tenderness on both sides of this ligament. In the writer's belief there is some degree of fallacy in assuming that this local tenderness indicates a subjacent injured cartilage, for, as has above been pointed out, it is very doubtful whether such cartilages are sensitive to painful stimuli. Again, if the nature of the lesion described above is accurate, it is unlikely that any partially detached tag will be sufficiently superficial to be felt. The teaching that, in certain positions of the joint, the free anterior end of the internal semilunar can be felt, has been largely given up, so that physical examination, in the intervals between the attacks, tells us little, and diagnosis chiefly depends upon the history.

Differential Diagnosis.—A history of injury to the knee of a young male adult will often arouse a suspicion of injury of a semilunar cartilage. In the majority of cases the suspicion will prove unfounded, for after adequate rest and support the effusion into the joint will disappear, complete mobility will be recovered, and subsequent attacks will not be met. Too much stress cannot be laid upon the conviction of Rutherford Morison, that a certain precise history is pathognomonic of injury to a cartilage; in addition it may be suggested that occasionally a disability of the knee-joint somewhat short of what has been written above, may be due to a tear in a cartilage. Thus, a young man, much addicted to football, gave a history of twisting his knee, and falling to the ground, but after a rest continued playing till the end of the game. Subsequently any turning movement caused the trouble to recur. "What was out" could be put back by traction by his fellowplayers, and he would continue the game to the end. This happened continually during two seasons, after which he was examined by the writer, who, feeling that a localized injury to a semilunar cartilage was the probable cause of the mischief, advised exploration of the knee-joint.

Other cases of this kind may be quoted, and those who have large experience of this injury will no doubt recall similar cases in which both the initial injury and the remainders were comparatively trivial. In elderly workingmen, chronic traumatic osteoarthritis is the condition with which most difficulty is encountered in differential diagnosis. Particularly is this true of that form of arthritis in which the synovial membrane is the part chiefly affected. Here each normal synovial fringe is enlarged and thickened, and in many cases one of these fringes may be palpable on the inner side of the joint, when it is mistaken for a displaced cartilage. Here the history of injury will be present, with subsequent disability and pain. In the absence of a history of similar

trouble in other joints, it will often be difficult to determine that the arthritis is not secondary to a torn cartilage. The age of the patient, the presence of arthritic changes in other joints, the continuous character of the disability rather than the intermittence which is so characteristic of an injured cartilage, and the presence of lipping of the articular margins will usually lead to an accurate diagnosis, but there is no doubt that occasionally osteoarthritic joints are explored on a wrong diagnosis, with unsatisfactory results in the majority of cases, though rarely a temporary benefit may result from removal of any villous fringes which mechanically interfere with the movement of the joint. Recurrent effusions into the knee, such as are met with in congenital syphilis or in hemophilia, will not give rise to any difficulty if the question of traumatism is investigated, and if no knee-joint is explored until the probability of a cartilage being injured can be fairly established. In the majority of cases an X-ray examination has been undertaken before operating, but the evidence obtained is purely negative, and serves only to exclude the presence of loose bodies containing osseous nodules.

Treatment.—During an acute attack, whether this is the result of the initial or of a subsequent injury, the first point to determine is whether the displaced portion of the cartilage is still impacted between the two bones. This is determined by the ability to extend the knee to the full extent. If this is impossible, an effort is made without, and subsequently if required, with, an anæsthetic. The manipulations, which will generally result in disimpaction of the cartilage, are flexion of the affected knee to or beyond the right angle; the leg is then pulled away from the patient's trunk, counter-extension being applied by an assistant to the thigh, so as to maintain the knee-joint flexed. By this means the articular surfaces are separated as widely as possible so that the cartilage may fall away from between them. To help this, rotation inward of the tibia will usually be of assistance, though Howard Marsh recommends that the leg be rotated both inward and outward. The leg is then quickly extended, and it will usually be found that the knee can be completely straightened, and often the replacement of the cartilage will be indicated by an audible click, or by the sensation of something moving under the operator's hand. In all cases, treatment of the acute synovitis, which is the usual sequela of the initial and subsequent injuries, should be undertaken at the earlier possible moment. The limb is placed at rest, amply surrounded with wool, and a wide Domette bandage applied firmly. The object of this is to limit synovial effusion, and slight congestion of the leg and foot, with some

œdema, need not be looked upon as undesirable, provided it does not produce appreciable discomfort. The application of a straightback splint to the distended joint is generally unnecessary, if the patient rests the limb in bed, and movements are controlled with sandbags. Further the position of full extension is, with a much distended joint, not the most comfortable, and it will be no disadvantage to the success of treatment if the patient is allowed to lie on either side, with the joint slightly flexed. Synovial exudation will usually continue to be poured out for 12 to 24 hours, but if the joint is firmly bound up in the way suggested, the effusion may be inhibited. When after two or three days, it is considered that effusion is no longer continuing, its absorption must be attempted. This is best carried out by daily massage, and after a week gentle passive movements may be begun.

It does not appear to the writer that the absorption of the fluid is in any way expedited by painting the affected joint with iodine. If the case is not brought under treatment until the joint is distended with fluid, the application of an ice-bag or of hot fomentations will tend to relieve the pain. In the more severe cases the patient will be able to use the limb at the end of a fortnight and to walk freely three weeks after the accident, and after slighter injuries the disability will only last a few days.

Prevention of Recurrence.—Many cases diagnosed as injury of the internal semilunar have no more trouble after one serious attack; yet it is difficult to believe that sound healing can take place in a torn cartilage. If it does occur it must be exceptional, and in the writer's opinion it is useless to formulate treatment so as to allow this to come about. It seems probable that in these cases in which recovery is complete a mistaken diagnosis has been made, and that if a cartilage is really torn, the initial attack is only the beginning of repeated disability. In those who earn their living in active employment, or who wish to enjoy more than a most limited amount of recreation, once the diagnosis of torn semilunar cartilage has been made, operation offers the only cure. For those whom age, or constitutional disease, or choice debar from operation, the wearing of a knee support may be recommended;[1] yet, as operation for removal of a semilunar cartilage is rare after 40 years of age, and may with impunity be undertaken under spinal anæsthesia in those who, from any of the above reasons, are unsuitable for a general

[1] The best appliance for the purpose is probably that devised by Howard Marsh, in which two leather collars surrounding the thigh and leg are connected by lateral longitudinal steel bars hinged at the knee-joint. Free flexion and extension are permitted, but it is planned so as to limit rotatory movements.

anæsthetic, it will be seen that, in the writer's opinion, when once a definite diagnosis of displacement of a torn cartilage has been made, there are very few cases indeed in which operation is not indicated.

Operation.—Over night the affected limb is cleansed with ether soap, shaved, purified with alcohol and ether, and painted with iodine in spirit 3 per cent., from the top of the thigh to the ankle-joint. The limb is then covered with sterilized dry lint, and bandaged. When the patient is anæsthetized the dressing is removed, and iodine again applied. At this stage a tourniquet may be applied to the thigh so as to prevent bleeding during the operation; it is removed after the dressing has been firmly bandaged on. Access to the affected semilunar is obtained by a vertical, horizontal or curved incision. Martin (*loc. supra cit.*) incises the capsule and synovial membrane horizontally immediately above the cartilage. Barker[13] advocates a horizontal incision through the coronary ligament, so opening the joint below the semilunar; the capsule is exposed by a curved skin incision. He advises and evidently practises removal of the whole cartilage. Rutherford Morison (*loc. supra cit.*) employs a free vertical incision on the inner side of the patella; as the knee is kept fully flexed during the operation, this affords excellent access to the anterior part of the joint cavity. The writer has been accustomed to employ a similar vertical incision, and has convinced himself that one of the chief requirements of such an incision must be that it shall be long enough to enable the operator to distinguish clearly what is the factor in the joint that is at fault. Good surgery will not be done, nor will surgical science be advanced, by the removal of part of an internal semilunar cartilage, whether abnormal or not, through a buttonhole incision, however high the level of operative dexterity may be which allows this to be done.

If a vertical incision is used, it should lie parallel to and on the inner side of the ligamentum patellæ, and pass upward within ½ in. of the inner border of the patella; it should extend upward to above the level of the upper border of the patella, and downward over the internal tuberosity of the tibia. If a horizontal incision is made use of, it will lie at the level of the lower border of the patella, and has to be carried inward from over the ligamentum patellæ to the internal lateral ligament. As it is deepened, the inner border of the ligamentum patellæ will be exposed in front and the internal lateral ligament behind, and particular care must be taken to maintain the latter structure intact.

By whatever means the skin is divided, its edges and the exposed skin surface are at once excluded from the wound by sterilized towels

held in position with clips or Lane's tissue forceps; it is also well to discard the knife which has been used for the skin incision. The incision is now deepened by dividing vertically the fibrous layers on the inner side of the patella; two may be distinguished, the more superficial and thinner being part of the deep fascia of the thigh, the deeper, the expansion derived from the vastus internus, forming the collateral patellar ligament. Between this layer and the synovial membrane will be found some loose connective tissue and fat, and in this layer are met the chief vessels which demand ligation or torsion; there is particularly one branch which is derived from the internal inferior articular artery, which runs horizontally outward just above the internal tuberosity of the tibia. When any bleeding points have been secured, the synovial membrane is freely incised vertically so as to expose the whole of the internal condyle of the femur and the space below in which the internal semilunar lies. If the margins of the wound be well retracted, almost the anterior half of the internal semilunar will now be exposed; its inner edge may be caught hold of with a small blunt hook and by forcible traction a tear or other lesion of its inner free sharp margin may be exposed. If such a cause for the joint trouble is found, the cartilage is detached from its anterior horn, and from its circumferential attachment to the capsule, with a pair of sharp pointed scissors or a tenotome. The part removed must of course include the torn flap, and as in most cases this will be situated well within the anterior half of the cartilage, it will be sufficient usually to excise the anterior half, which has been well exposed from the time that the synovial membrane was incised. If no lesion of the internal semilunar is obvious, it is well to extend and flex the knee-joint and, with the idea of promoting impaction of any loose fragments between the two bones, forcible traction may be exerted upon the cartilage while this is being done. This may serve to show that the lesion of the cartilage is situated in its posterior half, and when necessary the circumferential detachment of the cartilage from the capsule is carried backward until the affected part is freed and finally removed by dividing the cartilage behind the point of injury. It should be made clear that it is unnecessary to remove the whole cartilage; that provided the part injured is removed, the remaining segment of cartilage produces no further ill results; and that, even if the lesion lies well behind the internal lateral ligament, the part affected may be easily removed through a free vertical incision, provided the anterior end, as it is detached from the capsule, is pulled forcibly forward. This has been the writer's experience, and records of operations on large numbers of

cases, by Martin, Rutherford Morison and Robert Jones, do not suggest that any other means of gaining access to the point is necessary in order to deal with a lesion of the posterior part of the cartilage.

It is of course clear from what has been written that even after the anterior horn has been divided and the semilunar partially detached, no evidence of injury may be found. It is necessary then to cut off that part of the cartilage which has been freed and search the articulation for some other cause of the disability. This may be found to be a lesion of the external semilunar, and should this be so it is best to gain access to it by a second vertical incision on the outer side of the ligamentum patellæ, which is made in exactly the same way, and encounters the same structures, as has been already described on the inner side of the joint. However, cases will be met with in which careful investigation fails to find a lesion of either of the cartilages. In these it must be appreciated that a mistake in diagnosis has been made, and that the disability results from a nipped synovial fringe or a loose body. Every operator of experience has made such mistakes, and it seems to the writer that those with most experience are most willing to acknowledge the possibility of such an error. Thus, Robert Jones (*loc. supra cit.*) said in 1909: "I have opened the knee-joint over 500 times, and in spite of this perhaps unique experience, am quite prepared in cases even with classical symptoms to find my diagnosis wrong."

Later in the same paper he says: "I am quite conscious that despite any amount of care in diagnosis, error is inevitable in a number of cases, and only exploration can give us accurate information."

When first the internal semilunar is being sought for, it may be found not to occupy its usual position over the internal tuberosity. In this case, unless an extensive flap of cartilage, formed by a large piece of the anterior half of the semilunar displaced backward, is exposed on movements of the knee-joint, its displacement into the intercondylar notch must be suspected, as described above under the term "bucket handle fracture." When the affected portion of cartilage has been removed, the joint cavity is freed from clots by the gentlest possible swabbing, the edges of the synovial membrane are brought together with a continuous suture of iodized catgut, and the capsule is similarly sutured with catgut of greater thickness. The skin incision may be closed with Michel's clips, salmon gut (silkworm gut) or catgut, used either with continuous or interrupted stitches. The writer has seen no ill effects from the uniform use of a continuous salmon gut suture for the skin. After suture of the synovial layer, the Ochsner's forceps, with which the

vessels have been secured, are to be removed, when it will usually be found that the continuous pressure exerted by these for several minutes has closed the ends of the bleeding vessels. Should there be any doubt on this question, the bleeding points must be secured with catgut ligatures, or under-run by the continuous catgut suture. This is particularly necessary, as post-operative bleeding from these vessels into the joint is one of the most annoying complications which may ensue, and is in fact, at present, the only one which seriously retards the patient's convalescence. It is best dealt with by prevention, and it is at this stage in the operation that a little care in making certain that all bleeding has ceased, before the sutures are inserted, will do much to ensure the patient a brief and uninterrupted convalescence. As a matter of fact it is, in the writer's experience, very rarely necessary to ligate these vessels. From a feeling that if there is any risk of bleeding after the operation it is better to know of it and to deal with it while the wound is open, the writer is not inclined to make use of, or to recommend to others, the application of the tourniquet to control bleeding during the operation.

After-treatment.—The wound is covered with sterilized dry pads, outside of which a large quantity of cottonwool is applied. This is secured by a wide Domette bandage very firmly applied with the knee in the extended position. This bandage is purposely put on so as to maintain, with the aid of the cottonwool underneath it, firm elastic compression of the joint, and should be so firmly applied as to produce some œdema of the leg, and yet not be tight enough to cause much pain. It is not usually necessary to apply a splint, and in most cases the knee may be actively bent within the first week, and the patient allowed to walk about with a stick or crutches. After eight days the skin sutures are removed and a collodion dressing applied, but for the next five or six weeks a wide rubber bandage should maintain an even pressure over the joint, and must continue to be worn as long as there is any swelling. During this period daily massage will usually be of value, both to aid in the absorption of the effusion into the joint and to restore the tone of the quadriceps extensor muscle, which will be found to be much weakened by a period of enforced rest. It is well to take the precaution of prohibiting violent exercise for three months following the operation, and this period may have to be prolonged if the operation has been followed by much effusion into the joint.

Complications.—In only one case in the writer's personal experience has convalescence been interrupted. Here, as in other cases which the

writer has observed, the trouble was due to hemorrhage into the joint; this no doubt primarily arose from faulty hemostasis at the operation. Pain, oozing from the wound, distention of the joint, with some rise of temperature, demanded removal of the dressings during the first week, and a few days later, as the painful distention did not subside, the joint was reopened and washed out with sterile salt solution, in order to remove the blood clot; the synovial membrane and capsule were again sutured, and the patient made an uninterrupted recovery, though convalescence was prolonged owing to the necessary weakening of the capsule by the second operation. The blood clot removed from the joint, subjected to bacteriological examination, proved sterile.

Most writers in textbooks dilate upon the risk of sepsis. The writer is glad to have no personal experience of this, though even the best operators who obtained their experience in the earlier days of the surgery of the knee-joint saw instances in which it occurred, and by these their view of this risk was naturally prejudiced. At the present day, any surgeon accustomed to modern surgical technique should be as safe in undertaking such an operation as in undertaking any operation in any part of the body. While instances of infection of the knee-joint must, in large modern institutions or in the private practice of those engaged daily in operations, be so rare as to have reached the vanishing point, it is perhaps even now necessary to insist on the imperative need for strict asepsis in dealing with a large joint, and to warn those who are not accustomed to the rigid routine which this demands that they should confine their attentions to the abdomen in which so rigid a routine is not required, and should leave to others the exploration of the knee-joint which by some is so lightly undertaken. Realizing the absolute necessity of the strictest cleanliness, it is the writer's habit not to allow anything except sterile instruments and swabs to come into contact with the joint cavity. These swabs must be held in forceps; when the joint is being sponged out no swab must be used which has been touched with the gloved hand; sutures must be threaded with dissecting forceps, and not touched with the gloves; and the needle carrying the suture must be held in a needle-holder. From what has been said, it is clear that the gloved fingers are not allowed to enter the joint or touch the surface of the wound; and in these operations, as in those dealing with recent fractures, it is well to make use of artery and dissecting forceps at least 7 in. in length, so as to obviate the possibility of either the surgeon's or assistant's gloved hands coming into contact with the wound. Until the operator has become accustomed to this technique, he may

find his manipulations clumsy and the time of operation prolonged, but this will be abundantly compensated for by his freedom from anxiety and by a short and uncomplicated convalescence of the patient.

Limitation of Movements.—One of the greatest anxieties of a patient before such an operation is that it may result in permanent interference with the movements of the joint. This can result only from sepsis, and is not a sequel which need be taken into account in advising operation. The sense of weakness with limited power of flexion, which are the chief troubles of the patient from the second to the sixth week after the operation, will as a rule at the end of that time disappear under the influence of massage and movements both active and passive. As long as an elastic bandage is worn this sensation will be maintained, but after this is removed, increasing active movements will soon eliminate the sense of weakness and will increase the range of movement, which at the end of eight weeks should be absolutely complete and painless.

REFERENCES

[1] W. Hey: Practical Observations in Surgery, 1803, p. 327.
[2] Howard Marsh: Diseases of the Joints, 1910, p. 266.
[3] Albert M. Martin: Proc. Roy. Soc. Med., Vol. VI, No. 1, p. 23.
[4] Rutherford Morison: Lancet, Feb. 27, 1909.
[5] Id., Clin. Jrnl., April, 1913.
[6] Walton: Proc. Roy. Soc. Med., Surg. Sect., Oct. 8, 1912.
[7] Nouveau Traité de Chirugie, Dentu et Delbet, VI, p. 288.
[8] Robert Jones: Annals of Surgery, Dec., 1909, p. 974.
[9] Griffiths: Brit. Med. Jrnl., 1900, II, p. 1171.
[10] Robert Jones: *loc. supra cit.*, p. 989.
[11] Howard Marsh: *loc. supra cit.*, p. 276.
[12] Lucas: Brit. Med. Jrnl., 1879, II, p. 774.
[13] Barker: Derangements of the Knee-joint, Practitioner, 1909, Vol. LXXXII, p. 309.

SECTION X

TUMORS OF THE LOWER EXTREMITIES

By

EMMET RIXFORD, B.Sc., M.D., F.A.C.S.

The more frequently occurring superficial tumors, such as sebaceous cysts, lipomata, fibromata (molluscum fibrosum), fibrolipomata, etc., are found on the lower extremities as on other parts of the body, but since they present no surgical problems incident to their location, they need but little discussion here beyond the statement that they are more common in the region of the buttock, upper thigh and calf.

Fibromata and fibrolipomata are particularly frequently found in the region of the buttocks where they are often pendulous and at times attain great size (Fig. 368). They may readily be removed by simple excision. These pedunculated fibrolipomata are not to be confounded with diffuse accumulations of fat in the buttocks which are so much more marked in the female and which now and then reach proportions of deformity.

Some individuals, mostly women, also suffer from deforming local accumulations of fat beneath the skin on the outer aspects of the thighs which are often associated with similar deposits on the outer and posterior aspects of the upper arms, and the surgeon may be appealed to to remove the masses surgically. "Lipectomy" has been successfully performed on the abdomen; it is perfectly feasible here and in special cases might be justified; the operation and the resulting scar being balanced against the tumor deformity. The wound, being a large one, should be closed in such wise as to obliterate the cavity and fix the flaps to prevent them sliding about. The wound should be drained.

In one case in which the fatty masses were most annoying I removed some three pounds of fat from the outer side of each thigh by a procedure illustrated by the following sketch (Fig. 369), which respresents a cross section of the wound made.

Healing of the wound was slow, being hampered by persistent reac-

cumulation of serum beneath the large loose flaps, the result of neglect to drain the wound in the beginning.

FIG. 368.—Local accumulation of fat in Zulu wife. (*Courtesy of Surgeon General Stokes* U. S. N.)

Systematic and persistent massage is of distinct value in dissipating fatty deposits.

In adiposis dolorosa (Dercum's Disease) (Univ. M. Mag., 1888, Am. J. M. Sc., 1902) the fatty masses may be deposited symmetrically or irregularly, first, in actual lipomata (encapsulated, lobulated, fatty tumors), second, in more diffuse but still regionally localized masses; and third, in widely diffused masses constituting a condition of general obesity with pain. The fatty masses may follow the distribution of some sensory nerve and may be associated with disturbances of the thyreoid gland. The face, hands, and feet are ordinarily not affected. The affection occurs much more frequently in women and is often associated with suggillations, asthenia, psychic disturbances, etc. It is of obscure origin and is of medical rather than of surgical interest except perhaps in the first form in which removal of the offending lipomata may be undertaken for palliative purposes. The wound may be expected to be painful.

Diffuse lipomata may penetrate into the depth of the buttock between the various muscles or they may originate in the deeper fatty tissues. Particularly in the latter event is diagnosis difficult. Subcutaneous lipomata are ordinarily easily removed except in the palm, sole, middle of the back, and back of the neck where they are diffuse and are entangled in the trabeculæ of fibrous tissue connecting the skin

with the deep fascia. Diffuse lipomata involving muscle are very difficult to remove without sacrificing important structures.

As suggested above lipomata have been found in the sole and may be superficial to or may lie beneath the deep plantar fascia. Lipomata have been found in joints and even within the bones of the extremities.

Subcutaneous lipomata may be symmetrical and have been known to occur symmetrically in several members of the same family (Rinne).

True dermoid cysts do not occur on the extremities though so-called traumatic or implantation dermoids or rather epidermoids are occasionally found there, but their location is entirely fortuitous. Little need be said of their treatment for the diagnosis is apt to be made only after excision.

Sarcoma of the skin is more frequently secondary to sarcoma of the deeper tissues and especially of the internal organs but primary

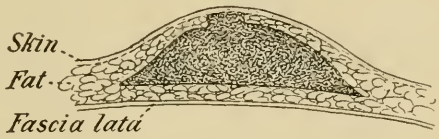

FIG. 369.

sarcoma of the skin is not rare. It occurs in several distinguishable forms and varies through the widest limits of malignancy. The pigmented sarcoma of childhood is rapidly generalized and is singularly malignant as is also the melanotic sarcoma which develops commonly in pigmented moles or nævi.

This latter tumor is considered by many pathologists to be epithelial in origin and therefore not sarcoma but carcinoma. At least it forms metastases by way of the lymphatics. The secondary tumors are apt to grow rapidly while the primary tumor remains relatively stationary. Primary melanotic sarcoma occurs with singular frequency about the nail or matrix of the nail especially of the great toe.

Particularly dangerous is a pigmented nævus (mole) if located at a point subjected to frequently repeated trauma. In a case in a man of 65 a small pigmented mole had existed since youth directly over the tendo Achillis at the level of the shoe top. Finally swelling of the glands of the groin was noticed, and soon thereafter a rapidly growing retroperitoneal tumor. Generalization soon followed. The primary tumor was not larger than a pea when the inguinal glands made a tumor the size of one's fist.

Many surgeons advise that pigmented moles be left strictly alone

because of frequent observation of the fact that sarcomatous development and generalization follow soon after excision. Certain it is that pigmented moles if excised should be removed with great care, the surgeon avoiding trauma of the mole and cutting wide of the visible tumor. But the malignancy of melanotic sarcoma is so intense that one should insist on radical removal of every pigmented mole which shows any tendency to change in size or in intensity of pigmentation. If the regional lymph-glands are enlarged or in any case in which the diagnosis of melanotic sarcoma is made and operation is undertaken, it should include excision of the regional lymphatic bearing tissues as is systematically done in carcinoma.

Fibrosarcoma of the skin is liable to follow trauma and is more common in the lower extremity than elsewhere. It is characterized by exceedingly slow growth with much atrophy in the center even to the production of a small depression below the level of the surrounding skin. Clinically it presents few of the commonly accepted characteristics of malignancy except its persistency and the fact that it is infiltrating and not encapsulated. It has little tendency to form mestastases and is readily curable by local excision.

In the seven cases in which I have excised fibrosarcoma of the skin there has been no recurrence or mestastasis and in several of the cases excision was performed more than 10 years ago.

Neuromata may occur on any nerve and be benign or malignant, single or multiple (Von Recklinghausen's disease), encapsulated or, rarely, infiltrating, isolated or diffuse (racemose).

When neuromata occur on nerves of unimportant function such as nerves of cutaneous sensibility they are best managed by simple excision, but when they occur on important motor nerves a more conservative treatment may be advisable. About 50 per cent. (Cuneo, J. de Chir., v. 3, 1909, p. 485) of isolated neuromata may be enucleated without serious detriment to the function of the nerve. In the remainder, resection with nerve suture is demanded. If the defect is too great for simple suture, some one of the various means of bridging nerve defects must be utilized—suture of the distal end into some neighboring motor nerve; suture of both ends into the side of some motor nerve, canalization; etc., etc., but the preferable treatment is to graft between the ends, portions of nerve tissue derived from some nerve of less important function.

Of particular interest in the surgery of the lower extremities is the so-called amputation neuroma. After section (or severe trauma)

of a nerve, healing takes place by granulation tissue developing into a sort of fibroma which expands the lower end of the nerve and produces a tumor which has been likened in appearance to a young onion. The axis cylinders grow out into this fibrous tissue in all directions and the cells of the sheath of Schwann multiply so that on section the traumatic neuroma presents the appearance of a fibroma filled with twisted axis cylinders, some with fibrous sheath, others with medullary sheaths.

Many procedures have been devised to prevent the formation of such neuromata after amputation—turning the nerve about and inserting its free end into the side of the trunk higher up (Bardenheuer); splitting the end and turning back the cut halves upon each other; enclosing the end of the cut nerve in a pouch of impervious fascia; etc., etc., but it is doubtful if any of these procedures is as successful in preventing subsequent pain as is the older one of drawing out the nerve from its sheath, cutting it off at a level where the neuroma which inevitably forms will bé covered with a goodly layer of protecting muscle.

The Groin.—The groin, or rather the region of the femoral triangle (trigonum subinguinale), for the "groin" properly includes the region on both sides of Poupart's ligament, presents such a variety of neoplasms and conditions characterized by tumor formation that it would seem convenient to present these lesions from the viewpoint of differential diagnosis.

Femoral hernia would ordinarily present no difficulties in diagnosis but occasionally an old adherent omental femoral hernia may be mistaken for a lipoma or more rarely a lymphangioma or even a cyst. From an operative standpoint the error is of little consequence provided the operator exercise reasonable caution in its excision guarding against omental bleeding and injury to the femoral vein.

But the hernia may be mistaken for a chronic lymphadenitis or, *vice versa*, the latter may be mistaken for the former, in which event the introduction into the peritoneum of even attenuated bacteria may set up serious peritonitis. Of course the danger is far greater when acute or subacute lymphadenitis is mistaken for a strangulated femoral hernia, and in the search for the sac fatty tissue is drawn out of the femoral canal giving the infection access to the cellular tissues. The normal peritoneum is readily drawn out with this fatty tissue making an artificial hernial sac which under the above conditions of infection may be opened with fatal result.

Luecke extirpated a cyst from the groin whose origin was an ovary contained in a femoral hernia (König). I personally undertook the excision of a tumor of the groin which proved to be the sac of an inguinal hernia filled with gelatinous material. Laparotomy showed the origin of this material to be a carcinoma of the appendix vermiformis. The patient is alive and well eight years afterward.

A very vascular sarcoma may be difficult to differentiate from a progressing femoral aneurism, the resemblance depending on the degree of inflammatory reaction present in the two cases. Both may pulsate and show signs of inflammation, such as redness, tenderness, and diffuse induration. Distensile pulsation, pain, interference with the circulation in the limbs, gradual enlargement of the pulsating tumor, history of syphilis or positive Wassermann reaction, and history of local trauma, penetrating wound, speak for aneurism. A rapidly growing vascular sarcoma not infrequently shows some rise in temperature, and, as already said, may pulsate. It is apt to be covered with dilated veins, quite as much the result of the enormously increased local blood supply, as of resistance to venous return.

Lymphangiectasis presents an elastic tumor with ill-defined borders made up of distended, contorted, thin-walled vessels of various sizes, even reaching an inch in diameter; it is slightly compressible, especially to continued pressure, but the contained fluid driven by pressure from one part of the tumor causes increased tension in other parts.

Lymphangioma makes a harder and less compressible tumor. It is encapsulated and may be movable, and on section presents the picture of a fibroma filled with irregular lymph spaces which are lined with endothelium.

Arterio-venous aneurism is practically always the consequence of direct trauma to the artery and accompanying vein, generally of the nature of gunshot or stab wounds, and may occur at any point of the vessels, but is more frequent in the thigh and groin and popliteal space. It is characterized by a relatively small tumor (this determined by the size of the so-called false aneurism present), by pulsation in the distended veins, purplish discoloration and wasting of the limb below, lowered peripheral temperature, muscular weakness and pain presumably from malnutrition of the limb.

One would think that no surgeon would require to be reminded that the Hunterian operation of proximal ligation of the artery would not cure an arterio-venous aneurism, yet I have seen a patient on whom this very operation had been performed with no very favorable result.

In fact such ligation can have no effect whatever on the aneurism though it might be of value if done several weeks prior to excision by assisting in the development of collateral circulation. Rost (Indian Med. Gaz. v. 44, 1909, p. 456) reports a case in which he successfully sutured openings in artery and vein in Hunter's canal.

Chronic lymphadenitis of the groin may require to be differentiated from carcinoma metastatic from the limb below or from the anus or scrotum or from melanoma (melanotic sarcoma) arising in a nævus or pigmented mole.

It not infrequently happens that in squamous-celled epithelioma of the leg occurring in an old varicose ulcer (Marjolin's ulcer), the femoral lymph glands will be enlarged as a result of septic absorption.

Carcinoma in the groin, secondary to carcinoma of the penis, scrotum and anus, if not removed sufficiently early is apt to invade the whole subcutaneous region of the groin with a thick brawny induration which often breaks down in the center, leaving a great gaping wound, which may have somewhat the appearance of a phagedenic ulcer.

It may also cause severe non-pitting œdema of the limb from lymphatic obstruction, and may invade the femoral or iliac vein causing venous stasis or even complete obstruction and with great potentiality for malignant embolism. Of course in such cases of secondary carcinoma of the groin when the diagnosis is established there is nothing to be done surgically beyond something palliative, because when the condition has progressed to the point indicated, metastasis has almost certainly occurred into the retroperitoneal lymph glands. In fact by reason of the obstruction to the lymphatic drainage, anastomoses have been opened up as a result of the back pressure and the carcinomatous cells have been carried through these anastomoses into the neighboring lymphatic systems, particularly in the opposite groin, the axilla, and the interior of the pelvis. Furthermore since the lymphatic anastomoses occur chiefly in the periphery, particularly the skin, and the obstruction produces an effective lymph stasis, carcinomatous cells which may be present in this slowly moving lymph stream will lodge in the skin, setting up so-called lenticular metastases which in turn will lead to diffuse carcinomatosis of the region.

At once the most terrible and the most hopeless form of tumor occurring in the groin is lymphosarcoma. It is the more heartrending in that it occurs most frequently in children (Fig. 370). A swelling appears in the groin, is painless and therefore not noticed till its size

attracts attention; it grows with great rapidity and extends in lymphomatous nodes through the subcutaneous tissues, beneath Poupart's ligament into the retroperitoneal spaces, rapidly causing venous stasis (cyanosis), enormous swelling of the limb, and forming huge retroperitoneal tumors which interfere with the function of bladder and bowels,

FIG. 370.—Congenital elephantiasis. Lymphatic œdema of right lower extremity.

and finally forming multiple metastatic lymphomata in lung, liver and spleen with rapidly progressive anæmia and death.

In the face of such a growth surgery is powerless; no case with established diagnosis having recovered or been cured by operative means.

The absence of symptoms in the beginning prevents an early diag-

nosis and radical operation, necessarily mutiliating if it is to be efficient, is not justifiable in default of a positive diagnosis. Furthermore there is no reason to suppose that a radical operation done even in the very incipiency of the disease will be effective. As in Hodgkin's disease arsenic in full doses and the X-ray and radium are of some value in retarding the progress of the affection.

Diffuse lymphangiectasis (Fig. 370) of the lower extremity, as of the upper is apt to favor the inner side of the limb and the dilated thin-walled vessels may be so superficial as to be subject to rupture on the slightest trauma giving rise to lymphorrhœa.

Great lymph cysts have occasionally been found on the inner side of the thigh—hygromata—comparable to similar collections of lymph in the region of the neck in infants and like them generally multilocular.

Excision of lymphangiectases should be undertaken only when sufficiently localized to make complete excision probably possible and then under the most rigid asepsis, for infection of lymphangiectatic tissues, while not necessarily fatal, is fraught with very great danger because of the ready access of bacteria to the interior of the body afforded by the dilated vessels.

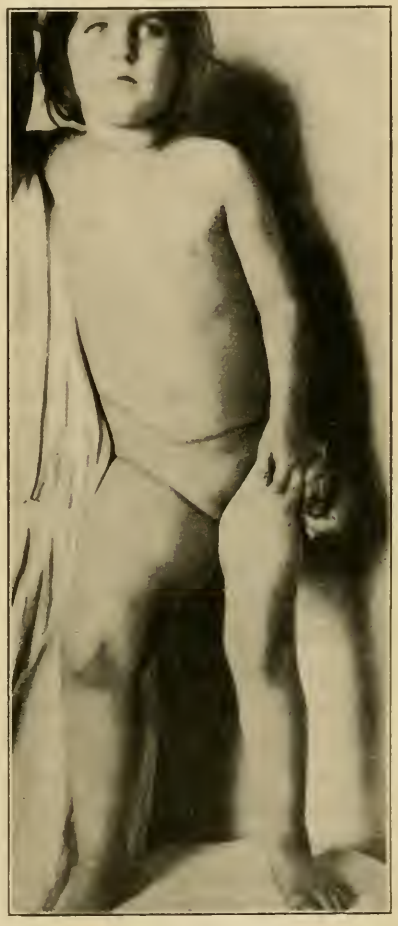

Fig 371.—Lymphosarcoma of groin invading retroperitoneal tissues in child of four.

The X-ray has proven to be of great value in destroying superficial lymphangiectases (Ref.).

The Buttock.—A great variety of tumors is found in the buttock, partly to be explained by the complexity of its structure and the great variety of tissues and organs contained in it. It is also subjected to repeated trauma and is in relation with the structures passing through the sciatic foramen.

Muscular and fascial tumors, fibroma, sarcoma, myxoma, the last often extending down the back of the thigh, are not uncommon. Tumors originating within the pelvis sometimes send prolongations out through the sciatic notch as in the case of a myxoma of the broad ligament reported by Brin (Rev. de Gyn. et de Chir. Abd. v. 15, 1910, p. 305) which produced a large fairly firm tumor of the buttock as well as of the lateral aspect of the vagina.

Bursal cysts about the hip and upper thigh and buttock may arise from any of the numerous bursæ in this region as may abscesses and inflammatory tumors which may be mistaken for sarcomata.

The most constant bursæ in this region are: the bursa between the fascia lata and trochanter major which is at once the largest, the most superficial, and the most exposed to trauma; that between the glutæus maximus muscle and the tuber ischii and that between the ilio-psoas and the anterior portion of the capsule of the hip-joint.

Cysts in such bursæ may continue slowly to increase in size until they reach enormous dimensions dissecting up the fascia lata or the intermuscular septa and extending almost to the knee.

If not too large they may successfully be evacuated by means of a hollow needle and the inner lining destroyed by the injection of a few drops of 95 per cent. carbolic acid but if large or if their walls are very thick they require excision. Incision or partial excision with drainage is feasible but objectionable.

The Hip-joint.—Aside from the tumefaction incident to the extensive development of arthritis deformans (malum coxæ senile) in which masses of osteophytes of considerable size form or general enlargement of the bones takes place, primary tumors of the hip-joint proper are rare. The hip-joint, however, is a favorite point for the localization of carcinoma secondary to carcinoma of the breast, stomach, etc. For such, when the diagnosis shall have been established, there is little to be done beyond relieving the suffering of the patient. For the diagnosis, X-ray pictures should of course be taken and with compression diaphragm in order to secure as sharp detail as possible. If a lesion suspicious of carcinoma is found systematic search over the body should be made for the primary focus and the Wassermann reaction sought for and if found to be positive, suitable antisyphilitic treatment should be instituted to exclude syphilis as the cause of the trouble. But it should not be forgotten that a person with carcinoma of the breast may have a syphilitic lesion of the hip-joint. Carcinoma

of the hip-joint is often painful; it may cause such suffering as to warrant excision of the femoral head.

Sarcoma does occur in the joint capsule and in the bone, but much less commonly than in the shaft and at the lower end of the femur.

The Thigh.—The muscles of the thigh, the fascias, aponeuroses, and the intermuscular septa are not infrequently the seat and origin of myxomata as are also bursæ, ligaments and periosteum. They form painless, rather rapidly growing, roundish, more or less elastic tumors which are roughly encapsulated. Their particular form depends largely on the particular point of origin and the pressure of surrounding parts. They are often pear-shaped, *i.e.*, they have a long neck leading from the point of origin.

They contain a stringy mucoid substance which in the interior of the tumors, because of the breaking down of trabeculæ, is contained in large cavities. When encapsulated, these myxomata may be shelled out, but care should be taken to remove not only the capsule but also a wide area of periosteum or intermuscular septum or bursa from which the tumors have taken their origin.

One great difficulty is to distinguish clinically between the relatively benign pure myxoma and the more malignant myxosarcoma of similar origin.

Chondroma occurring in muscle is extremely rare as is also fibroma. An old hematoma in the belly of a muscle may simulate sarcoma; its traumatic origin and its tendency to remain of constant size (chronic hematoma) should lead one to investigate it histologically before resorting to a mutilating operation. If the hematoma is merely a local expression of a general dyscrasia, the proximate cause being a relatively slight trauma, most probably other hemorrhages would be in evidence. Simple excision is curative but incision and drainage away of its fluid content may be efficient.

Hernia of muscle is most common in the thigh, particularly in the region of the abductors and the quadriceps, and might be confounded with a neoplasm. It has its origin in a trauma (transmitted violence, rarely, by a cutting or crushing wound) sufficiently severe to be remembered. The tumor appears when the quadriceps or the adductors are contracted and a muscle mass prolapses through the rent in the aponeurosis.

The treatment is the operative closure of the rent followed by prolonged rest, else the bulging of the muscle in contraction will tear open the rent in the fascia or muscle sheath and cause recurrence; or

the longitudinal pull of the muscle on its fascial attachments may pull apart the edges of the wound in the fascia, for Bardenheuer would have it that the deep fascias are connected to the muscles, a principle which he has made the basis of his traction treatment of fractures.

Traumatic exostoses may arise from any area of bone subjected to injury but are more common in the region of muscular attachments such as the trochanters, linea aspera, adductor tubercle, etc. They occur more frequently in the lower extremities than elsewhere in the body. Muscle tissue affords a favorable environment for the growth of bone, especially if injured, possibly because its loose structure and the relative motion of its parts and possibly in cases of injury because of the presence of blood clot.

The essential cause of so-called muscle bones is not clear. By some they have been considered to be tumors ("Muskelosteom"), but by others to be of inflammatory origin; hence the term myositis ossificans traumatica which presupposes the presence of some congenital remnant of bone-forming tissue (*Knochenkeim*). A more likely explanation is the traumatic tearing away of some minute portion of periosteum from a neighboring bone or the attachment of the muscles affected, for commonly muscle bones form in muscles near their bony insertions. Or such a tearing up of the point of attachment of the muscle may set free a few osteoblasts which proceed to develop in their new and favorable environment, a theory which would well account for the common development of bone in the brachialis anticus muscle after posterior dislocation of the elbow, the attachment of the muscle to the coronoid process of the ulna being injured. Others take a middle ground distinguishing between the muscle bones which are in relation to bone and periosteum and those which are free in muscle, the former being classed as inflammatory, the latter as tumors. The absence of inflammatory products about muscle bones has been urged as an argument against the inflammatory theory in favor of the tumor theory. But the frequently observed regression and absorption of muscle bones is scarcely to be reconciled with the conception of a neoplasm.

Riders' bones most commonly arise in the attachment to the os pubis of the great adductor of the thigh but may grow from any point on the shaft of the femur which is subjected continually to trauma. Such riders' bones may grow to considerable size and may seriously interfere with blood-vessels and nerves as well as with muscle and joint function.

The appropriate treatment is excision which to be successful must be radical and which, because of tough fibrous connections and irregu-

larities and the possible involvement of nerves or blood-vessels, may be annoying and even most difficult.

Sarcoma arising in the fascias, intermuscular septa, etc., forms large, fairly firm tumors often encapsulated and hence removable by excision. Nevertheless the prognosis is unfavorable even before metastasis has occurred for the capsule itself is sarcomatous and at the point of origin the tumor is generally infiltrating. Therefore in excision the entire capsule must be extirpated with scrupulous care, for recurrence is almost sure to follow enucleation of the tumor from within its capsule. For the same reason the tissues about the point of origin must be excised widely.

In all but the well encapsulated cases, amputation offers the only safeguard against local recurrence, but so mutilating an operation is unjustifiable of course in the presence of metastasis. Before resorting to amputation, diligent search for metastases should be made especially of the lungs, and here the X-ray is invaluable.

There is greater safety in excising the entire muscle which is the seat of a sarcoma than in any more local operation. Lecene (Bull. et Mem. de la Soc. Anat. de Paris, V. 85, 1910, p. 894) would have it that total ablation of a muscle with its tumor may give satisfactory end results as shown by the observations of Alglave, Durans, Danielson, Meril than which the results of amputation are but little better. Amputation is to be performed in cases in which the tumor has passed the confines of the muscle, but in amputation for a fascial or muscular sarcoma of the thigh the operation should be so modified as to provide for the removal in its entirety of the muscle involved.

These tumors often follow single or frequently repeated slight traumata. A prominent auctioneer in San Francisco for years habitually slapped his thigh with his hand on the conclusion of a sale and at this point a fascial sarcoma developed which deeply invaded the muscles. The patient succumbed in spite of amputation (Dr. L. C. Lane).

A striking example of the traumatic origin of sarcoma is published by Heinrich (Deut. M. Woch. V. 37, 1911, p. 164). A man of 41 received a blow on the calf immediately followed by a swelling the size of a hen's egg (hemorrhage). In seven months a semifluctuant tumor was present which proved to be a round-celled sarcoma. The patient recovered from amputation of the thigh but succumbed to spinal and other metastases two years later.

Mantelli reports (Gaz. d. ospedali e. d. cliniche) a case of recurrent

sarcoma of the sheath of the femoral vessels which invaded the femoral artery. He resected the artery with the tumor and successfully re-

FIG. 372.—Multiple exostoses.

paired the vessel by means of free transplantation of a section of the saphenous vein.

Tumors of the Femur.—Pedunculated osteomata or congenital exostoses arise from the regions of the epiphyseal cartilages most often

on the inner and outer sides of the lower end of the femur and the upper end of the tibia (Fig. 372). They are congenital in origin, are singularly apt to be symmetrically located and not infrequently appear in several members of the same family in several generations. They are tipped with cartilage from which they grow as do plants from terminal buds, but they ordinarily cease growing about the time of the cessation of growth from the epiphyseal cartilages. The cartilaginous bud seems to expand laterally so that such exostoses are often larger in their peripheral portions and are then really pedunculated tumors with narrow stalks. The direction of their growth often changes to be finally parallel with the shaft of the bone, the femoral exostoses about the knee turning upward and the tibial, downward.

In a case of mine in a young man of 17, symmetrical exostoses growing from the inner side of his femur just above the knees were so large as to strike each other as the patient walked which "interference" was the principal reason for the patient's request for the removal of the tumors.

Over their more prominent portions bursæ often develop which are in turn subject to the various inflammations and tumors which occur in bursæ elsewhere, more commonly myxomata.

Bone Cysts.—Cysts are found in bone in many pathological conditions to which the long bones of the lower extremities are rather more subject than the upper. Tietse (Ergeb. der Chir. v. 2, 1911, p. 32) mentions the following:

1. Cysts forming at points of breaking down of solid tumors (sarcoma, enchondroma).

2. Parasitic cysts (ecchinococci, cysticerci).

3. As the end product of an infective osteomyelitis (osteomyelitis, periostitis albumosa).

4. As a product of a rarefying bone lesion [subchondral in arthritis deformans] (Ziegler), in senile osteoporosis in neck of femur and vertebræ (Braun), in osteomalacia.

5. In Barlow's disease (infantile scurvy).

6. As callus cysts (Frangenheim).

7. In osteitis (osteomyelitis fibrosa) of the types of von Recklinghausen's and of Paget's diseases.

But there is a group of bone cysts quite independent of the above pathological conditions, the so-called true bone cysts which are simple cavities in the bone often lined with a fibrous capsule and filled with fluid. They are an affection of the growing period, practically all

cases occurring before the age of 20. Such cysts have been observed in infancy. There is often a history of antecedent trauma. The cysts develop slowly, generally without much pain and cause central absorption of the bone which protects itself by continuously forming new bone in the periphery. In this way such cysts sometimes attain great size. The weakening of the bone often leads to spontaneous fracture which may be the first phenomenon to direct attention to the limb.

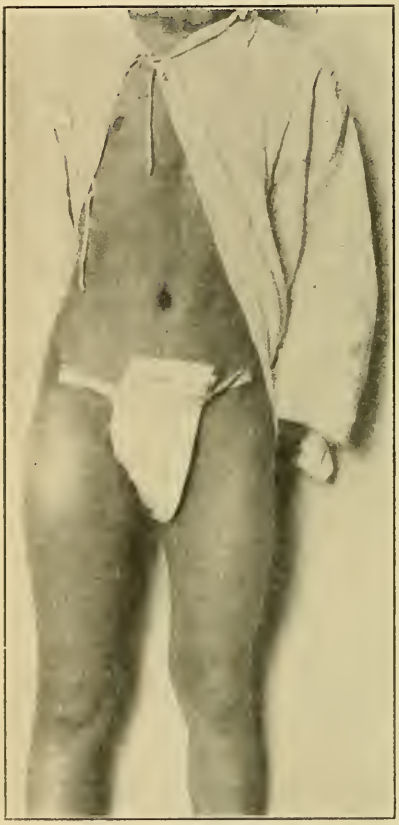

Fig. 373.—Osteosarcoma of femur in boy seventeen.

True bone cysts occur most frequently in the humerus, femur and tibia and in that order (Bloodgood, Ann. Surg., 1910, v. 52, p. 145). For the diagnosis the history (age, trauma, long duration), lack of pain, spontaneous fracture if present and Röntgen picture generally suffice yet caution in the matters of prognosis and treatment should be exercised because of the similarity in the above description to certain cases of more or less malignant tumors with cystic degeneration. On the long duration of the swelling perhaps with the Röntgen picture is most reliance to be placed. Nonmalignant bone cysts ordinarily do not traverse the epiphyseal line.

When removed by resection or curetting with crushing together of the bony shell there is little if any tendency to recurrence. Koerte, however, reported a case of recurrence. The spontaneous fractures commonly heal with abundant callus.

Resection should be done in such a manner as to save the periosteum for its aid in the reproduction of the bone. While the new bone is growing, the leg must be supported and to this end sometimes an internal splint is desirable (Lexer used ivory plugs and Kaposi, living bone grafts) and care should be exercised not to permit the limb to

become shorter or to bend during the healing process. In the lower extremity the new bone should be protected for a longer period than in the upper; weight should not be borne for upward of three months.

It should be remembered that serious oozing from the bone may follow the operation of curetting. In two cases, quoted by Bloodgood,

Fig. 374.—Radiograph of osteosarcoma of thigh in boy of seventeen, same case as Fig. 373.

the hemorrhage was uncontrolled and in another it was so severe that amputation was required. The operation should be done under an Esmarch bandage. Oozing from bone can often be controlled by the use of Horsley's wax which is so efficient in controlling bleeding from the diploë of the skull.

Sarcoma is at once the most frequently occurring tumor in the femur and affects the femur more frequently than any other of the long bones (Figs. 373, 374 and 375).

The statistics of Altschul (Beit. z. klin. Chir. v. 67, 1910, p. 3 59) showed 63 sarcomata of the long bones from the Klinik of Wölfler, (Prag) of which 26 were of the femur, 15 of the tibia, 10 of the fibula, 7 of the humerus and 5 of the ulna. While no age is exempt, a majority of the cases (two-thirds) occur between the years of 15 and 40.

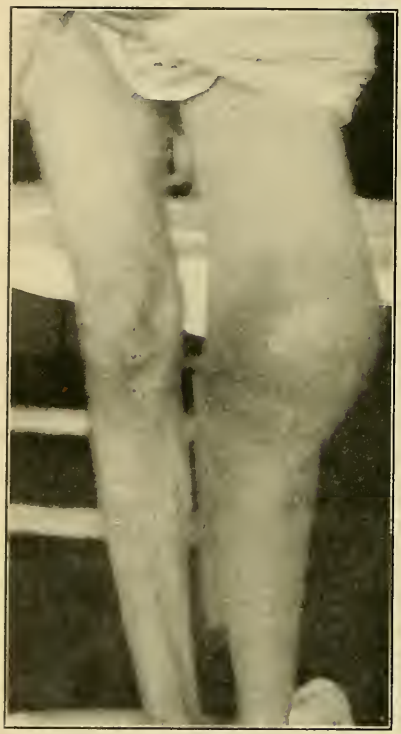

FIG. 375.—Myxosarcoma of lower end of femur three years after discovery. Patient is alive and free from recurrence six years after high amputation.

Sarcomata of the long bones vary so greatly in malignancy, they are so easily mistaken for other less serious lesions and their surgical treatment so often requires amputation or at least sacrifice of the weight-bearing function of the lower extremity that the responsibility of the diagnosis and determination of the indications for operation and particularly the choice of operation is very great.

In the diagnosis of central, periosteal and giant-celled sarcoma of the femur, the X-ray picture is invaluable for it gives information not otherwise obtainable except by amputation. Syphilis, hydatids, chronic osteomyelitis, tuberculosis, bone cysts, must all be excluded as must also metastases of distant carcinoma, sarcoma, hypernephroma. The last may grow slowly for years like a benign tumor, then suddenly form metastases (Neu. Ztsch. f. gyn. Urol.,v. 2, 1911, p. 323) (Scudder Ann. Surg. v. 54, 1906).

Paget's disease produces deformity of the long bones with production of fibrous tissue and of cystic cavities with islets of cartilage and of red tissue of the structure of giant-celled sarcoma for which it may be mistaken (Hartmann, Beit. z. klin. Chir. v. 73, 1911, p. 627).

Syphilis mimics sarcoma of bone so completely that it may deceive

expert Röntgenologists and histologically may deceive even experienced pathological anatomists. I have known of a thigh to be amputated in pre-Wassermann days in a patient who a few months later returned with many lesions manifestly syphilitic and another instance in which on clinical ground amputation was arranged for when a consultant insisted on mercury and iodides being given in large doses. The "sarcoma" rapidly disappeared.

Fortunately we now have the Wassermann reaction which, in good hands, and where the other diseases in which a positive reaction has been observed can be eliminated, is absolutely diagnostic of syphilis when positive, though of very doubtful value when negative, as it depends much upon the activity of the disease. However, when used in making the diagnosis between sarcoma and syphilis, *i.e.*, with a large lesion presupposing a considerable degree of activity of the syphilitic process, a negative reaction, if repeated (and properly controlled in order to establish the quality of the reagents used in the test) is of very great value in excluding the disease, and it will probably be found that at least 75 per cent. of tumors suspected to be sarcoma may thus be excluded provided they are of syphilitic origin. In cases in which the tumor is suspected to be of syphilitic origin and the ordinary Wassermann reaction results negatively, a positive reaction may sometimes be obtained with the provocative Wassermann test, *i.e.*, the testing of the patient's blood serum after the administration of a dose of from 0.3 to 0.4 grams of salvarsan.

In every case of suspected sarcoma of the femur the Wassermann reaction should be tried, and if positive, antisyphilitic treatment should of course be given a thorough trial, but it should be borne in mind that a person with syphilis may have sarcoma. If the Wassermann reaction is negative antisyphilitic treatment should still be tried before resorting to so mutilating an operation as a high thigh or hip-joint amputation.

The so-called myeloid or giant-celled sarcoma arises from the cancellous tissue of the metaphysis, less frequently from the epiphysis. It is encapsulated, non-infiltrating and is so little malignant as almost to require to be classed with benign tumors. Local excision is sufficient to cure even when the tumor is recurrent after incomplete removal. Indeed simple curetting if thorough will often suffice, though it may require to be repeated. In curetting, the danger of hemorrhage is great and warrants use of the Esmarch bandage with

cauterization of the walls of the cavity. Recurrence has been known as late as 12 and 14 years after local operations (Müller).

The more rapidly growing round-celled sarcomata, whether arising from the periosteum or endosteum, are frightfully malignant and can be dealt with successfully only by amputation.

In the differential diagnosis the X-ray is invaluable. The myeloid sarcoma is characterized by having a distinct bony shell and by being filled with bony trabeculæ and by seldom traversing the epiphyseal line, while in the softer forms of sarcoma there is less bony tissue in their interiors or none at all. The outlines of excavations in the bone, instead of being definite and clear-cut, are ragged and not surrounded by much sclerotic reaction on the part of the surrounding bone.

Tumors arising in the interior of the bone and perforating through the compact layer of the shaft into the soft parts, whether benign or malignant, lift up the periosteum permitting new bone to be deposited beneath. This results in a flaring rim of bone being built up about the area of perforation.

Pulsating tumors of the long bones—bone aneurisms—often with marked bruit, are generally sarcomatous, but cases have been observed with no evidence of neoplasm as their cause (le Dentu, Arch. Gen. de Chir. v. 6, 1910, p. 1).

Decision on the questions of when and where to amputate in a given case of periosteal or osteoid sarcoma entails much responsibility.

Amputation is to be done only when vigorous search has failed to show metastasis of the tumor in question and that the tumor is itself metastatic from some distant tumor. Severe anæmia, cachexia and marked loss of weight are often contraindications in that they are much more apt to be due to generalization of the tumor than to the primary growth.

Except in tumors involving the upper third of the femur there is little advantage from the standpoint of avoidance of recurrence in amputation through the hip-joint over a high thigh amputation, and considerable disadvantage from the greater operative risk.

In periosteal sarcoma the results of amputation are not much better than resection so that in still localized (limited, encapsulated) sarcoma resection might be tried, but most surgeons will agree that amputation is indicated if the diagnosis is made in an early stage of the tumor as giving the patient the best chance for life.

Of 68 cases of periosteal sarcoma of the femur treated by ampu-

tation at or below the trochanter collected by Butlin, only one was permanently cured.

In inoperable cases Coley's toxines deserve a trial. Coley reports a case of round-celled periosteal sarcoma of the femur with metastases treated by the mixed toxines of erysipelas and prodigiosus which remained well some 10½ years when local recurrence was noticed. The toxines were tried again but with no effect, the patient finally succumbing to metastases (Tr. Am. Surg. Assn., 1913, p. 281).

In the lower extremity in view of the weight-bearing function, amputation is much more apt to be required in the presence of extensive bone cysts and giant-celled sarcomata than in the upper extremity because of the at times inevitable weakening by local operations of the otherwise efficient bones. The conservative surgeon will exercise his ingenuity in performing local operations, resections with not excessive shortening or the replacement of the resected bone by suitable bone grafts (in free transplantation) taken from the diaphysis of some distant bone or a freshly amputated leg.

When, because of the presence of metastases or from too extensive involvement of tissues, the tumors are determined to be inoperable, their growth may often be considerably inhibited by the use of arsenic. Manheimer (Beit. z. kl. Chir. v. 72, 1911, p. 74) reported a case of spindle-celled sarcoma with myxomatous portions favorably influenced by arsenic. See also Czerny and Coan (Munich. med. Woch. v. 58, 1911, p. 881).

Patella.—Tumors of the patella are rare as are tumors of the epiphyses. Vanach (Chir. Arch. Veliaminova. v. 26, 1910, p. 198) (ref. in J. de Chir.) reported a case of giant-celled sarcoma of the patella. The tumor the size of an infant's head in a woman of 37 was successfully excised with the patella. The tumor had appeared 21 years previously after a fall and had increased very gradually in size. It had begun to grow rapidly following another fall one year before it was seen by Vanach. Vanach collected from the literature 4 benign and 16 malignant tumors of the patella. Of the latter 9 were central sarcomata, 3 periosteal, 4 giant-celled, 3 spindle-celled and 3 round-celled sarcomata. The four benign tumors were a fibroma, an osteochondroma and two chondromata. Three modes of operative treatment suggested themselves. Resection was rejected as possibly applicable only to cases of malignant tumor which had invaded the knee-joint and as being then inefficient. Amputation was advocated for the advanced cases and the operation of choice for most cases was considered

to be the total ablation of the patella and tumor with lateral suture or plastic repair of the quadriceps.

Popliteal Space.—Like the groin the popliteal space is the seat of a great variety of tumors, bursal cysts, myxomata, lymphatic tumors, aneurisms, fascial, lymphoid and other sarcomas, etc.

A large but inconstant number of mucous bursæ are found in the popliteal region commonly divided into two lateral groups; there is none in the central region of the popliteal space. With a few exceptions each muscle attached to the bone in this region has a bursa beneath its tendon, *e.g.*, sartorius, semimembranosus, gastrocnemius on the inner side and biceps, outer head of gastrocnemius, popliteus on the outer, besides a bursa between the inner head of the gastrocnemius and the semimembranosus and one between the popliteus and the external lateral ligament of the knee-joint. Several of these bursæ communicate with the knee-joint and do so considerably more frequently in older subjects than in the young.

Cysts may develop in any of these bursæ as a result of recurring bursitis, traumatic or otherwise. Myxomata may also develop.

In the popliteal space aneurism is more common than elsewhere, except in the chest, possibly because of the frequent trauma of the artery incident to complete flexion of the knee. Sacculated aneurysm here lends itself best to the Matas operation of endo-aneurysmorrhaphy which, though it seldom accomplishes its design of preserving the continuity of the artery, successfully obliterates the aneurismal sac without the great difficulty and the dangers of excision, as in the operation of Antyllus. But here also the Hunterian operation of proximal ligation finds its best sphere of application.

The Knee-joint.—The region of the knee-joint is a common site for a variety of tumors in addition to those mentioned as occurring in the patella and the popliteal space.

Lipomata reported as occurring in the interior of joints are nearly all of the knee (Weir, N. Y. M. Rec., June 26, 1886). They develop in the ligamenta alaria, ligamentum mucosum, etc. Fibromata and sarcomata developing from the synovial fringes, as well as lipomata, are often pedunculated. Any of these tumors may give rise to some disability, locking of the joint, swelling and pain. Tuberculosis of these fringes may make tumor-like masses quite without the usual symptoms of joint tuberculosis.

Sarcoma may arise from ligaments, fascias, periosteum and bone. The lower end of the femur and the upper end of the tibia are more

common sites for sarcoma than other parts of the same bones. Giant-celled sarcoma and bone cysts are here particularly common and present an important problem to the surgeon of removing the tumors without destroying the weight-bearing function of the limb. These tumors being of such slight malignancy can often be excised or scraped out without entering the knee-joint, in which event the cavity left may be filled with Mosetig-Moorhof paste and the limb be protected from undue strain till the bone shall have grown sufficiently to permit of weight bearing or some osteoplastic procedure be carried out to partially fill the cavity or by free transplantation of a piece of bone from elsewhere to furnish bone-forming material.

Soft round-celled and most spindle-celled, rapidly growing sarcomata, whether they arise from the marrow or the periosteum of femur or tibia, require thigh amputation which should be performed as early as possible. Caution in making the diagnosis and the exclusion of syphilis by Wassermann test and antisyphilitic treatment are as advisable here as in the thigh (see page 457).

The question of the advisability of opening into such a tumor and removing a piece of it for histological examination is a vexed one. There is perhaps little objection to making such an incision into a sarcoma and amputating a few minutes later but the decision to amputate is a very important one to be based on the microscopical examination of a frozen section. The histological pictures are not always characteristic and mistakes may easily be made even by expert pathological anatomists.

Carcinoma of the lower extremities is practically always of the form of squamous-celled epithelioma. The extreme rarity of sebaceous or sudoriparous adenomata in this region naturally determines the rarity of adenocarcinoma. While the epithelioma may develop at the site of any chronic irritation, it much the most commonly develops in a chronic ulcer of the leg, a condition described by the elder Marjolin and since then often called Marjolin's ulcer. It is characterized by exceedingly slow growth and by a red surface which easily bleeds and which is nodular with raspberry-like elevations. It is of an exceedingly low degree of malignancy infiltrating but slowly and seldom forming metastases, a fact to which Volkman called attention, and in which respect it is comparable to rodent ulcer of the face. However, the lymph-glands of the groin are often enlarged as a result of infection.

The tumor may grow slowly in all directions through many years,

invading all the structures of the leg, including the bone. In one case, in which I was enabled to perform an amputation below the knee in a man of 71, the tumor had eroded completely through both tibia and fibula and the foot being virtually amputated was left dangling by a strip of tissue posteriorly which contained the blood-vessels. No metastases were detectable. The man lived three years, dying of an intercurrent affection with no recurrence of his tumor, although the line of amputation was in places within an inch of the line of palpable induration.

Amputation is generally required in Marjolin's ulcer, though in beginning cases local excision covering the defect with Thiersch skin

FIG. 376.—Marjolin's ulcer. Squamous-celled carcinoma in woman of seventy-two which developed in scar of an ulcer of life-long duration. Death ten months after amputation below the knee of pulmonary metastasis.

grafts may be justified. In the amputation it is often possible to save the knee-joint and a useful length of tibia even though it require to be covered by a long posterior flap after a Teale's or a Stephen Smith's amputation reversed. If the flaps are scant, the stump may be made smaller by removal of the fibula and any of the muscle remaining.

In the case illustrated by Fig. 376 in a woman of 72, the tumor developed in an ulcer of the leg which had existed since childhood. It had of late become exceedingly painful by reason of invasion of the nerves of the leg by the carcinoma. There was a mass of tender, enlarged glands in the groin which, however, disappeared after am-

putation of the leg below the knee. While the patient was relieved of her pain and rapidly gained weight after the amputation, within four months she began to suffer with neuralgic pain in the right arm and succumbed to pulmonary metastasis 10 months after the operation. There was no local or regional recurrence. Metastasis had most probably occurred anteriorly to the time of the amputation, possibly by way of the blood-vessels in the bone.

Fig. 377.—Syphiloma of tibia with spontaneous fracture.

Rehn (Beit. z. kl. Chir. v. 66, 1910, p. 147) reported a case of squamous-celled carcinoma which developed about the orifice of a sinus leading from the bone cavity in a case of chronic osteomyelitis of the tibia with sequestrum.

Tibia and Fibula.—The bones of the leg are subject to a great variety of tumors much as is the femur and present few special problems. Syphiloma (Fig. 377) may closely simulate sarcoma.

Malignant tumors of the fibula are much less common than of the tibia, probably because of its less degree of exposure to trauma, and

Fig. 378.—Boy of sixteen, same case as that of Fig. 380. Osteoid sarcoma. Radiograph of section of tibia ½ cm. thick showing great density of tissue of the sarcoma within the bone as great as that of compact bone of the shaft. Tumor growing in popliteal space after perforation of periosteum is but little calcified.

may on occasion be extirpated together with much of the bone without the necessity of amputation, for the fibula takes no part in weight bearing and little disability follows the removal of all but its lower portion.

FIG. 379.—Osteoid sarcoma tibiá.

Osteoid sarcoma and chondrosarcoma occur in this region and though less malignant than the softer forms of sarcoma require amputation. It is important to remember in making the diagnosis that all these viciously malignant tumors are prone to break through the epiphyseal line while the giant-celled sarcoma and benign cysts rarely do so.

When an osteoid sarcoma breaks through the periosteum, it grows much more rapidly and is much less dense than when confined within the bone (Fig. 379). The harder parts within the bone may be even more dense than the surrounding bone as shown in Fig. 378, a radiograph of a section with parallel sides of such an osteoid sarcoma (Fig. 380). The tumor in this case was so malignant that in spite

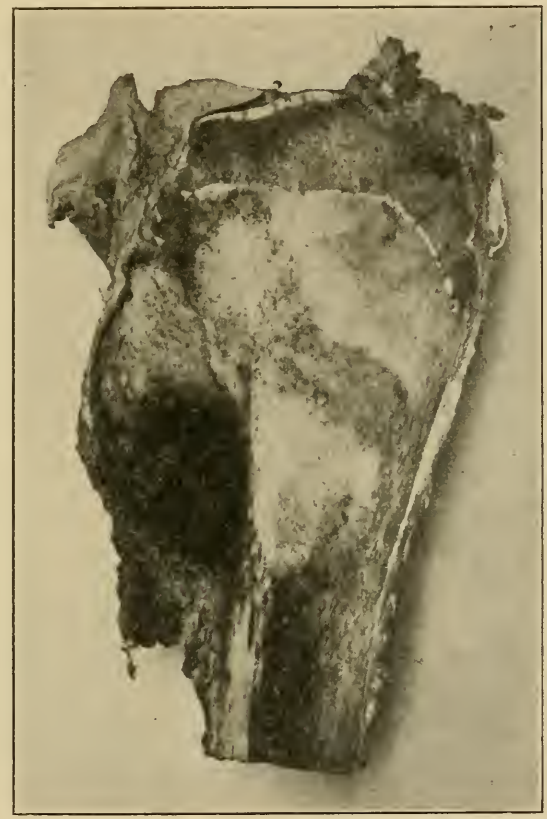

Fig. 380.—Osteoid sarcoma of tibia in boy of sixteen which traversed the epiphyseal cartilage and perforated posterior surface of tibia forming in the popliteal region a rapidly growing tumor. Death from pulmonary metastasis.

of amputation of the thigh the patient, a boy of 16, died within two months of pulmonary metastasis.

If the tumor be limited to the upper end of the tibia and be of a less malignant variety, one may be justified in performing a Gritti amputation because of the better functional results than in higher amputation.

The Ankle and the Foot.—Aside from bursal cysts and ganglia the most frequent tumor of the ankle region is sarcoma (Fig. 381) which may arise in the bone, the ligaments, joint capsule, tendon sheath, etc.

Sarcoma of the joint capsule of the ankle-joint is described by Hannemüller as observed in the Kuttner clinic in Breslau (Beit. z. kl. Chir. v. 63, p. 307, 1909). He reviews the literature of joint cap-

Fig. 381.—Sarcoma of ankle joint.

sule sarcoma showing the rarity of the affection and calls attention to the gross resemblance of the lesion to tuberculosis from which and from syphilis it is to be differentiated by the specific reactions of those diseases after Moro, von Pirquet and Wassermann. Rudiger-Rydigier (Deut. Ztsch. f. Chir., Bd. LXXXII) indicates another point of differentiation in that the joint motion in capsular sarcoma is but little interfered with, but Garré has reported a case with limitation of

joint motion as well as fever. Glandular swellings are generally absent.

Sarcoma of the tendon sheaths has been studied by Rosenthal (Beit. z. kl. Chir. v. 44, p. 577, 1909) who gathered together 70 cases from the literature and reported one. While it is most common in the sheaths of the tendons of fingers and toes, it may occur in any tendon sheath and its local frequency is modified by trauma. It is of variable though generally slight malignancy for the most part remaining local; when recurring, it does so locally. Only two cases of

Fig. 382.—Myeloid sarcoma of os calcis.

the 71 died of generalization. Diagnosis is difficult and apt to be made only after removal. Thecal sarcoma may be painful, especially if subjected to trauma.

Sarcoma rarely arises as a primary tumor in tendon tissue and then takes the histological form of epulis (Fritsch. Beit. z. klin. Chir., Bd. LX, 1908, p. 344).

Sarcoma of the tarsal bones is not frequently met with but does occur and most frequently in the os calcis (Fig. 382). It is apt to be of the myeloid variety which excavates the entire interior of the

affected bone and perforates the peripheral layer of compact bone only late in its course. It produces a diffuse swelling of the bone whose peripheral layer may be indented with the finger. Radiographically the bone is seen to be more or less uniformly enlarged, its usual internal sculpture being destroyed and replaced by an irregular arrangement of bony trabeculæ separating large transparent spaces.

FIG. 383.—Calcaneal spur. (*Marty.*)

Myeloid sarcoma of a tarsal bone may be successfully removed by local excision, the entire bone being removed, but in the case of the os calcis local excision leaves the foot very much maimed.

Synovial cysts of tendon sheaths (ganglia) according to Bergermann (Beit. z. kl. Chir. b. 66, p. 468, 1910) are not hernial sacs but the result of colloid degeneration of peritendinous connective tissue and Payr would have it that trauma is not as prominent in causation as commonly believed. They may perhaps be best treated by excision but ordinarily simple incision, splitting the sac with a tenotome through a puncture

in the skin and evacuating the contents into the cellular tissues by digital pressure, suffices.

Exostosis may occur at many points of the skeleton of the foot, especially under the influence of trauma such as the constant irritation due to the pressure of ill-fitting footwear as in many bunions and inflamed bursæ on the instep.

But there are two exostoses of the os calcis which are typical and are of special interest; the one at the insertion of the plantar fascia on the anterior edge of the heel (Fig. 383), the other under the tendo Achillis just above its insertion. While these exostoses have been thought to be due to gonococcal infection as periostitis and bursitis in this region commonly are, flat-foot, producing a persistent though intermittent and abnormally severe traction of the plantar fascia on its point of attachment, is the principal cause of this spur.

The sharp point of the spur may so prick the soft parts in walking as seriously to discommode the person so afflicted. The remedy consists in cutting away the exostosis and enough of the neighboring part of the os calcis to prevent its recurrence, preferably through a lateral incision, but correction of the flat-foot, and the fitting of proper shoes should not be forgotten.

Beneath the nails of the toes, more especially of the great toe, and probably as a result of trauma there occasionally develops an exostosis which lifts back the nail and causes disability (subungual exostosis). Excision taking the dorsum of the terminal phalanx is effective in permanently removing the growth. In some cases it may be well to remove the matrix to prevent abnormal growth of the nail.

In addition to the above-described simple exostosis, there occurs beneath the nail a malignant tumor, subungual angeiosarcoma. It appears as a small, red tumor with smooth surface lifting up the nail and unless removed continues to grow and finally breaks down and becomes infected.

In its beginning it may be locally excised after removing the nail; later it requires amputation of the toe.

Carcinoma as well as sarcoma of the toes has been observed, having arisen at the site of an ingrown toe nail.

Chondroma also occasionally occurs on the toes, as on the fingers, and is sometimes multiple.

A comparatively trivial tumor of the skin of the sole which, however, causes a great deal of suffering is benign papilloma or ordinary wart. It is quite common and is generally looked upon by the patient and often

by the chiropodist as a refractory corn and is frequently pared even till it bleeds by which it is hoped to lessen the pain due to pressure in walking and standing. As ordinarily seen, it is level with the skin surface, most of its tumor mass projecting inward. Its cut surface shows a number of large papillæ. It is often multiple. It may best be managed by excision under local anæsthesia.

It is said that on occasion squamous-celled carcinoma begins in such papillomata of the sole, and that carcinoma of the sole is frequently painful.

SECTION XI

NON-TRAUMATIC AFFECTIONS OF THE LOWER EXTREMITIES

By

STANLEY STILLMAN, M.D., F.A.C.S.

SOFT PARTS

Erysipelas originates less frequently in the lower extremity than elsewhere on the body and its diagnosis and treatment are the same as elsewhere.

Furuncles are common about the buttocks and outer side ofthe thighs and legs. They are usually secondary to boils on the neck, being the result of auto-inoculation by the finger nails through scratching after dressing or squeezing the primary boil. Patients should never be allowed to dress or touch their own boil, though it is very hard to make them keep their fingers away from it. Furuncles should be incised early and dressed so that the discharges are promptly absorbed and not spread over the adjacent skin, and the skin should not be macerated by poultices or moist dressings. Carbuncles should be freely and promptly excised and the surface at once skin grafted. The same treatment often saves time and suffering in the case of boils.

Acute Abscess.—Acute abscess may occur in any part of the lower extremity, but occurs more frequently about the buttocks, groin, popliteal space and feet. Ischiorectal abscess sometimes points in the gluteal region or on the inner surface of the thigh near the perineum. Popliteal abscess usually results from a suppurative adenitis and is discussed under that head. Rarely it occurs as the result of suppuration of the sac of a popliteal aneurism; any popliteal abscess may simulate an aneurism as the result of transmitted pulsation. As elsewhere, the pulsations are never expansile as in aneurism. Early incision of popliteal abscesses by the Hilton-Roser method is imperative, as otherwise the suppuration may involve the knee joint or give rise to an extensive deep phlegmon of the thigh or leg.

Acute abscess about the saphenous opening may be due to pointing of an abscess originating in the pelvis, but in the vast majority of

cases it is the result of suppuration of the inguinal or saphenous glands. Plantar abscess is rare as compared with palmar abscess and is always of traumatic origin. Abscess due to suppuration of a hematoma is common in the leg and thigh and many abscesses of obscure origin are due to suppuration of one of the many bursæ (*vide* Bursæ).

Phlegmons are not uncommon and may be very deep seated. A superficial phlegmon arising from suppuration of the prepatellar bursa may cause obliteration of the normal depressions around the knee-joint and simulate a suppurative synovitis. Suppuration of the deep bursæ may give rise to deep phlegmon of the thigh particularly along the adductor group of muscles. A dangerous situation for phlegmon is the connective-tissue plane between the deep and superficial groups of sural muscles. The entire leg becomes swollen and painful and œdematous but as the pus is confined by the attachment of the fascia to the tibia and fibula it may extend from the popliteal space to the ankle before external evidence of its location is manifest. The suppuration may involve the sural muscles and as a result of the suppurative myositis permanent contraction of these muscles may result.

Cold abscess, originating in tuberculosis of the spine or sacroiliac synchrondrosis, may point in the lumbar region but usually reaches the surface at the saphenous opening, being confined beneath the iliopsoas fascia till it reaches the region of the lesser trochanter:

Cold abscess in the popliteal space originates from tuberculosis of the popliteal glands or of the tibia or fibula and may even have its origin in the hip-joint. Cold abscesses of the groin or popliteal space are specially liable to be mistaken for aneurism if the character of the pulsation be not carefully noted. The treatment is that of cold abscess elsewhere, either complete removal of all tuberculous tissue, mopping with 50 per cent. iodine solution and suture, or if this is not possible aspiration and injection of 2 per cent. iodine solution or iodoform suspended in glycerine 10 per cent. When the focus is inaccessible the greatest care must be taken to avoid secondary infection.

Ulcers.—Simple ulcer of the leg occurs usually as the result of a slight abrasion, which has been neglected. Such abrasions over the tibia are very apt to develop into ulcers, unless the limb be put at rest and kept in a horizontal position. The dependent position of the limb interferes with the process of repair and the irritation of the clothing and infection combine to start an ulcer. This is particularly true in individuals past middle life and to these the caution should be

given to give the injured limb rest in bed. The conditions predisposing to ulceration are increased if the individual is subject to eczema of the leg or to varicosities. The distinctions made between the various forms of ulcers of the leg are unnecessary, and to some extent confusing. Varicose ulcers differ in no way from other simple ulcers, except that while the underlying condition due to varicose veins exists, the ulcer is more difficult to cure, and more apt to recur than when it is not. Clinically, we may make some classification of ulcers for purposes of treatment. In such classification would be included.

Simple acute ulcer which results usually from neglect of a slight abrasion and mild infection. With rest in bed, soothing lotions, preferably warm boric acid solution, the reddened area surrounding the ulcer quickly subsides, pain ceases, and the ulcer rapidly heals. No matter what treatment is employed it is very apt to progress, and may even become chronic if the patient insists on walking around or standing up.

Phagedenic or infected ulcer which progresses often with considerable rapidity, both peripherally and in depth, particularly if the patient insists on keeping the upright position. The discharge is generally profuse and irritating to the surrounding skin, which is œdematous, tender and painful. The quickest and best treatment or antiseptic procedure in these cases is thorough cauterization with the Paquelin cautery under nitrous oxide anæsthesia, and this may have to be repeated, if certain areas escape the first application of the cautery. If the patient then be confined to bed and the ulcer lightly packed with gauze or lint, soaked in equal parts of turpentine and olive oil, the sloughs very quickly separate and a healthy granulating surface appears. The next step is to stimulate the growth of the granulations until they reach the level of the surrounding integument. There is a great variety of powders and solutions used for this purpose, but turpentine, of the strength mentioned, is among the best. Whatever stimulating application is employed no pressure should come upon the granulations, or their growth will be checked. When the granulations have reached the level of the surrounding integument, epidermization begins to take place from the edges, but this will be checked if the granulations rise above the level of the surrounding skin. If this takes place the ulcer becomes a *proliferating ulcer* and the granulations require repression, so that epidermization may continue. These exuberant granulations, of course, constitute the proud flesh of the laity. They may be kept down by the use of astringent powders to some extent or by the

application of caustics, as the solid stick of nitrate of silver, but these chemicals, while they destroy the granulations for the time being, stimulate also the growth of new ones and destroy the young epithelial cells, where they are growing from the periphery. The best method of treatment is to cover the healthy granulating surface with perforated oil-silk, or gutta-percha tissue, of such size as to just cover the granulating surface, and over this to apply a sterile dressing with plenty of cotton and bandage the part tightly enough to repress by pressure the growth of the granulations. The smooth surface of the rubber tissue serves to guide the young epithelial cells over the surface, and they are not detached by the removal of the dressing, which should not be done too frequently. The blue line of advancing epidermization spreads very rapidly under such a dressing, and a comparatively large surface will heal with great rapidity.

Chronic or atonic ulcer may result from the acute or may be chronic from the start. In these, as the result of long continuance, there is formed, around the edges and beneath the floor of the ulcer, a wall of cicatrical tissue, the contraction of which has obliterated practically all of the capillaries, and there is no blood supply for the formation of granulations to fill the defect level with the surrounding skin, and until this has been accomplished, epidermization cannot take place. Such ulcers once formed tend to remain stationary for years. They are particularly apt to occur in the advanced stage of varicose veins, when the leg becomes œdematous, hard and brawny from the œdema incident to the condition. They also occur frequently in legs subject to chronic eczema. There is a long list of powders and chemicals and many methods in use for the treatment of this type of ulcer, but none of them succeed very well, because of the thick barrier of scar tissue which surrounds and underlies the ulcer. The quickest and most satisfactory treatment of all ulcers of this type is excision of the ulcer together with the cicatrical tissue to comparatively normal structure, whether it be periosteum, muscle or fat, and immediately covering the surface with Thiersch grafts. If the excision is made deeply enough, so that a good healthy bleeding surface is reached and hemorrhage checked before the grafts are applied, the grafts will almost invariably live. In some cases, it is well to do the excision under artificial ischæmia by the Esmarch bandage on account of persistent bleeding that occurs from small veins, when all the scar tissue cannot be excised, as in the case in late stages of varicose veins and chronic eczema. If this be done, it is well to leave the constrictor in place

for three-quarters of an hour after the grafts have been applied, and after its removal to keep the limb elevated until the resulting hyperæmia has subsided. The resulting cicatrices are much softer and more pliable and much less liable to break down again than the surface obtained by epidermization. If, for any reason, this procedure cannot be employed, multiple deep incisions made through the scar tissue will permit granulations to spring up from the bottom of the incisions and these may spread in time over the intervening parts of the floor of the ulcer. In other cases the ulcer may be circumscribed by a deep incision, but the certainty and rapidity of the method first described, makes it seem a waste of time and labor to attempt anything else. Where the conditions arising from old varicose veins of the leg are present, excision and skin grafting succeeds quickly, but the ulcer is very apt to recur, or others form, unless the tissues can be restored practically to normal by proper treatment of the varicose veins. The same is true when chronic eczema exists. Simple, chronic ulcers occur almost always on the lower half of the leg, particularly over the tibia and near the malleoli. Ulcers occurring near the knee are always to be viewed with suspicion, as this is the favorite location of *syphilitic ulcers*. These are apt to be multiple and either circular in form or if due to the coalescence of several small ones to the form of a figure-of-eight or a trefoil, etc. They may result from the breaking down of gummata, hence their circular form. Their base is generally covered with a grayish exudate, looking not unlike wet chamois skin, with few or no granulations. The edges are precipitous, and somewhat undermined. When they have healed, there is left the evidence of their previous existence in the form of more or less circular scars, but the presence of such scars should not necessarily lead to a diagnosis of specific ulcer, in the case of another ulcer in the lower part of the leg, for a simple chronic ulcer, such as has been described, may occur in syphilitics, as well as in any one else, and heal under the same treatment, and while the patient may require syphilitic treatment, such treatment will have no more effect on the simple ulcer on the lower part of the leg, than it would in one who does not have syphilis.

Callus.—Callus, tyloma, tylosis, keratoma occurring on the palms of the hands and soles of the feet may be regarded as physiological. Callosities are the result of the natural tendency the epidermis of these parts has to become thicker as necessity requires. Any region covered by skin, however, if subjected to long-continued pressure and friction, may be the site of callus. On the soles of the feet callosities

may be congenital, then representing anomalies in the development of the skin. Hyperidrosis of the palms and soles is frequently an exciting factor in their production. Callus on the sole or palm may hide a wart and be so painful and rebellious to treatment as to give rise to suspicion of malignancy; this is the so-called "rose corn" of the chiropodist.

Callosities on the feet are usually situated on the sole over the heads of the metatarsal bones; in deformed feet, they develop wherever pressure and friction are brought to bear.

Callosities are the result of an effort on the part of the skin to protect itself against external irritation and it is usually exerted in response to friction or pressure.

Histologically there is hypertrophy and increase in the density of the horny layer. There may be thickening of the stratum granulosum. The mucous layer is, however, usually thinned and the papillæ flattened, as the result of pressure. The underlying corium may or may not show the changes of inflammation. Individuals who go barefoot and upon whose soles callosities have developed are also frequently exposed to cuts and injuries that may become infected. Such an infection, running its course under the heavy callus, may undermine it extensively and institute a widespread phlegmonous inflammation. Eventually, however, it may heal without causing any destruction of tissue or even leaving a scar.

Callosities, if causing no annoyance and the result of occupation, are better not treated, because they furnish needed protection. When painful or otherwise troublesome, they should first be soaked for half an hour in warm soap and water and the surface then pared off smoothly, or gradually dissolved away with liquor potassæ, after which it is a good plan to apply smooth layers of zinc oxide adhesive plaster over the surface. Hyde and Montgomery highly recommend, for the removal of callosities, soaking the part in warm oil, followed by the application during the night of a piece of soft flannel saturated with oil. Flexible collodion containing 30 to 60 gr. of salicylic acid to the ounce may also be used to dissolve the callosity. The collodion is to be painted on each night for four or five successive nights, and on the following night upon soaking the foot in hot soap and water for half an hour, it will then be found that the sodden epithelium may be peeled off in layers. When the callosity hides a wart, after removal of the callosity as described above the wart must be either excised, cauterized carefully with nitric acid or removed by some appropriate method.

Callosities on the bottom of the feet in patients who suffer from hyperidrosis are very intractable, and are often the cause of great annoyance, making walking a continual source of pain, and because of the intractability of the hyperidrosis, their treatment is very unsatisfactory. The treatment of hyperidrosis is the first consideration, after which the callosities may be treated in the ordinary way.

"The most satisfactory method of treating such feet is the application of X-rays. These should be cautiously applied from day to day until the hyperhidrosis ceases. Usually this occurs and the callosities disappear without the production of any X-ray reaction" (Pusey).

Clavus.—Corns are an anomaly of cornification brought about by pressure from ill-fitting shoes or boots. They consist of localized thickenings of epidermis over enlarged papillæ and may occur on any part of the body which is subject to intermittent pressure, but are usually found on the feet of those individuals who have worn high-heeled, tight or pointed-toed shoes.

At first the corn is only a callosity but soon becomes a cone-shaped mass, with its apex pointing toward the papillary layer of the skin. Two forces are at work to bring about this change, the upward growth of the epithelial cells from the papillary layer and the pressure from without, which holds these cells down. The corn presses down upon and finally between the papillæ, forcing them apart. As these papillæ are supplied with highly sensitive nerve endings, the pressure from the hard epithelial cone is exquisitely painful. Long continuance of this pressure not only separates the papillæ but causes them to atrophy, as it does the connective tissues of the skin, and nature to protect herself sometimes develops a synovial sac or adventitious bursa beneath the corn. In paring a corn which lies upon a joint, great care should be exercised in order that a bursa which may lie beneath it be not infected. Infection and suppuration may occur beneath a corn, the pus being prevented from escaping by the hardened cuticle. It gives rise to great tension, pain and consequent inflammation of the surrounding skin and subcutaneous tissues. Phlegmon and ulceration may result.

Two varieties are described, the *hard* which occurs most frequently over bony prominences of the foot and toes, and the *soft* which occurs on the lateral surfaces of the toes. The two are identical, except that the heaped up epithelium around the soft corn is macerated and kept soft by the moisture between the toes and is whiter than the surrounding skin, while the conical plug is yellow and rather soft.

Removal of the hardened epithelium with salicylic acid paste,

salicylic acid collodion, or by paring, as in the treatment of callosities, is first to be done and then the conical plug is to be dissected out with a sharp pointed knife. Recurrence can be prevented by changing the shape of the shoe or protecting the bony prominence by a corn plaster.

In the treatment of soft corns they should be allowed to become dry and hard by keeping the toes separated with cotton or lint and dusting them with oxide of zinc or some other form of astringent and mildly antiseptic powder, and then treated in the same manner as hard corns.

The paring of corns with a knife, if the sufferer be senile or the victim of some disease, as diabetes, which lessens the caliber and expansibility of the blood-vessel, may result in infective gangrene should the corium of the toe be cut into and the knife not clean. In the young and healthy, erysipelas or lymphangitis have resulted from this accident. Those who are suffering from arteriosclerosis or diabetes should be cautioned against paring their corns, as a slight wound of the corium inflicted in this way may result in gangrene.

Ingrowing toe nail usually occurs on the great toe and is the result of two sins, one of commission and one of omission—the first, wearing of tight shoes, the second not being careful to cut the nail straight across. If inquiry be made, it will be found that when the first pain was experienced the tight shoes were not discarded, but the corner of the nail was trimmed off along the ungual fold in order to relieve pain. This cutting is repeated and each time it is done the ungual fold is forced farther and farther over, until the irritation, ulceration and infection following the pressure against the sharp nail result in the growth of exuberant granulations and the appearance is as if the nail had grown into the flesh. The disability brought about by it is very considerable and out of all proportion to the simple character of the lesion.

Palliative treatment will be sufficient in the milder cases. It consists in wearing broad shoes which give the toes plenty of room and pressing back the exuberant granulations and protecting them from the sharp edge of the nail. This is best accomplished by a thin piece of dry sea sponge gently crowded under the sharp edge of the nail and repeated from time to time till the corner of the nail has grown out beyond the ungual fold. Its continued use is sometimes necessary to prevent recurrence if the nail is deformed. It is usually necessary to cocainize the toe before the strips of sponge can be crowded under the buried edge of the nail the first time. No other material is so efficient. In the more severe cases it will be necessary to remove half

or the whole of the nail. Avulsion of half or the whole of the nail may be done by splitting the nail longitudinally and tearing out one or both halves but is inefficient as the matrix is not removed and the new nail gives as much or more trouble than the old.

The proper procedure is the removal of the nail together with its matrix. Under general or local anæsthesia and artificial ischæmia a longitudinal incision is made in the mid-line almost as far as the joint and to the bone; this is joined by a horizontal incision also to the bone just beyond the joint and carried laterally well to the side of the toe. The flap is dissected from the nail and the bone back of it and held to one side by a tenaculum, the nail is split longitudinally and the half removed. The matrix is then carefully removed with the soft parts to the bone, especial care being taken to remove the portion in the deep angle of the wound. The flap is then turned back and held in place by two or three sutures. Granulations should be scraped away and a dry dressing should be applied which should not be removed till it is loose. The bed of the nail becomes covered with cornified epithelium and soon ceases to be sensitive.

BONES

Measurements of the Lower Extremity.—The length of the lower extremity is determined usually by measuring the distance from the anterior-superior spine to the tip of the internal malleolus, and, while this method is not absolutely exact, it is sufficiently so for practical purposes, and probably possesses as small a margin of error as any other. In normal persons there may be a difference in length of about a centimeter in the two extremities.

Another measurement often of service in determining the presence of abduction or adduction is the distance between the umbilicus and the internal malleoli. If abduction is present, this distance will be increased; if adduction, diminished.

Nélaton's line is a line drawn from the anterior-superior spine to the most prominent part of the tuber ischii, and when the hip is in semi-flexion, the line passes just about over the top of the greater femoral trochanter. In dislocation of the hip (generally) or in fracture or bending of the femoral neck, the trochanter rises above this line.

Bryant's triangle is the triangle formed by a perpendicular downward from the anterior-superior spine of the ilium, while the patient lies on the table (that is, the line runs antero-posteriorly), a per-

pendicular from the tip of the great trochanter to this line, and a line from the tip of the trochanter to the anterior-superior spine.

In testing for muscular atrophy, the circumference is taken of the thighs and calves at a given distance from the patella or from the anterior-superior spine of the ilium.

Periostitis.—Periostitis of the tibia, fibula and metatarsal bones, particularly the first and fifth, occurs as the result of trauma or of hematogenous infection without trauma. *Acute periostitis* following injuries of these exposed bones may subside rapidly, although some tenderness and spontaneous pain may persist for a long time, as well as some thickening. If a hematogenous infection of the extravasated blood occurs, suppuration usually results. In some cases, however, particularly of the femur, the virulence of the organisms is very slight or the resistance of the tissues very great, for active suppuration does not take place, but a collection of serous fluid containing but few organisms follows and the symptoms are mild in comparison to those of suppurative periostitis. This is the form known as *serous periostitis*. It may pursue a very chronic course and be followed by more or less superficial necrosis. In some cases the fluid becomes encapsulated constituting what is known as a "*periosteal ganglion*." Whether the symptoms are severe or mild, early free incision through the periosteum gives the speediest and most certain relief.

Incision is sometimes called for in cases of old traumatic periostitis of the tibia in which suppuration has never occurred, but pain has persisted for many months after the injury. Longitudinal incisions, one or two in number, should be made, splitting the periosteum, and these should be lightly packed. Chronic periostitis from long-continued irritation by badly fitting footwear may occasion considerable formation of new bone. This is particularly apt to occur at the distal ends of the first and fifth metatarsal bones, gives rise to deformity of the feet and toes and to much pain. A good shoemaker may be able to remedy the cause and if this is done early enough, the development of Hallux valgus and resulting excision of bone may be prevented.

Acute Osteomyelitis.—According to statistics gathered in the Tübingen clinic more than 80 per cent. of the cases of this disease occur in the long bones of the lower extremity. The cases in the tibia slightly exceed those in the femur, while those in the fibula amount only to 3 per cent. of the total. In the femur the lower end of the shaft is the usual seat of invasion; in the tibia both ends are affected about equally. It occurs most frequently between the ages of 6 and 14.

The disease usually begins with severe pain in one end of the femoral or tibial shaft. The pain increases rapidly and in 24 hours may be intense. The temperature is high, often reaching 104° or more. Leucocytosis is high. Palpation and tapping reveal an area that is extremely tender. In a few days the affected region is swollen, the skin shiny and the superficial veins dilated. The skin becomes red only when pus not merely has made its escape from the medulla, but has perforated the periosteum and is close to the surface. The neighboring joint often becomes swollen. The further course of such a case with its cloacæ (Fig. 384), sequestrum and involucrum, is beautifully described by Lexer.

FIG. 384.—Osteomyelitis of the tibia.

In the moderately severe cases the disease has been confounded most frequently with acute articular rheumatism. Such an error is easily made, because by a number of patients the pain is referred to the adjoining articulation, and because an effusion may also appear later in that joint. In the differential diagnosis the following points should be considered; in osteomyelitis the source of infection is usually to be found; there is a high leucocytosis with increase of neutrophiles; pressure reveals an area of exquisite tenderness in the bone, not the joint; with care the surgeon can move the joint without giving the patient pain. In contrast with this, in acute articular rheumatism the swelling of the joint coincides with the pain; no movement of the joint can be made by the surgeon without great suffering; the leucocytosis is insignificant; the disease is likely to be polyarticular. In the grave cases of osteomyelitis the sepsis may be so severe that stupor appears before the local symptoms in the bone become evident; then confusion with typhoid fever may occur. The onset is

sudden in the bone infection, gradual in typhoid. There is the leucocytosis of osteomyelitis, the leucopenia of typhoid. Finally in a blood culture there may be found on the one hand the typhoid bacillus, on the other, one of the pyogenic organisms. When osteomyelitis is due to the extension of infection from the periosteum into the medulla (most frequent in thetibia) the diagnosis is to be made by operation as will be described subsequently.

In the most grave cases the disease quickly causes death and the diagnosis is made at the necropsy. In the moderately severe cases the amount of bone that dies varies from a small portion to the whole shaft, depending upon the virulence of the infection and the promptness with which operative relief is afforded. The disability and the deformity following a healed osteomyelitis varies with the extent and the position of the bone lost. The photograph (Fig. 385) shows well loss of bone and consequent deformity in a case which appeared recently in the surgical clinic of Stanford Medical School. The attack of osteomyelitis occurred four years ago, in a boy, now 14 years old.

Fig. 385.

Just as soon as the diagnosis is made the medulla should be exposed, for the longer the delay, the greater the destruction of bone. The guide to the incision is the area of greatest tenderness. The periosteum is split; an opening is made through the cortical substance with a small trephine, or better with a gouge and chisel, and these latter instruments used to enlarge the opening until sound medulla is reached. The free exposure of the diseased medulla is all that is needed. No curetting of it is to be done, as sound osteogenetic cells would be removed with the diseased. With such free exposure, the pain lessens, the fever subsides and the patient enters upon the stage of waiting for the time at which it is best to remove the necrosed portion.

In a case which presents great swelling and redness of leg or thigh, especially with a history of injury with abrasion, it may be impossible to determine whether the case is primarily osteomyelitis with secondary infection of the soft parts, or a diffuse phlegmon with possible subsequent infection of the bone. An incision should be made down to the periosteum. If bare bone is found, an opening should be made into the medulla in the manner already indicated, and if pus is discovered, the

whole infected area of medulla uncovered. If the examination of the medulla is negative, the opening should be lightly packed with iodoform gauze. When in doubt the safer procedure is to expose the medulla.

After a period of waiting, during which new bone (involucrum) has been forming between the periosteum and the dead bone, and the demarcation between living and dead bone becomes evident, the time arrives for the removal of the dead portion. When the sequestrum is small, there is no difficulty. When, however, the femur is the seat of disease and a considerable portion of the shaft is lost, the time to operate is of great importance. There is the danger of a useless limb through too early an operation, and a bone cavity that will never heal through too late a one. In the tibia, which has the support of the fibula during the period in which the new bone is forming, we can operate earlier, from three to six weeks after the acute symptoms have subsided. The incision through which the medulla was opened is lengthened and the thickened periosteum stripped back gently with an elevator. A small sequestrum is easily removed with gouge and forceps. If the entire circumference of shaft is necrotic, perpendicular incisions in the periosteum will be needed to permit its reflection. The division is made above and below the necrotic segment through sound bone by means of a Gigli saw. The reflected periosteum is sutured with drainage and so also the remaining soft parts. The leg is placed in a fenestrated gypsum cast. The time required for regeneration is from two to four months. When the femur is the seat of the disease and there is reason to believe that the whole circumference of the bone is involved, it is advisable to delay the removal of the necrosed shaft longer than when the tibia is involved. The new formed involucrum thus secures a rigidity which prevents deformity and shortening. But too long an interval must not be allowed to elapse or the osteogenetic power of the inner layer of periosteum bone will be lost and we may have a discharging cavity which cannot heal. With a needle one can best determine the rapidity and the depth of the ossification. When this is believed to have advanced enough to give sufficient rigidity, the incision is again opened widely, the involucrum chiselled away sufficiently to expose the sequestrum which is then removed. After removal of the sequestrum it is imperative that all overhanging edges of the defect be removed so that the sides and edges of the cavity slope toward the bottom. If it is possible to accomplish this, the cavity will fill up with granulations and no portion of it will be converted into a pocket by the closing in of granulations over it. In the shaft of the tibia the resulting trough will grad-

ually be covered with epithelium, extending from the skin edges, or the process may be hastened by covering the surface with Thiersch grafts at the time of operation or later, when the surface is covered with granulations. It may be treated after the method of Neuber described below.

If the patient be weak and anæmic from long-continued suppuration and often fever from inadequate drainage, it may be best to stop with the removal of the sequestrum and complete the operation at a later period. It is not necessary to curette the granulations underlying the sequestrum; this is as dangerous as to curette the wall of a pyogenic abscess. In most cases sequestrotomy should be done under artificial anæmia.

If the cavity be in the head of the tibia or the lower extremity of the femur, or in an involucrum formed around the shaft of the femur, other measures may be needed, and these, moreover, are likely to fail. They have as their basis the introduction of a substance into the cavity which will become organized or form a medium into which tissue will grow. As a preliminary to this the cavity must be most accurately cleansed and rendered aseptic. It is because of the extreme difficulty in securing this asepsis that these methods fail. The methods by which it is attempted to secure asepsis are: first after thorough curetment, mopping the surface with pure carbolic acid followed after a minute or two by alcohol; second, by mopping the surface with sponges dipped in boiling water; third, by mopping the surface with tincture of iodine; fourth, by drying the cavity with hot air (Sillermarck). This latter method can be accomplished by a hot air blast, or by use of a paquelin cautery, and gives an encouraging number of successes. After preparation of the cavity one of the following methods of filling the defect may be employed.

Schede's Method.—The cavity is allowed to fill with blood after the skin has been sutured over it; no drain is to be used, but a space is left between sutures for the escape of excess of blood, which is absorbed by an abundant sterile dressing, left in place until the incision has healed. The blood is supposed to coagulate and subsequently become organized and afford a framework for development of granulation tissue, and ultimately scar tissue, *i.e.*, bone. The clot usually suppurates or liquefies and in either event the healed incision reopens and the attempt fails.

Neuber's Method.—The edges of the defect are beveled as much as possible, and then flaps of skin are slid into the defect from each side and held in place by nails or by silkworm-gut inversion sutures. The flaps are to be freely separated from the deep fascia and sliding permitted

by two long incisions parallel to the edges and 2 or 3 in. from them. In some cases a pedunculated flap may be employed.

Senn's Method.—After preparation the cavity is dusted with iodoform and filled with iodoformized, decalcified bone chips over which the skin is sutured. Others use fresh bone chips or larger inserts. The procedure generally fails from inability to secure perfect asepsis and the same is true of most of the other materials used, such as formalin gelatin (Schleich), plaster of Paris, amalgam, bismuth paste (Beck), boiling oil and sterile water. The least unsuccessful is the "bone wax" of Mosetig-Moorhof. This is a mixture of iodoform 60 parts, spermaceti 40 parts and oil of sesame 40 parts, gradually heated to 212°F. and allowed to cool, whereupon the mixture becomes solid. For use it should be melted at a temperature of about 120°F. and poured into the previously prepared bone cavity, stirring it while pouring. It fills in the interstices of the defect and solidifies almost immediately. This material has been known to keep its place and serve its purpose even when the soft parts could not be completely sutured over it.

Chronic Suppurative Osteomyelitis.—The chronic suppurative process consequent upon an acute osteomyelitis with necrosis is but a sequel of the acute affection, and has been considered under that head. There are several forms of chronic, non-syphilitic, non-tuberculous osteomyelitis, some of which are mildly suppurative, and some not suppurative at all. If there be an acute stage it is very mild and transient and often unrecognized. The symptoms are those that are also observed in some cases of acute osteomyelitis that have finally healed after sequestrotomy, namely, thickening of the bone, and continuous or intermitting pain of a mild character, without fever, persisting for years. There is often one or more small sequestra at the bottom of the trouble, unaccompanied by suppuration. Sometimes there are small abscesses which show no disposition to enlarge or to give rise to fever. More often there is only the great thickening and hardening described by Garré as *sclerotizing osteomyelitis*. The medulla is gradually encroached upon and the canal almost obliterated. In some cases, perhaps after an injury, perhaps without, a small abscess may form and possibly a small sequestrum be discharged.

The principal complaint is that of pain, described as of a dull aching character in the bone, ceasing at times for perhaps a year or more and then recurring with more or less severity over a period of many years. Temporary relief is sometimes afforded by splitting the periosteum or by removing a portion of the thickened bone, but complete relief can

be afforded only by subperiosteal resection of the whole affected portion of the bone and replacing it by an insert, over which the periosteum is sutured, or by removing with a chisel all but a slender strip of bone, sufficient to permit of handling the limb and to prevent shortening. In either case the bone will be regenerated in from four to six months.

Brodie's abscess is a chronic abscess developing in the head of the tibia or lower end of the femur from spores of staphylococci left behind after recovery from an acute osteomyelitis. These may have been latent for many years before giving rise to the abscess which is essentially chronic and is accompanied by enlargement of the bone and sclerosis in its vicinity. The abscess finally perforates the bone, either beneath the periosteum or into the neighboring joint. The cavity left after its evacuation should be treated according to one of the methods described under acute osteomyelitis. The above conditions may be sometimes difficult to differentiate from syphilis, tuberculosis, sarcoma and bone cyst without exploratory incision and microscopic examination (*vide* Lexer).

The manifestations, in the bones of the lower extremity, of certain constitutional diseases are marked. The bowlegs and knock knees of rickets are well known. In "*osteomalacia*" and "*osteopsathyrosis ideopathica*," the thigh and leg bones suffer frequent fracture. In Paget's deforming osteomyelitis, the tibiæ and femora are thickened and bowed. In *chrondrodystrophia fœtalis*, the legs are short and stubby and the bone are short and thick.

Spurs and exostoses are sometimes formed on the under-surface of the calcaneus, giving rise to a condition known as "painful heel." Pure cultures of gonococci have been recovered from cases of this kind, but in some instances the affection seems to be caused by strain upon the plantar fascia in flat feet, and yields to appropriate treatment along this line.

Osgood's Disease, Schlatter's Disease.—Osgood (Lesions of the Tibial Tubercle Developing during Adolescence, Boston Med. and Surg. Journ., 1903) has described a peculiar condition of the front of the head of the tibia, found occasionally in adolescents. He ascribes it to a partial avulsion of the tibial tubercle. It is characterized by pain and slight swelling over the tibial tubercle, and is diagnosed by the symptoms and by the X-ray.

Treatment by crisscross strapping will usually be found efficacious. Schlatter and Jacobsthal call attention to the fact that the symptoms disappear with the ossification of the epiphysis in this situation.

Acute Infective Synovitis and Arthritis.—The term "synovitis" is used to denote a primary inflammation of the synovial membrane, the ligaments and other structures of the joint being but little affected. If the inflammatory process advances so that other structures of the joint (*e.g.*, cartilages, bone and ligaments) are involved, the condition is known as "arthritis." These terms are often used synonymously. While the term "synovitis" is used to denote an inflammation which is supposed not to have extended beyond the limits of the synovial membrane, the employment of the term is not strictly correct for there is no way of telling, in many cases, whether or not the inflammatory process has remained confined to the synovia, and a synovitis is essentially an arthritis. Yet clinically the term "synovitis" has its use, for if the synovia bear the brunt of the infection and the other structures of the joint are but little affected, good functional results may follow, whereas involvement of the bone ends, erosion of the cartilages and the formation of adhesions seriously impair function or result in complete ankylosis.

The Hip-joint.—A large number of cases of primary synovitis of the hip accompany or follow the various infectious diseases, *e.g.*, acute rheumatic fever, gonorrhœa, typhoid fever, pneumonia, scarlet fever, measles, etc. That the condition is produced by the specific organisms of some of these diseases, has been demonstrated by the recovery from the joint effusion of the diplococcus rheumaticus, gonococcus, typhoid bacillus, pneumococcus and certain strains of streptococcus in pure culture. In some cases, *e.g.*, gonorrhœa, where the effusion has been sterile, the specific organisms have been found in the synovial tissue. The specific organisms of the acute infectious diseases apparently produce the milder grades of inflammation. In the more severe suppurative types, the streptococcus or staphylococcus is found alone or together with other organisms. The effusion in cases of *infective synovitis* is rarely purely serous, the leucocytes being increased so as to render the fluid opalescent or cloudy. The synovitis may be of the serous, sero-fibrinous or mild suppurative types. The synovia is hyperæmic, thickened and spongy. In the serous type the exudation of fluid into the joint predominates and may be quite marked (gonorrhœa, typhoid fever). The fluid may be completely absorbed and the joint returned to its normal condition. In the hip-joint extensive effusion often causes spontaneous backward dislocation. The cause of this is apparently to be found in the distention of the capsule, which, because of the tense Y ligament anteriorly, becomes most

marked posteriorly (typhoid fever). The effusion may persist and chronic serous synovitis results. If, however, there is but little fluid poured out into the joint cavity, but chiefly an infiltration of the synovia, with a sero-fibrinous exudate (gonorrhœa, adhesive form), shrinkage of the capsule takes place and stiffness or ankylosis of the joint results. In some of the infectious diseases (scarlet fever, measles, etc.) a purulent infiltration of the synovial membrane may occur in the hip-joint, but the inflammation often runs a mild course and remains confined to the synovia. When this occurs, shrinkage of the capsule with consequent functional disturbances rarely results, provided early incision and drainage are carried out. If the organisms are of a higher degree of virulence, especially if the acute synovitis is due to the ordinary pyogenic cocci, the inflammation may spread rapidly to the bone marrow and give rise to an acute arthritis. On the other hand, the inflammation may begin in the bone marrow and spread to the synovia. Acute osteomyelitis of the upper end of the shaft of the femur is usually followed by acute arthritis of the hip-joint. This is favored by the fact that the epiphyseal cartilage is intracapsular. Without early and efficient surgical interference the cartilages are destroyed, the capsule becomes softened and ruptures and pus may make its way between the muscles along the fascial planes or come to the surface at any of the localities for hip-joint abscesses. If the patient survives, the head of the femur may be detached and lie free in the disorganized articular cavity.

Symptoms.—At the height of one of the infectious diseases or during convalescence, inflammation of the hip-joint may occur. In many cases the affection of this joint is preceded by temporary attacks of pain in other joints, occasionally with a rise of temperature. The joint becomes painful and swells. Swelling is due to the effusion, and this may be slight or marked. With a large effusion spontaneous dislocation may occur.

Fluctuation is difficult to elicit in the hip-joint and only exceptionally is it obtained over the anterior surface of the joint. Examination reveals a little fullness and tenderness in the gluteal region or in the upper and outer part of Scarpa's triangle. Heat is present in varying degrees; the skin may or may not be reddened.

A characteristic feature is the attitude of the limb. This is maintained by muscular spasm in the position which gives the greatest ease; the thigh is flexed and adducted (flexion abduction and eversion is the position given by some). Limitation of movement is equally

marked. The constitutional symptoms may be slight or are those of the primary disease. When an acute suppurative synovitis or arthritis develops, the symptoms as a rule become more marked.

Pain and swelling increase; redness of the skin becomes evident; the temperature generally rises. The fever is usually ushered in by rigors, is of the septic type, and prostration is marked. Leucocytosis is present and usually high. Anæmia develops rapidly. Aspiration reveals a purulent exudate. When arthritis develops as the result of osteomyelitis, the onset is usually sudden. Children or young adults, apparently in good health are suddenly affected with high fever, often accompanied with chills. Motion in the hip-joint is lost. The patient complains of intense pain in the hip or pain may be referred to the knee, as in tuberculous disease of the hip-joint. Pain is increased by pressure over the trochanter or upon the sole of the foot. The slightest movement causes severe pain. The joint is fixed by muscular spasm. An œdematous and boggy swelling soon appears at the hip especially in the gluteal region. The thigh becomes swollen and the symptoms of sepsis appear early. Exceptionally, pain is slight. The patient is first noticed to limp and this increases gradually, the severer symptoms not appearing for several weeks.

Diagnosis.—The diagnosis of special forms of infective synovitis and arthritis will be given under that heading.

In acute arthritis of the hip-joint following osteomyelitis, tuberculous disease of the joint must be differentiated. If the onset be acute there is usually no difficulty, but if subacute the diagnosis is more difficult. Spontaneous dislocation, the coexistence of osteomyelitis in other parts of the body, bacteriological examination, and the X-ray are valuable aids to diagnosis.

Prognosis.—This depends essentially upon the nature and severity of the affection, and upon the treatment. In the milder forms of acute serous synovitis following the acute infectious diseases, the prognosis is good as a rule, but if the effusion be considerable, the capsule and ligaments may be stretched, and a weak and irritable joint is likely to remain. The tendency of gonorrhœal involvement of the hip to fibrous ankylosis is marked. In the purulent forms of synovitis, a certain amount of stiffness generally follows, but proper treatment will often restore the normal function, especially in the case of children.

Suppurative arthritis of the hip is always a serious affection. If the patient survive the acute stage, exhaustion, septicæmia or pyæmia

may follow and cause death and even if the inflammation is controlled by early and efficient treatment, permanent changes left in the joint seriously impair function.

Treatment.—It is essential to ascertain the exciting cause, as the nature of the treatment will depend upon the diagnosis. For instance, in acute rheumatic fever, the joint affection responds readily to the action of the salicylates. In gonorrhœal arthritis, attention must be directed to the causal lesion in the genito-urinary tract. Locally, in the milder cases (serous or sero-fibrinous synovitis), complete immobilization by a plaster-of-Paris spica should be secured. When there is considerable exudate present, aspiration is often beneficial. It relieves the pain and removes the pressure on the inflamed capsule. Extension by weight to keep the articular surfaces from pressing against one another is desirable, but the weight should not be too heavy, else the inflamed and softened capsule and ligaments may be stretched. Fixation is continued until the signs of acute inflammation have subsided. When local heat and tenderness have subsided and the exudate begins to be absorbed, massage, compression by elastic bandage, and careful passive motion will hasten absorption. When the effusion has disappeared, restricted but gradually increasing use of the protected joint is permitted; but only after the synovia has apparently returned to its normal condition, and the use of the joint is not accompanied nor followed by any serious degree of pain, is unrestricted motion allowed. Prolonged fixation favors muscular atrophy, and renders the joint weak and irritable. If there is any doubt concerning the character of the exudate, an exploring needle should be used. If a purulent exudate is present, free incision, irrigation of the joint with normal saline, and the establishment of thorough drainage are essential.

The joint should be immobilized in the position which will give the best functional results should ankylosis occur, that is, slightly abducted and extended; adduction and flexion should be avoided as favoring spontaneous dislocation. Drainage of the joint should be discontinued as soon as safety permits, and gentle passive movements, massage and baking should be begun as soon as the acute symptoms have subsided. If local and general symptoms continue and the destruction of the cartilages becomes more extensive, resection of the joint is indicated and may be the only effective surgical procedure.

If fibrous adhesions have formed, a careful attempt should be made to break these under general anæsthesia and to mobilize the joint. After breaking up adhesions, the extremity should be immobilized in

the correct position for a few days, after which gentle passive motion, massage, baking, etc., should be begun. Renewed effusion often follows this procedure, especially after long immobilization, but if slight, it should not discourage careful movements. If marked and accompanied by pain, the joint will require further immobilization. Adhesions are quite apt to reform. Where this procedure proves a failure or where ankylosis is complete, arthroplasty may give a useful articulation.

The Knee-joint.—Although frequently the result of trauma, infective synovitis and arthritis of the knee occur from extension of inflammation from the surrounding structures, *e.g.*, abscess, erysipelas spreading over the joint, acute periarticular phlegmon, suppurative inflammation of the prepatellar bursa or osteomyelitis oft he articular ends of the femur or tibia. It occurs also as a local manifestation of certain acute infections, *e.g.*, acute rheumatic fever, gonorrhœa, typhoid fever, scarlet fever, etc. In the milder degrees of infective synovitis, the synovia is reddened and swollen, and fluid is poured out into the joint cavity. In these cases the effusion is rarely purely serous in character, the leucocytes being increased in number so as to render it cloudy. Fibrin may be present in varying amounts. Small flocculi may be present in the fluid or the synovia may be covered with fibrinous deposits, from which fibrous adhesions are quite apt to form. Absorption of the fluid may be complete and the joint return to normal, or the ligaments may remain somewhat relaxed and a little passive effusion may persist, giving rise to a chronic serous synovitis. With the sero-fibrinous exudate, the fibrinous deposits on the synovia may undergo organization and fibrous ankylosis with marked impairment of function result. If adhesions form they may seriously impair the function of the joint. With an infection of greater severity, a suppurative synovitis or arthritis may result.

Suppurative synovitis, the so-called "catarrhal suppurative inflammation" of von Volkmann, is a mild form. It is caused most frequently by staphylococci and streptococci, less frequently by pneumococci, and occurs in small children. The inflamed synovia is infiltrated with leucocytes and a sero-purulent exudate is poured out into the joint cavity. If proper treatment is instituted early, there is little or no destruction of the synovia and the joint returns to its normal condition. Without early and efficient treatment the marrow becomes involved and a severe arthritis with destruction of the cartilages occurs.

Suppurative arthritis, though due chiefly to direct infection of the joint in wounds, follows a suppurative osteomyelitis of the articular

ends of the tibia or femur, and the joint cavity rapidly becomes filled with a purulent fluid varying in color from yellow to green. With the extension of the infectious process to the surrounding tissues, the ligaments become infiltrated, softened and destroyed. Partial or complete luxation of the ends of the bones results, abscesses form in the bone marrow, the bony trabeculæ are destroyed, the cartilages become œdematous, softened, fibrillated and eroded, the joint totally disorganized, and the condition proves rapidly fatal unless proper surgical procedures are instituted, and sometimes in spite of this.

With free incision and efficient drainage, infection usually subsides and repair takes place. As long as suppurative inflammation is confined to the synovia there is hope for good functional results, but as a rule, in the severer types of inflammation, the synovia is destroyed with portions or the whole of the cartilages, granulations arise, adhesions form, and there is partial or complete obliteration of the joint cavity with fibrous or bony ankylosis. In children the outlook for motion, in these cases, is more favorable than in adults.

Symptoms.—In the milder forms of an infective synovitis the clinical picture depends primarily upon the effusion. Effusion into the knee-joint is indicated by an obliteration of the normal hollows at the sides of the patella and ligamentum patellæ. Swelling is also present in the region corresponding to the subcrural pouch, more marked on the inner than on the outer aspect for 3 or 4 in. above the patella. The upper recess may be connected with the joint cavity by means of a narrow opening, and if the effusion is marked the swelling will assume an hour-glass appearance. Because of the firmness of the capsule posteriorly, swelling in the popliteal region is rare, but if the bursa between the tendon of the semi-membranosus and the medial head of the gastrocnemius or the one between the medial head of the gastrocnemius and the medial condyle communicates with the joint, the swelling is hemispherical and extends posteriorly and toward the side of the joint. Fluctuation varies with the amount of exudate present. As a rule, it is easily obtained in the knee, if the leg is extended and the muscles relaxed. Restriction of motion is due largely to pain, distention of the joint with fluid, and slight loss of power in the muscles occurring early in acute inflammation of the joint.

With considerable fluid the patella is floated or pressed away from the underlying bony surface, and fluctuation can be detected by alternate pressure with the fingers on either side of the quadriceps tendon. With the leg extended, the patellar tap or click can be elicited by sudden

backward pressure on the patella, thus causing it to strike the intercondyloid notch of the femur. With a slight amount of exudate the click can be obtained by pressing the fluid downward from the subcrural pouch. On the other hand, it may be prevented by tension accompanying a profuse exudate, but in this case the swelling is characteristic. If the bursa behind communicate with the joint, through fluctuation may be elicited. Effusion into the prepatellar bursa is recognizable by the central position of the swelling in front of the patella, which renders the outline of the latter obscure. With considerable fluid in the joint the knee is usually held in a slightly flexed position.

In the serous type of synovitis the soft parts may remain unchanged. The skin may be normal in color or a reddish flush is seen, and local heat is present in a slight degree or more marked as in acute rheumatic fever. Pain and tenderness vary. They are quite severe in some cases (gonorrhœa and acute rheumatic fever), slight in others (typhoid fever). There may be only a slight fatigue or weakness of the joint, or function may be markedly disturbed because of pain or swelling. Fever corresponds to the general infection or to the inflammation adjacent to the joint. It may be high—102°–104°F. in acute rheumatic fever or gonorrhœa without suppuration. High fever, especially if continuous and if not explained by complications elsewhere, should always arouse suspicion of suppuration. Aspiration may confirm the suspicion. If suppuration takes place, it is often attended by one or more chills. The local signs and symptoms increase rapidly. Pain is more severe, the tenderness increases, and the slightest jar causes agony. Flexion increases to a right or an acute angle. The skin becomes red, hot and œdematous. Swelling is marked and is often accentuated by thickening of the soft parts about the joints.

Diagnosis.—Synovitis and arthritis of the knee are easily recognized. The important point is the determination of the exciting cause, and this can usually be found if a careful local and general examination is made.

Prognosis.—As in other joints, this depends upon the nature and severity of the affection and upon treatment. Complete recovery may occur in the milder cases, but even in the acute serous forms the hypertrophied villi may become fibrous, cartilaginous or osseous and give rise to the movable or free bodies so common in this joint.

Because of the extensive synovia with its recesses, the knee-joint is quite difficult to drain thoroughly, and suppurative synovitis rarely ends in complete recovery except in children. Gonorrhœa affects the

knee more frequently than other joints and fibrous ankylosis is quite likely to result.

In the severer forms of suppurative inflammation following osteomyelitis with destruction of part or the whole of the cartilages, a stiff joint is the best for which we can hope. Deformities are quite difficult to prevent in the knee-joint. Contractures, backward dislocation, a valgus or varus position may result.

Treatment.—Treatment in general is the same as just given for the hip and is directed toward the cause. Locally the joint should be immobilized by a posterior splint or traction should be applied. Immobilization in plaster of Paris is used only where pain is great and the effusion is slight. An ice-bag to the joint is serviceable in the acute stage. If absorption is slow and tenderness is slight, compression by bandage and gentle massage are indicated. If the exudate is large or if a sero-purulent exudate is present, aspiration of the fluid, lavage of the joint with normal saline followed by slight compression, and immobilization for a few days are sufficient. Because of the difficulty in overcoming stiffness, mobilization of the joint should be begun at the earliest possible moment. Gentle passive movements, massage, baking, etc., are valuable. Active use of the joint in walking is not permitted until motion is free from pain. If suppuration develops, the diagnosis is easily established by aspiration, and free incision and drainage should be instituted. Two longitudinal incisions are usually sufficient. In severe cases, however, or where imperfect drainage exists, a U-shaped incision should be made. In this the longitudinal incisions are united by a transverse one through the ligamentum patellæ and the joint thoroughly exposed by turning up the patella. The knee should be fixed in extension. If arthrotomy does not suffice, and especially if the cartilages are involved, resection of the joint is indicated. If the suppurative process extends rapidly or symptoms of general infection appear, amputation is called for. Ankylosis of the knee has been successfully treated by arthroplasty.

The Ankle-joint.—Acute, non-traumatic inflammation of the ankle-joint occurs in a number of infectious diseases, notably among which are acute rheumatic fever and gonorrhœa.

Suppurative inflammation often follows an acute osteomyelitis of the lower end of the tibia (Fig. 386), rarely an osteomyelitis of the astragalus. It may follow a suppurative tenosynovitis of the neighboring tendons and it occurs by pyæmic metastases. The changes which take place in the synovia, bone marrow or cartilages are the same as

those occurring in infective processes in other joints. There is a marked tendency in inflammation of the ankle-joint to the development of tenosynovitis of the neighboring tendons.

Symptoms.—Effusion into the ankle-joint is not so easily detected as in the knee. Acute effusion, as a rule, first distends the capsule anteriorly and swelling is seen in front beneath the dorsal tendons and in front of each malleolus. If the soft parts are but slightly involved, the swelling is sharply circumscribed and fluctuation may be obtained.

FIG. 386.—Osteomyelitis of tibia.

Later, swelling appears posteriorly. The hollows between the tendo-Achillis and the malleoli are obliterated by fluctuating swellings. The foot may assume the position of slight extension and inversion. Pain, tenderness, and restriction of motion vary with the degree of inflammation. These are, as a rule, marked in acute rheumatic fever and gonorrhœa. In the latter there is frequent involvement of the tendon sheaths. The skin is generally reddened and hot. When suppurative

inflammation occurs, the symptoms become more severe. Pain, tenderness and swelling become more marked. The skin is red, hot and œdematous, and aspiration shows a purulent exudate.

General symptoms vary with the severity of inflammation. There may be slight or no increase in temperature or the temperature may be that of the primary condition. In the suppurative conditions, the symptoms of sepsis and high fever may make themselves evident early.

Treatment.—The general treatment is the same as given for the hip and knee. Mild forms of synovitis are treated by rest and the application of cold. In immobilization of the ankle-joint, the foot should be placed at a right angle to the leg and midway between inversion and eversion, which position gives the best functional result if ankylosis occurs.

If suppuration occurs, early incision on either side of the extensor tendons in front of, and also behind, the joint is indicated. As the ankle is difficult to drain freely, it may be necessary to excise the astragalus.

If osteomyelitis is the cause of the joint trouble the focus must be cleared out and drained, in addition to the drainage of the joint. Amputation may become necessary in the severe cases with the occurrence of extensive phlegmons, osteomyelitis or general infection.

Chronic synovitis (*hydrarthrosis, dropsy or hydrops of the joint*) occurs frequently as the result of acute synovitis, of either traumatic or infective origin. If the acute condition has been of infective origin, the organisms may survive with attenuated virulence, or if these have disappeared, the results of the inflammatory process, *e.g.*, hypertrophied synovial fringes, persist and serve as mechanical sources of irritation. Chronic synovitis is more frequently the result or symptom of some other disease of the joint than an independent clinical entity. It arises as the result of certain infective processes, such as gonorrœha, syphilis, tuberculosis and arthritis deformans, or from some general *disturbance*, the etiology of which is not clear, such as hemophilia or gout. It occurs also as an intermittent affection of unknown etiology. It occurs secondarily to sarcoma involving the joint.

The synovial membrane is vascular and thickened and the villi hypertrophied. A variable amount of serous exudate is present in the joint. The subsynovial tissues undergo similar changes, the capsule is thickened and becomes distended, and eventually the capsule and ligaments become relaxed with a resulting loss of stability of the articulation.

This latter condition is of itself a further source of irritation to the joint. The condition develops gradually and may remain stationary for a considerable period or even subside spontaneously if proper care is exercised. Exacerbations are quite frequent, however.

Hip-joint.—Chronic synovitis of the hip-joint may result from any of the causes producing synovitis. It may follow an acute synovitis, the effusion persisting and the joint remaining irritable and tender, or it may come on so insidiously that the patient is unable to tell when the trouble began. It occurs in children and adults. In the former it frequently follows tonsillitis, diphtheria and other throat infections; in the latter the causation is often referable to gonorrhœa, syphilis, etc. The patient complains of pain, which is often slight or present only after exercise. This is felt in the hip-joint or referred to the knee. The movements of the joint are limited. The thigh is flexed and adducted or abducted. When the patient walks, a limp is observed. The skin over the joint is of normal color and, because of the depth of the joint, increased surface temperature and fluctuation are absent. In children the condition resembles clinically tuberculous disease of the joint, and it is only by careful and prolonged observation and noting the effect of treatment that the diagnosis is established. The X-ray is of service in ruling out tuberculous disease.

Treatment.—If due to syphilis, gonorrhœa, etc., these conditions must be treated. In children the condition is treated in the same way as tuberculosis; in adults by rest to the joint, traction if necessary, counter-irritation, protection by apparatus, followed by massage. Active and passive motion are indicated, but care should be exercised not to use the joint too early.

The Knee-joint.—Of the various joints, the knee is most frequently affected by various forms of synovitis and arthritis. Besides the mechanical causes of irritation, such as loose bodies, displaced semilunar cartilage, etc., chronic serous synovitis is often seen in infectious processes, notably in gonorrhœa and syphilis. As a sequel of acute synovitis or as a primary joint affection in gonorrhœa or syphilis, the joint is swollen, tender to pressure, and a varying degree of pain is present. The skin over the joint is normal in color and, because the joint is superficial, heat may be detected and fluctuation easily obtained. Motion is limited, flexion occurs and passive motion often elicits joint crepitus. Atrophy of the muscles associated with the joint is common. The patient complains of a sense of fullness in the joint, that it is weak and insecure and that slight pain is experienced, especially after exertion.

The condition improves with rest and becomes worse again after exertion or a slight twist.

Treatment.—The cause must be found and treated. If the result of an acute synovitis, and pain and tenderness persist, traction and fixation are indicated. Compression by bandage, mild degree of counter irritation and massage will hasten the absorption of the exudate. In cases not influenced by these procedures, operation is indicated.

The Ankle-joint.—Chronic serous synovitis of the ankle arises from any of the causes of synovitis. In certain infective processes, *e.g.*, gonorrhœa, an accompanying tenosynovitis of the neighboring tendons exists.

Symptoms.—Varying degrees of pain and discomfort in walking are present. The exudate causes the natural hollows behind the malleoli to be obliterated. Increase of local temperature is often present, but without redness of the skin. Of the movements of the joints, that of dorsal flexion is limited. Joint crepitus is obtained by passive motion.

Treatment.—Treatment consists in the removal of the cause, in rest, massage, stimulation of the local circulation, and support to the joint if necessary. Use of the joint should be gradual. In less severe cases, prolonged rest is undesirable. Massage and passive motion should be begun early.

Intermittent synovitis, intermittent hydrarthrosis or hydrops are terms applied to an infrequent though well-recognized affection of the joints, of obscure etiology. It is independent of any clearly defined local or general condition. The condition is characterized by a non-inflammatory serous effusion which occurs at more or less regular intervals, continues for a definite time and subsides spontaneously. The striking feature of the affection is the periodicity of the attacks; so regular is this in a given case that the patient is often able to foretell the time of onset. The periodicity varies, although each case has its own cycle which is remarkably regular. The swelling begins at a certain time, reaches its maximum within a given period and occupies a constant interval in its recession. The cycle commonly occupies 10 to 15 days, though it may be much shorter. Attacks may cease as suddenly as they appeared, and there may be no recurrence for many weeks or months. There is a tendency to spontaneous recovery, in most cases after varying intervals, such intervals often extending over many years. The condition is most commonly met with in early life, and females seem to suffer more than males. The knee is the joint most often affected. Symmetrical joints (knees, ankles) may be affected, and when this occurs the

swelling alternates as a rule, so that when one joint is at its maximum the other is free from enlargement. Swelling is due to infiltration of the capsule rather than to any considerable effusion into the joint sac. Save for a little thickening and laxity of the capsule there are no definite changes in the joint. Functional disturbances may result after the attacks have been repeated for a considerable time.

Symptoms.—The onset of the swelling is abrupt, and there is moderate tenderness to pressure. There may be a slight increase of surface temperature. The onset of the swelling may be preceded by neuralgic pains; less frequently severe arthralgia accompanies the effusion. As a rule, however, the affection is not very painful, and the chief discomfort is from distention of the joint and stiffness which accompanies it. Motion is not restricted save at the height of swelling. Active and passive movements of the joints are not painful, and crepitation is seldom felt. Atrophy of the muscles is uncommon. Effusion in most cases is absorbed, only to return during the next attack. When the attacks are repeated frequently a certain amount of fluid remains permanently.

Treatment.—No satisfactory treatment has been formulated. Prolonged rest does not seem to have any beneficial effect in preventing recurrence. Quinine and arsenic have apparently proved efficacious in some cases. Hydrotherapy has been used with some success, but as spontaneous recovery has occurred without treatment, it is difficult to determine the value of these therapeutic agents.

Special Forms of Infective Synovitis and Arthritis.

Acute Rheumatic Synovitis.—Of the acute inflammations of the joints that which occurs in acute rheumatic fever is the most frequent. Although the disease belongs to the province of the internist it is most important that the surgeon keep the condition in mind when confronted by an inflamed joint, for various forms of infective arthritis have been diagnosed as rheumatism, mistakes which, in some instances, have cost lives. It has been proved that the condition is an infective synovitis. A number of investigators (Poynton and Paine, Walker, Cole, Beattie, *et al.*) have shown that from the joint effusion, the tonsils, the endocardial vegetations and sometimes the blood, organisms may be obtained, which, when inoculated into animals, cause a condition very similar to acute rheumatic fever, with synovitis, endocarditis and even fibrous nodules. Considerable confusion has existed in the minds of many because the organisms described by different investigators have not coincided. Rosenau has shown, however, that the

same organisms may be changed by cultural methods, so that they may in mediums show progressive phases of transmutation. A careful history will often elicit the fact that the patient has suffered previous attacks, and examination may reveal legacies left by these, *e.g.*, organic mitral disease. A history pointing to several attacks of tonsillitis, torticollis, chorea, rheumatic erythema, or the presence of nodules will be helpful.

There are no characteristic changes in the joints. The synovial membrane and ligamentous tissues are hyperemic, and the joint cavity contains a turbid fluid. Suppuration does not occur and the joint returns to its normal condition. A distinguishing feature of the disease is its abrupt onset. This may be preceded by irregular pains in the joints, slight malaise, sore throat, and particularly by tonsillitis. A definite rigor is uncommon, the temperature rises rapidly, several joints become painful and within 24 hours of the onset, the disease is fully manifest. Several of the larger joints (*e.g.*, knee, ankle, shoulder, wrist, elbow or hip) are affected first and chiefly, although in very severe cases the smaller joints of the hand may be involved. The joints are not affected simultaneously, a special feature being the tendency of the inflammation to subside in one joint while increasing with great intensity in another. Symmetrical joints are often involved. This fleeting character of joint involvement is important and the diagnosis of acute rheumatic fever should not be made if only one joint is affected. The inflammaotry process subsides rapidly, a condition which does not, as a rule, obtain in other forms of infective arthritis. Pain is very severe, and is increased by the slightest motion. The swelling is usually moderate, and, as a rule, limited to the joint proper, but in the ankle it is sometimes increased by an accompanying tenosynovitis of the neighboring tendons. Local temperature is increased and the skin over the joint is flushed.

The general temperature rises rapidly with the onset and ranges between 102°–104°F. Anæmia occurs with great rapidity, there are profuse acid sweats of peculiar sour odor, and the sweating is quite apt to be accompanied by sudaminal vesicles. Moderate leucocytosis is present. The inflammation generally begins to subside in a few days, the joint returning to normal in about 10 days to two weeks. Because of its short duration, rheumatic synovitis is not accompanied by muscular atrophy. Rheumatic nodules are rare, but when present are of considerable diagnostic value. These are found in children affected with acute rheumatic fever and cardiac disease.

Syphilitic Arthritis.—Syphilis may affect the joints in a greater or less degree in every stage of both the acquired and congenital forms, and its occurrence is much more common than seems to be generally supposed. It occurs not infrequently in the joints of the lower extremity, most often in the knee. The types are varied and simulate other forms of arthritis, especially tuberculosis of the joints. The disease may exist in three well-defined forms and possibly in a fourth. It may manifest itself as a primary synovitis, as an arthritis, the primary lesion of which is either in the synovia or in the bone marrow, and as an arthropathy known as Charcot's disease.

While no conclusive evidence has been adduced to support the view, it is possible that syphilis is responsible for certain cases of polyarticular inflammations included under the rather loose term, "Progressive type of arthritis deformans." The pathological changes are ostensibly those of synovitis and osteomyelitis. In the early stage of acquired syphilis, either during the period of primary incubation, or during the period of secondary symptoms, several joints, hip, knee, ankle, shoulder, elbow, etc., may become painful. This so-called "arthralgia" resembles that which occurs in other infectious diseases, and as far as is known is unaccompanied by any anatomical changes in the joint. It is doubtful whether this is not a periarticular condition. Pain may be severe in and around the joint, and the only feature which may differentiate it from other conditions is that it is often worse at night. Pain is not increased by movement, in fact, it may be relieved by exercise of the joint. The range of motion is slightly, if at all, impaired. A little local tenderness may be present and the joint is, as a rule, a little stiff after the night's rest.

The Hip-joint.—Of the jonts of the lower extremity the hip is probably the least often affected by syphilis. In the secondary stage of *acquired* syphilis, the hip may be affected alone or simultaneously with other joints. The lesion is an acute or chronic synovitis. In many cases an effusion appears without warning and is usually associated with some pain and tenderness which is not increased by motion. It may be unaccompanied by any other sign or symptom of the disease, there being no constitutional disturbance. As a rule, neither pain nor tenderness is a prominent symptom. In some cases, however, there may be a good deal of local pain in addition to the effusion and if fever is present and several joints are involved, the condition may be mistaken for acute rheumatic fever or gonorrhœal arthritis.

From acute rheumatic fever the syphilitic synovitis is differentiated

by the presence of signs of syphilis, the absence of the fleeting character of the joint pains, absence of acid sweats and cardiac involvement, and lastly the mild character of the constitutional symptoms (J. B. Barret, British Journal of Children's Diseases, 1909).

In gonorrhœal arthritis, examination will usually reveal the primary lesion in the genito-urinary tract, and there is more pain and fixation of the joint. The Wassermann reaction is a valuable aid to diagnosis when other signs and symptoms of the disease are absent. Specific treatment will confirm the diagnosis.

The hip-joint is more frequently involved in *congenital* syphilis, and the cases resemble and are often mistaken for tuberculous disease of this joint. It is common early, during the first year of life, or later between the fourth and twentieth years. The lesion begins as an osteitis in the epiphysis of the head of the femur and is characterized by a proliferative inflammation of the marrow accompanied by serous effusion into the joint. The bone becomes rarefied, the cartilage eroded and gummatous infiltration of the synovia occurs. The essentials of the pathological process are the same as those of tuberculous disease of the joint. Considerable destruction of the joint structures may occur and discharging sinuses may form. There is, however, more new formation of bone and cartilage in syphilis than in tuberculosis, and though destruction seems great there is usualy not so much shortening as occurs in tuberculosis.

The symptoms, also, may resemble tuberculous disease of the hip. The onset is often sudden with fever, pain, tenderness, swelling, lameness and night cries. Motion is limited but muscular spasm is often absent or if present is uually not so marked as in tuberculosis. Pain is also less severe, and is usually moderate on motion. Effusion is usually slight. Atrophy of the muscles is, as a rule, not so marked as in tuberculosis. In establishing the diagnosis the parental history is of importance. Careful examination should be made for signs and symptoms of the existence of the disease, *e.g.*, snuffles, scars of eruption, scars at the angle of the mouth, ulcerative destruction of the soft palate, Hutchinson's teeth, interstitial keratitis, enlargement of the spleen and general lymphatic enlargement. These are, however, frequently absent and the parental history may fail to indicate infection or still births, and the diagnosis must depend upon the Wassermann reaction, which in congenital syphilis is practically always present.

The Knee-joint.—Syphilis affects the knee-joint more frequently than any other joint, both in the acquired and congenital forms. During

the secondary stage of *acquired syphilis* an acute or chronic synovitis may develop in the knee alone or together with other joints, *e.g.*, shoulder, elbow, ankle. In many cases it appears without warning and is usually accompanied by some pain and tenderness which is not increased by motion, and it may be unaccompanied by any other signs or symptoms. In some cases fever and severe pain in addition to the effusion may be present, and if other joints are involved the condition may be mistaken for acute rheumatic fever. The diagnosis is made on the presence of signs of syphilis elsewhere, the absence of the fleeting character of the joint pains, the comparative mildness of the constitutional symptoms and the Wassermann reaction. Diagnosis is confirmed by specific treatment.

Hydrops of the knee may be the only clinical manifestation of the disease and it may appear early in the secondary stage or a year or more after infection. The onset is insidious and usually without pain, or it may follow the more acute form. The diagnosis is made on the Wassermann reaction and the reaction of the joint to treatment.

In the tertiary period the knee again is most often affected. There may be a subacute or chronic synovitis associated with little pain or interference with motion, an important point in diagnosis. Occasionally there is a slight rise of temperature. There is, as a rule, a little thickening of the synovia and a little creaking may be elicited on movements. The amount of effusion varies greatly from time to time. Gummatous infiltration of the synovia may occur during this stage. The effusion is generally slight or absent. Irregular lumpy thickening of the synovia occurs. In some cases gummatous masses may completely fill the joint, resembling tuberculosis. The amount of pain varies and is frequently worse at night, though there is no "starting" pain. Motion may cause very little pain and even with extensive disease there may be little limitation of movements. According to Patton remission and indeed an apparently almost complete cure is often followed by a recrudescence and this is very characteristic of the disease.

When the disease is primarily in the marrow of the end of the femur or tibia, the condition is essentially more destructive. With disease of the marrow, there is an accompanying inflammation of the synovia with some thickening of the latter. As a result of this the bone becomes rarified, the cartilage fibrillated and eroded, the bone ends become grooved, and eburnated in places, and often there is some lipping of the margin of the articular surfaces, though this is never a very marked feature. The condition resembles arthritis deformans, and the diagnosis

is made only by evidences of syphilis and the results of treatment. Usually there is considerable limitation of motion, often some deformity of the joint. This is either a consequence of the destructive process, or due in addition, to contracture of fibrous tissue, which has invaded the soft tissues of the joint, as well as to the action of the muscles governing the joint. With a good deal of thickening of the soft parts. the appearance of the joint is like that in tuberculous disease. Pain is usually slight as compared with tuberculous arthritis, though rarely it may be severe.

The Wassermann reaction is a valuable aid to diagnosis, though it must be remembered that tuberculous arthritis may occur in one who has syphilis. The therapeutic test will confirm the diagnosis. Finally the gummatous deposits may break into the joint cavity or rupture through the skin. Secondary infection with the ordinary pyogenic cocci and septic arthritis may follow.

In *congenital syphilis* the knee is frequently affected. One of the most common forms is a simple symmetrical serous effusion found in children between the ages of 8 and 15 years. Hutchinson states that double knee-joint effusion, developing synchronously or in close sequence, without any definite reason, can be considered luetic. In this condition there is practically no pain, and very little limitation of motion. The amount of effusion may be considerable, and no other change in the joint may be present. The condition, however, may be secondary to syphilitic osteitis in the end of the femur or tibia. It may be associated with other manifestations of syphilis, though children may have repeated attacks which occur earlier than the specific keratitis or specific teeth.

Primary gummatous affections of the synovia and osteitis with gummatous disease of the synovia (pseudo white swelling) do not differ essentially from similar conditions in acquired syphilis. In syphilitic osteitis of the lower end of the femur, there may be considerable enlargement of the bone with greater or less effusion into the knee, but without other evidence of joint disease. Any interference with motion is due to alteration in the size of the bone. Effusion usually clears up with specific treament but there is a tendency for the condition to recur.

The Ankle-joint.—The ankle is fairly frequently affected by syphilis and the forms of joint involvement are like those found in other joints. Arthralgia, simple synovitis, gummatous synovitis and osteitis, especially of the lower end of the tibia may occur. If osteitis occurs there is enlargement of the lower end of the tibia or malleoli, the joint becomes swollen and painful, and pain is often worse at night. Usually

tenderness is not very marked. There is, as a rule, no muscle spasm and motion, though limited, is without pain. Sinuses may form about the joint. With the knee and ankle there seems to be a fairly definite connection between strain of the joint and the development of syphilitic synovitis and arthritis. Syphilis may involve the feet and give rise to a condition which simulates to a considerable degree flat-foot. The type of flat-foot is that which is usually associated with gonorrhœa. Radiograms often show nodes on the lower end of the tibia, on the astragalus and on the metatarsal bones, but these are not the spur-like osteophytes seen in gonorrhœa. Pain is promptly relieved by specific treatment.

Prognosis will depend upon the accuracy of the diagnosis and the promptness and faithfulness of the treatment. If treatment is begun in the early stage, complete recovery can be expected. Even in cases where there is considerable destruction or scar formation, specific treatment arrests the process, and saves what is still reparable (Harttung). If the condition is not treated, considerable damage to the joint is apt to result.

The treatment of syphilis of the joints is that of syphilis anywhere else in the body. Immobilization except for pain is quite unnecessary in most cases. If, however, the joint is involved in a destructive process, apparatus to secure rest and protection is indicated.

Typhoid Arthritis.—Arthritis, though a very rare complication of typhoid fever, may occur at the beginning of the disease, or may appear in the acute stage or during defervescence; exceptionally it appears during convalescence. The affection may be monarticular or less frequently polyarticular. It does not differ essentially in its clinical manifestations from other forms of infective arthritis. The typhoid bacillus is sometimes found in the fluid of the joint, at other times pyogenic organisms are present. The condition has been produced by the intra-articular injection of the typhoid bacillus (Orloff: "Centralblt F. Bakt.," 1890). The polyarticular variety may appear at the beginning of the disease. Several joints, knee, elbow and others, become affected, and pain and swelling are present in varying degrees. The inflammation is not of a serious character; it is more apt to be of the nature of a serous synovitis, and usually subsides rapidly, but may be followed by considerable stiffness. The monarticular type is generally more severe, and affects one of the large joints, most often the hip. It occurs during the height of the fever, less often during defervescence. Pain is, as a rule, slight but it may be severe. Swelling due to effusion

into the joint cavity is usually marked. The course of the arthritis may be comparatively mild, the attack subsides and the joint returns to the normal condition. If the effusion is quite large, the capsule may become stretched and spontaneous dislocation may follow.

At times the inflammation persists and ankylosis results or a suppurative arthritis may develop. This latter condition is the usual form of septic affection of the joints, due to the presence of staphylococci or streptococci, which have entered the circulation from intestinal ulcers or bed sores in the course of the disease. Because of the severity of the general disease and the apathy of the patient, the arthritis may be overlooked. The milder forms of joint inflammation occurring in typhoid fever do not, as a rule, add to the gravity of the prognosis. Suppurative arthritis is a highly dangerous complication and generally proves fatal. In a few cases, even when there has been no evidence of joint involvement during the fever, a chronic arthritis may appear during convalescence. This more often affects the joints and ligaments of the spine (typhoid spine) and causes considerable pain and stiffness, but may occur in the hip.

Pneumococcic Arthritis.—This is rare in adults and nearly always occurs as a complication of acute pneumonia (lobar or lobular). It is more frequent in small children and is associated with pneumococcal disease of the lungs or middle ear. Rarely it occurs without any evidence of pneumococcal disease in other parts of the body. The inflamed mucous membranes of the nose or throat afford the atria of infection. The affection is generally monarticular, occasionally it is polyarticular, and with the exception of the hip the larger joints (knee, shoulder, elbow) are most frequently involved. There are no special features which characterize this form of infective arthritis. Clinically the symptoms are severe, and the course rapid. The onset is, as a rule, sudden with pain in the joint; the joint swells rapidly and pain and tenderness become marked. Swelling may extend to the soft tissues beyond the joint, redness of the skin is present, and the general temperature is high. The inflammation is essentially destructive, suppuration occurs frequently, and the joint contains a yellowish-green pus. As the condition is serious it is important to make an early diagnosis, for early incision and drainage are absolutely called for. Diagnosis is obviously easy if the patient has pneumonia but may be difficult if no evidence of pneumococcal infection in other parts of the body exists. Bacteriological examination of the blood and joint fluid is important.

The prognosis is grave, especially when the arthritis is added to a more or less severe attack of pneumonia. In cases not complicated by pneumonia, the amount of blood infection is usually comparatively slight and the outlook for recovery better. The treatment is governed largely by the condition of the patient and the character of the exudate. If the joint contains very little fluid, if the fluid be serous, and if the constitutional involvement be not great, one may temporize. Cases of cure by simple aspiration and immobilization have been reported. If the exudate is purulent and constitutional symptoms are severe, the sooner arthrotomy is done the better.

Gonorrhœal arthritis occurs as an acute or chronic synovitis or arthritis, which may be mon- or polyarticular and, while any joint is subject to attack, the larger ones are most frequently involved. In women the causal agent is sometimes difficult to find and post-puerperal arthritis of gonococcal origin is often called puerperal rheumatism. While no age is exempt, it occurs most frequently in young adult life (20–30 years), and more often in the male than in the female. In some cases, there is a cessation of the urethral discharge at the onset of the arthritis, and a reappearance with the subsidence of the latter. The arthritis, at times, follows the passing of a urethral catheter or sound. Infants with ophthalmia neonatorum, and little girls with gonorrhœal vaginitis may suffer from the joint affection.

That the arthritis is caused by the presence and activity of gonococci in the joints or in the articular exudates is shown by the fact that these organisms can be obtained in great numbers and grown in pure cultures from the joint effusion, and even in those cases in which the joint fluid is sterile, smears made from the synovial villi show gonococci in great numbers. The affection has, as a rule, the characteristics of a synovitis, and the pathologic process may remain confined to the synovia. The clinical forms assumed by gonorrhœal arthritis have been grouped under various types.

1. *Arthralgic*, without apparent definite lesions in the joints. It is characterized by wandering pains about the joints without redness or swelling. Pain may persist for a considerable time and give rise to stiffness.

2. *Serous.*—This variety may be mon- or polyarticular. There is a rapid effusion into one or more joints. The exudate is clear or slightly turbid and may contain flocculi of fibrin. The synovial membrane is injected and there is œdema of the periarticular tissues. From the swollen and reddened villi gonococci may be obtained in large numbers.

The cartilage is not eroded, nor is there any bone involvement; the swelling gradually subsides, but may recur. As a rule, general symptoms are not noticed, though the evening temperature may be 2° or 3° above normal. Occasionally the temperature rises to 103° or 104°F., and signs of extraarticular inflammation, œdema and infiltration of the periarticular tissues and involvement of the tendon sheaths appear.

3. *Serofibrinous.*—This form develops suddenly. As a rule there is little fluid in the joint cavity. The periarticular tissues are extensively involved and the skin is often red and hot. Pain is severe. The inflammation ultimately subsides and, depending upon the extent of the destruction, the joint is rendered stiff for a long time, or fibrous ankylosis, which is permanent, follows.

4. *Suppurative (purulent and phlegmonous).*—These forms are fortunately rare. The onset is usually attended with severe pain, swelling and constitutional disturbances, though general symptoms may be absent in some cases. Mixed infections may be present but the most severe purulent or phlegmonous type may be due entirely to the gonococcus.

Symptomatology.—During the florid stage of a gonorrhœal urethritis, often in the third week, the patient notices stiffness, slight tenderness and experiences pain, more or less diffuse, darting or shooting in character, in various joints. Often the small joints of the hands and feet are first involved without symptoms other than tenderness. Examination of the joints may be negative or slight swelling in one or more joints may be present. In a day or two the symptoms subside or disappear entirely from these joints and pain of a greater degree appears in one or two of the larger joints (knee, ankle, wrist) and these begin to swell, become reddened and local temperature is increased. Again, without the preliminary involvement of the smaller joints, one or two of the larger joints may be affected from the first. General malaise may have preceded for a day or two the onset of the joint pains. General temperature is irregular, of a moderate grade and may disappear while the joint condition remains unchanged. In occasional instances, the temperature may rise to 103°–104°F. and this, in the serous form, without suppuration. In these cases there is involvement of the periarticular tissues, tendon sheaths, ligaments and fascia. In the severer suppurative forms all local signs are markedly increased and constitutional disturbances are present. In certain cases of great severity, however, constitutional symptoms may be practically absent. Pain and tenderness are severe and constant, and pain is very much accen-

tuated by movements of the limb. Because of this the joint is usually held quite firmly fixed. Pain and tenderness are marked even in the serous form. That pain is due, in part, to a stretching of the capsule by the effusion, is shown by the fact that it is considerably diminished by aspiration.

Swelling, redness, and increased local temperature vary. Swelling may be marked in the serous form and is due principally to the effusion into the joint. In the sero-fibrinous type swelling, as a rule, is less marked and is due rather to involvement of the extraarticular tissues than to the joint effusions. Redness is present, especially in the sero-fibrinous and suppurative forms, and in the latter, a brawny induration of the periarticular tissues is present. A chill occasionally occurs at the onset. In regard to the onset, Murphy (Surgical Clinics, I, 1912, p. 926) says, "the rule is they do have a chill, and quite a severe chill, even in the Neisserian metastatic type of infection." Profuse perspiration is not often present. Crepitus obtained on passive motion is not constant, and is often due to an accompanying tenosynovitis. The blood shows a slight anæmia and a moderate degree of leucocytosis, but there is no apparent relationship between the latter and the severity of the joint lesions.

The hip-joint is the seat of gonococcal infection more frequently than was formerly supposed. In the combined statistics of Northrup, Finger and Bennecke, in a total of 704 cases the hip-joint was involved in 42 (Young's Manual and Atlas of Orthopedic Surgery). The onset may be gradual, with more or less diffuse darting pains in various joints and a moderate elevation of temperature. The hip finally becomes involved and bears the brunt of the infection. On the other hand, the onset may be quite sudden, with sharp pain in the joint, so intense at times that morphine is required for relief. The joint becomes swollen by serous effusion, accompanied by marked swelling of the periarticular tissues. Redness is present and the local temperature is increased. Pain and tenderness are constant and pain is increased by motion. In cases with marked effusion, spontaneous dislocation may occur. With serous effusion the swelling gradually subsides, pain and tenderness disappear, but recurrences are apt to follow or a condition of chronic hydrarthrosis result. In cases with a serofibrinous exudate, adhesions are quite apt to occur and cause serious impairment of motion. Tenderness and stiffness may persist and some periarticular induration remain.

Gonorrhœal arthritis of the hip occurs in children, especially in little girls with vulvo-vaginitis, but has, as a rule, a favorable course.

The knee is the joint most frequently affected by this form of arthritis. In the combined statistics of 704 cases referred to above there was involvement of the knee in 258. It may become involved secondarily at any time during the urethritis, but is usually affected early in the disease. Exceptionally, however, the arthritis develops after the disease has lasted for some time. The onset is, as a rule, sudden. A sudden chill accompanied by fever and pain in the joints of the hands and calves of the legs may usher in the arthritis. The knee becomes painful and stiff and a fusiform swelling due to effusion into the joint and to periarticular infiltration rapidly supervenes. Fluctuation is easily made out and the patella floats. Redness of the skin is present, and the local temperature is increased. Pain and tenderness are extreme in the knee-joint. The general temperature is not at all proportionate to the intensity of the local signs. The joint is fixed by muscular spasm. If the effusion is serous, the inflammatory signs usually subside and recovery takes place in four or five weeks with perfect motion. In cases where the exudate is extreme, backward subluxation of the leg may result. If the exudate is sero-fibrinous, organized adhesions form and greatly impair function, and in a still more severe grade of inflammation the cartilage becomes fibrillated and eroded and bony ankylosis results. The patella may become adherent to the condyles of the femur early. Suppuration occasionally supervenes.

The ankle-joint is quite frequently the seat of gonococcal invasion. In the combined statistics of Northrup, Finger and Bennecke, in a total of 704 cases the ankle was involved in 125.

In this joint the arthralgic form of the disease is quite common, and the small joints of the foot are frequently involved. Slight tenderness and wandering pains are present; redness and swelling are absent. This frequently persists for a long time and may give rise to a troublesome form of flat-foot. In other cases there is slight tenderness, redness, swelling and pain across the instep, or swelling redness, tenderness and pain are much accentuated, and the surface temperature is elevated. Resolution may be complete. Stiffness may persist for a considerable time or ankylosis result.

Chronic Gonorrhœal Arthritis.—This may follow the acute condition or develop gradually and persist for years. In fact, unless the primary inflammation of the genito-urinary tract is healed, the joint inflammation is wont to persist as a chronic process and extend until the function of the joint is destroyed. The final result is ankylosis and when this has been attained, inflammation subsides. After the

active stages of proliferation, the synovia gradually undergoes a fibrous change and finally after some time the joint becomes a mass of adhesions. Because of disturbances of nutrition the cartilage becomes fibrillated. Gonococcal involvement of the joint is primarily a synovitis, and just what part the lymphoid marrow and periosteum take in the process, is hard to determine because of the difficulty of securing specimens with a definite and complete history. The final picture, however, is similar to other forms of chronic arthritis and it may be difficult to distinguish it from tuberculosis. The radiograph shows thinning and erosion of the cartilage or its disappearance, and a rarefaction of the bone, possibly its partial destruction.

The joint is shrunken and stiff, and as long as the morbid process remains active, painful. When the disease has reached its logical outcome, ankylosis, pain disappears and the patient is able to get about with comfort. While a moderate degree of deformity may be present, the extreme contractures so characteristic of tuberculosis are not seen. This is probably due to the fact that the disease process is largely confined to the synovia, and there is little destruction of bone. The muscles of the limb atrophy.

Diagnosis.—Certain cases present considerable difficulty in diagnosis. Differential diagnosis is to be made from acute rheumatic fever, the acute stage of arthritis deformans, gout, syphilis, and tuberculosis. The principal point to establish is the presence of the primary disease, urethritis, salpingitis, etc., and especially the demonstration of gonococci in great numbers in the urethral or vaginal discharge, but one must always bear in mind the possibility that a urethritis may be associated with other forms of arthritis. The relation of the time of onset of the joint affection to the appearance of the primary disease is helpful in many cases, the metastatic infection of the joints often appearing in the third week of the urethral trouble. The demonstration of the gonococcus in the joint exudate by aspiration or by smear from the synovial membrane is the only positive test, and whenever possible, examination of the joint fluid should be made.

From *acute rheumatic fever*, gonorrheal arthritis may be differentiated by the fact that the pain of the latter condition is not affected by the administration of salicylates, sweating is not nearly so pronounced, and there is not the same tendency to cardiac involvement. Obstinacy is a distinguishing feature of gonococcal involvement of joints.

In *arthritis deformans* the affected joints are rarely so tender. The smaller joints are more often involved and the condition persists with

thickening of the joint and marked periarticular changes as shown by the radiograph.

Acute gout, as a rule, is localized early to a single joint, most often the metatarso-phalangeal articulation of the great toe. The age, history, mode of onset, presence of tophi, and an accurate estimation of the uric acid excretion, are helpful features in the diagnosis.

In *syphilis*, arthritis and pains in the limbs are common secondary manifestations. Occasionally the joint affection is severe. The history is of the first importance. A careful examination for evidence of the primary lesion, mucous patches, skin eruptions, lymphatic glandular involvement, the Wassermann reaction and finally the therapeutic test of the antisyphilitic remedies will render the diagnosis clear.

Tuberculosis.—The gradual onset of the arthritis with easy fatigue, the limp, slight pain, absence of tenderness and swelling in the early stage; the intermission following rest in which the symptoms subside and pain disappears; the radiograph showing epiphyseal foci—all are points to be remembered.

Although gradually progressive, acute exacerbations often appear and subside, and the process seems to remain stationary, but without proper treatment the process continues and increases in severity until finally pain and swelling are marked, motion in the joint very much limited and crepitus may be elicited. Early muscular atrophy is a distinguishing feature. Finally the presence of tuberculosis in other parts of the body as indicated by symptoms and physical signs, or the reaction to the tuberculin tests (ophthalmo-tubercular reaction of Calmette or von Pirquet's cutaneous reaction) is suggestive, while inoculation of a guinea-pig with the joint fluid may be the means of reaching a positive diagnosis.

In the chronic form of gonorrhœal arthritis if careful examination is made, the focal gonorrhœa can usually be found. In men this is usually in the prostate or seminal vesicles; in women the glands of the labia, endometrium or Fallopian tubes may harbor the organism. Discovery of the cause will render the diagnosis absolute. Examination of the urine may reveal shreds and gonococci. Frequently, however, it is imposible to find the organism in the genital lesions in these cases.

Finally the complement fixation test for diagnosing latent gonococcic infections as worked out by Schwartz is a valuable aid. Schwartz (American Journal of Medical Sciences, 1911) has prepared a polyvalent antigen from a mixture of many different strains, and this fixes the complement whenever one of its component strains does so,

and consequently the necessity of testing the serum against a number of antigens is avoided.

Prognosis.—Gonorrhœal arthritis is not in itself dangerous to life. The acute inflammation of the joint may subside completely, and leave the joint in a normal condition, but it is quite likely to persist and become chronic, resulting in fibrous ankylosis. Even in chronic cases, a cleaning up of the focus of infection may cure the joint condition.

Relapses are frequent unless the causal lesion can be cured. In the arthralgic and serous forms the outlook is good. In the serofibrinous and suppurative varieties, much loss of function, with considerable crippling, the result of fibrous and bony ankylosis, is to be expected.

Treatment.—The first indication for treatment is to attend to the causal lesion. Whether reinfection from the genital lesion is constantly occurring is not known, but patients recover more quickly with active and successful treatment of the primary lesion. In the acute stage to prevent further injury to the inflamed joint the patient is put to bed and the joint immobilized by means of a splint. Care must be exercised to avoid the dangers of prolonged immobilization. Murphy of Chicago (Surgical Clinics, 1912) recommends the application of Buck's extension to the leg in order to relieve intra-articular pressure, and to keep the joint surfaces from coming together. He uses repeated injections of a 2 per cent. formalin in glycerin solution to produce strong reaction to overcome the infection. Hot or cold applications are often grateful. With considerable distention aspiration of the fluid often relieves the pain, but the fluid frequently reaccumulates. If pus is present, aspiration and lavage, or incision is indicated in the phlegmonous form, particularly in the mixed and secondary infections.

In regard to the use of vaccines and antigonococcus serum, reports as to the efficiency of the method are varied and doubtful. No conclusive evidence can be obtained as to the real value. Further, the dosage and frequency of administration is by no means definite. Neither vaccine nor serum renders the patient immune. Relapses after this method of treatment are common. As to the dosage of the vaccine, L. E. Schmidt (Therapeutic Gazette, 1909) advises the administration of comparatively small doses, 10 million to 30 million, in cases of acute gonorrhœal joints. In the subacute or chronic cases, 30 milion to 50 million bacteria give the best results. He further

states that the best results were noted when injections were given about five days apart. For the administration of the serum, Horevitz recommends doses of 2 cc. given daily for a week, then, after five days' intermission, again for seven days. This is continued for three or four weeks. Schmidt reports the following results in the treatment of cases of gonorrhœal infection with either serum or vaccine or both.

No improvement	14.28 per cent.
Improvement	57.16 per cent.
Cured	28.56 per cent.

Reports of other observers are not so encouraging.

After the acute symptoms have subsided, active and passive movements are instituted. These should be gentle at first and increased daily, according to the pain and reaction produced. In the beginning the joint is bandaged after each exercise. Hot moist compresses are applied at night. Renewed effusion may follow the first movements, especially after prolonged immobilization, and this may delay treatment. Bier's passive hyperæmia has proved effective in some cases. Baking is beneficial; the temperature is gradually raised to 250° or 300°F. and the joint allowed to remain in the apparatus for 20 minutes. Exercises on the Zander machines are useful. Where ankylosis is partial and all acute symptoms are absent, the adhesions may be broken up under anæsthesia. If bony ankylosis has occurred, an arthroplasty may be performed.

Tuberculosis of the Hip.—*Synonyms*: *Morbus coxæ*, *Morbus coxarius*, *Coxalgia*, *Hip Disease*.—Tuberculosis of the hip starts most frequently in the head or neck of the femur near the epiphyseal line. It may, however, start in the acetabulum, and primary tuberculosis of the acetabulum is much more common than was formerly thought. The question of the occurrence of primary synovial tuberculosis of the hip is still an unsettled one and, though difficult of proof, may be answered tentatively in the affirmative.

The disease begins with one or more small foci in the bone marrow. The tubercles form exactly as tubercles do in other situations. When the tubercle reaches a certain size its central portion undergoes caseation. In the meantime new tubercles are formed around the periphery of pre-existing ones. In other words the tuberculous tissue tends to spread at the periphery and to break down at the center. The result of this marrow tuberculosis is rarefaction of the bone trabeculæ included in the area, which may advance to a stage of necrosis and disappearance. When the tuberculous granulations reach the surface,

they may lift the cartilage from the bone, or they may cause its absorption in places and perforate it, or they may spread out under it and enter the joint at its margin. As soon as the disease has gained the joint, the synovia becomes infected. When the denuded surfaces of the two bones lie in approximation, ankylosis may take place. This ankylosis is probably always fibrous except in children after a secondary infection. The gross deformity of the joint is sometimes very great. The head of the femur becomes roughened and irregular and smaller. The acetabulum may become considerably eroded, especially upward from the pressure of the head of the femur against it, so that instead of being a cavity with a circular outline, it becomes ovoid or elliptical, "wandering acetabulum." Sometimes the disease perforates the acetabulum and extends into the pelvis.

Abscess formation is frequent in hip disease. The fluid usually breaks through the joint capsule anteriorly on the under-surface, and the abscess presents on the anterior surface of the thigh.

Roughly speaking, tuberculosis of the hip forms about 30 per cent. of all cases of osseous tuberculosis. It is exceeded in frequency only by tuberculous spondylitis (Pott's disease).

Although hip disease occurs at all ages, children are much more frequently affected than adults. Almost 90 per cent. of the cases occur in the first decade and about 50 per cent. of the cases before the age of five. The disease practically never occurs before the second year.

The reason for the frequent occurrence of tuberculosis in the hip is unknown. Trauma probably has nothing to do with it, as the joints of the foot, ankle and knee are injured more often than those of the hip. According to Fraser ("Situations of Lesions in Osseous Tubercle," Edinburg Medical Journal, November, 1912. See also Ely, "Joint Tuberculosis," Wm. Wood & Co., 1911.) The favorite starting point of the disease is the lower part of the neck of the femur, just external to the epiphyseal cartilage, a part singularly protected from trauma. It is possible that some peculiarity of the structure of the marrow in that area is responsible.

Symptoms.—The symptoms of hip disease generally come on slowly and insidiously, but in rare instances they may come on acutely. They are limp, pain and stiffness; the limp usually comes on slowly, gradually developing from an almost imperceptible change in the gait to a well-defined limp. The limp is due to the change in attitude of the limb, to the pain and to the muscular spasm and limitation of motion, and not to any actual shortening of the bone until the late stages of the disease.

The child walks in such a way as to avoid jarring the hip as much as possible. He steps on the ball of the foot, not on the heel, and keeps the knee bent. Often, in the early stages, the limp is present in the morning, and disappears on exercise. In cases in which the pain is severe, the child will refuse to use the leg at all. In the late stages of the disease the limp is due, at least in part, to actual shortening of the bone, and also to displacement of the head upward.

The pain varies in intensity. Some cases are extremely painful from the start; in others the pain is comparatively irregular. It often comes on in paroxysms during the night, waking the child up—night cry. It is usually worse from exercise. It may be felt in the hip, thigh or knee. The pain in the knee in early hip-joint disease is notorious, and has given rise to many mistakes in diagnosis. Tension within the joint from the accumulation of the products of disease is one of the causes of pain.

Physical Signs.—In eliciting the physical signs in a suspected case of hip-joint disease the greatest care and thoroughness should be observed. If the patient be a child, he should be invariably stripped. This rule knows no exception. If it be a man the same rule should be followed. In the case of a woman the clothes should be removed and she should be examined under a sheet upon a table. The gait is first to be noted. The examination in the recumbent posture should be conducted upon a fairly firm table, not upon a soft and yielding bed. All the motions of all the joints of the lower extremity should be tested in their full range and any departure from the normal should be noted down in black and white; any peculiarity of attitude, any change of contour, any lengthening or shortening of the size of the two limbs at corresponding points should also be noted. The measurements should be made, not with the naked eye, but with a tape measure. The patient's general condition should be noted.

The chief physical signs of tuberculous hip-joint diesase are *limp*, *muscular atrophy*, *muscular spasm*, *deformity* and *limitation of motion*. The limp is caused by deformity, by muscular spasm and by the limitation of motion. It is a limp of pain and stiffness rather than of weakness. The muscular atrophy is a peculiar phenomenon in hip-joint disease, and occurs at a very early stage. It can be explained partly as an atrophy of disuse, but as a rule, is greater in tuberculous joint disease than in any other. It is present in the thigh and calf of the affected side. The difference in circumference may vary from about 1 cm. to even 10 cm. or more. In this atrophy all the tissues of the affected

extremity participate. The bones become lighter in texture and smaller in diameter.

Muscular spasm also is an early and important sign, and like the preceding is greater in tuberculous joint disease than in others. It is to be interpreted as nature's effort to keep the joint at rest. It varies in intensity from a slight degree at extremes of motion to marked severity at the slightest exercise. It disappears under an anæsthetic and is probably responsible for the change in attitude in the earlier stages of the disease.

The deformity is the result of the muscular spasm and of the products of inflammation within the joint. In the early stages of the disease the deformity is usually in extension and abduction, later in flexion and adduction. In the late stages of the disease gradual shortening in the extremity and severe muscular contracture may take place. The cause of the peculiar attitudes in hip-joint disease has given rise to much speculation, but no explanation has ever received general acceptance. The attitudes of flexion, extension, abduction and adduction have a marked effect in producing the symptoms of the disease, and an apparent effect upon the length of the extremity. If a normal person lies upon a table, his thighs lie in apposition, neither abducted nor adducted, in normal extension and in slight outward rotation. If one of his thighs be fixed in abduction by disease it will be drawn away from the other. In order to bring it down parallel with this other thigh the patient must tilt his pelvis downward. This draws up the other side of the pelvis, making the well limb apparently shorter and the diseased one apparently longer—*apparent lengthening*. This takes place in hip-joint disease as soon as the patient tries to walk. Again, if the affected joint be in adduction, the limb is crossed over the well side, and in order to bring it down parallel with the other the patient must draw his pelvis up on the affected side, thus producing *apparent shortening*. Adduction causes a deepening of the fold of the groin. Actual shortening is detected by measurement from the anterior-superior spine to the tip of the medial malleolus, apparent shortening by measurement from the umbilicus to the tip of the medial malleolus. The influence of flexion upon the production of a limp and of apparent shortening can be readily appreciated. Flexion causes a deepening of the fold of the groin and a shortening of the gluteal fold upon the affected side. In order to find out whether flexion is present, it is necessary, when the patient lies upon his back, to hold his lumbar spine upon the table by flexing his sound thigh; otherwise the patient will arch his

lumbar spine forward, releasing the diseased flexed thigh and allowing it to come down upon the table. This will disguise the presence of the flexion deformity.

In the late stages of the disease, especially if untreated, the characteristic deformity of flexion and adduction may reach an extreme degree, and this deformity is accentuated by a gradual shortening of the limb, the result, not as one might suppose, of destruction of the femur head and dislocation, but of great atrophy and of subluxation of the head of the femur by wearing away of the upper portion of the acetabulum, so that the head of the femur comes to rest perhaps an inch or so higher in the acetabulum than normal, the "wandering acetabulum" mentioned above.

The limitation of motion may vary between a slight limitation of motion at the extremes, and a practical or complete abolition of all motion. It is the result of the muscular spasm and of the inflammation within the joint. The former disappears under an anæsthetic, the latter does not. The greatest limitation of motion in hip-joint disease is usually in the direction of abduction and complete extension.

Diagnosis.—This may or may not be a simple matter. There is nothing definitely characteristic of a tuberculous joint disease except the demonstration of the tubercle bacilli or the tubercle itself. The X-ray findings, the symptomatology, and the pathology of joint tuberculosis are largely the same as are those of numerous other joint diseases, such as syphilitic arthritis, pneumococcic arthritis, chronic streptococcic arthritis, gonococcic arthritis, traumatic arthritis, etc.

The diagnosis in every case is to be made by a study not only of the joint itself but of the course of the disease, of the patient and of his history. The tuberculin test is suggestive but not conclusive. The following points speak for tuberculosis—youth, slow onset, gradual and more or less steady course interrupted perhaps by exacerbations, monarticular nature, demonstration of a tuberculous lesion elsewhere, extreme muscular spasm, absence of cartilaginous or bony outgrowths, muscular atrophy, flexion and adduction. Syphilis and gonorrhœa can often be excluded by a careful history and a thorough examination. The same may be said of pneumococci, typhoid and traumatic arthritis, but one must keep one's mind open to all the possibilities of error, and must be on the alert for any sign in any part of the body which may point to the true nature of the disease. In other words, having made the diagnosis of tuberculosis of the hip-joint, the surgeon should always be eager to prove that he is mistaken. It is this reluctance to

admit error which is responsible for many reputed cures of so-called hip-joint tuberculosis.

Differential Diagnosis.—From certain diseases of the hip-joint tuberculosis can be distinguished by what has been said under the head of diagnosis. New growths occur near the joint but usually do not affect the joint itself. They occasion destruction of the bone over a considerable area, sometimes are surrounded by new bone, and are not characterized by the pain and muscular spasm of coxitis. The so-called osteoarthritis of the English writers, arthritis deformans of the Germans, Goldthwait's hypertrophic arthritis and Ely's arthritis type II is usually monarticular, like tuberculosis, but unlike tuberculosis occasions bony thickening rather than bone rarefaction and the limitation is caused not by muscular spasm, but by actual mechanical interference with motion by bony outgrowths. It occurs most frequently in elderly people (morbus coxæ senilis) and its characteristic deformity is one of extension and abduction. It often follows a distinct trauma.

Prognosis.—The prognosis as to life is good if secondary infection can be prevented, and if involvement of vital organs by tuberculosis does not take place; in fact, hip-joint tuberculosis carries in itself no danger to life. Secondary infection immediately makes the prognosis much worse. The prognosis as to function varies between extreme limits and is generally influenced by the efficacy of treatment. Perfect return to function is rare, if it ever occurs, and should make the surgeon extremely sceptical as to the correctness of his diagnosis. Recurrence is not uncommon many years after apparent cure.

Treatment.—Two indications stand out above all others: first avoidance of secondary infection; second, deprivation of function.

1. Avoidance of infection. All operations undertaken upon a tuberculous joint should be characterized by scrupulous asepsis. A tuberculous joint should never be scraped and packed. To employ drainage in a tuberculous joint is to invite secondary infection. One provides thereby, not so much for the exit of tuberculous material, as for the entrance of pyogenic organisms and opens thereby a door which possibly he can never close. Abscesses should be aspirated before they approach the surface too closely.

2. Deprivation of function. This may be divided into two classes, conservative and radical. The first is almost invariably the treatment for children, the second for adults. It may be laid down as a cardinal rule on the one hand that conservative treatment should

be continued with children until all hope of saving the limb is gone, then amputation should be done as a life saving measure. On the other hand radical treatment should be followed practically invariably in adults or in adolescents who have almost reached their growth as soon as an absolutely positive diagnosis can be made. Conservative treatment is always long and tedious and is never followed by good function. The danger to life is lessened by radical treatment, the result is as good functionally and the length of the treatment is, of course, much shorter.

Conservative Treatment.—This has two objects: first, prevention of deformity or its correction if it has taken place; second, deprivation of function. Any existing deformity is to be removed at the beginning of treatment. The characteristic deformity of flexion and adduction should be changed to one of extension and slight abduction. This may be done in one of three ways: (*a*) Rest in bed with weight and pulley traction. (*b*) Reduction of deformity under ether and the immediate application of a brace or of plaster of Paris. (*c*) The application of several plaster spicas at short intervals, correcting the deformity a little at each time. The second method requires extreme care in its application, in order to avoid wounding the joint structures, and possesses a small element of danger, though in practiced hands it is very satisfactory.

In a general way two distinct methods are employed for carrying out these indications; one by plaster of Paris and the other by braces. Both, of course, would be increased in their efficacy by rest in bed, but on account of its deleterious influence upon the genral health of the patient, this is not advisable except as a temporary measure and to meet special indications. The effect of any so-called brace or plaster-of-Paris dressing in tuberculous hip-joint disease, no matter what may be the idea of the surgeon who uses it, is simply to hold the limb in place, and to deprive it of function until the disease is cured.

The usual type of brace in use in America consists of a pelvic band with perineal straps. To this perineal band is bolted an upright of steel, which reaches down to a point about 3 in. below the sole of the foot, and is held to the leg by a circular band at the knee. Counter extension of the limb is provided by adhesive straps applied to the leg and thigh and fastening below to the sole piece formed by a right angle bend of the upright at its lower extremity. This brace removes the hip from weight bearing and exercises a certain amount of immobilization. The Thomas brace, which is the type in use in England abandons

the idea of extension, and secures immobilization by steel splints running from about the level of the nipple to the calf, and provided with circular bands about the chest, thigh and calf. The patient with this form of splint goes on crutches and wears a high shoe on the other side. The plaster-of-Paris spica now forms the routine treatment for many surgeons and possesses the peculiar advantage that it does not require the aid of a skilled bracemaker. It holds the limb very exactly and permits greater freedom of motion for the child than any other form of apparatus. The short spica as advised by Lorenz reaches from about the waist to the knee and is cut out well from the perineum and also anteriorly over the abdomen, leaving a thick but rather narrow bridge. So-called scratch bandages consist of strips of ordinary muslin which run underneath the plaster to keep the skin in condition. The spica must be well applied at the knee and about the crests of the ilia, and must be snugly applied and carefully moulded about the pelvis. With this spica applied the patient is permitted to go about as much as he pleases, but is not encouraged to use the limb if pain results. In case any weight bearing is considered inadvisable, the plaster spica is continued to the ankle and is provided with a foot piece of steel—a "stirrup"—extending down 2 to 3 in. below the sole. This is incorporated in the plaster on either side of the calf. The long plaster spica reaching from the axilla to the toes has its advocates in Germany, but is rarely used in this country. Whatever form of conservative treatment is employed should be continued for years and then should be left off gradually, while the effect upon the joint is watched carefully. If symptoms recur the apparatus must be re-applied. The duration of tuberculous hip-joint disease under conservative treatment varies from two years to ten or, one may almost say, to a life time.

Radical Treatment.—This may be carried out in one of two ways, namely, by removing much or little of the head of the femur and possibly of the neck and trochanter and thus producing a dislocation, or, following out Albee's idea, by denuding of cartilage the acetabulum and a large part of the head of the femur and then putting the head up in plaster in a position of slight abduction and extension, with the purpose of obtaining a bony ankylosis. In either case the object to be attained is a destruction of the joint, as it is manifestly impossible to eradicate all the tuberculous tissue from the pelvis, whatever we hope to accomplish in the femur. For a patient leading an outdoor life an ankylosed hip probably is better than a dislocated one, but for the patient who follows an indoor occupation a dislocation is preferable. The shortening can be

compensated by a high shoe, and the limb will be fairly useful for walking.

Tuberculosis of the knee, (*Tumor albus*, *White Swelling*), may start from a focus in the femur or in the tibia occasionally in the patella or the head of the fibula, or it may be a primary synovial tuberculosis. In König's clinic 547 cases of knee tuberculosis were examined when access to the joint was obtained through operative procedures. Almost two-thirds of these cases occurred in adult patients. According to his figures 281 cases (51.4 per cent.) show primary bone lesions, 266 (48.6 per cent.) cases were apparently primary synovial tuberculosis. Primary bone lesions were distributed as follows:

Femur	93 cases (33.1 per cent.)
Tibia	107 cases (38.1 per cent.)
Patella	33 cases (11.7 per cent.)
Multiple lesions	48 cases (17.1 per cent.)

According to Nichols (Trans. American Orthop. Assn., Vol. XI) primary synovial tuberculosis is extremely rare. He examined 120 tuberculous joints either at autopsy or in joints removed by operation and states that in every case he discovered a primary bone focus. His teachings have received almost universal acceptance in America, but recently opinion has veered. The weight of opinion now is that primary synovial disease is not infrequent, especially in adults. The point is a difficult one to prove absolutely, but primary synovial tuberculosis differs in no essentials from primary tendon sheath tuberculosis and the occurrence of the latter is no longer questioned.

Etiology.—Although tuberculosis of the knee is more common in adults than is tuberculosis of the hip or spine, still it is largely a disease of early childhood. From statistics gathered at the Hospital for Ruptured and Cripples in New York an analysis of 1000 cases shows the frequency for each five years up to the age of 40 to be as follows:

Years	Cases	Years	Cases
1–5	409	25–30	19
5–10	340	30–35	9
10–15	114	35–40	5
15–20	54	After the age of 40 there were 2 cases	
20–25	48		

Males and females are affected about equally, according to the same statistics. Males 512; females 488.

Right and left sides are about equally affected. Right side 485; left side 515.

Symptoms.—The general symptoms of tuberculosis of the knee are similar to those of tuberculosis of the hip and spine. The special symptoms are pain and limp. The principal physical signs are muscle spasm, limitation of motion, tenderness, atrophy of the leg and deformity. The pain is usually more severe at night, and increases at any attempt at motion. The limp occurs early in the disease. The leg is held in semi-flexion and the consequent limp is characteristic of knee-joint trouble. On examination of an early case the patient is found to hold the knee slightly flexed. Atrophy of the leg and thigh are present. The atrophy is more marked when the disease is primary in the bones. The same is true of the deformity. The outlines of the knee-joint will be somewhat obscured, the prominences and depressions will not be as marked as on the sound side, occasionally there will be a complete obliteration of the markings of the joint when an effusion is present, but usually the swelling in the joint is due to the thickening of the synovial membrane. Deformity other than flexion may be present as will be described later.

Points of tenderness can usually be made out, the actual site of the tenderness varying with the site of the lesion. Usually the sensitiveness can be noted best by pressure applied below and to the side of the patella when the knee is flexed. In case of an effusion into the joint, fluctuation may be elicited. Limitation of motion is very great and due to muscle spasm. In a normal child the range of motion is from full extension to an angle that is determined by the impinging of the calf against the thigh in flexion. The limitation of motion that is determined by muscle spasm varies with the extent of disease. In adults the disease frequently comes on much more insidiously than in children; it resembles a chronic synovitis of other than tuberculous origin. In these cases pain is noticed only when the leg receives some twist or a knock or jar. The swelling is not so great as in the acute form and muscle spasm and limitation of motion are much less marked.

The characteristic deformity of knee-joint disease in the early stages is semi-flexion; in the late stages the flexion may be extreme and has added to it an external rotation of the leg and sometimes an attitude of valgus. In addition, in cases of long standing, a subluxation of the tibia backward upon the condyles of the femur takes place. The ligaments become shortened to such an extent that if straightening of the leg be attempted, the head of the tibia is subluxated backward upon the femur. In other words the tibia comes to lie, after forcible cor-

rection of the deformity, in the proper line but in a plane posterior to that of the femur.

Shortening of the lower extremity as a whole usually takes place after tuberculosis of the knee, but in the early stages of the disease the limb may be actually increased in length, probably on account of stimulation by irritation of the bone marrow near the epiphyseal lines of the tibia and femur.

Abscess formation is quite frequent in knee-joint tuberculosis and owing to the nearness of the joint to the surface, rupture and secondary infection of the abscess are hard to prevent.

Prognosis.—It is extremely doubtful if knee-joint tuberculosis in young or old ever recovers without impairment of function. This impairment may vary from a slight restriction at the extremes of motion to a complete bony ankylosis. The latter probably only takes place in children after secondary infection. The ankylosis is usually fibrous.

Treatment.—This is conservative in children, practically invariably radical in adults. The essentials of conservative treatment are to bring the tibia into a straight line with the femur and hold it there until it is well. If backward displacement of the tibia has taken place the deformity should not be reduced immediately at one sitting for fear of producing the deformity described above. The patient should be put to bed with weight and pulley traction on the leg, and also with traction forward by weight and pulley on the upper part of the calf, in order to draw the head of the tibia out from under the condyles of the femur. A slight amount of forcible correction may also be done under ether, if the force be applied forward on the head of the tibia and not by simply crowding the knee down upon the table. For maintaining the leg in complete extension during the entire course of the disease, a plaster-of-Paris dressing may be employed, reaching from the perineum to a point 1 inch above the medial malleolus. The plaster should be applied snugly and should be moulded carefully upon the limb. A small amount of padding may be used over the knee and the top and bottom of the dressing, but no padding is advisable over the muscle bellies.

If treatment by braces be selected the Thomas knee brace will probably be the most satisfactory. This reaches from the perineum to a point about 3 in. below the sole of the foot. The other foot should be provided with a sole of 2 or 3 in. in thickness.

A cure under conservative measures should not be expected in less than two years.

Radical Treatment.—This may be summed up in one word as a rule, *resection.* The object of this resection is simply to destroy the joint and to secure primary union of the wound. No attention need be paid to the removal of the tuberculous tissue, according to Ely, though most operators heretofore have endeavored to remove with painstaking care every visible trace of it. The operator may select his favorite incision and should remove about ½ in. from the condyles of the femur and about the same amount from the tuberosities of the tibia. If the crucial ligaments are intact they need not be divided. Removal of the semilunar cartilages will probably lessen the subsequent pain of the operation. Bone sutures, wires, steel nails, etc., may be used, but they are probably unnecessary. The wound *should be sutured up without drainage* and the patient should wear a plaster dressing for about six months thereafter. It is extremely interesting to watch by means of X-ray plates the change in the structure of the bone at the site of the resection. Its spongy nature disappears and a dense formation of bone takes place at the periphery. Amputation should be reserved for the desperate cases. No mobilizing (arthroplastic) operation should ever be undertaken in a knee that has been the seat of a tuberculous inflammation (Ely).

Tuberculosis of the ankle is practically identical with tuberculosis of the other joints. The primary focus may be osteal or synovial. The cases are about equally divided. In the osteal type of the disease the focus is in the talus in the majority of cases, less frequently in the tibia and fibula or the lateral malleolus. Again the disease may begin in any of the tarsal bones and involve the ankle secondarily by extending through the talus. This is a peculiarity of tuberculosis of the wrist and foot. The numerous synovial sacs and the exclusively spongy nature and small size of the bones, favor the spread of the disease from one articulation to another. This fact has an important bearing not only on the pathology and symptomatology, but also upon treatment.

Etiology.—Tuberculosis of the ankle is much less frequent than tuberculosis of the hip or knee. It occurs about one-fourth as frequently as tuberculosis of the knee. Like tuberculosis of other joints it is found most frequently in childhood, but is relatively more common in later life than is either hip or knee tuberculosis. It occurs with about equal frequency in males and females.

The chief *symptoms* and *physical signs* of tuberculosis of the ankle, as of other joints of the lower extremity, are pain, stiffness, limp,

muscular atrophy, musclar spasm and deformity. Swelling is usually rather marked. In the severe cases the swelling may take on the classic spindle shape. The entire region of the ankle-joint may be swollen, or the swelling may be in front of either of the malleoli or behind them. The foot may be seen to be turned somewhat outward and is usually in equinus. Fluctuation may be present but more frequently it is a pseudo-fluctuation, that is, the swelling is due to the tuberculous granulations and to the infiltration of the soft tissues. On attempting to move the ankle the range of motion is found to be limited, the muscular spasm prevents dorsal and plantar flexion. Local tenderness can be easily elicited in the ankle by slight pressure. Atrophy of the calf is usually present, but is less than in knee-joint disease.

Diagnosis.—This rests largely on the presence of stiffness, muscular spasm, pain and tenderness in one joint extending over a considerable period of time.

Much the same conditions must be taken into consideration as in tuberculosis of other joints, especially sprain, and acute arthritis and epiphysitis in childhood, and occasionally chronic suppurative osteomyelitis of the lower end of the tibia. Flat-foot can be excluded by the position of the points of tenderness (see flat-foot) and by the fact that in flat-foot the pain disappears when weight is removed, as when the patient is in bed, while in tuberculosis of the ankle the pain is usually more severe at night. Again, motion is not restricted in the ankle-joint in flat-foot. The stiffness and pain are located in the mid-tarsus.

Practically the only complication is abscess. When this does occur it does not form long fistulæ, because of the proximity of the joint to the skin, and there is no chance for long burrowing sinuses to form. On the other hand, rupture and subsequent secondary infection of an abscess once formed in the ankle is almost impossible to avoid.

Prognosis.—The prognosis in tuberculosis of the ankle is better than in tuberculosis of the hip or knee. Its mortality is lower, and recovery with good functional result and without deformity occurs more frequently. Shortening of the leg is slight and not of sufficient degree to cause much limp. The course of the disease is shorter than in tuberculosis of the hip or knee when treatment is efficient.

Treatment.—Again the treatment is either conservative or operative. The best form of conservative treatment is by means of a plaster-of-Paris dressing extending from the toes to the knee, the foot being flexed to a right angle and held slightly inverted. If there be deformity and

the position cannot be corrected easily otherwise, it should be done under anæsthesia. Usually, however, this is not necessary. The plaster is changed from time to time, the periods varying from four to eight weeks. The foot should not be allowed to touch the floor, the patient should wear a high shoe on the well foot and should use crutches. Bier's bandage applied about the calf three-quarters of an hour twice a day has been recommended as an adjunct to the treatment. If the patient does not improve under conservative treatment, operative measures become necessary. Good access to the ankle-joint can be had, and thorough inspection of the joint can be made without doing much or any damage. The joint should be opened by the Kocher incision, *i.e.*, a curved incision under the lateral malleolus, the peroneal tendons are to be either retracted, or cut and subsequently sutured, and the incision carried down to the joint. The diseased areas or perhaps the entire talus are removed and the joint is closed again *without drainage*. Curetting should not be done. While a cure may be obtained after most careful work and primary union, recurrence is common, and not infrequently amputation finally has to be performed.

Tuberculosis of the tarsal bones and of the mid-tarsal joints is not uncommon. The site of the disease is usually indicated by local swelling. In these cases the X-ray, particularly in the adult, is invaluable as indicating not only the location but the extent of the disease. The disease spreads easily from one bone to another. Tuberculosis of the calcaneus is most frequent in the anterior portion of the bone, and shows little tendency to involve the joints, in this respect differing markedly from tuberculosis of the other bones. Abscess formation is the rule in tarsal tuberculosis.

Symptoms.—The symptoms of tarsal disease are pain, limp and deformity. The general attitude of disease of mid-tarsus is toward slight calcaneus and valgus deformity.

Treatment.—This is conservative in the child, radical in the adult. The conservative treatment is best carried out with a plaster-of-Paris dressing reaching from the upper part of the calf to the toes. The foot should be relieved of weight bearing either by means of crutches and a high shoe (2 or 3 in. sole) on the other side, or better by a Thomas knee brace which prevents absolutely all weight bearing.

In adults the treatment is almost invariably radical. If the disease be confined to one bone, and if a synovial membrane be not involved, in other words, if the process be rather narrowly circumscribed, possibly a cure may be attained in rare instances. Otherwise

the treatment may be planned on one of three different lines. The first is still in the experimental stage and consists essentially in destroying all the joints in the immediate vicinity of the focus, in the hope that the resulting change in the bone marrow and synoviæ will make the tissues unsuitable to harbor the tubercle bacillus. The second plan is to do a resection so wide that every particle of infected tissue is removed. Some surgeons report good results from this procedure. The third plan of treatment is that of amputation, which usually, of course, should be postponed until all of the others have been tried.

Tuberculosis of the joints of the toes is seen occasionally, but is rather rare, doubly so in children. The symptomatology is that of tuberculous arthritis generally. If the great toe be affected, resection is probably the best treatment, if the other toes, amputation.

Tuberculosis of the shafts of the metatarsals and phalanges has been described, similar to the more common "spina ventosa" in the hand. The joints in this form of the disease, show little or no tendency to involvement.

If the disease occurs in the phalanges, amputation is the wisest procedure and if it occurs in a metatarsal bone, the whole shaft of the bone should be resected.

Osteoarthritis.—By this term is meant a morbid process whose characteristic features are quite different from those of tuberculosis, and whose symptomatology, though superficially simulating that of tuberculosis, differs radically from it. This morbid process has received different names; in Germany it is known as *arthritis deformans;* in this country both terms are used as well as Nichols and Richardson's *degenerative type of arthritis*, Goldthwait's *hypertrophic form*, Ely's *type II*. The chief pathological features of this type are a degeneration of the synovia and of the bone marrow and a marked proliferation of the bone and cartilage. Round-cell infiltration is found in areas in the marrow and synovia also, showing a mild degree of inflammation.

Occurring in the hip it is also known as "morbus coxæ senilis, sive juvenilis." The head of the femur may become enlarged and flattened, and distorted so that it no longer fits into the acetabulum. Bony and cartilaginous masses are formed, not only about the head of the femur, but also about the acetabulum. Spurs about the acetabulum are a frequent phenomenon. The joint cartilages become thick and fibrillated, often present under the microscope a peculiar bizarre appearance, and a roughness, which has been well described by the term "tatters."

Islands of cartilage form in the marrow of the bones entering into the articulation and these islands may probably be converted later into bone. The relative amount of bone and marrow in the bone end changes at the expense of the marrow. The marrow also undergoes striking changes of a degenerative nature and these marrow changes have been considered by some to be responsible for most of the changes in the bone and cartilage. Cysts may be found in the marrow, especially that near the joint cartilage. Ankylosis of the joint never takes place. The femur and acetabulum are never united either by bone or fibrous tissue. The restriction to joint motion which ensues is always mechanical. The synovial membrane, while it may be thicker than normal, and may form folds and tabs, does not undergo a typical proliferation of its functional elements. The cartilage in the later stages may wear away, leaving the thickened and eburnated bone ends bare.

The cause of this type of arthritis is still a matter of debate. The joint changes have been said to be an exaggeration of those ordinarily taking place as age advances. Beitzke (Beitzke, Zeitschrift für klinische Medezin, 1912) in a series of consecutive post-mortem examinations found lesions in the fingers of a large proportion of his subjects similar to those described above. Axhausen (Axhausen, Archiv für klinische Chirurgie, 1912) also imitated these changes by burning the joint cartilages of the knees of dogs and rabbits with an electric needle. Severe trauma is almost undoubtedly responsible for the disease in some instances, and repeated small traumata of certain occupations also. The rôle of infection probably is not so important in this type of arthritis as in some others, though that there is some causal relation is not to be denied (Arbuthnot-Lane, Lancet-Clinic, 1913). Chronic strain is also held to be a cause of this form of arthritis.

Symptomatology.—The onset of the disease is usually slow. Sometimes months after what is supposed to be a causal injury the patient complains of pain and stiffness in his hip and of pain running down the affected extremity. A limp is almost invariably present. The pain may be severe or it may be comparatively insignificant. The joint is usually held in slight abduction and either in flexion or in extension. Motion in it is limited and painful in all directions, though painless motion may be possible within certain limits. The obstruction to motion is naturally not that which would be caused by muscular spasm and by inflammatory products in and about the joint, but is mechanical in its nature. The trochanter may be found slightly higher than usual, but great deformity is not present on inspection. The X-rays show a distorted

head, often a mushroom appearance, and bony thickening and excrescences.

Treatment.—As a rule this is not very satisfactory. The milder cases are relieved by the application of heat and by rest. All manipulation of the joint should be avoided as doing actual harm. The severe cases are best treated by radical measures. Albee's ankylosing operation of the hip converts a painful, slightly movable joint into a painless, ankylosed one and will probably give the best results. It consists in denuding the acetabulum and the head of the femur of cartilage and then of putting the joint up in slight abduction and slight flexion until ankylosis has taken place. The prospect of a good result from the so-called arthroplastic operation is not alluring. Naturally if an error in mechanics or a possible source of infection can be demonstrated, it should be removed before resort is had to operation.

In the knee this form of arthritis characterized by bony thickening is found quite frequently and affects both knees more often than both hips. Its cause, pathology and symptomatology are practically the same as in the hip. The joint may be in complete extension or in slight flexion. Slight thickening may be detected near the joint line, but the diffuse thickening of the capsule, so marked in the other type of arthritis is not common in this. Creaking and grinding may be detected on palpation. The Röntgen rays show the "lipping" at the circumference of the joint, and the new production of bone. Pain, as a rule, is not severe, but stiffness and disability are usually prominent features. Here, as in the hip, painless motion may be possible within certain limits, but motion is restricted at the extremes of flexion and extension.

Treatment.—The principles of treatment are the same as in the hip. For the milder cases, a brace may be worn which permits motion within the painless arc. In severe cases when one knee only is involved, a resection may be done, but if both knees are affected, this operation is contraindicated, and we must content ourselves with conservative measures, often most unsatisfactory.

The Ankle and Tarsus.—This form of arthritis is not very frequent in the foot, but it does occur. Probably it is responsible for much of the pain and stiffness in severe cases of flat-foot. In these cases after reducing the deformity under ether, and maintaining the correction by plaster of Paris for about six weeks, one should apply a Whitman flat-foot brace to prevent the recurrence of deformity. Otherwise the treatment of these cases is much the same as that recommended for the hip and knee.

Osteoarthropathies of the Tabetic Type (*Charcot's Joints*).—In the course of certain diseases of the spinal cord, notably in tabes and syringomyelia, a peculiar form of arthropathy occasionally occurs. This was first described by Charcot in 1868, in cases of tabes, and the condition still bears his name. But while the arthropathy occurs in patients who exhibit the classical signs of tabes, it also appears in cases in which these signs are few or indeed entirely absent (Barré, Les Osteoarthropathies du Tabes, 1912), and may precede the appearance of the tabetic signs many years. Not infrequently this condition is the first serious indication of the disease and may lead to the diagnosis of tabes or syphilis. The arthropathy, therefore, is not a manifestation of tabes *per se*, but rather a consequence of syphilitic infection. We may, therefore, following Barré, speak of an arthropathy of the tabetic type occurring in a patient who has syphilis, but who is not tabetic. In about 75 per cent. of the cases of tabes, the affected joints are those of the lower extremities. In a table of 268 tabetic arthropathies colleced by Chipault 207 were found in joints of the lower extremities, and of these, 120 involved the knee and 57 the hip-joint. Frequently the arthropathies are multiple, and then most commonly symmetrical, and joints which have been injured previously are more liable to be involved.

Premonitory symptoms may be absent in a large number of cases, but careful histories have revealed the fact that patients suffering from arthropathies of the tabetic type experience pain far more frequently than has generally been supposed. Particularly is this true in the cases of arthropathy of a tabetic type occurring in patients who have syphilis, yet who are not tabetic. *Painlessness* is, then, not a pathognomonic sign of the arthropathy but rather an indication of the existence of tabes. Contrary to the usual description of this affection, the onset of the arthropathy may be quite painful, and pain may persist for several months after the appearance of the effusion into the joint. Furthermore, as a prodromal symptom, pain may have existed for months or years before the onset of the arthropathy.

The onset is, as a rule, peculiar. With slight injury, which under ordinary conditions would be quite inadequate to produce any serious result, or without known cause, the joint suddenly becomes swollen to a degree rare in any other condition. The extent of the swelling varies within the widest limits, and as a rule extends far beyond the limits of the affected joint. The whole or greater part of the limb may become infiltrated, and the swelling is a solid œdema which pits but slightly on pressure. Extreme distention renders the skin over the af-

fected joint white and shining and the subcutaneous veins become quite prominent. The joint swelling is due to a hemorrhagic effusion, in many cases almost pure blood; later this becomes a reddish yellow fluid, always viscid and never a purely serous exudate.

The Wassermann reaction in the exudate is always positive. As has been said, the onset of the arthropathy may have been preceded by pain. This may have existed for some t me and may have involved both extremities, while the arthropathy is confined to a single joint. Examination of the articulations at the time of onset of these pains may have been negative, and the diagnosis of sciatica made. Spontaneous pains may exist in the affected joint and be quite severe at the onset of the arthropathy, and these may continue for days or weeks. The pain is often less in the morning and worse in the evening and may simulate the pains of acute rheumatism. They have been described as tearing or grinding. Further, pain may be well localized to definite points about the joint (*e.g.*, knee and ankle), and in this respect resembles tuberculous disease of the joint. Pressure on one of these points elicits pain which gradually increases in severity and does not reach its maximum for some hours or even days (Barré). In the arthropathies of a tabetic type in patients presenting signs and symptoms of tabes, *pain* is notably absent, and because of this the patient gets about and even continues to work until extensive destruction of the joint makes locomotion impossible.

Crepitus, so distinctive of this condition, often precedes the arthropathy. It varies in character with the amount of destruction in the joint. In the hip-joint it is often a fine crepitus, not unlike that felt in a normal joint. Crepitus has been described in different joints in various ways. It has been compared to that produced by grains of corn; to that produced by walking on a pebbly beach. Large crepitus of large elements has been likened to that felt when nuts within a sack are moved. It is described as hard or soft, as moist or dry crepitus. The patient often experiences crepitus or may be unconscious of it. He may hear it and describe it as a creaking in the joint. It is usually not painful, and though the patient may have pain in the joint, he is in most cases able to walk and this without accentuating the pain. The cause of these crepitations, especially the finer ones, has been shown in some cases to be due to hypertrophied, greatly developed buddings or fringes of synovia, plume-like, at the extremities of which are ovoid cartilaginous bodies the size of rice grains. In the ankle not only is fine crepitus felt, but at times there is a special rough rubbing like the attrition of osseous

or cartilaginous surfaces. An audible shock may be elicited in this joint when the bone ends are brought together. With extensive changes in the joint, deformities occur. There is no elevation of temperature, though locally the affected joint may, by palpation and comparison with its fellow, feel warmer. Redness is likewise absent.

The hip-joint is not infrequently affected by arthropathy of this type. Among 149 cases Flotow found unilateral involvement of this joint in 38 and bilateral involvement in 9. Arthropathy of the tabetic type in the hip may occur in one who has syphilis, yet who, upon the closest examination, presents none of the signs or symptoms of tabes, and without any history of trauma. An individual who has regarded himself as perfectly sound may, while in bed, notice a sudden swelling of the hip, or while convalescing from some acute disease find that his entire extremity from the hip to the foot has suddenly become swollen. Again, some trivial injury such as a misstep may precede the swelling. If non-tabetic, the patient often experiences pain in the joint and thigh. This is continuous or there are painful paroxysms, likened to a "knife thrust into the flesh." A careful history may reveal the fact that pain has existed for some time before the onset of the swelling. Because of the pain and swelling, the diagnosis of phlebitis or sarcoma of the femur may be made. The skin over the joint is tense and shining, the subcutaneous veins are prominent. Redness is absent. Comparison with the opposite unaffected hip joint reveals increase in temperature. Aspiration shows the effusion to be bloody and viscid in recent cases, reddish yellow in color at a later period. The swelling gradually subsides and the patient is able to get about with the aid of crutches or a cane. If pain is absent the disability produced by this, the grossest of joint lesions, is exceedingly small, and the patient often continues to walk or even work till the deformity becomes marked. The voluntary movements may be nearly normal, there being but slight impairment in flexion only. Finally shortening occurs (6 cm. or more), the ligaments are relaxed, there is an accompanying deviation of the pelvis with scoliosis. Dislocation occurs without any special violence. It may occasionally occur while the patient is in bed and be recognized by him. When the joint is considerably disorganized, abnormal mobility renders it incapable of supporting the body weight. Crepitus may be fine like that often felt in a normal joint, or a rough rubbing or grating sensation is felt.

If the cerebro-spinal system is not involved, the reflexes are normal, sensibility is preserved, bladder and rectal functions are normal and

there is no increase in the number of lymphocytes in the spinal fluid, neither does this react positively to the Wassermann reaction. The blood, however, may, and the effusion into the joint will be positive to the Wassermann test. If the onset of tabes has occurred, the reflexes will indicate this. The Achilles reflex, the first to disappear, is absent, or this with the knee reflex is absent. There may be a history of fleeting ocular paralysis, lightning pains and certain sphincter troubles. The Argyll-Robertson pupil may be present. The cerebro-spinal fluid generally shows an increase in the lymphocyte count and may give a positive reaction to the Wassermann test.

If now an X-ray examination be made, certain distinct and characteristic features will be observed. In the ordinary type of tabetic arthropathy of the hip-joint, the atrophic changes predominate and lead to a fairly rapid destruction of the upper end of the femur. This may appear as a pointed process corresponding to the great trochanter. The trochanteric region may be involved in the atrophy also. The pelvis on the same side is atrophic or some compensatory formation of osteophytes about the rim of the acetabulum is seen, but as a rule these are small. Hacker, in an open operation of one of these joints, found the cavity full of villous growths; the capsule, no trace of which could be found, was replaced by similar tissue. While the atrophic changes, as a rule, predominate in the hip-joint, a certain number of cases show an exception to this. The onset in these cases is likewise sudden, simulating a spontaneous fracture of the upper end of the femur, and examination of the joint reveals a large mass of bone enveloping the outer aspect of the os innominatum, or the bone mass may occupy the iliac fossa, extending into the lower quadrant of the abdomen, and the diagnosis of sarcoma be made (Furney).

The knee is the joint most often affected with this form of arthropathy. Among 74 patients with 112 joint affections Rotter found the knee-joint involved in 49, and in 26 cases of tabes with symmetrical joints involved there were 11 with bilateral disease of the knee. Occasionally the arthropathy begins before any of the signs or symptoms of tabes are present, but commonly it occurs in the preataxic stage. It develops suddenly without apparent cause or after some slight injury. The patient may awake in the morning to find that one of his knees is much swollen, or while he is walking his leg suddenly gives way under him. The joint becomes rapidly distended with fluid in a few hours or days, or the swelling may not reach its maximum for a week or two. The skin over the affected joint is normal in color or, if

distention is extreme, pale and shining. The venous network of the knee and leg is prominent and increased temperature is detected by comparison with the opposite joint.

The diffuse solid swelling in many cases involves the lower half of the thigh also. This pits but slightly on pressure. The extensive œdema has been explained as a dissemination of the effusion through a tear in the capsule, a condition which has been verified in the knee at autopsy. It is also considered to be the result of vasomotor disturbances. The swelling gradually subsides; the movements of the joint are at first little affected. Extension is normal, flexion is slightly limited and there is slight abnormal lateral movement. The patient walks about with apparently little or no pain. He may even continue to do hard work for years—six or more in reported cases (Barré)—before destruction proceeds to the extent of rendering walking impossible.

Examination in early cases reveals stretching of the soft parts and bony increase. By applying the palm of the hand to the affected joint and flexing and extending the leg, one feels crepitation. This is fine or coarse, hard or soft. The patient is often conscious of this crepitation; later there is definite creaking in the joint. It has been shown that crepitations in the knee are due in part, at least, to the existence of small ovoid cartilaginous blocks the size of rice seeds attached to the ends of plume-like fringes of the hypertrophied synovia. These may be felt on either side of the patella. Aspiration shows a reddish-yellow syrupy fluid containing many red and white blood corpuscles. This fluid gives a positive reaction with the Wassermann test.

Systematic examination shows, as a rule, impairment of sensibility. Deep sensibility may be absent. In some cases the patient is able to locate the position of his thighs and legs but fails to appreciate the position of the foot or more particularly the toes. The Achillis and knee reflexes are often absent and the Argyll-Robertson pupil present. The spinal fluid may show an increase in the number of lymphocytes and the blood and spinal fluid may give a positive Wassermann test. X-ray examination shows, as a rule, hypertrophic changes in the femur, tibia and patella. These are thickened by osseous growths. Osseous formation is often extensive and forms the most prominent clinical feature. Atrophy occurs, however, and affects the condyles of the femur and central portion of the tibia, but this is masked, as a rule, by the overlying bony deposits.

As has been said, the patient may get about for years after the

onset of the arthropathy and the subsidence of the swelling, and even be able to do hard work, the process appearing to come to a standstill or to progress very slowly. The articulation may rarely become fixed by bony ankylosis, but often the changes progress and, because of the absence of pain, the diseased joint is not favored and pronounced deformity results. Lateral movements are increased; abduction of the leg occurs, and this is increased by use of the limb, and the affected knee may strike the opposite limb and thus interfere with locomotion. Pronounced hyper-extension and abduction of the leg give rise to a genu valgum recurvatum, and finally the leg may hang flail-like from the thigh. Palpation reveals the presence of small and large irregular bodies in the knee-joint. These have been shown to be detached fragments of bone.

The ankle is affected less frequently than the knee or hip. Here, too, it may occur in a person who presents none of the signs of tabes. The onset is, as a rule, sudden, and in many cases is ascribed to slight trauma such, for example, as a slight twist of the foot while walking. The joint is enlarged by effusion, also by a thickening of the epiphyses of the tibia and fibula, and in severer cases it is usually loose. With a history of trauma the occurrence of slight pain, swelling, abnormal mobility and crepitus may lead to the diagnosis of fracture, and the parts be immobilized. After the swelling subsides, and upon removal of the splints, marked abnormal mobility, deformity and crepitus persist and lead to the recognition of the arthropathy. Pain may be present or absent. The effusion is similar to that found in other joints affected with an arthropathy of the tabetic type and gives the positive reaction with the Wassermann test.

Crepitus in these cases often has a special rough, rubbing character like that produced by the attrition of osseous or cartilaginous surfaces on each other. An audible shock is sometimes elicited in these cases when the bones are brought together. X-ray examination often shows the astragalus fragmented, and the fragments may lie as free bodies in the joint cavity. The articular surfaces of the tibia and fibula are widened and partly united to each other by growths of the periosteum. Fractures of the malleoli and pseudarthrosis are also found. Enlargement of the bones may suggest a bony tumor. Finally, as in the arthropathies of the tabetic type of the hip- and knee-joints, examination may or may not reveal the presence of tabes, and the same results in the examination of the systemic blood, joint effusion and spinal fluid obtain.

The Tabetic Foot.—Tabetic disease of the tarsus was described by Mr. H. W. Page in 1881, and by Charcot in 1883. This condition occurs frequently in the early stage of tabes and may be unilateral or bilateral. The process is apt to develop insidiously or abruptly. In some instances pain is absent; in others dull pain, a sense of heaviness, numbness or formication are present in the foot. If seen in the early stage, the only obvious change may be an abnormal thickening of the dorsum of the foot, but deformity, as a rule, develops rapidly in the course of a few weeks or months and may be fully established before the patient seeks advice. Besides the thickening on the dorsum, swelling in many cases is quite marked on the inner border of the foot, over the scaphoid and astragalus. The sole is flattened. Abduction, especially on the front part of the foot (tabetic talipes valgus), with eversion usually occurs, but adduction and inversion with extension (varus and equinovarus) may take place.

In some cases the toes look as if they arose immediately from the tarsus, the explanation of this being that the metatarsus may be dislocated either above or below the tarsus. The swelling of the soft parts of the foot is a hard œdema. The skin is often distinctly hypertrophied. Manipulation elicits crepitus which may be so distinct and diffuse that the foot may feel like a bag of bones. X-ray examination generally shows the malleoli much thickened and, in consequence of the collapse of the calcaneum, they may rest upon the ground. The bones of the foot are rarefied, their contours often obliterated or very much altered either by fracture or alteration of opposing surfaces. This condition may be accompanied by a perforating ulcer with necrosis of the metatarsus and phalanges, resulting partly, however, from infection, the ulcer having served as the atrium for the organisms.

Diagnosis.—Little difficulty in diagnosis exists if the possibility of the occurrence of the arthropathy in the non-tabetic as well as in the tabetic is kept in mind. A hemarthrosis, at first, may present similar signs and symptoms. This, too, occurs suddenly and either spontaneously or after some slight injury, without pain, fever or further functional disturbance. The hemorrhagic character of the effusion is similar also, but does not respond positively to the Wassermann test. A history of hemophilia and also of former attacks with rapid recovery, the youth of the patient, the pallor which often accompanies the condition will point to hemarthrosis.

Prognosis.—The prognosis as to complete recovery in these cases is bad, even though proper treatment be instituted at the earliest

possible date. In the benign affection the condition may progress very slowly or even come to a standstill, and this form is not incompatible with a fair degree of function for years. In the so-called malignant form, where rapid destruction of the joint structure occurs, the prognosis is quite unfavorable.

Treatment.—On the theory that the arthropathy of the tabetic type is the result of syphilitic arteritis and phlebitis, the administration of salvarsan and mercury would seem to be indicated and ought to prove beneficial. Clinically this is found to be the case in the early stage of the disease, but it is wholly without effect when the condition is more advanced. The effusion, when considerable, may be removed by aspiration, but it is very likely to recur. When the above procedures prove ineffectual, conservative treatment is usually best. A well-fitting brace will prevent further trauma to the joint and will often enable the patient to go about with comfort for years. Resections have been done with good result in the ankle, but with less beneficial results in the knee, bony union failing to take place. Amputations of the leg have also been successful, but surgical procedure is much more dangerous in the thigh.

Joints in Syringomyelia.—There is nothing absolutely distinctive of the arthropathies of syringomyelia which differentiates them from those occurring in tabes dorsalis and from certain cases of arthritis deformans. A large percentage of the joint affections in syringomyelia begin before the thirteenth year and occur in males about twice as often as in females. Arthropathies have been met with in several members of the same family. One or more joints may be simultaneously affected. They occur in about 10 per cent. of the cases of syringomyelia, and corresponding to the cord lesion, which in most cases involves the cervical and dorsal regions; the joints affected are most frequently those of the upper extremity, most often the shoulder and elbow. In tabes, on the other hand, 75 to 80 per cent. of the affected joints are those of the lower extremities. Atrophic and hypertrophic changes occur in the bones, as in the arthropathies of tabes. Rarefaction occurs and in advanced cases the bone gradually disappears. At the same time, a certain amount of hypertrophy with lipping of and overgrowth from the ends of the bones, together with periosteal thickenings, go on side by side with atrophy. A painless effusion into the joint occurs, the capsule and ligaments become relaxed and instability of the joints results. With involvement of the joints of the lower extremity there is often considerable destruction of the bone and cartilage from pressure. The

tendency to ankylosis is slight. Spontaneous dislocation is apt to occur and may be the first sign of the disease. Fracture of the bones near the affected joint occasionally results.

The arthropathy may develop suddenly and a history of trauma immediately preceding the onset of the joint symptoms may be given, or prodromal symptoms, such as localized or referred pain about the joint, may indicate the onset of the joint affection. The course of the arthropathy is, however, generally much slower than that of tabes. There may be a history of gradually increasing weakness, swelling, pain, abnormal mobility, and recurrent displacement of the affected joint, and this may have extended over a period of years before the more acute symptoms and increased disability cause the patient to seek treatment. Examination of the affected joint, *e.g.*, the knee, reveals swelling due largely to effusion into the joint sac, with some thickening of the peri-articular structures. The skin over the joint is tense, smooth and shiny, and the superficial veins distended. The end of the femur or tibia is usually enlarged and distinctly palpable. The lower end of the femur may be unnaturally prominent owing to backward displacement of the tibia. Examination may also reveal increased knee reflex, a spastic condition of the legs, loss of sensation of pain and temperature, but retention of the tactile and muscular senses. Because of the loss of pain and temperature sense, the parts are more liable to injury. In the feet symmetrical ulcers often develop on the balls of the great toes. These may perforate into the joint, and suppuration may follow. Occasionally loss of toes and great deformity of the foot result. Absence of pain in these cases is shown by the fact that the patients can walk about in spite of extensive destruction of the affected parts.

Diagnosis is established by the presence of signs and symptoms of syringomyelia. "The combination of an amyotrophic paralysis, the picture of progressive muscular atrophy of the Aran-Duchenne type with retention of tactile and loss of thermic and painful sensation, is probably pathognomononic of the disease" (Osler, "The Principles and Practice of Medicine," 8th Edition, page 965.)

Prognosis for the arthropathy is very unfavorable . In some cases rapid destruction of the joint may occur, but in the majority the pathologic process may be slow and function of the joint is not materially interfered with for years.

Treatment.—Some form of orthopedic apparatus to protect the joint from injury or dislocation and to aid function should be used. Aspiration of the exudate, followed by pressure with a bandage, will often

prevent reaccumulation of the fluid. As a rule, operative procedure is not indicated. Slight operations for the removal of sequestra and the curetting of fistulas may be done and may be performed without anæsthesia. If suppuration occurs, arthrotomy and drainage are generally ineffective and resection or amputation is usually required.

Loose Bodies in the Joints.—*Loose cartilages*, joint mice, floating or movable bodies, etc., are terms applied to movable, free or partly free bodies, which have their origin in the joints and which act as sources of irritation to the joint structures. There may be one, two, or even hundreds of these bodies present in a single joint, and they may be free, or connected to the articular surfaces or to the synovial membrane by delicate pedicles. They may lie free in a joint recess or diverticulum, and cause no trouble, or they may glide about in the joint cavity and occasionally cause "locking" by getting caught between the articular surfaces during the ordinary movements of the joint. In size they vary from that of a small pea to that of a plum or hen's egg, and are of various shapes, flat, ovoid, spherical, pyriform with smooth or irregular surfaces. They vary in consistency and density; some are quite soft, others are very hard. They are usually white or yellow in color.

Mode of Origin.—Loose bodies may be of more than one order and may be classified as follows:

1. *Fribrinous Loose Bodies.*—These are small translucent homogeneous or laminated, rice-grain-like bodies, composed of hyaline material, with occasional indications of cells. These so-called corpora oryzoidea, are not uncommon in tuberculous synovitis or bursitis, arthritis deformans and Charcot's disease, and are regarded as hyaline fibrin or as disassociated portions of necrosed granulation tissue. These bodies are not peculiar to joints, but are found in tendon-sheaths and enlarged bursæ, whether they communicate directly with or are completely separated from a joint. They are more frequently found in the smaller articulations than in the knee and it is thought that they always arise from a degeneration of the synovial membrane. They are nearly always accompanied with a varying amount of chronic effusion.

Clinically they differ from other varieties of loose bodies in that they never produce "locking," and they are usually recognized by the crepitating sensation imparted to the examining finger as they roll upon one another in the synovial effusion during passive movements of the joint.

Treatment is directed chiefly toward the primary disease.

2. *Loose Bodies of Connective-tissue Origin.*—These bodies are found as the result of trauma as well as disease. As the result of chronic irritation to the synovia occurring in arthritis deformans, Charcot's disease or repeated and intermittent traumatism, the synovia becomes thickened, roughened and papilliform. From time to time, even during ordinary movements of the joint, the hypertrophied synovial fringes are caught between the articular surfaces and traumatized. As the result of repeated irritation, fatty, fibrous, cartilaginous tissue, or bone, or combinations of these tissues develop in the villi which gradually increase in size and become pedunculated. Finally, during some forcible movement of the joint, they are nipped off between the articular surfaces and lie free in the joint sac.

Under this caption are included, also, detached osteophytes and marginal ecchondromata found in Charcot's disease and arthritis deformans. When they are the result of some constitutional disease, the clinical features are chiefly those of the primary disease, and their removal is indicated only when necessary to relieve pain or restore motion. The commonest variety of loose bodies which gives rise to the classical symptoms of the condition, and for which surgical operation is most frequently performed is that which arises as the result of chronic irritation of the synovial membrane in a more or less healthy joint. This condition is most commonly met with in men of middle age, though athletic and active women are not exempt. The knee is the joint most frequently affected, though occasionally other joints, shoulder and elbow, are involved. The condition results most frequently from injury, but whether the primary synovitis was of traumatic or of infective origin, the resulting hypertrophied synovial villi are productive of further irritation and synovitis. With continued mechanical irritation the villi enlarge by fibrous tissue proliferation. Cartilage develops in those most subject to repeated trauma; they become larger and pedunculated and finally are nipped off by some sudden movement of the joint and lie free in the joint cavity.

Symptoms.—The symptoms vary. The patient may complain of vague pains or occasionally of creaking in the joint during the ordinary movements or in some simple movement as in rising after resting. In most cases, however, there is a history of one or more attacks of sudden "catching" or "locking" of the joint while in the act of stooping, walking, running or even in some simple movement, such as turning in bed, the joint suddenly becomes fixed in a position of partial flexion. This "locking" of the joint is attended by severe

agonizing pain. The pain is often so intense that the patient falls to the ground, becomes nauseated and faints. Extension and flexion are impossible until the body slips from between the articulating surfaces, and this may ocur in a moment or two or the joint may remain "locked" for hours. Sometimes by gentle manipulation the body is dislodged; at other times the joint remains "locked" and any attempt to move it causes recurrence of severe pain. "Locking" is followed by a serous effusion, which may gradually subside in a few days. The joint is left in a weakened condition and often remains a little swollen. The attack is very likely to be repeated. With repetition of the attacks the joint becomes more tolerant and the symptoms less severe. A small body is more liable to cause locking than a large one, but the large body is more difficult to disengage once it is caught. The patient can frequently feel the body and it can sometimes be pushed into a superficial area where it can be palpated and slipped about. The place where they can be detected externally is in the pouch over the external and internal condyle of the femur, or at the inner side of the patella. If the body is dense, X-ray examination may reveal it, but in interpreting the radiogram one must remember that a sesamoid bone in the internal head of the gastrocnemius may cast a shadow, which may be mistaken for a loose body.

Diagnosis.—If there is a history of previous attacks of "locking" with well pronounced symptoms, and the finding of a movable body which can be slipped from place to place, the diagnosis is not difficult. In some cases of loose body in the knee-joint, it may be impossible to differentiate the condition from *dislocation of the semilunar cartilage*, *inflamed synovial villi* and *joint lipoma.*

Loose bodies can usually be found and isolated by the patient. They often cause locking of the knee but this is, as a rule, only transitory. The symptoms are sharp, but not acute, and unless the body is pedunculated they may be referred to different parts of the joint. Effusion is common.

With injury to the medial semilunar cartilage, the history of the mode of production is helpful. The onset is acute, there is persistence of pain, usually referred by the patient to the front of the joint until pressure localizes it over the injured cartilage. Tenderness is marked in a limited area over the head of the tibia. Irregularity may be found along the articular margin; the protrusion of the detached semilunar may be felt. A sense of discomfort is experienced when the tibia is abducted and rotated outward. Injury to the lateral semilunar car-

tilage gives rise to a similar train of symptoms occurring on the outer side of the knee.

Symptoms of nipping of a synovial fringe are not so acute in its primary occurrence. Pain is strictly local. Frequently a prominence may be found over the site of the pain, but this is not freely movable. Effusion is always present. Creaking in the joint is a frequent accompaniment, and swelling due to chronic thickening of the fringes occurs at the sides of the ligamentum patellæ.

Joint lipomata sometimes cause locking. The symptoms are rarely acute, often painless, and pressure on the knee does not produce pain. Swelling, as a rule, is dense, and most often at the sides of the patellar tendon.

Treatment.—Loose bodies in the joint, especially in the knee, are sources of danger, for locking may occur while the patient is at work, while descending a stairway, or while walking in the street, and he may fall and sustain serious injuries. To relieve locking, manipulation with forced flexion and sudden extension often dislodges the body. Unless the most rigid aseptic precautions can be carried out, especially where the loose body gives rise to little or no trouble, operation is contraindicated. In cases where there are a number of free bodies, and their presence is associated with arthritis deformans, and the joint is considerably impaired, their removal will prove of little, if any, benefit. If one or more loose bodies of fair size can be detected in a healthy adult, operation is indicated, but it is to be remembered that operation does not cure the causative lesion and bodies may reform.

Operation is performed under artificial ischæmia. Strict asepsis must be observed, the loose body brought to a point where it can be felt by the surgeon and fixed in position by a needle passed through the skin. Location and fixation of a loose body in the knee should always be the rule of procedure before operation. If the body cannot be palpated when the patient is placed upon the operating table, it may be made to appear by manipulation of the joint. This should be done before a general anæsthetic is administered. If the loose body slips from view into a recess of the joint during operation, pressure at different points and movements of the joint may force it into view. The joint is opened, the body removed and a careful exploration for other bodies is made. The wound is sutured and dressed, and the joint immobilized by a splint for a week or 10 days; passive motion is begun after a few days. Local anæsthesia may be sufficient in some cases.

Hemarthrosis (Hemophiliac joint).—This comparatively rare joint lesion is met with occasionally in "bleeders" and like other manifestations of the diathesis occurs exclusively in the male sex. It occurs with greatest frequency in the knee, though other joints (hip, ankle, elbow) are sometimes affected. The predisposing cause is as yet unknown, though in hemophiliacs there is a delay in the coagulability of the blood. Addis has shown that the coagulation time may be delayed as much as 40 to 60 minutes. The exciting cause is some slight trauma, in many cases too slight to produce harmful results in a normal joint. As a result of this, hemorrhage occurs into the synovial membrane and into the joint cavity. The presence of blood in the joint is a source of irritation and the synovial membrane proliferates, sometimes enormously, to form the well-known reduplication of villi, *i.e.*, a typical villous arthritis results. The fluid may be absorbed rapidly or it may persist for a considerable length of time. The whole trouble often subsides, but more or less swelling may persist for a time and even if recovery does take place, relapse is likely to occur. Fibrin is deposited on the surface of the synovia, and becomes organized. Erosion of the cartilage, due probably to impairment of the blood-supply resulting from the damaged vessels, takes place, and dense adhesions form, which limit motion and produce fibrous ankylosis.

Symptoms.—The clinical picture is more or less characteristic. Usually after slight trauma or without any history of trauma whatever, the joint swells with sometimes much, sometimes little, pain or discomfort according to the rapidity of accumulation of blood. As a rule, pain is not a prominent symptom. Examination reveals a swollen joint. Tenderness and increased local temperature may be present. Fluctuation can be elicited but is not so evident as in cases of serous effusion. Motion of the joint is not restricted in early cases unless effusion and pain are marked. The knee is usually held in semiflexion. In later or old cases, especially after several attacks, adhesions interfere with motion. Discoloration of the skin may appear. There may be considerable elevation of temperature, due to the absorption of blood.

Diagnosis.—This is made on the family history, history of the individual and symptoms. A sudden swelling of a joint without sufficient cause should always arouse suspicion of hemophilia and should occasion a rigid inquiry into the family history and into the past history of the patient for occurrences of bleeding. As a rule, the diagnosis is not difficult if the possibility of the condition (hemophilia) be kept in mind. The condition is to be differentiated from tuberculosis, inter-

mittent hydrops, syphilitic synovitis and Charcot's joint. In the active stage of tuberculous disease of the joint the differentiation can be made only by a careful history. It is of great importance that an accurate diagnosis be made, for fatal hemorrhage has followed operation on these joints.

Intermittent hydrops presents in its typical manifestation a characteristic periodicity of attacks, a regular cycle and a slower onset. It occurs also in the female.

Syphilitic synovitis will be accompanied by other stigmata of syphilis, is slower in its onset, more chronic in its course and yields rapidly to antisyphilitic treatment.

Charcot's Joint.—The signs and symptoms of tabes, the para-articular swelling, the evidences of bony changes, both clinically and skiagraphically will make the nature of this condition plain.

Finally in the late course of hemarthrosis, the lesion may be mistaken for an old case of infectious arthritis, tuberculous or non-tuberculous. Nothing remains except the evidence of a dense fibrous ankylosis in one or more joints and it is only by careful inquiry into the history that one can reach an accurate diagnosis.

Treatment.—Rest and protection, moderate pressure and the application of cold, furnish the chief local measures. Little can be done to favor absorption. In severe cases horse serum (diphtheria antitoxin in case of need) rabbit or normal human serum, and transfusion of blood, have been used, and in some cases with apparently good results. Operative treatment is contraindicated.

Gouty Arthritis.—The chief importance of this form of arthritis to the surgeon lies in the fact that it may be mistaken for other forms of joint inflammation. It occurs as an acute or chronic inflammation of one or more joints. In the *acute* form, the onset is usually sudden, the attack occurring during the night, and is characterized by severe, agonizing pain in the metatarso-phalangeal articulation of the great toe, most often the right. The joint swells rapidly, becomes hot, red, shiny, œdematous and is extremely sensitive, and its appearance resembles gonorrhœal or acute suppurative inflammation. Sometimes the attack is preceded by twinges of pain in the small joints of the hands and feet, indigestion and nocturnal restlessness. The general temperature may rise to 102°–103°F. After a few hours the pain subsides rapidly but the joint remains swollen and the patient may pass a comparatively comfortable day, but he suffers a recurrence of pain during the next night. The symptoms recur each night for a week or

so, gradually becoming less severe and finally the swelling subsides without leaving any obvious change in the joint. The general condition remains good.

With repeated attacks the joint symptoms persist for a longer period and gradually a number of joints, ankle, knee, wrist and the small joints of the hands, become affected. Deposits of urates occur in the articular cartilages, capsule and ligaments, and in severe cases extensive concretions form about the joints and along the tendon sheaths and in the bursa. The skin over these may ulcerate, and the chalk stones are freely exposed. Several joints may become stiffened and deformed. Intercurrent attacks of acute polyarthritis may occur.

Diagnosis.—With a history of gout in the family, and one or more attacks of acute arthritis limited to the metatarso-phalangeal joint of the great toe, especially the right, the diagnosis is not difficult. The real difficulty arises in acute cases with fever and pain, swelling and redness in a joint (*e.g.*, knee) other than the characteristic one. Such cases, if not gout, are some form of infective arthritis. If the exudate is purulent, the arthirits is not gout, for in acute gout, however intense the inflammation may be, suppuration does not take place. If more than one joint is involved in acute arthritis at the same time, the probability is against gout, and the greater the number of joints affected the less likely is the case one of gout. The presence of tophi is often conclusive. The involvement of the tendon sheaths about the ankle and pain in the back of the sole of the foot occur in gout and in gonorrhœal infection. The presence of a source of infection in the genito-urinary tract speaks for gonorrhœal arthritis and tenosynovitis.

Chronic gout may be difficult to differentiate from arthritis deformans. The detection of sodium biurate, usually as white hard masses in connection with the gout, bursa, etc., a family history of gout, a history of previous acute attacks, will aid in establishing diagnosis. The presence of osteophytes is strongly against gout, but it is not conclusive, for these may occur in true gout, either more or less all around the joint or as small nodules, but they never become the large size common to arthritis deformans. Gout rarely attacks the shoulder- or hip-joints which are commonly involved in arthritis deformans. Urinary examination in gout shows the uric acid output usually very low during the intervals of the paroxysms. This increases greatly, as a rule, during the height of the attack.

Treatment of gout belongs to internal medicine. The only operative procedure to be considered is the removal of large chalk stones in the

soft tissues and amputation of deformed or infected toes or fingers. Removal of masses of urates with the curet, is not, as a rule, successful, for the tissues rarely react to form healthy granulation tissue and new deposits are very likely to form.

BURSÆ

Bursae are sacs varying in size and normally containing a small amount of fluid. They are interposed between structures in various places in the body where friction occurs; usually between skeletal parts and tendons, muscle or fascia, between tendons, muscles and tendons, or fascia and tendons. Their function is to diminish friction and to permit of a gliding movement. Many are present at birth, but new ones may appear in situations exposed to uncommon pressure or friction. The wall of a bursa is composed of condensed connective tissue, lined more or less with a cellular lining. The contained fluid is of the nature of synovia.

A distinction is to be made between *normal bursæ*, or those which are present from birth, or formed later as growth and development occur and fuller functional activity is assumed; and *adventitious bursæ* which arise from pressure applied to the body surface over bony prominences. Adventitious bursæ may be classified into two groups: one includes all those bursæ which arise in connection with the various occupations, or the wearing of badly fitting apparel, as shoes; the other group includes those which arise from pressure produced in some unusual place through deformity. Those falling into this latter group may be considered as strictly abnormal. Examples of the first group are the "housemaid's knee," "miner's elbow" and those bursæ which appear over the malleoli and tendo Achillis; the second group includes those bursæ which are produced over the cuboid in talipes equinovarus, over the medial condyles of the femora in bad cases of genu valgum and under callosities.

The anatomical classification of bursæ indicating relations is of practical surgical importance. Anatomically, they constitute two divisions, the *bursæ mucosæ* and *bursæ vaginæ*. The latter are the synovial sheaths of tendons.

The bursæ mucosæ seem to be little more than exaggerations of the spaces between the layers of areolar tissue or of existing lymph spaces. From their position and relation, they can be classified as subcutaneous when developed beneath the superficial fascia; subfascial

when situated beneath the deep fascia and between it and some bony prominence, muscle or tendon; submuscular when between two muscles, a muscle and some skeletal part, or between a muscle and a tendon; subtendinous when intervening between a tendon and a bone, tendon and ligament, or between two tendons; intratendinous when located within a tendon.

Bursæ vary greatly in numbers and size and under unusual pressure or friction may become enormously enlarged and inflamed, constituting a bursitis which necessitates surgical treatment. Attention to the relations of the various bursæ will explain the serious consequences that may follow an acute suppuration of a bursa, which, when in relation to a bony surface, may give rise to caries, or a superficial necrosis, while subacute or chronic inflammation may lead to thickening of the bone from osteoplastic periostitis, or when in relation to a joint may bring about serious complication or disease in the joint.

The bursæ of the lower extremity may be conveniently considered under three groups: *first*, those in the vicinity of the hip-joint; *second*, those about the knee; *third*, those of the ankle and foot.

Bursæ in the Vicinity of the Hip-joint.—The number of bursæ about the hip-joint varies from 14 (Heineke) to 21 (Synnestvedt). Various authors describe a total of 31 (Bryant and Buck).

The *subcutaneous trochanteric bursa* is situated over the trochanter major, between the integument and the deep fascia. It is inconstant. When inflamed, according to Berend, it forms an oval subcutaneous swelling in the long axis of the limb. The mobility of the tumor is limited by its position, and it is not displaced by movements of the limb. The skin is usually normal and movable over it. When inflamed, it has to be differentiated from an inflamed great trochanteric bursa, which is located beneath the aponeurotic tendon of the gluteus maximus. When diseased, the subaponeurotic bursa presents the surface form of a rounded or ellipsoid swelling, which obliterates the hollow behind the trochanter and slides backward in flexion of the limb.

The *bursa of the great trochanter* separates the broad tendon of insertion of the gluteus maximus from the lateral surface of the trochanter major. It is usually large, simple or multilocular, and is always present. Its walls are usually weak at three points, behind, in front, and below. It is these thin places which give way when suppuration has taken place. In beginning inflammation, tenderness is present over the site of the bursa. Pain is experienced upon movements of the limb and especially on attempts to voluntarily rotate the limb outward;

the pain is greatly augmented when the limb is held firmly in counter-rotation by the examiner. When the bursa becomes distended with fluid, a rounded or ellipsoid swelling presents, which obliterates the hollow behind the trochanter. When extensive, the gluteal fold may be obliterated. The tumor may be divided into two parts by the muscles. When acutely inflamed it may be accompanied by abduction and eversion of the limb, in order that the gluteus maximus may be relaxed as much as possible. Consequently the condition may somewhat resemble the earlier stages of hip-joint disease, from which it can be differentiated by the absence of flexion (Rose and Carless; Bryant and Buck), although flexion is said to be present by Deaver, Bergmann and Bull, and the fact that passive movements, including the so-called test movements for hip disease, can be made with little or no pain. It is to be noted that in these cases there is an absence of swelling of the hip-joint, and that the head of the femur can be rotated in the acetabulum without exciting pain. When suppuration occurs, the pus may burrow extensively beneath the gluteus. The sciatic nerve may be involved and cases are known in which it was infiltrated and displaced.

The *gluteo-femoral bursæ* are two or three small bursæ interposed between the lower part of the gluteus maximus and the femur posteriorly, and the vastus lateralis anteriorly above its insertion into the gluteal tuberosity of the femur. When one or the other of these bursæ is inflamed, there will be tenderness over and just above the point of insertion of the gluteus into the femur and just below the great trochanter. Pain is intensified by contraction of the gluteus maximus and there is apt to be abduction and eversion of the limb. When marked distention of the inflamed bursa has occurred, there will be an elastic swelling that will present either below or above the tendon of insertion of the gluteus into the femur. When it presents below, the lateral portion of the gluteal fold will be obliterated; when above, the swelling will be below or even over the lower part of the great trochanter. When the bursa between the gluteal tendon and the vastus lateralis is inflamed, the tenderness and swelling will be in front of the gluteal tendon. In suppuration of the diseased bursa the pus will burrow, as in case of the bursa of the great trochanter. The sciatic nerve may be involved in severe cases.

An *ischio-gluteal bursa* is frequently present beneath the gluteal maximus where it passes over the ischial tuberosity. It may become inflamed in those who sit a good deal, such as coachmen, weavers, etc., as it is pressed upon in the sitting position. When inflamed, it causes pain

and great discomfort in sitting. It is commonly known as "*weaver's bottom*." The swelling may be solid and symmetrical. It is easily diagnosed from its position and the history of the person's occupation. It may press on the inferior pudendal nerve and cause pain and functional disturbance in the area of distribution of the nerve.

There are four bursæ, other than those already enumerated, in close proximity to the great trochanter. Two of these are in relation with the gluteus medius as follows: an anterior trochanteric bursa is interposed between the tendon of the gluteus medius and the summit of the great trochanter. A posterior trochanteric bursa is usually present between the tendons of insertion of the gluteus medius and the pyriformis. A trochanteric bursa for the gluteus minimus is present between the tendon of insertion of the gluteus minimus and the great trochanter, while the bursa of the pyriformis muscle intervenes between the tendon of insertion of the pyriformis and the summit of the great trochanter. These four closely associated bursæ are particularly related to the summit of the great trochanter. In case of inflammation of either one of these bursæ, tenderness and pain will be present on pressure. Contraction of the related muscles will likewise be painful. When distention of the bursa has taken place an elastic or doughy swelling will be felt in relation to the trochanteric summit and the tendons of the muscles inserted into it. The symptoms will be less pronounced than in inflammation of the great trochanteric bursa, which lies over the lateral surface of the trochanter. Tests to show absence of pain or tenderness in the hip-joint will eliminate coxitis.

A bursa is interposed between the internal obturator and the medial surface of the ischial tuberosity at the point where the muscle leaves the pelvic cavity, and is reflected at right angles as it escapes through the lesser sciatic notch. At this point the ischium is grooved for its reception, the latter being covered with cartilage and lined by the synovial bursa. A second bursa is usually present between the tendon of the internal obturator and the posterior surface of the capsular ligament of the hip-joint. This bursa is narrow and elongated in form and occasionally communicates with the ischial bursa, the two forming a single sac. The close relationship of these bursa to the hip-joint, especially the capsular obturator bursa, necessitates great care in differentiating, on the one hand a bursitis, and on the other an intracapsular inflammation or coxitis. When the ischial obturator bursa is inflamed, much can be determined by direct pressure through digital examination per rectum. Direct pressure upon the point of exit from the pelvic cavity of

the obturator tendon will locate tenderness and pain at that point. Possible continuity between the two obturator bursæ must be borne in mind. Inflammation of a simple capsular obturator bursa will have to be eliminated by tests indicative of the presence of a coxitis.

The large *iliopectineal bursa* which intervenes between the common tendon of the iliopsoas in front, and the eminentia iliopectinea superiorly, and the capsule of the hip-joint inferiorly, is situated anteriorly to both of these latter structures, and all are contained in the lacuna musculorum, along with the femoral nerve. This bursa is important, not only on account of its size, but because it often communicates with the hip-joint. When inflamed, tenderness and pain are present in the lateral portion of Scarpa's triangle and over the hip-joint; the swelling may become large and fluctuating, project anteriorly enough to obliterate the inguinal groove, and present in the medial portion of the triangle. The tumor may press on the femoral nerve and cause pain and functional disturbance in the area of its distribution. If tenderness and pain are present, there will be flexion of the thigh with increase of the pain upon extension. These symptoms resemble psoas abscess and hip-joint disease and the pain is often referred to the knee, as in hip disease. The surgeon, when operating, must remember that the bursa often communicates with the joint cavity, and that it lies in immediate contact with the articular capsule. It is best reached by a vertical incision external to the femoral artery, the fibers of the iliopsoas being retracted inwardly or cut, if necessary.

The following seven bursæ are of minor importance and are distributed as follows: A subtendinous iliac bursa is interposed between the tendon of insertion of the iliopsoas and the femur at the trochanter minor. There intervenes between the pectineus and the medial surface of the trochanter minor and tendon of the iliopsoas the pectineal bursa. At the point where the deep surface of the quadratus femoris and the trochanter minor come in contact, a bursa is interposed. Frequently a bursa lies between the surface of the ilium and the reflected head of the rectus femoris which is inserted above the acetabulum. The superior bicipital bursa is sometimes found separating the common tendon of the semi-membranosus. An anterior subcutaneous iliac bursa may be present over the anterior-superior-iliac spine, as well as one over the posterior iliac spine.

Bursæ about the Knee.—In the adult there are usually 12 bursæ about the knee, seven of which are in relation with the boundaries of the popliteal space. A subcutaneous *prepatellar bursa* is present in

88 per cent. of cases (Bize) over the lower half of the patella, and it is usually single. It is very often inflamed and enlarged in those who kneel much, as housemaids, stone masons, religieuses, etc. When acutely inflamed, it is very painful. Suppuration of this bursa has caused caries of the patella. Its enlargement constitutes "*housemaid's knee.*" This bursa may be multilocular, and superimposed bursæ in this situation have been described. Their presence would account for the recurrence of bursal swellings after excision; they may even develop *de novo*. Occasionally a bursa is present between the expansion of the fascia lata and the quadriceps and the patella. It lies more often over the lower and inner parts of the patella. A subtendinous bursa may sometimes be present between the quadriceps tendon and the anterior surface of the patella. A deep *infrapatellar bursa* of small size intervenes between the upper part of the tuberosity of the tibia and the ligamentum patellæ. It is separated from the synovial membrane of the knee-joint by a pad of adipose. When distended, it forms a fluctuating swelling which obliterates the depression each side of the ligament and is compressed between the patellæ and tibia. Chronic enlargement may cause the ligamenta alaria to be pushed backward into the joint so that they are apt to be nipped between the bones when the individual attempts to stand with the leg extended. The pain induced is somewhat similar to that caused by a displaced meniscus. Subcutaneous tibial bursæ are found over the tuberosity of the tibia and may become irritated from much kneeling. A *suprapatellar bursa*, which in the majority of adults communicates with the synovial sac of the knee-joint, intervenes between the anterior surface of the lower end of the femur and that part of the quadriceps tendon formed by the tendon of the crureus. It is usually of good size. Synovitis of the knee with distention of the synovial sac occasions a prominence immediately above the patella, while on greater distention it will extend to a greater distance above and to the sides of the patella, forcing its way beneath the surrounding muscles which, in this situation, are connected to the femur by loose connective tissue. A bursa exists between the subcrureus muscle and the femur; in the adult it communicates with the synovial sac of the knee-joint.

The *bursa anserina* is a fairly large bursa and is situated between the tendons of insertion of the gracilis and semi-tendinosus muscles and the tibial collateral ligament of the knee-joint. It may communicate with the bursa of the sartorius which intervenes between the tendon of the sartorius above its insertion and those of the gracilis and semi-mem-

branosus muscle. In acute inflammation of these bursæ, tenderness and pain are present over the superior and medial surfaces of the tibia.

The bursæ about the popliteal space are somewhat irregular. In the medial boundaries of the space will be found a bursa which frequently communicates with the synovial cavity of the knee-joint, is interposed between the medial head of the gastrocnemius and the capsule of the knee-joint and medial condyle of the femur; another bursa separates the tendon of insertion of the semi-membranosus from the medial head of the gastrocnemius. It also often communicates with the synovial cavity of the knee-joint. These two bursæ are in communication and in reality constitute a rather large double bursa. Usually there is a small lateral bursa of the semi-membranosus muscle separating the tendon of the semi-membranosus from the medial condyle of the tibia; it seldom, if ever, communicates directly with the knee-joint, but it may communicate with the large double bursa. The lateral boundaries of the popliteal space contain the following: Intervening between the lateral head of the gastrocnemius and the articular capsule and lateral condyle of the tibia there is the *lateral bursa of the gastrocnemius.* It is frequently in communication with the synovial cavity of the knee. Almost constantly, the tendon of insertion of the femoral biceps is separated from the fibular collateral ligament of the knee-joint by the *inferior bicipital bursa* over which runs the peroneal nerve, while more rarely a bicipito-gastrocnemial bursa is interposed between the tendon of insertion of the femoral biceps and the lateral head of the gastrocnemius. Beneath the popliteus and the capsule of the knee-joint a bursa intervenes, while another separates its tendon of origin and the lateral condyle of the femur. It is to be noted that the synovial membrane of the superior tibiofibular articulation is occasionally continuous with that of the knee-joint through the latter bursa.

Bursæ about the Ankle and Foot.—The more important bursæ about the ankle and foot number about ten. Holden has described the frequent occurrence of a large irregular bursa between the tendons of the extensor digitorum pedis longus and the underlying prominent head of the talus. This bursa is of interest because it sometimes communicates with the mediotarsal joint. Between the tendo calcaneus (Achillis), just above its point of insertion and the upper part of the tuber calcanei, a *retrocalcaneal bursa* is interposed. Badly fitting boots may produce an inflammation and enlargement of this bursa. When distended, it presents a fluctuating swelling on either side of the tendo calcaneus, with obliteration of the normal depression which exists

there. This condition is known as *Albert's disease* or achillodynia. The bursa may become cartilaginous, or osteophytes may form on the surface toward the calcaneus. A subcutaneous calcaneal bursa lies beneath the skin over the tendo calcaneus. When inflamed or distended, it is easily recognized as being superficial to the tendon. It is not uncommonly initiated by the shoes or particularly by the high, heavy boots frequently worn for the first time on a camping or climbing trip. Another, the inferior subcutaneous bursa of the heel, may be present on the sole of the foot, beneath the tuberosity of the calcaneus. Subcutaneous bursæ are present over the malleoli. They are inconstant. The one over the lateral malleolus, when inflamed, is known as the "*tailor's bursa.*" Sometimes a posterior tibial bursa is present between

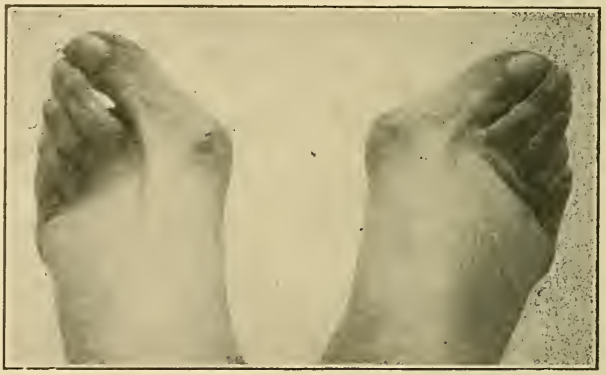

Fig. 387.—Hallux valgus and bunion.

the tendon of the posterior tibial muscle and the tuberosity of the scaphoid bone, while another usually intervenes between the tendon of the tibialis anterior and the first cuneiform bone. Bursæ are interposed between the ends of the tendons of the lumbrical muscles and the transverse capitular ligaments. The three medial are more constant than the lateral. Four intermetatarso-phalangeal bursæ are found between the contiguous sides of the heads of the metatarsal bones and dorsal to the transverse capitular ligaments. One of the most frequently inflamed bursa is the normal or sometimes adventitious bursa which intervenes between the skin and the metatarso-phalangeal joint of the great toe. When the great toe has been forced outward (hallux valgus) and the metatarso-phalangeal joint is made unduly prominent from badly fitting shoes, or in pes planus, undue pressure and friction result. A bursitis is developed, which is commonly called a "*bunion*" (Fig. 387). Under such circumstances, the bursa becomes distended

and the surrounding connective tissue undergoes condensation, the medial lateral ligament becomes elongated, and the head of the first metatarsal bone becomes enlarged; the cartilage over its medial articular surface may atrophy and disappear, a communication being finally established between the bursal sac and the synovial cavity of the joint.

A knowledge of the existence and location of the above mentioned bursæ of the lower extremity may explain many cases of obscure pain following pronounced violent exertions as climbing, fencing, boxing, wrestling, tennis, football, etc., and account for some deep-seated abscesses of obscure origin. In some cases calcareous deposits may occur in bursæ, giving rise to persistent pain when certain movements are made; such a condition is usually readily detected by use of the X-ray and usually calls for excision of the affected bursa.

Acute inflammation of a bursa usually rapidly subsides with rest and the avoidance of motions calling into play the muscles or tendons involved, and usually no other treatment is required. Continuance of the irritation is apt to be followed by thickening of the walls of the bursa and a progressive increase of the quantity of fluid it contains, the condition passing into one of chronic inflammation. Not infrequently the inflammation is chronic from the start and attended with but little or no pain till the bursa has attained a considerable size; even then pain may not be present, but rather a sense of weakness and disability in making certain motions. Suppuration may occur and, as has been stated above, may involve the joint or may give rise to a deep or superficial phlegmon. Chronic inflammation of a bursa may be treated by aspiration alone or aspiration and injection of iodine, if the walls are not too much thickened. If, however, such is the case or it contains fibrous masses, as is usually the case in chronic prepatellar bursitis, incision and packing, or preferably excision of the bursa, is the proper treatment. Suppurative bursitis should be treated by prompt free incision and drainage. Inflamed adventitious bursæ and bunions are particularly difficult to manage, as it is difficult to relieve them from pressure. Prevention is better than cure and too much attention cannot be given early to the prevention of improper pressure by badly fitting apparatus or shoes. When suppuration has occurred in a bunion, it is necessary to incise and drain it, and usually it is necessary to remove the greater portion of the outer wall of the bursa before it will heal. The remaining cicatrix is tender to pressure, but with properly made shoes this can be avoided. When marked hallux valgus is present and the head of the metatarsal bone is enlarged, this must be removed.

TENDONS AND TENDON SHEATHS

Affections of the tendons and tendon sheaths are not so frequent in the lower extremity as in the upper. Most of them are of traumatic origin and are considered in the preceding chapter. Tuberculous and suppurative tenosynovitis is not uncommon, however, and syphilitic and gonorrhœal disease occurs more frequently than in the upper extremity.

Dry and Serous Tenosynovitis.—The dry type follows trauma. It is most frequent in the sheaths of the tendons of the peronei behind the lateral malleolus, the sheaths of the tendons of the tibialis posticus, flexor longus digitorum and flexor longus pollicis, behind the medial malleolus, and the sheaths of the tendons of the tibialis anticus and extensor longus digitorum on the front of the ankle. The pain and crepitation make the diagnosis simple. Fixation so as to secure perfect rest effects a cure. With persistent use of the extremity or repeated traumatisms, there may be an effusion into the sheath, in which case the diagnosis is made by the enlargement along the line of the tendon. The treatment is the same as in the dry variety.

Suppurative Tenosynovitis.—This usually has its origin in a perforating wound through which the infection enters directly into the sheath, or into the surrounding tissue from which it spreads into the sheath. In rare cases—in pyæmia, typhoid fever and scarlet fever—the infection is carried by the blood, and is more likely to lodge in the sheaths about the ankle. The symptoms, cause and treatment are the same as in the hand: redness, swelling, constitutional disturbance with spread of infection, if unchecked, throughout the sole of the foot and upward.

Treatment is incision to expose fully the seat of infection. When the infection is in the sheaths about the ankle, early incision is urgently indicated.

Tuberculous Tenosynovitis.—Its seat is in the sheaths about the ankle. As elsewhere, it occurs primarily in two types: first, hydrops, usually with, occasionally without, rice bodies; second, the fungus form with little fluid and great development of granulation tissue. A tendon sheath may become diseased from the spread of the tuberculous process from an adjoining bone. The course is slow. The peronei are most commonly affected, next the extensors at the ankle. The swelling is first noticed above and below the annular ligament because of its pressure on the tendon sheaths. On pressure upon the distended sheaths,

rice bodies may be made to slip back and forth above and below the ligament. The treatment is thorough excision of the diseased sheath, every bit of which should be removed. The divided ligament is to be stitched accurately.

Gonorrhœal Tenosynovitis.—Gonorrhœa occasionally causes inflammation in the sheaths of the extensor tendons independently of disease in the ankle-joint. The presence of gonorrhœa, and its acute development, leads to its recognition. The treatment is the same as that of the gonorrhœal joint.

Syphilis of Tendons and Sheaths.—As a tenosynovitis, this is rare. It usually involves the sheaths of the tendons in front of the ankle (Fig. 388.) and simulates tuberculous tenosynovitis. Gumma in the

Fig. 388.—Syphilitic tenosynovitis (diagnosis verified by subsequent operation).

tendon is less rare. It has been found in the tendon of the quadriceps extensor and the tendo Achillis. Both these conditions are diagnosed through the history and other evidences of that disease.

VESSELS

Arteritis.—Acute inflammation of the arteries in the lower extremity is usually part of a general bacterial invasion. The local manifestations are, therefore, frequently lost in the gravity of the constitutional disturbance, until complete obstruction of the vessel occurs through clot formation and gangrene results. The symptoms and treatment are those of thrombosis and embolism. Arteritis due to local causes, bathing of the vessel wall with pus, is rare. In pre-antiseptic days,

when infection was the rule and usually severe, there was frequent occurrence of secondary hemorrhage from giving way of the infected vessel wall or from liquefaction of the thrombus following ligation.

Arterio-venous Aneurism.—In the lower extremity this disease practically always has as its cause a gunshot or stab wound of the vessels. The most frequent site is in the femoral artery and the next most frequent is in the popliteal. The free hemorrhage following the injury soon ceases and the wound heals. The symptoms may come on shortly after the wound has healed or months may pass before they appear. Then the veins of the extremity become dilated and pulsation becomes visible in them; the leg or thigh becomes swollen and a painful tumor develops at the site of injury.

The diagnosis is to be made from true aneurism. There is, in addition to the characteristic thrill, a constant bruit, with its maximum during systole, transmitted both upward and downward, and there is also distinct pulsation in the veins. The disease is serious. It leads to great functional disturbance, to muscular atrophy, to huge œdema with intractable ulcers, and sometimes to local gangrene.

Until recent years the treatment of this condition has been extremely unsatisfactory. Ligation of the artery proximal to the sac or on both sides of it has usually failed to cure, or has been followed by gangrene. In the proximal and distal ligation of both artery and vein, with or without extirpation of the sac, the frequency of gangrene has been high, much more so than after ligation for true aneurism, because of deficient oxygenation due to the admixture of arterial and venous blood. The most satisfactory treatment, at the present time, is as follows: with hemostasis secured, either by a rubber constrictor or by the application of Crile clamps upon the exposed artery and vein, the sac is exposed and the clots turned out. The openings in the artery and vein are found and are closed with fine silk sutures and needles, as indicated in the technique of vessel suture. There may be small perforations to be closed by a suture or two, or a long slit, or a complete division of the vessel to be closed by a continuous suture, or an opening with margins so torn as to require resection of the vessel. A small segment excised (2 cm.) will still permit of successful end-to-end suture of the vessel, but if more than this is resected it will be necessary to insert in the defect a segment of vein. The same should be done also in a case in which lateral suture would dangerously narrow the lumen of the vessel. If a segment of vein is implanted, its axis should be turned so that any enclosed valve will not obstruct the passage of blood.

Arteriosclerosis.—In the lower extremity this disease may be of interest to the surgeon in two ways: first, in the calcareous form in which, because of the resultant brittleness of the arterial walls, serious difficulty may be encountered when ligatures are applied, as in amputation for any cause. Under the above circumstances the use of flat ligatures, or of two ligatures side by side is appropriate. Second, and much more important, through the narrowing of the caliber of the arteries and the resulting reduction of the blood supply, it produces serious disturbance in the nutrition of the extremity. This manifests itself in such sensations as coldness, numbness, pain, cramps, intermittent limping, and also in sudden cyanosis or anæmia. In the early stages of the disease these symptoms are likely to be misinterpreted as rheumatism, flat-foot, neuralgia, etc. Intermittent lameness accompanied with sudden anæmia is a grave symptom, as it indicates impending gangrene. The treatment in the earlier stages is the prophylactic, dietetic and medicinal treatment of the underlying condition, and of the general arterio-sclerotic process of which the disease of the lower extremity is a local expression.

The affected extremity is to be protected from injury and exposure, for even an apparently trivial infection may be the beginning of gangrene. When there is marked anæmia or cyanosis, with absent pulsation in the dorsalis pedis or posterior tibial at the ankle, the condition is grave. Rest in bed with the leg elevated and kept warm may secure, for a time, a readjustment of the circulation. The active hyperæmia induced by the hot-air bath is of value, but must be used most cautiously because of the great danger of burning. In spite of the best efforts along the lines indicated, the disease will progress or, after an apparent improvement, recur, to progress to the point of gangrene. It is because of this grave prognosis in advanced arteriosclerosis that some surgeons have urged that reversal of the circulation in the affected extremity be accomplished by using the deep veins to carry the arterial blood. The operation, however, has been a complete failure in all but a few of the 60 reported cases. In these few only a temporary cessation of pain has been obtained, with the exception of one by Wieting and one by Glasstein. These two cases were reported as practically well some months after the operation. Even if it were possible to secure a true reversal of circulation, the venous sclerosis and thrombophlebitis that are so frequently present would nullify any partial arterial flow that could occur. A complete reversal of circulation is made as follows: a long incision is made over the femoral vessels below the origin of the

profunda because a large exposure is needed to permit the turning of the vessels required for suturing. Crile clamps are applied well above and below the proposed site. With the technique for vessel suture described under aneurism, the proximal end of the divided femoral artery is sutured to the distal end of the divided femoral vein, and the proximal end of the vein to the distal end of the artery. A lateral anastomosis is much more easily made. With the vessels cleaned and clamped as before, an incision is made of equal length on the adjoining sides of the vessels in their long axes. A stay suture holds each extremity. The continued suture unites the deeper margins first. Wieting made a partial reversal of circulation in his first and most satisfactory case, as follows: after exposure of the vessels, and application of clamps as above, the femoral vein was tied, and below the ligature the upper end of the divided femoral artery was sewed into an opening in the vein. The distal extremity of the femoral artery and all tributaries of the vein close to the site of operation were ligated.

The treatment of the gangrenous extremity will be taken up under the head of gangrene.

Arterio Thrombosis.—This is not an uncommon occurrence in the lower extremities. Because of the grave diseases with which it is associated, sepsis, typhoid, influenza, etc., the process usually cannot be noticed until gangrene appears. In a superficial vessel, as the common femoral, it may be possible to feel the hard, tender, non-pulsating cord. Except in thrombosis following upon an embolus, the development is gradual. In thrombosis of the external iliac, not extending below the origin of the profunda femoris, sufficient collateral circulation may develop to prevent gangrene. Such development cannot occur in complete involvement of the popliteal. The gangrene that occurs is to be met as indicated in the separate article on that subject.

Embolism.—Embolism of the arteries of the lower extremity is rare. Occurring in one who presents the possible cause, an endocarditis or an aneurism on a vessel between the heart and this extremity, a severe pain in the foot or leg comes on suddenly and soon becomes agonizing. In his suffering the patient may beg to have his shoes, even his stockings taken off for relief from the terrific sense of pressure. When the foot is inspected it is pale. There is no pulsation in the posterior tibial or the dorsalis pedis. In some hours the mottling of gangrene appears. In such a case, it is the popliteal or femoral that is the seat of embolus. If the clot can be localized and cut down upon immediately and removed and the vessel wall again sutured, the limb might be saved, but

this distant prospect of success can be realized only if the clot does not have a septic origin. In most cases the only hope of the patient lies in an early and high amputation. Sepsis appears early and progresses with great rapidity.

Key reports the successful removal of an embolus in the femoral artery in a case of mitral stenosis (Wien. Klin. Woch., XXVI, 936).

Gangrene.—Excluding embolic gangrene the symptoms and course are the same in all non-traumatic cases of gangrene, whether senile, presenile, syphilitic, or diabetic, except that in the last-named the progress is likely to be more rapid, and the secondary infections much more frequent because of the excellent culture medium for the organisms furnished by the sugar-containing serum. After the prodromata described under arterio-sclerosis, a livid spot appears on one toe, usually the small one, where it has been subjected to pressure, or to some injury, as from paring of a corn too deeply. Gradually the whole toe becomes livid, and later black. The gangrene may remain limited until this affected toe has practically separated, before the adjoining toes become involved, and the process extends to the dorsum and sole of the foot. The pain is extremely severe, even large doses of morphine may fail to relieve it satisfactorily; it is felt at a higher level than the gangrenous area. With slow progress the dead portion undergoes mummification and there is little discharge or odor. When the spread is rapid, as in the diabetic type, and secondary infections occur, the discharge is profuse with foul odor. Lymphangitis appears, the constitutional disturbance is great, and death occurs early.

In the treatment of this condition, it is of great importance to wait for the line of demarcation to form when the process is confined to a single toe, or is spreading very slowly on to the foot. Mummification is to be encouraged by dry dressings as this decreases greatly the danger of secondary infection. Moist dressings favor decomposition, and the entrance of microörganisms into the interior, while antiseptics turn the scale against life in tissues already devitalized by deprivation of much of their blood supply. During this period of waiting the constitutional condition ought to be treated. The best field for such treatment is in diabetes, where the acidosis may be corrected and the sugar reduced. In cases in which sepsis is marked or in which the gangrene is spreading rapidly, amputation should be done promptly. Surgeons are divided as to the height at which amputation should be done for gangrene in the foot, whether above or below the knee. The cause for the difference is found in the fact that the main vessels are obstructed

far above the level of the gangrene. The difficulty in feeling the weakened pulse in the hardened and partly closed arteries, has lead to the development of methods for recognizing the height of satisfactory blood supply. That of Moskowicz has been warmly praised. The extremity is elevated long enough to drain it. A rubber constrictor is applied high up on the thigh for five minutes and is then released. A wave of hyperemia follows the release, and its spread down the extremity is watched. It is safe to operate in the pink area. Another method is to expose both extremities to the temperature of the room for half an hour and by comparing the temperature of the sound with the diseased side, determine the height at which the diseased side retains its heat, above which the line of operation must go. This is not so satisfactory as Moskowicz's test. The amputation is to be done quickly. Gas-oxygen anæsthesia, with blocking of the nerve trunks with novocaine adrenalin solution, is the safest anæsthetic. Hemorrhage is best controlled by digital pressure on the femoral at the hip. Any clots found in the arteries in the flap should be removed with forceps. The flaps should not be too long, should be composed of muscle as well as skin, and there should be no tension when they are sewed. Drainage should be provided.

Aneurism.—The lower extremity is the favorite extrathoracic seat of aneurism. In the frequency with which the individual arteries are involved, there is a wide difference. The popliteal is by far the most frequent, representing one-third of the peripheral aneurismata, whereas those occurring on the femoral, the larger vessel, are only one-fourth as frequent as those on popliteal. There is no satisfactory explanation for this difference. Those on the profunda femoris, on the gluteal, on the sciatic, on the arteries of the leg are rare; those on the arteries of the foot are extremely rare. Multiple aneurisms are most common on the superficial femoral. A simultaneous or subsequent involvement of both lower extremities occurs not infrequently in the popliteal. In the frequency with which the ætiological factors operate, there are wide differences in the individual arteries. Most popliteal aneurisms are due to pathological changes in the arterial wall, and few only to trauma. In those of the common and superficial femoral, the dominant factor is trauma, but disease of the vessel wall is important. In the smaller vessels of the buttock, of the leg and of the foot, trauma is the great cause. The first symptom usually to attract the patient's attention is some form of sensory disturbance. This may be a sensation of tension, or it may be described as rheumatic. With the increasing size

and the increasing pressure the pain may become that of an intense neuralgia. From pressure upon the vein œdema appears, an early symptom in the popliteal variety, to be sought for not by digital pressure, but by measuring the two legs. In the femoral it may be the pulsating tumor which first attracts the patient's attention. As the tumor grows there is interference with the motions of the hip in aneurism in the groin, and with the motions of the leg in those in the popliteal space. Disturbances due to involvement of the motor nerves of the leg are common in the popliteal variety. The usual course is that of a rather rapid progress to one of the two terminations to be described. In some cases, for reasons not known, there is an interruption in this steady growth, but any hope as to a spontaneous cure is ill founded, as that is extraordinarily rare. Gangrene may occur at any time from the detachment of a bit of clot and its lodgment in the peripheral vessel, or from the closure of the distal portion (the exit) of the sac with clot. The other termination is rupture of the sac. With the increasing growth, the surrounding nerves, veins and fascia become adherent. The skin becomes discolored and finally sloughs. The hemorrhage may cause immediate death, or may cease with the decreasing blood pressure and the formation of clots, to return later with fatal result. Rupture into the subcutaneous tissue leads to gangrene of the limb. Rupture into the hip or knee occurs but rarely. The swelling of the knee, found with a popliteal aneurism, is usually due to an accompanying synovitis. Most aneurisms are easily recognized. A tumor in the line of an artery with an expansile pulsation and bruit can only be an aneurism. The characteristic expansile pulsation is to be found early in its course, but with the increasing size and the deposition of abundant clots, it may disappear. Then the diagnosis may become not only extremely difficult but impossible. The most frequent and the most dangerous error has been to regard the inflamed sac as an abscess and to open it. The situation of the apparent abscess with reference to the artery, and the comparison of the pulsation in the two posterior tibials with the finger or sphymograph would prevent such an error. Osteosarcoma may cause doubt through its pulsation and bruit. An accurate history will discriminate, for in the sarcoma the pulsation and the bruit appear when the growth has reached large size, whereas the larger the aneurism the greater the likelihood of the disappearance of pulsation and bruit. A radiogram may also aid. The history may give information as to which portion of the artery first became the seat of the disease. Comparison of the pulsation in the

two posterior tibials will differentiate between one of the profunda and one of the superficial femoral.

Gluteal and sciatic aneurisms have the same symptoms and diagnostic marks as the femoral and popliteal. The recorded cases show that in some cases it has been impossible to distinguish the gluteal from the femoral, the posterior tibial from the peroneal. The treatment of peripheral aneurisms by digital or mechanical pressure upon the artery, by pressure through flexion, by material introduced into the sac, by galvanopuncture, are all to be regarded as untrustworthy and dangerous. The pressure has lead to rupture of the sac, and in the other methods the clot produced has been carried into the peripheral vessel with gangrene of the extremity with a frequency in each method too great to encourage its future use. Probably more aneurisms of the lower extremity have been treated by the method of ligation than by all other methods combined. This has been employed in two forms. In one the ligature has been placed close to the sac on the cardiac side (Anel's method). In the other it has been placed some distance nearer the heart (Hunter's method). For over a century the latter has been the favorite in the United States and Great Britain. In aneurism of the common femoral, or of the upper part of the superficial femoral, the external iliac ought to be the vessel tied. Ligation of the common femoral itself has been very disastrous because of a too free collateral circulation. In popliteal aneurism the superficial femoral is tied in Hunter's canal or immediately higher. The weakness of this method lies in the occurrence of gangrene in a certain proportion of cases, and in the failure to cure, since pulsation may return to the tumor almost immediately, or some months or years later.

The researches of Wolff, Krüger and von Frisch in the three German clinics to which they are attached, have shown that the danger of gangrene has been much underestimated. The treatment of the aneurism by excision removes any danger of recurrence. An incision is made over the aneurism so as to expose the main artery above and below where arterial compressors or ligatures are applied close to the sac. In the popliteal variety, hemostasis may be secured by an elastic constrictor on the thigh. The sac should then be opened and the clots removed, or an attempt may be made to dissect it out entire. In either case a number of collateral vessels will be found entering the sac. These are to be tied. In the dissection of the sac, a difficult piece of work, special care should be taken to avoid injury to the nerves and the vein. This may be most difficult, indeed impossible, because of the

fusion of the wall of the aneurism with surrounding structures. The nerves are more important, as an opening in the vein may be repaired by suture. Every bleeding point should be closed and an endeavor made to avoid drainage. Even should the patient escape the danger of gangrene following both ligature and excision, there may still be grave disturbances in the nutrition of the extremity, due to the failure in development of a free collateral circulation. The leg may be weak, cyanotic and painful. According to Krüger and von Frisch there was such disturbance in about two-thirds of the cured cases.

To avoid the danger of gangrene after ligation and excision, attempts have been made to increase the collateral circulation by causing a gradual closure of the main artery. Metal bands have been used for this purpose by Halstead, and rubber ligatures by Doberauer, who took from two to four days before twisting the ligature so tightly as to interrupt completely the circulation. Such methods will find their best application on other vessels than those of the lower extremity. The first operation to reconstruct the vessel channel successfully was the endoaneurismorrhaphy of Matas. Where the form of aneurism permits, as in the fusiform type with elastic walls, he makes a new channel out of the sac walls and obliterates the remainder of the sac (see Lexer and Bevan).

The latest development in the treatment of aneurism is the transplantation of a segment of vessel (the saphenous vein of the opposite thigh of the same individual) into the defect remaining after excision of the sac. This is done according to the Carrel technique for vessel suture. The transplanted segment of vein takes on the characteristics of an artery. Several cases have been reported in which this procedure has been successfully performed. That of Goecke was immediately successful, but defective wound healing led, rather suddenly, to the patient's death about four months after the operation. Omi of Japan has reported a case which was immediately and has continued to be a brilliant success. Tuffier has also reported a case of excision of a popliteal aneurism with implantation of a segment of internal saphenous vein with a gap of 10 cm. in which the result was successful, but no pulse was felt in the dorsalis pedis, while Lexer excised an external iliac aneurism and implanted a segment of the long saphenous vein in a gap of 15 cm. with a result perfect in all respects. Pringle (London, Lancet, 1913), reports the excision of a popliteal aneurism with the implantation of 4 in. of long saphenous vein into the gap, successful six months later. Unger reports first, excision of a popliteal aneurism with implanting

of 15 cm. of long saphenous vein, successful five months afterward; second, excision of a popliteal aneurism with failure to implant because caliber of vein was too narrow to permit its union to artery; third, in an arterio-venous aneurism caused by a pistol ball he made a lateral suture in the vein and sewed 10 cm. of saphenous vein into the gap in the artery, successful (Berlin Klin. Woch., 1913, 2172). Coenen reports he sutured successfully a segment of vein in a high arterio-venous femoral aneurism incurred in the Balkan war.

To summarize the treatment of aneurism. Proximal ligation has been, in the past, the favorite form of surgical treatment, and is the safer in the hands of those of moderate surgical skill. For the more skilled surgeon, aneurysmorrhaphy or excision are to be preferred. Excision with transplantation of a segment of vessel is only to be attempted by those who have developed a satisfactory technique by much work on the lower animals.

The technique of vessel suture is as follows: Kirby No. 16 needles, threaded with fine silk and boiled in vaseline, are used. The margins to be sutured are to be cleaned most carefully and accurately of any loose fascia, for this is a most important element in the success of the work. A needle is introduced from without inward, as close to the cut margin of the vessel as possible, and still have it hold. It goes through all the coats. The needle is then introduced into the other vessel from within out, also as close to the margin as possible. The two ends of the suture are held together with fine clamps to avoid being tangled with the other suture to be inserted. Then a second needle and suture is similarly inserted one-third the circumference to one side of number one, and a third suture inserted at one-third of the circumference to the other side of number one. Thus the three sutures are at equal distances from each other, and the ends of each are held together with clamps. The margins of the vessels to be sutured are then touched with sterilized vaseline, and each suture tied separately. The margins of the vessels to be united are thus in accurate approximation. Another suture, somewhat longer than the stay suture, is taken. An assistant holds the clamps with sutures 3 and 1 in their bite, making enough tension to cause the line to be sewed to be prominent. The operator then sews with a continuous suture from 3 to 1. When this is complete, the assistant drops 3 and takes up 2, making tension as before when the operator sews from 1 to 2. The assistant then drops 1 and takes up 3, which he passes behind the vessels. Two and 3 are then put under slight tension, and the final third of the circumference

sewed. All sutures are cut short, and the muscle and fascia sutured over the vessels so as to protect them. Of first importance in securing a previous vessel is the removal of all fascia about the line of suture; second, the placing of the stay sutures in corresponding points on the two margins to be sewed; third, including in the suture as small a bite of the vessel wall as possible. There need be no fear of hemorrhage. If there is some flow of blood through the line of incision, it may be checked by puttting on the clamps again for some seconds, when the insignificant clot which forms in the suture line will check it. If that fails another suture may be put in at the point of leak.

With this technique a segment of the saphenous vein of the other thigh is sutured between the arterial sections left by excision of the aneurism.

Phlebitis: Periphlebitis (*milk leg*).—Inflammation of the veins is not at all uncommon in the lower extremity. The infection causing it may secure entrance through one of the tributaries of the internal or external saphenous, or may be part of a general sepsis. In the latter case the local conditions are not likely to attract attention until the gravity of the constitutional involvement has decreased. Phlebitis is most frequently and best seen as the result of the infection of an ulcer of the leg accompanied by varicose veins. A patient with such an ulcer complains of pain on the inner side of the thigh with a moderate amount of malaise. Inspection shows a line of redness along the course of the internal saphenous. The vein is felt as a hard, tender cord. With a pyogenic infection there is increasing involvement of the surrounding tissue, periphlebitis with pus formation in or outside the vein. The more frequent termination is thrombosis.

The diagnosis is easily made when a superficial vein is inflamed. The only source of error, a line of lymphangitis, following the course of the vein, can be differentiated by its location, being entirely in the skin. In the deep veins, as the femoral, the one most frequently involved, the diagnosis may be impossible until the evidence of thrombosis appears.

The treatment is directed to the control of the source of the infection, and to securing resolution with the prevention of embolism, the great source of danger in the disease. The affected extremity, wrapped in cotton, is placed on a well-padded, posterior splint and elevated. Local applications are without much value, though ichthyol, iodine and mercurial ointment are commonly used. They have the

objection that they disguise the color of the overlying skin and one is not able to accurately note the progress of the infection and make incisions as early as they should if suppuration occurs. The patient should be kept in bed until organization of the thrombus is effected—about three weeks. Too early motion and massage involves the danger of embolism and should be avoided.

Venous Thrombosis.—This condition is a most frequent result of a phlebitis or a trauma to a vein. When it is confined to one of the superficial veins, and organization has occurred it is of no import. When, however, the femoral vein is the seat of this process, the condition is a serious one, as it may lead to permanent crippling of the affected extremity.

The usual clinical history is as follows: In the midst of a typhoid fever, puerperal sepsis, or in the second week after a laparotomy in the lower abdomen, the patient complains of pain in the thigh, more frequently the left, which in some cases is extremely severe. When the thigh is examined, a hard, tender cord may be felt in the line of the femoral vein. By the time that the disease is noted, the swelling following the thrombosis will usually have developed to such an extent that only the tenderness along the line of the vein can be appreciated on palpation. The color of the swollen limb is usually white, hence the name *phlegmasia alba dolens* or *milk leg.* Under the treatment given under phlebitis, the pain usually subsides and the swelling decreases, but there is always left a permanent increase in the circumference of the leg and thigh, accompanied by a sense of weight, easy exhaustion and cramps. In rare cases gangrene may develop. If gangrene appears, is it to be treated as indicated under that head. Obliteration of the common femoral is apt to be followed by dilatation of the saphenous and its branches, and the anastamosing branches of the superficial epigastric, circumflex iliac and superficial external pudic veins.

Varicose Veins.—The importance of this subject is shown in the enormous amount of crippling and loss of efficiency to society that it, together with its complications, occasions. The disease usually appears, first in the internal saphenous, though the external may occasionally be the first involved, but eventually the disease involves both veins up to their termination. In the well-to-do who can avoid making demands upon their diseased veins, the development will be slow, while in firemen working in a hot atmosphere the progress is rapid and the disability early. The first symptom to be noticed is a

sense of weight in the affected extremity, which is easily exhausted through use. The ankle and leg swell on vigorous use. Muscular cramps appear when the deep veins are affected. Neuralgic pains occur and are due to the involvement of the veins in the saphenous or the sciatic nerve. Under the increased pressure from the insufficiency of the valves in the veins, the skin over the varices becomes so thin that the underlying vein shines through as a blue tumor, so characteristic of the disease. A slight injury to one of these may lead to necrosis of the thin skin, ulceration into the vein and hemorrhage. The amount of blood lost may be serious if the patient is asleep or drunk. In the leg in which a marked œdema is present, another complication is sure to appear in the patient who is dirty, the varicose ulcer which is discussed under a separate head. Phlebitis has been named already as a complication.

The diagnosis is easy. The only error that the writer knows has been to confuse a varix at the saphenous opening with a femoral hernia.

Whenever the condition of the patient will permit and there is no history of a previous phlebitis of the femoral vein, operative measures should be adopted. The most satisfactory is the complete excision of the internal saphenous vein, and the external also if that is involved. As this is a long and tedious piece of work, instruments have been devised to shorten it. Probably the best of these is the enucleator of C. H. Mayo. It is a steel ring, ¼ in. in diameter, attached to a long handle. The vein is exposed and divided between ligatures at the saphenous opening. The ring of the instrument is passed over the end of the vein and forced carefully down along the course of the vein while tension is maintained on the end. When a sufficient length has been secured or an obstruction reached, a new incision is made over the ring, the stripped segment removed and a fresh start made. In those cases where the instrument would be of most value, it is apt to fail, that is in those cases in which the varices are composed of extensive convolutions with thin walls. In the excision of the internal saphenous, care should be taken of the saphenous nerve. It is well to break the line of incision at the line of flexion of the knee. Œdema of the foot and ankle persists for several months after this extensive excision and the limb should be bandaged with a flannel bandage for this length of time.

Ligation of the internal saphenous in the upper third of the thigh was advocated by Trendelenburg in the cases in which there is insufficiency of the valves. His test is as follows. The patient is put

in the recumbent position with the affected extremity elevated until all the varices are drained. The surgeon then makes pressure over the saphenous opening and directs his patient to stand. The veins will fill very slowly from below, but if the pressure is quickly removed and the valves are incompetent the varices are at once widely distended. In the operation advocated by Schede a circular incision is made in the upper part of the leg, extending to the deep fascia. This incision divided all the veins which are tied above and below. Numerous small separate incisions, with division of the vein between two ligatures have also been advocated. All three methods are unsatisfactory in that they do not touch the free communications which exist between the varices and the muscular veins, and thus fail to secure the obliteration of the varices. The same objection applies to certain newer methods; the insertion of the saphenous vein under the sartorial muscle; the union of the central end of the deep femoral vein with the peripheral end of the internal saphenous. A number of cases have been reported in which the internal saphenous vein has been transplanted into the femoral vein below the first valve in the latter. In such an operation the Trendelenburg sign must be present. It requires perfection in vessel suturing and is too recent an operation to pass judgment upon its permanent curvative power.

When the varices appear in the pregnant woman or in the subject of serious organic disease, palliative treatment is to be considered. The patient reduces the burden upon the diseased veins by frequent rest in the recumbent position with the lower extremities elevated. In the upright position the veins should be supported with an accurately fitted elastic stocking or a carefully applied bandage.

The complication of hemorrhage is met by pressure upon the bleeding point with elevation of the limb.

LYMPHATICS

Anatomical Considerations.—There are two series of superficial lymph vessels in the lower extremity, one accompanying the short saphenous vein, the other the long saphenous. The first-named receive the lymphatics from the heel, the posterior portion of the outer border of the foot and from the posterior portion of the leg. They terminate in the popliteal lymph nodes. The second group of lymph vessels receive tributaries from the network on the plantar surface of the foot and from that on the inner border of the foot, the greater part

of the dorsum, and the anterior portion of the outer border of the foot. In their course upward they receive further tributaries from the front of the leg and all the surface of the thigh. They terminate in the superficial nodes of the saphenous group. It is along the two groups of lymph vessels that infection extends up the lower extremity. The infrequency of infection of the popliteal lymph nodes is due to the small area which drains into them and also to the fact that this area is less liable to injury.

The inguinal glands receive the flow from the superficial lymphatics of the genitals, perineum, anus, abdominal wall and buttocks, and so become enlarged in infections and carcinomata in these regions. The saphenous group receive, in addition to the supply indicated above, some lymph from the perineum, anus and buttocks.

Acute Lymphangitis.—In the lower extremity this disease has its most common origin in an infection in the foot, introduced through an abrasion, an interdigital fissure, or a wound of the sole of the foot or leg. In the leg it is often associated with the phlebitis accompanying a varicose ulcer.

It may be confined to a main lymph trunk and thus simulate a phlebitis, or it may be diffuse and resemble erythema or erysipelas.

The symptoms are those of lymphangitis elsewhere, a marked redness of the skin surrounding the point of infection which rapidly extends in the direction of the main group of lymphatic vessels. This redness may be diffuse or mottled or net-like, but in a few hours, one or several streaks develop from the area which rapidly extends toward the main lymphatic trunk, coalescing as they progress and terminate either at the saphenous opening or the popliteal space. The onset is accompanied by fever and not infrequently a chill; the temperature may be as high as 103° or 104° and be accompanied by marked general symptoms, but usually it is moderate. There is pain and tenderness along the inflamed vessels and often the leg and thigh are diffusely swollen and painful. If the infection has involved the deep lymphatics alone, the pain is more dull in character but more distressing than when the superficial alone are involved. The enlargement and tenderness of the lymph nodes in this case afford the explanation of the symptoms; often both deep and superficial groups of glands are simultaneously involved. As a rule the lymphangitis rapidly subsides, the redness often persisting for some days however, gradually becoming a dusky red and then disappearing; sometimes the involved trunks may be felt as hard cords for a long time, but this is unusual. In some cases abscesses may form

along the lymph vessels and from these phlegmons may originate, but such severity is rare.

Treatment consists in absolute rest in bed. The limb should be moderately elevated and gently handled. The primary source of infection should be properly treated and the supply of microörganisms cut off as quickly and thoroughly as possible by the use of the knife, cautery or antiseptics. Heat is generally agreeable and moist warm compresses of bichlorid may be used or the streaks of lymphangitis covered with strips of lint spread with mercurial ointment. Ichthyol ointment 50 per cent. may be of some benefit, but the essential things are rest and disinfection of the atrium.

Lymphadenitis.—Disease of the inguinal lymph nodes, especially in the male, is very common. As the course and treatment depend so much upon the cause, the several types of inguinal adenitis ought to be accurately distinguished.

Syphilitic Lymphadenitis.—Every primary infection on the genitalia or the lower abdomen has as its invariable accompaniment enlargement of the inguinal nodes, on at least one side. Less commonly the glands on both sides are enlarged. The individual nodes are of the size of a small marble, hard, painless and freely movable. The innermost of the group may be larger than the others. The glands continue in this indolent condition for weeks, subsiding slowly under treatment. They never suppurate except as the result of a mixed infection with pyogenic organisms. Syphilis may also cause disease of an inguinal or femoral lymph node through the formation of gumma in it. It is rare and it follows the course of gumma in other parts, a slowly increasing, somewhat painful tumor, which becomes adherent to the overlying skin, softens and discharges, leaving a circular ulcer with characteristic floor and edges.

Tuberculous Lymphadenitis.—Tuberculous lymphadenitis of the inguinal or saphenous nodes is not common except when associated with other tuberculous lesions of the skin, bones or joints of the lower extremity. It may occur in those presenting tuberculous disease in other parts of the body, however, and in rare cases may occur without visible evidence of the source of the infection. In such cases the diagnosis may not be possible in the earlier stages, particularly if the disease is confined to a single node. The disease follows the course of tuberculosis of lymph nodes elsewhere, usually involving the whole group of nodes and going on to caseation and softening and the formation of a cold abscess.

Treatment is that of tuberculous lymphadenitis elsewhere, viz., enucleation, if periadenitis has not taken place to such an extent as to prevent it; if so, incision and curetment or evacuation of the abscess through a small incision and injection of iodoform suspended in glycerin are proper.

Suppurative Lymphadenitis.—Suppuration in the lymph nodes is produced by the introduction of pyogenic organisms or of chancroidal virus.

In the first named, the course varies much with the virulence of the culture of microörganism. In the most severe cases the picture is that of a rapidly developing abscess. Early incision should be made, usually parallel to Poupart's ligament in case the inguinal group is involved, or parallel with the long axis of the limb, if it be the saphenous group. The incision should be made with care and if the abscess is deep seated, under an anæsthetic; the resulting cavity should be packed lightly with gauze until it is filled with healthy granulations. In many cases the infection is not so imminent and if seen early, the affected nodes can be distinguished and excised, thereby saving much time and suffering. None of the methods of aborting abscess formation in these cases can be relied on. When the infection is of a mild type the nodes increase slowly in size and become painful. Gradually periadenitis occurs and when the capsule of the node ruptures, the overlying skin becomes reddened and fluctuation apparent, the process being similar to tuberculosis but more rapid. In this type there is a little hope of securing resolution by rest in bed and application of an ice-bag, but usually such efforts fail, though for a time they may have apparently succeeded. Should suppuration supervene, excision, rather than incision, should be done as usually there are many foci of suppuration and often abscess after abscess will develop with burrowing of pus and formation of sinuses, all of which may be avoided by early excision. The injection of argyrol, carbolic acid, etc., into the nodes to abort the infection has seldom proved successful.

The lymphadenitis accompanying chancroid may be due to pyogenic organisms, as well as the special chancroidal virus. Especially in this case is it important to open early and remove the necrotic tissue and nodes so as to prevent burrowing and the infection of other glands. In case the wound surface becomes chancroidal, that is, phagedenic, the infection can best be overcome by the actual cautery.

Tropical bubo is a chancroidal bubo of chronic type in which the enlarged nodes are honeycombed with suppurating foci instead of breaking down into an abscess.

Suppuration in the popliteal lymph nodes is not common. It has the same clinical picture as any acute abscess and because of the density of the popliteal fascia below which the glands lie, it is very painful. As indicated under aneurism it is to be distinguished from that condition. It may also be mistaken for acute osteomyelitis or epiphysitis. The treatment is prompt incision, preferably by the Hilton-Roseh method.

Elephantiasis.—This disease has its greatest frequency in tropical and subtropical countries, because of the prevalence of the parasite which is the common etiological factor, *filaria Bancrofti.* The cases following removal of the inguinal lymph nodes by operation or their destruction by disease are rare compared with those of parasitic origin.

The parasitic case usually begins with a severe, diffuse lymphangitis in one foot and leg, accompanied by fever. When the attack has subsided the affected extremity is seen to be a little enlarged. In a few weeks or months another attack of lymphangitis appears, leaving another increase in that foot and leg. And so appear repeated attacks of lymphangitis with repeated increase in the size of the limb. The skin and the subcutaneous tissues become hard and dense, and form folds about the joints. With the huge size that the extremity may attain, the patient becomes helpless.

The non-parasitic cases follow the same course, except in this, that the lymphœdema precedes the attacks of lymphangitis.

The diagnosis is easy in all well-developed cases, as it is made by inspection. There is no other condition with which it can be confused.

The treatment recommended years ago by the Dutch East India surgeons, ligation of the femoral artery, is to be condemned. It has no influence whatever on the course. The excision of large wedge-shaped masses across the long axis of the extremity is the operation that has been most frequently practised. It is only a palliative measure, but it converts a helpless individual into one who can move about for several years after the operation, before the further increase cripples him again. There are two points in the operation that are very important. The first is the sterilization of the skin, a condition difficult to secure because of the foul material which accumulates in the deep creases. The second is the control of hemorrhage. Because of the density of the tissue in which they lie, the veins remain patulous and bleed profusely. Even the small ones should be ligated. Lymph-angioplasty, devised by Handley, has been applied to this condition.

The non-operative treatment includes the protection of the extremity from injury, cleanliness, massage, elevation of the limb with accurate bandaging. The non-operative treatment has been developed extensively by Castellani of Columbo, who places his patient in bed with pressure by a flannel bandage and with compresses accurately applied upon the thickest areas. During this period injections of thiosinamin are made, preferably into the buttocks. After some months of such treatment, he states that the swelling is so reduced that the skin hangs in folds, when he has a surgeon excise long strips.

Lymphangioplasty.—This operation was devised by Handley for the lymphœdema in the upper extremity occurring in carcinoma of the breast. He has also used it in elephantiasis of the lower extremity. In the latter condition it will probably be found unsatisfactory, because of the great difficulty of having the silk threads remain buried in tissue which harbors septic organisms. This was seen in Handley's own case. A better field would be the œdema following the thrombophlebitis of typhoid fever and puerperal sepsis.

The operation is done as follows: a small incision is made in the region of the ankle. A probe threaded with silk, which more than equals the limb in length, is introduced into the opening and pushed as high as it will go. The tip of the probe is then cut down upon, the probe drawn out, introduced again, and again pushed up as high as it will go. Another small incision is made upon the tip, and the process of withdrawal, introduction and incision repeated until the silk thread reaches the abdominal wall where it is buried. In the same way a number of other silk threads are buried subcutaneously, extending from the ankle to the abdominal wall or gluteal region.

SECTION XII

DEFORMITIES OF LOWER LIMB

By

Sir ROBERT JONES, Ch.M., F.R.C.S., Hon. F.R.C.S.I. and DAVID McCRAE AITKEN, A.M., M.B., Ch.B., F.R.C.S. (Ed. and Eng.)

In dealing with deformities of the lower limb, the factor which the practical surgeon must keep constantly in view is that the lower limb is intended to carry the weight of the body and that, therefore, whatever the local deformity in any part of the limb may be, the correct alignment of the several joints must be restored or maintained if a good functional result is to be obtained. This is the key to the orthopedic problem, whatever the ætiology of the conditions under treatment may be. It may be congenital, paralytic, traumatic, or it may be due to some obscure infective condition giving rise to softening of the bones, and consequent shearing or bending under the effect of gravity. Further, once the body weight is deflected away from the true line, the altered condition of stresses will necessarily lead to alteration of structure of bone in accordance with Wolff's well-known law, which, to the orthopedic surgeon, is as important as is the law of gravity to the astronomer. Should there be just cause for accusing some toxic agent of being the prime factor, it goes without saying that every resource of modern scientific medicine should be called on to combat the infective process. An illustration of this is to be found in the rachitic infant, for here the primary error cannot be at once eradicated, even under the best conditions, and therefore the tendency to deformity under the stress of gravity must remain for some time. Experience has shown that rachitic deformities can be almost entirely avoided by laying the child out flat with its lower limbs fixed in a straight position like an Indian papoose (Fig. 389). The splint we use is the double Thomas frame with headpiece. Even the formation of Harrison's sulcus on the ribs is averted by this means, for the child cannot sit up with its back bowed and its head sagging forward, and the whole position of the trunk tending to produce this transverse depression across the front of the ribs. With the child in a position in which gravity and muscular forces are least likely to cause deformity,

we can wait till errors of nutrition are corrected and growth and development have made the bones strong enough to perform their ordinary function.

Other familiar instances of the importance of paying due consideration to the carrying power of bones of the lower limb may be found in the troubles which sometimes follow simple fractures. For example, we are frequently consulted by patients who have had Pott's fracture of the fibula two or three months previously. The injury was originally recognized and skilfully treated by a competent surgeon. Firm union has occurred in good position, and for the first few weeks after being allowed to walk the patient complained of no pain, but after this, when he had returned to more active life, he began to complain of pain about the ankle, weakness of the foot and vague pain up the leg, especially on the outer side. As he stands and walks, the foot is seen to be everted—he is commencing to develop a traumatic flat-foot. On the surgeon running his finger up the fibula the patient winces as soon as pressure is made over the seat of fracture, and the picture is complete. What has happened is that under the normal stress of walking and working the recently formed callus has begun to yield and at the same time, reacting to this trifling insult, has become activated, vascularized and tender.

Fig. 389.—Thomas' frame with head piece. Suitable for a case of active rickets to prevent deformity.

This may be relieved and corrected by the simple device of keeping the foot in an inverted position when walking, by making the inner side of the heel higher than the outer. The weight of the body is thus deviated on to the outer side of the foot, and the upward pressure of the astragalus is more on the tibia than normally, thus relieving the external malleolus from the outward thrust of the astragalus, which is the cause of all the trouble.

If the patient is heavy it is well to give him an outside (Fig. 393) brace with a T-strap to keep the foot well inverted.

The fact that this straining of callus with a train of symptoms, which may be very puzzling when their real cause is not understood, may arise after a fracture has united firmly in good position, simply from a disproportion between the stress on the bone and its strength at its weakest point, and is equally simply corrected by a slight deviation of the body weight so as to relieve the bone of undue stress, is one which the orthopedic surgeon must always keep in view, for much of the success of his treatment will depend on it.

Again keeping to the same case, the reappearance of tenderness in the callus is an important symptom. It means that the callus has reacted to some insult, is vascularized and ready to be strained and twisted. In dealing with malunited fractures of the shaft of the femur, for example, it may be taken as a general rule that if the callus is tender and painful it is weak enough to be broken down by manipulation without an open operation, and then the limb can be brought into correct alignment by forcible traction.

Between these two cases of a gross malunion and a perfectly correct union of a fracture, both of which were tender on account of strain, one may place a whole host of conditions arising from minor injuries, obscure inflammations and errors of position about joints, the careful study of which gives many useful guides and pointers in orthopedic treatment, with a regular gradation, up to gross deformities requiring some radical readjustment of parts before they will properly perform their function; and yet in all, a proper adjustment of the lines of stress will be an essential part of the treatment. With this foreword we may pass to a consideration of various conditions of deformity.

Coccygodynia is a term applied to pain in the region of the coccyx, and is really the name of a symptom, not of a disease. The region of the coccyx is supplied by the sacrococcygeal nerves, derived from the fourth and fifth sacral and coccygeal nerves. The uterus, bladder and rectum receive this nerve supply through the sympathetic system partly from the fourth sacral nerve. On the anterior aspect of the coccyx there is the terminal plexus of the sympathetic system. It is quite intelligible, therefore, that in some cases coccygodynia may arise as a reflex pain, when the real fault may have to be sought in an inflammation of some pelvic organ, such as endometritis. Such cases, therefore, belong to the domain of the gynecologist, and like all cases of referred pain, the treatment is difficult, unless the actual

cause can be found and treated. A second cause of coccygodynia is a fracture or dislocation of the coccyx. The displaced part is generally driven inward. The mode of the accident is usually slipping when going downstairs, falling in a sitting position, striking the coccyx on the edge of a step. The patient is nearly always a woman. The male coccyx is tucked in more than the female, and is not so exposed to injury. At the time of the accident the woman generally has both hands full carrying a tray of dishes, or a child, and so cannot save herself from a straight fall by catching at the banisters. A rectal examination should never be omitted. With the patient in the left lateral position, the front of the coccyx can be easily felt, and a forward displacement from either fracture or dislocation cannot be missed. In a very recent case, with the forefinger inside the anus, and the thumb outside, the displacement can be reduced. Generally the patient does not seek advice at first, but the continuance of pain during defecation, or when sitting, and even when walking, drives her to it in the end. A diagnosis may be made, if severe pain is felt on pressure on the coccyx, on the discovery, on rectal examination, of a displacement of the coccyx forward.

Treatment.—1. *Conservative.*—The continuance of pain and tenderness is due to irritation kept up by repeated pressure on the coccyx. To obviate this the patient wears a pad, shaped like a horseshoe magnet. She stitches this to her clothes so that the tip of the sacrum and coccyx is in the hollow of the pad when she sits down. The pad permits the patient to sit down in comfort, and by saving the inflamed region from pressure gives the tissues the rest necessary for the subsidence of inflammation, and so in most cases effects a cure.

2. *Operative.*—In exceptional cases, which have failed to respond to less drastic methods of treatment, removal of the coccyx or at least of the displaced fragment, may be necessary. An incision is made over the coccyx, and the bone or the displaced fragment is dissected out of the surrounding tissues. The deep wound should be carefully closed. The bowels should be kept confined for some days to avoid the risk of infecting the wound. The results are satisfactory in these cases of traumatic origin. The coccyx should not be removed unless all other treatment has failed.

Knock-knee (genu valgum) may originate in many ways when there is some alteration in the firmness of the bones as in rickets, or where actual inflammatory or tuberculous disease attacks the ends of the femur or tibia, or after split fractures of the ends of these bones.

In such cases there is a definite primary cause, which requires treatment. Throughout such treatment, however, the laws governing the treatment of the familiar static knock-knee must be observed, and therefore we proceed to deal with this case first of all.

In a normal, well-built individual standing with the feet parallel and slightly apart, so that a vertical line through the hip-joints falls through the middle of the ankle-joint, this line will fall slightly to the inner side of the middle of the knee. That is to say that, owing to the natural slight bow of the femur and tibia, the center of the knee-joint lies a little external to the vertical line of action and reaction between the body weight and the ground.

This position, with the feet parallel and slightly separated, is the natural stance of the young child before his feet have been weakened by the wearing of badly designed shoes. In the old position of attention with heels together and feet forming a right angle, the forepart of the foot is external to this line, and hence the pressure of the floor on the ball of the foot has an everting effect on the foot and therefore tends to produce flat-foot and knock-knee. This has been recognized by the best schools of Swedish gymnastics in which an angle of 45 deg. has now been adopted as a compromise. The child, the red Indian, and the successful long distance runner walk and run with the line of the foot straight forward using their limbs to the best advantage. Further, anyone who has been fatigued by much standing knows that to relieve his feet and knees he stands on the outer edge of the foot. His astragalus bears more against the angle between the inferior surface of the tibia and the internal malleolus and has less outward thrust on the external malleolus, while the iliotibial band takes more of the strain at the knee. It is, therefore, obvious that this position should be adopted as a rest position whenever knee or foot are suffering from strain produced by body weight.

Age Incidence.—Turning next to a consideration of the ages at which knock-knee commonly makes its appearance, we find that it is particularly liable to occur first at early childhood, about the fourth to sixth year, and again in the rapid period of growth which occurs in girls somewhere between the ages of 10 and 15, and in boys between 14 and 18. In the earlier of these two periods the child has just developed from the toddling infant into an active child. Growth at this age is very rapid. If there are any rachitic tendencies, the new bone laid down is rather defective and solidifies slowly; every case, however, is not rachitic. The essential features are rapid increase in

body weight, with rapid growth of new bone at the epiphyses, *plus* some small *deviation* in the line of transmission of body weight, which may be due in the first instance to very trifling causes, such as a slight twist or sprain of the ankle or a kick about the knee. These injuries, small in themselves, may be quite enough to determine a twist in the lines along which new bone is being deposited when growth is rapid, and the weight to be carried is increasing out of proportion to the strength of the bones.

In most instances the shear in the lines of the bone trabeculæ is most pronounced in the lower end of the shaft of the femur; in rare instances the maximum deformity is in the upper end of the shaft of the tibia just below the epiphyses. It is difficult to find out what accidental condition determines such a variation, but a case recently seen by one of us suggests a possible explanation. A little girl, convalescent from spinal caries and wearing a spinal support, suddenly began to walk very badly, with the left knee in the valgus position. The child also began to complain of pain about the knee. The school gymnastic mistress had noted that the girl was everting her left foot too much.

On examination there was an area about the tibial attachment of the internal lateral ligament which was tender, and the periosteum felt thick and soft to touch. Passive abduction of the knee so as to put strain on the internal lateral ligament caused severe pain. Now if this case had been overlooked or diagnosed as growing pains, and the child allowed to go on walking in the valgus position, the constant strain in the ligament would have kept up the periostitis near the epiphysis of the tibia which necessarily shares in the increased vascularity, and would be all the more prone to rapid change of shape and structure. The only history of injury was a fall a few days before the child began to limp, but this in addition to the slight eversion of the foot was enough to make her adopt a genu valgum position when walking.

In young children it is always right to suspect an early stage of knock-knee when the mother complains that her child is acquiring a habit of walking with the toes turned in. This is the child's natural but unconscious effort to bring the center of support of the foot nearer the middle line, so that the vertical line of body weight from the hip falls more on the outer side of the foot; this of course means that the line of weight passes through the knee at a point nearer the internal condyle than normal and so relieves the internal ligament of some of the strain. In fact the child tries to walk in a bow-legged position.

On examining one of these children it is found that with the knee extended it is possible to abduct the leg slightly, which is quite impossible in a normal knee in which the internal lateral ligament is not stretched.

This condition which we call "slack knee" is often the earliest sign of knock-knee to appear, and also the last to disappear under treatment, and we make it a rule not to regard any recovery as complete and free from all danger of recurrence till this lateral movement is gone and the ligaments have become short and strong.

Where the line of the lower end of the shaft of the femur has been curved (Fig. 390) the line of the joint and the shape of the joint surfaces must be altered in accordance with Wolff's law. It is only by keeping the line of stress to the inner side of the knee for a long time that this will be altered, and it is only when the bony surfaces are truly adapted to the corrected position that the ligaments can undergo final and permanent adaptive shortening. The subject of knock-knee is inextricably mixed up with that of flat-foot, and while this connection is commonly enough seen in young children, it is almost constant in cases occurring in children in the later period during school life, the period which we often refer to as the second-growth period (in girls 10–15, and in boys 14–18) in which the growth for a time is prodigiously fast. Epiphyses are actively laying down new bone, ligaments and muscles are rapidly lengthening, appetite is in proportion to the physiological activity, and the rapidly growing tissues are not capable of withstanding much strain. Hence any oppression, whether it take the form of too much physical or too much mental strain, tells heavily on adolescents, and we find that they tend to be listless, round shouldered and generally slack jointed, and are peculiarly prone to develop scoliosis, knock-knee or flat-foot if any deviation of body weight or muscular strain occurs to determine them. Thus, a slight attack of broncho-pneumonia may cause a child to restrain respiration on one side for a time, and some time afterward it is noticed that she has developed a scoliosis which is primarily dorsal. Another child sprains an ankle, the injured ligaments in the foot stretch, being none too strong to carry the increasing body weight, and a unilateral flat-foot results; next, with the deviation of the line of support caused by the everted foot, knock-knee results.

FIG. 390.—Knock-knee. X-ray of knock-knee showing that the deformity is mainly in the region of active growth immediately above the epiphysis of the femur. This is the most common variety.

If the ankle remains tender for some time, the child may acquire the habit of carrying the body weight mainly on the other leg; this means tilting of the pelvis slightly while avoiding weight carrying on the injured limb, and this gives rise to a scoliosis. in this instance primarily lumbar.

This goes to show that in all deformities, deviations of stress must inevitably produce strains of the structures, ligamentous, muscular, and osseous in accordance with Wolff's law. It is wrong to consider one deformity by itself. A surgeon who is asked to see a case of flat-foot must think of knock-knee, coxa vara and scoliosis, and strip and examine his patient or he has not done justice to his case, and may lay himself open to want of success because he has stupidly overlooked some other defect which is related to the one he is called on to treat.

(*a*) The treatment of knock-knee in the very earliest stage, say in a child who is turning in his toe to save his knee, is to let him go on doing so or to help him to do so by "crooking" the heel of his boot by making the inner side a little higher than the outside.

(*b*) In the rather more advanced case, a knock-knee brace may be worn at night, and the crooked boot by day. The night splint extends from the trochanter to the malleolus and consists of a slightly bowed outside bar, to which the knee is bandaged and a posterior bar to steady the apparatus.

(*c*) In cases a little more severe, day and night braces should be worn. The day knock-knee brace we use is the same as the night brace in principle, but is continued to the heel of a "crooked" boot. It should have *no joints* at either knee or ankle—no joint at the ankle because it is not necessary and only adds to the expense, and if there is a marked degree of flat-foot it diminishes the control on this deformity; no joint at the knee because a knock-knee brace with a joint at the knee is entirely ineffective, for the child will certainly walk with the knees slightly flexed and so avoid the corrective strain which we desire to supply.

These methods are practically effective when the child is growing rapidly and when the deformity is not severe. When the distortion of bone is great, especially in adolescents, these measures would be too tedious, and osteotomy is then a necessary part of the procedure. In most instances a simple osteotomy of the femur just above the epiphysis is all that is required. The limb must then be brought into absolutely true alignment till the fracture is sound. The patient must then walk in a knock-knee brace with crooked heels till he has recovered

from his knock-knee, that is until all slackness of the joint has disappeared. Merely getting the bones into correct line is not sufficient, this corrects only the gross deformity; joint surfaces and ligaments must have time to adapt themselves to the new position before the case may be pronounced finally and definitely cured. The many recurrences and unsuccessful results which are met with are too often due to the fact that the surgeon who treated the case did not have a definite standard of cure to work by and did not persevere long enough in the after-treatment. In many cases no static after-treatment is employed. This we think is a serious omission.

When called upon to treat such cases as split fractures or T-shaped fractures of the condyles of the femur or of the tuberosities of the tibia, the surgeon should bear in mind the principles just laid down. Such injuries are potential causes of traumatic knock-knee. If the limb is fixed in a Thomas knee splint in the way described, the displaced fragments can often be replaced in correct position and retained by bandage or sticking plaster, without having recourse to an open operation and plating.

When dealing with potential causes of deformity about the knee-joint, such as tuberculous or other arthritis, the increased susceptibility of the ends of the bone to distorting stresses should be remembered.

Most surgeons respect a tuberculous arthritis in the convalescent stage, for the penalty for any carelessness is swift and sure. Few surgeons or physicians, however, exercise the same caution in dealing with a joint which is tender and vascularized as a reaction to some obscure toxic condition. The lipping and distortion of these joints occurs only if the patient strains them when the bone ends are too vascular and soft to carry his w ight. It would be well to remember that such cases are of orthopedic as well as of hematological and bacteriological interest.

Operation.—The surgeon may choose any of the methods of osteotomy he prefers, but the simpler the procedure the better. The following is a brief account of the technique usually adopted by us.

1. *Osteotomy of Femur.*—The line of the intermuscular septum behind the quadriceps exterior can always be felt on the outside above the external condyle. On this line 2 to 2½ in. above the condyle a knife is plunged in, right down to the bone and the periosteum is incised; this should be well above the epiphyseal line. Without removing the knife, a periosteum elevator is passed along it and the

periosteum lifted over the front of the bone. Before removing the periosteum elevator, it is used as a guide along which the blade of an Adam's saw with a guarded point is passed. The bone can then be sawn through the greater part of its thickness and the firm bone at the back is easily broken to complete the fracture. One stitch closes the skin wound, there is very little bleeding and this can be controlled with a firm bandage.

There is now a transverse fracture of the femur which requires treatment. Set all fractures of the femur below the trochanter minor in a Thomas' knee splint. The ring of the splint rests on the tuber ischii. The usual sticking plaster extension straps are fixed to the limb from the ankle to the seat of the fracture; stout tapes attached to these are tied to the lower end of the splint as shown in the diagram (Fig. 391). We thus have a firm unyielding extension with counterextension from the ischial tuberosity. This is infinitely superior to elastic tension or tension by weight and pulley, for it is impossible for muscular contraction to occur, and therefore there is no spasm of muscles induced by sudden alterations of tension when the patient moves.

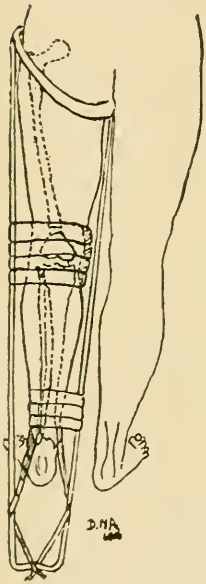

Fig. 391.—Knock-knee. Showing correction of knock-knee in Thomas' splint after osteotomy of femur. The back splint is omitted for the sake of clearness.

With this apparatus there is no difficulty in getting the hip, knee and ankle in line and that is all that is required.

A gutter-shaped sheet-iron or aluminium splint, extending from just below the buttock fold to about 3 or 4 in. above the heel, is placed behind the limb. This is slung by strips of bandage from the side bars of the knee splint and so cradles the limb. This sling should be adjusted so that the axis of the limb is midway between the two side bars. If the knock-knee is a severe one, the knee must be fixed in a corrected position, by bandaging it to the outer bar of the knee splint, as in the diagram, or still better, by using two sheet metal side splints, suitably padded, opposite the seat of osteotomy on the inner side and near the upper end of the thigh and lower end of the leg on the outer side.

There is no need to worry about the lower fragment of the femur being flexed backward by the gastrocnemius muscle, and so pressing on the artery. When a limb is firmly fixed in a splint like this, there

is no muscle reflex to bother us after the first 24 hours. Weight and pulley extension is quite useless for all orthopedic purposes, for every time the patient stirs he alters the state of tension on his muscles and excites a reflex contraction of muscles, which is harmful and quite avoidable. At the end of four or five weeks the patient may get up in a walking caliper splint, with the knee bandaged to the inner bar. The sooner we can allow some physiological action the more rapid will be the physiological adaptation to the new conditions. As the patient really sits on the ring of the calliper, he does not carry any weight at the site of the osteotomy. After about 10 weeks he may safely discard the caliper, and the surgeon must use his judgment whether the patient is to wear a knock-knee brace for a few more weeks or may be left to rely on a crooked heel. The crooked heel should never be omitted from the after-treatment.

2. *Osteotomy of the tibia* is not required so frequently as that of the femur. We generally divide the bone with an osteotome. It is not necessary to remove a wedge of bone, but after the osteotome has been driven four-fifths of the way through the bone, the hard bone at the edge of the incision may be crushed with a strong pair of forceps. When the fracture is completed this crumples up between the two fragments and forms an excellent basis for osseous repair.

The limb is set in side splints, with a good pad on the inner side opposite the deformity and round the inner condyle, and pads above and below on the outer side so as to bow the limb slightly. It is seldom necessary to break the fibula completely; it is usually quite sufficient to strain it a little when completing the fracture by hand after removing the osteotome. In very gross cases of deformity it may require division, but such cases do not fall under everyday routine treatment.

The ambulatory after-treatment is the same as in the former case.

Dislocation of the Patella.—This term may be taken to cover a number of different conditions. First of all there are congenital displacements of the patella in which it may occupy some abnormal position, the most common being an outward displacement. There may, of course, be a traumatic displacement of the bone which does not particularly concern us here. The patella may be displaced outward as an acquired condition. This practically always is associated with a knock-knee.

Finally there is a condition called slipping patella in which, owing, to laxness of the aponeurosis and quadriceps muscles the patella slips

to the side when the muscles are relaxed, but is pulled into its normal position when the muscles are taut. This condition may be a congenital peculiarity, or may be due to an injury of the aponeurosis on one side, which allows the patella to slip away. If the latter be the whole cause of the trouble the treatment is easy, for lacing up or plicating the torn or stretched aponeurosis will cure the defect. Of all the other conditions enumerated above the various forms of outward displacements are the only ones which need detain us here, for they are by far the most common.

On looking into the mechanism of these, they all share a common factor; the axis along which the quadriceps extensor acts is not fairly along the middle of the front of the joint, and the greater the degree of associated knock-knee, the greater the deviation from normal.

It is, therefore, obvious that any knock-knee deformity present should first of all be fully corrected.

In a case which is giving serious trouble to the patient this would require an osteotomy of the femur.

When the bone is united the next point is to investigate the new line in which the quadriceps is acting.

In other cases where there is no appreciably knock-knee deformity, the real fault may be that the tubercle of the tibia with the insertion of the ligamentum patellæ is unduly far out. In such cases two procedures are open to the surgeon.

1. In the milder case he may split the ligamentum patellæ and detach the outer half, and, passing this under the inner half of the ligament, attach it afresh (Goldthwaite). This shifts the insertion of the ligamentum patellæ half its own width nearer the mesial line of the body, and makes a very appreciable difference to the line of traction across the joint.

2. He may remove half the tubercle of the tibia and mortise it into the tibia again, nearer the middle line.

Each of these operations may be fortified by plication of the capsule.

In some cases which are congenital or have begun in infancy and have not received early efficient treatment, the trochlear surface of the front of the condyles is necessarily adapted to the false movement which has so long been taking place. Great care must therefore be taken, when movement is allowed after either or both the preceding operations, that this movement is only in a correct direction, so that future adaptive changes may be toward the normal.

In a very severe case now under treatment by one of us (R. J.)

there is no outer lip to the trochlear surface while the inner lip is very high. To remedy this, osteotomy has first been performed to correct the knock-knee. A thin wedge of bone has been cut out of the inner condyle and the prominent edge of the trochlear surface pushed back without fracturing the articular cartilage. The case is now being watched and if necesssary the low outer edge of the trochlear surface would be lifted by driving a broad chisel behind it and levering the edge up gently, and then wedging it with a scrap of bone cut from some convenient place. Up to the present the case promises well, and is quoted only as an indication of the new field opened up by modern plastic surgery of bones.

Congenital dislocation of the knee is a very rare deformity, and no surgeon is likely to see many cases. The treatment must be designed to meet the deformity. The dislocation should be reduced, where possible, and kept reduced long enough for ligaments to shorten and other adaptive changes to take place. The child should of course walk as soon as possible in order to derive benefit from the physiological stimulus. This can usually be attained by fitting a walking caliper, with at first a close-fitting celluloid or other splint on the knee to keep the parts in correct position. Later a knee cage may be worn allowing some degree of movement, and so step by step the case can be carried on, till the maximum recovery possible is reached.

Bow-leg.—The commonest cause of bow-leg is rickets, but the deformity may follow an injury. It differs in one important particular from knock-knee, inasmuch as a mild degree of bow-leg is a position of strength and stability, while even the mildest degree of knock-knee is a weakness. As we have already stated, infants with active rickets should be laid out flat from head to heel with the lower limbs kept straight by splints. Most cases which come for treatment are in young children.

There are two distinct varieties of bow-leg. In one the whole limb is slightly bowed—this might better be called a bow-knee. If it occurs in a growing child it may be easily corrected by wearing a long inside brace similar to the outside knock-knee brace; in adolescents the progress is slower and more tedious.

The much more common variety is a bow-leg proper, in which the gross visible curve is mainly in the tibia and fibula. Such cases are practically always rachitic in origin. The femur is usually found to be more or less crooked, but only occasionally requires active treatment.

Treatment.—Apart from attention to diet, which belongs to the domain of the physician, the most important thing to remember is complete relief from the strain of carrying the body weight, and maintenance of the limbs in correct position, till the bones get hard. In children who have really got over the stage of active rickets, walking may be permitted in an inside brace or bow-leg iron, to which the curved limb is bandaged. This should have no joints, for as in the case of knock-knee splints, a joint in the splint allows the child to avoid the corrective strain, and much valuable time is wasted. No violent measures should be adopted in cases of active rickets, because while the bones are soft correction by splints in bed is easy, and during the active stage the child ought in any case to be kept lying down in a Thomas frame or similar appliance. For bow-knee the brace should extend to the groin, in bowed tibia from the tuberosity of the tibia to the heel of the boot.

Operative Treatment.—Gross cases may require osteotomy or osteoclasis, of the femur as well as of tibia and fibula, but these are comparatively rare. Up to the age of two years or so, it should be possible to correct every case of bow-leg manually without fracturing the bone. At one time we used to insist on breaking the bone or at least producing a definite green stick fracture. In recent years we have more and more contented ourselves with moulding the leg and fixing it in splints. We use sheet metal side splints. Prepare two pads of felt with holes in them, the one to fit the internal condyle, the other to fit the malleolus. The bow-leg is then bandaged tightly down to the gap between these two pads with or without an outside splint. Sheet metal splints have a small degree of resilience, which permits of much tighter bandaging than can be employed with wooden splints. The metal yields a little to the shape of the limb, and the risk of producing pressure sores is much less. In cases over two years of age the bones are generally too hard to be moulded; up to the age of four years the tibia can generally be broken by hand, the surgeon using the tuberosity of his own scaphoid as the fulcrum across which he breaks the bone. Manual osteoclasis is partly a matter of strength, but largely depends on the way the strength is applied. This knack may be acquired by practice, but cannot be described. There is one rule which should never be broken, the surgeon must never allow himself to use all his strength to break a bone. If he cannot break the bone with some of his strength in reserve to control the action, he should adopt some other means. Osteoclasis with an osteoclast is eminently

satisfactory in children up to 12 or 14, and often can be employed in still older subjects.

Cases requiring correction in later life will usually require osteotomy, for the bones are generally too hard to permit of correction by osteoclasis with precision and accuracy.

FIG. 392.—Defect of tibia.

For all such fractures of the leg, two side splints padded so as fully to correct the deformity are needed to control the limb perfectly. As already indicated, with sheet metal splints the surgeon can bandage with greater firmness than when he uses wooden splints. The wooden splint is less adaptable to the shape of the limb and would certainly

cause pressure sores if applied as firmly as we are accustomed to apply metal splints.

We never use padding made up and fixed to the splint but adjust cotton wool or felt where it is required.

It is wise to make sure that there is no undue pressure at any point within 24 hours of putting on the splints. A wisp of wool which presses on the skin will cause a pressure sore as quickly as a harder substance, and will often do so without the patient complaining of pain.

Congenital Defect of the Tibia and Fibula.—Congenital absence of the tibia is fortunately rare, for it is a very disabling condition (Fig. 392). Treatment should first be directed to correcting any curve in the fibula (in an infant this can be done by hand); the next thing is to supply a splint or apparatus in which the child can walk. Physiological exercise promotes the growth of the limb and induces the fibula to get thicker and stronger in response to the strain put on it. After the age of 10 years some operation may be considered. Thus when the upper end of the tibia was present the fibula has been mortised into its marrow cavity and the lower end into the astragalus, giving a fairly firm limb. Few cases, however, will be able to dispense with some sort of artificial support.

Congenital defect of the fibula is a much more common condition and is much easier to treat.

The diagnosis is not difficult. A baby is seen with a rather unusual type of club-foot, and the leg crooked. The presence of a dimple usually somewhere on the lower third of the leg on its outer side at once rouses suspicion. Palpation should then prove the diagnosis and an X-ray will confirm it. Sometimes the upper end of the bone is absent; more often the lower end, and rarely the whole bone. Very often both epiphyseal ends are present. The dimple seems to be produced by the intermuscular septum from the end of the bone that is present.

Treatment consists first of all in correcting all deformity present by moulding and splinting in infants; in older children an osteoclasis or osteotomy may be necessary to get the tibia straight. When the foot is square and the leg straight the child must walk to promote growth. An outside brace is a most excellent substitute for the absent fibula, as is shown by the accompanying photograph (Fig. 393). Note that the heel of the boot is "crooked" on the inner side, and that the counter-pressure of the ground is on the outer side of the foot up toward the internal malleolus. As there is no fibula, the ankle will not stand an outward thrust.

If the X-ray shows even a trace of an epiphysis at both ends, the proper line of treatment is first to correct any gross deformity of the tibia, and then transplant a strip of bone cut from the anterior edge of the other tibia, laying it between the two epiphyses, which should be slightly hollowed to receive the ends of the graft.

Congenital Club-foot.—One cannot put congenital club-foot among the "static" deformities, but the principles which govern its production and correction are those which apply to all the static deformities. There can be little doubt that the unusual varieties of congenital talipes such as talipes valgus and calcaneus are due to the foot being caught in some unusual position *in utero* and held there long enough for adaptive changes to take place. The most common variety, however, is talipes equinovarus, in which the deformity is merely an exaggeration of the normal intrauterine position of the feet.

FIG. 393.—Flat-foot shows boot with heel "crooked" on inside, and outside brace and strap to divert body weight on to outer edge of foot.

Some years ago attention was drawn to the presence of additional facets or to the peculiar shapes of the articular surfaces of the femur, the tibia and the astragalus in Zulus and natives of India, who habitually adopt squatting attitudes. One writer pointed out that these occurred also in the Indian new-born infant. It requires only the examination of a few new-born infants to show that these peculiarities are common also to the European infant, and depend on the squatting attitude *in utero*. In pursuance of this idea, one of the writers examined all the specimens of the tibia and astragalus which were kept for teaching purposes, in the dissecting room of the new school in Edinburgh. These were not a special series, but had been dried and prepared in the ordinary way from bodies which had been dissected and then kept for teaching purposes. About 30 per cent. presented the characteristics of squatting races. The explanation is to be found any fine summer evening by a tour round the mining villages where men, lads and children will be found squatting on their heels, the position in which miners in this district work underground.

The object of this digression is merely to show how profoundly the skeleton is modified by habitual positions and strains in accordance with Wolff's law.

We accordingly find in congenital talipes equinus that the deformity at birth consists of extension at the ankle-joint, some adduction at the

ankle-joint, and very pronounced adduction at the mid-tarsal joint. Along with this we find the lower end of the tibia rotated inward more than is normal.

All these peculiarities exist in a slight degree in the normal infant. Every infant when learning to walk begins in a bow-legged in-toed position like one of the great apes, and it is only when the child gets established in the erect position that the feet and knees assume the normal position, which by habit, we regard as correct. Unfortunately, as we shall see in dealing with flat-foot, the process may be carried too far, and the normally supinated foot of the new born may in a few years become a pronated foot.

FIG. 394.

FIG. 395.

FIGS. 394 AND 395.—Showing method of bandaging an infant club-foot in extreme over correction with sticking plaster.

The difficulty to be overcome in the first instance is the shortening of all structures on the inner side of the foot and the shortening of the tendo Achillis. This is not all, for, to get a cure, the elongated tendons on the outer side and dorsum must undergo adaptive shortening and regain power under exercise. This is the part of the treatment so often omitted and this neglect is the most frequent cause of failure and relapse.

The test of recovery is that the child can *voluntarily* evert the foot; till this stage is reached the foot must be kept under treatment.

The stages of treatment depend entirely on the stage of neglect at which the case is seen, and on the added deformity due to muscular action or, if the child has walked, to weight bearing; these added

difficulties are purely static and when they occur somebody is to blame.

1. The new-born infant should have treatment begun on the day of birth. At this early stage there is no difficulty in correcting the deformity fully with the thumb and forefinger.

The foot is then fixed in a fully corrected position in the following manner (Figs. 394 and 395). A strip of adhesive plaster is put round the foot from without inward over the dorsum; the tail of this strip is then pulled parallel to the outer side of the leg, to evert the foot and is there fixed with a circular strip round the calf.

If the skin will not stand any sort of adhesive strapping the same thing can be done with a soft linen or calico bandage, but this is more apt to slip.

This little device should be applied daily by the practitioner, the mother, or the nurse. The foot should not for one instant be allowed to relapse into the deformed position.

In a month or six weeks the previously over-stretched peronei and extensor muscles, and the stretched skin about the external malleolus will all have undergone adaptive shortening and the evertors of the foot are then ready to take charge of the situation. To give them exercise the mother tickles the sole of the infant's foot, near the outer edge; if the evertors have recovered the child everts the foot and dorsiflexes the ankle. The case then requires periodical supervision, until the child has learned to walk.

2. Three months of neglect change the picture completely. The child which began life with short calf muscles and tibialis muscles has for some months kicked about in its cradle and exercised these muscles. The evertors of the foot and extensors of the toes being at first over-stretched and unable to oppose the short muscles have really had no exercise and are more over-stretched and helpless than before. At birth the plantar fascia could be stretched with the finger and thumb; now it is hard and strong. Similarly it will no longer be possible to stretch the tendo Achillis without using an amount of force which puts the former method of daily stretching quite out of court as a practical procedure, for to put the foot up in the best position into which it can be forced means an amount of strain and tension which the child simply cannot endure, and is, moreover, harmful to the epiphyses near the ankle.

The most satisfactory method of procedure in our opinion is to

reduce the foot as quickly as possible to the soft pliable condition it was in at birth (Figs. 396 and 397).

FIG. 396.—Stretching the sole across the block.

This means division with the tenotome of every tight band in the sole of the foot. and by forcible moulding correct *all* the plantar

FIG. 397.—Moulding a club-foot over the wedge.

flexion and *all* the adduction at the mid-tarsal joint. In a badly neglected case some of the more tense fibers of the deltoid ligament may require division near their attachment to the os calcis.

When wrenching the foot, it is very important to guard the knee from injury. An assistant should grasp the leg below the knee and also the knee, and so prevent the surgeon from unintentionally straining the ligaments. If working single-handed it is a wise precaution to apply splints to the limb extending above and below the knee to guard the joint from strain. Neglect of this precaution may result in a bad strain of the internal lateral ligament of the knee, which is followed by a knock-knee, the treatment of which is very troublesome when a club-foot must be treated at the same time.

Last of all, when the foot is fully corrected, divide the tendo Achillis and correct the equinus deformity. The tendo Achillis must be left



FIG. 398.—Thomas' wrench and simple club-foot shoe. Note sole plate is slightly everted.

to the last, for it is the resistance against which the surgeon works to unwrap the curling of the sole.

If the case is properly handled the surgeon can now put the foot into full dorsiflexion and eversion by putting the tip of his little finger under the ball of the little toe. If the foot shows any tendency to wriggle off his finger and return to its deformed position, there must be some tight band or muscle acting against him. This he must find and must abolish its resistance by completely over-stretching it or by dividing it. He must not rest content until he has the foot absolutely plastic and under complete command. It may then be put at once into plaster of Paris, taking several turns on the same way as the turns

of sticking plaster shown above. If done properly there should be neither swelling nor pressure sores. Of course a complete well moulded covering of plaster of Paris should be got on at once, before any reactionary swelling comes on; if the surgeon prefers he may bandage the foot firmly in a club-foot shoe (Fig. 398) and put it in plaster two or three days later. The child should be left in this for a month or six weeks. If the position of the foot is then not perfect, mould again and put in plaster in better position.

As soon as the evertors take command and voluntary eversion can be performed without effort, active treatment is really at an end, and all that is needed is to watch the child till it begins to walk. A simple club-foot shoe may be worn at night with advantage.

In older cases in this group it will sometimes be found that the os calcis is very short and the heel very poorly developed. This is the natural result of a very much inverted foot, in which the os calcis is tilted inward and the natural traction development of the heel is perverted by the wrong line of action of the tendo Achillis. This gives a great deal of trouble, and is only one more reason for immediate treatment at birth.

In older children of four or five years of age, a poorly developed os calcis is an absolute bar to a really perfect result; fortunately only a small number of cases suffer from very short heels. If the child is a year old the surgeon may mould the foot in two stages if he thinks fit. As a rule this will depend more on his own dexterity than on any real difficulty in the way of complete correction at one sitting. Our own rule is when in doubt not to do too much, but on no account to be timid.

In children under a year an anæsthetic is optional. The manipulation undoubtedly hurts for the time, but no child remembers events in its first year in after life. If the parents are within earshot, or if the child is the delicate offspring of neurotic parents, an anæsthetic is advisable.

If the surgeon elects to follow the school of doing a little stretching at a time, and doing it often, he will terrorize the child. Our own experience is that even if the infant is considerably hurt at the first stage, by doing all the necessary stretching once and for all the child is not hurt at the second visit, and immediately recovers confidence, and by the third visit friendly relations can be established without trouble.

If the case has been neglected till the child has begun to walk, changes due to gravity are added to those due to unopposed muscular action.

The apparent deformity is no real measure of the intractability of

FIG. 399.—Congenital club-foot. Case J. H. B., before operation.

FIG. 400.—Congenital club-foot. Case J. H. B., before operation.

FIG. 401.—Congenital club-foot. Case J. H. B., after operation. Preliminary wrenching followed by a small cuneiform osteotomy.

FIG. 402.—Congenital club-foot. Case J. H. B., after operation. Preliminary wrenching followed by a small cuneiform osteotomy.

the case. A child of five may be walking on the dorsum of the cuboid and yet a shapely foot can be rapidly obtained by wrenching and moulding alone, without any osteotomy.

Some cases will require a cuneiform osteotomy in the end, but if the surgeon moulds the foot and patiently waits for adaptive changes after each sitting, he will find that a very moderate cuneiform osteotomy will suffice, whereas in the first instance it appeared quite impossible to get a straight foot without a very formidable removal of bone (Figs. 399, 400, 401 and 402).

In some instances a wedge from the outer side of the neck of the astragalus will suffice. In the worst cases a wide cuneiform osteotomy, regardless of the actual bones cut into, is the only thing which will enable the patient to get the sole of his foot fairly and squarely on the ground.

Fig. 403.—Congenital club-foot. Boot with "outside flapper" to evert the "fore-part" of the foot: also inside brace.

A cuneiform osteotomy is at best a mutilating operation for it means removal of bone and unavoidable shortening of the foot.

In all cases begun before the child walks, and in all cases treated later, the child must be taught to walk with the foot well everted.

To secure this we employ a boot with a low heel and a strip of leather or iron along the outer edge of the sole (Fig. 403). This was called an "outside flapper" by H. O. Thomas. The position in which the foot is placed by this device everts the foot and so allows the child's body weight to complete the work of the surgeon.

In many cases in addition to the deformity in the foot itself, there is an inward rotation of the lower part of the leg, so that the antero-posterior line between the malleoli does not correspond with the antero-posterior line of the knee.

At one time it was our practice almost as a routine to perform an osteoclasis of the lower third of the tibia and turn the lower part outward through the desired angle. One case 15 years ago failed to unite and has remained ununited in spite of numerous attempts to secure union by operation. Today we seldom perform this operation.

Rotation by Hand.—Experience has shown that in young children it is possible to twist the tibia by hand. The surgeon grasps the leg below the knee and at the malleoli, then forcibly wrings the lower end outward. The mother or nurse is instructed to twist the leg two or three times daily in the same way. It is only necessary to strain the structure of the bone a little in the first instance, but not necessary to produce an actual fracture. If this is done, the wearing of an "outside flapper" on the boot when the child is allowed to walk helps to increase the outward rotation.

In obstinate cases the action of the outside flapper is reinforced by an inside brace (Fig. 403) and T-strap.

Note that the brace has no joint opposite the ankle. A joint increases the expense, reduces the efficiency of the splint while adding to its weight and is really a disadvantage in walking.

Finally, in some instances in which all deformity has been completely overcome without removal of bone, there remains a tendency to relapse, because the evertors of the foot are too weak efficiently to control the invertors. To obviate this we have for some years transplanted the tibialis anticus into the dorsum or outer edge of the cuboid with gratifying results. The greater the weakness to be overcome, the further out the tendon is shifted. The technique of this operation will be described in the treatment of paralytic deformities.

The other varieties of congenital club-foot are treated *mutatis mutandis* in precisely the same way. The principles which guide us are very simple.

1. Abolish all contracture by dividing the stronger bands of fascia which have become short and by stretching the others. We have a dread of open wounds in these cases and therefore never employ such procedure as Phelps' well-known operation. Experience has shown that by working steadily with the hands in young infants and with the Thomas' wrench (Fig. 398) in older children, every resisting structure can be fully stretched. There should never be any rough or irregular movement made with the wrench. "Suaviter in modo sed fortiter in re" is the motto to follow.

2. If every resistance is completely overcome, the deformed foot may be fixed in the fully over-corrected position till (*a*) it has recovered from the assault made on it, and (*b*) till the previously over-stretched ligaments have shortened and adapted themselves to the new position.

There are two faults to be avoided: first, if every tight structure is not completely over-stretched and the surgeon puts the foot up with

tension on some muscle or ligament, the pain will absolutely prevent sleep and in 48 hours the child will be a nervous wreck, and both child and parents will be opposed to having more done; next if in fear of this the surgeon puts the foot up in less than the best possible position, the stretched and ruptured tissues will heal in a shortened position and the cicatrix will tend to contract still further. At a subsequent period the surgeon will have to stretch this scar tissue and will find it very difficult to do. Meddlesome surgery with inefficient after-treatment is to be strongly deprecated. It is very annoying to have to treat a case in which somebody else has performed an inefficient and half-hearted operation, or has allowed tissues to contract, instead of keeping them fully stretched till the repair was absolutely complete.

Do not lose sight of the case till the child is walking well with the foot in good position; appearances are deceptive but a good functional result will not relapse for the body weight will keep it correct if the after-treatment is properly carried out.

The statement still sometimes seen in surgical textbooks that congenital club-foot is a most intractable condition and one particularly prone to relapse, is not true. Such a statement can be based only on indifferent surgery and half-hearted after-treatment.

In conclusion, we may say that the causes of relapse are:

(*a*) Incomplete correction of the deformity in the first instance.

(*b*) Incomplete shortening of the lengthened structures, and especially incomplete recovery of strength in the muscles. In this connection it may be noted that the cause of the relapse is exactly the same as the cause of paralytic club-foot, namely, the over-stretched muscles cannot balance the stronger short muscles.

(*c*) Walking with the body weight so borne as to cause a recurrence. The body weight must be deviated so as to maintain the correction until the muscles recover full power.

If these points are carefully attended to, relapse should be very rare. The surgeon need have no fear of failure of union in the divided tendo Achillis.

Hollow or Contracted Foot, Claw-foot (*Pes Cavus or Pes Arcuatus*).—Pes cavus is a condition in which the antero-posterior arch of the foot is greatly exaggerated; it is further characteristically marked by dorsiflexion of the toes at the metatarso-phalangeal joints and flexion at the interphalangeal joints (Fig. 404). The deformity is, therefore, similar its nature and its treatment to congenital club-foot.

This type of deformity is undoubtedly often seen in paralytic af-

fections such as Tooth's paralysis and Friedreich's hereditary ataxia; there has been some controversy as to its etiology, some neurologists maintaining that all these cases are paralytic in origin; on the other hand the orthopedic surgeon, while admitting the paralytic origin of a large number, is driven to the conclusion that some are purely postural due to contracture of the structures on the sole, induced perhaps by a growing child wearing boots that are too short, and that some must be attributed to peripheral not central nerve lesions; this question is, however, too big for discussion here.

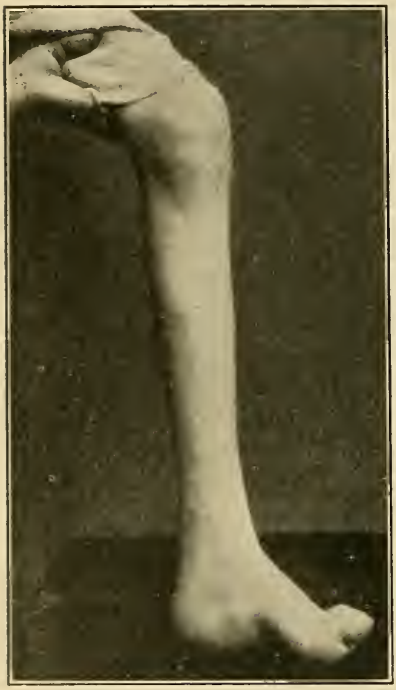

Fig. 404.—Claw foot: Note (1) cavus or flexion at midtarsal joint; (2) characteristic dorsiflexion of toes.

We can have no sympathy with the view taken in some neurological clinics that the deformity is a minor and not very interesting feature of an interesting nerve lesion. This view is not shared by the patient, for his nerve lesion as such does not hurt him, but his feet do, for he is compelled to walk on the ball of the foot. His gait is, therefore, unsteady, because he cannot get his heel properly to the ground; further he gets a row of callosities across the ball of the foot under the heads of the metatarsals, the pain of which makes walking any distance an impossibility. The view of the orthopedic surgeon is very different, for he sees many cases of pes cavus, in which the origin may well have been a transitory paralysis, following scarlet fever, influenza, or some other acute infection, of which no very definite history can be obtained, but of the scores of cases seen in a period of 15 or 20 years, very few prove to have a progressive paralytic condition, and even when a progressive paralysis is present its progress is so slow that it is quite possible to give the patient years of comfort in walking before he is disabled by his paralysis, and this is well worth doing.

The orthopedic treatment depends on the stage of the deformity. Of these stages six may be distinguished, the extremes varying so greatly in appearance and in symptoms that unless cases had been

followed through the various degrees it would be difficult to believe that they really represent different stages of development of the same condition.

I. *The First Degree.*—The first degree of claw-foot is generally recognized only among the better class of patients, for the poorer classes seldom seek advice till a later stage is reached. At this stage there is no visible deformity of the foot. The only complaint made is that the child is clumsy and stumbles. This condition may be recognized at the age of five or six years. To diagnose the condition extend the patient's knee and test the range of dorsiflexion at the ankle. It will be found that the foot cannot be brought beyond a right angle. Also if the patient be asked to stand on his heels, lifting the forepart of the feet off the ground, he cannot do it.

Fig. 405.

Fig. 406.

Fig. 405.—Claw foot. Case F.F. Shows correction of deformity by lifting ball of foot with finger. Therefore, suitable case for tendon transplantation.
Fig. 406.—Claw foot. Case F.F. Shows characteristic deformity.

In the earliest stages there is little or no flexion at the mid-tarsal joint, and the treatment is, therefore, directed to securing a freer range of dorsiflexion of the foot (*a*) by manipulation, (*b*) by knocking off the heel of the boot and putting a bar ¼ in. thick across the sole.

II. *The Second Degree.*—In the second stage deformity of the foot is just beginning to be visible. Owing to flexion at the mid-tarsal joint, the ball of the foot is dropped and the toes slightly dorsiflexed at the metatarso-phalangeal joints, the contraction of the plantar fascia is very slight (Fig. 405). There is of course some contraction of the tendo Achillis. The patient walks too much on the fore part of the foot and has difficulty in getting his feet fairly on the ground.

The test the surgeon must apply is to put one finger under the head of the first metatarsal and see if he can lift the ball of the great toe and so

flatten the sole of the foot without difficulty (Fig. 405). If he can do this then the case is a second-stage case, and the following treatment should suffice.

(*a*) Subcutaneous division of plantar fascia and thorough wrenching to stretch all structures in the sole of the foot.

(*b*) Division of the tendo Achillis only when the sole is quite flat with no remaining resistance.

(*c*) Transplantation of the tendon of the extensor proprius hallucis into the head of the metatarsal.

Technique.—(*a*) Incision parallel to the inner side of the tendon. (*b*) Expose and divide the tendon as long as possible. (*c*) Cut down on the metatarsal bone just behind the head, drill a hole right through. (*d*) Tie a ligature to the end of the tendon, pass it through the bone, drawing the tendon right through. If the tendon is long enough it is brought round the inner side of the bone and secured to its own proximal portion; if not long enough for this it is secured to the periosteum.

After-treatment is, as before, walking in a boot with low heel and a bar on the sole, and if there is any fear of the sole contracting again, the foot should at night be firmly bandaged flat on the sole piece of a club-foot shoe to prevent contraction during sleep.

III. *The Third Degree.*—In the third stage all the contractions are more marked. The patient complains of callosities forming under the heads of the metatarsals. The plantar fascia is contracted so much that the ball of the foot can be lifted only with difficulty, and the surgeon cannot make the foot look normal in this way.

When this degree of deformity is reached, operation must be in two stages.

1. Division of every tense band in the plantar fascia, and then very thorough wrenching till the sole is fully stretched and all cavus deformity is eradicated.

Then put up in a club-foot shoe or better still in plaster of Paris with a metal sole plate. If not complete in one sitting repeat the wrenching.

2. Second operation. When the deformity of the sole has been completely overcome and not before, divide the tendo Achillis, and transplant the extensor proprius hallucis as before.

IV. *The Fourth Degree.*—The characteristic deformity is present, but now the callosities on the sole are very thick, hard and painful. The toes are rigid in dorsiflexion, and the patient cannot move them freely. There is often in addition a slight varus deformity, which makes the condition look like a talipes equinovarus were it not for the characteristic position of the toes.

Here again operation must be in two stages, but the operation already described will not suffice.

1. In addition to dividing the plantar fascia and wrenching, the extensor tendons of all the toes should be divided subcutaneously. Also the tenotome is slipped in on the flexor aspect of the interphalangeal joints and the plantar aspect of the capsule divided. Each toe is then straightened out.

2. As it is impossible to get all the structures of the sole completely stretched, the second stage consists in meeting this difficulty by shortening each metatarsal except the fifth, by cutting a piece out of the middle of the shaft. After division of the tendo Achillis, the foot is put up in the fully corrected position.

FIG. 407.—Claw foot. Sixth stage case showing result after amputation at necks of metatarsals.

V. *The Fifth Degree.*—In the fifth stage the foot is very painful and useless. All the deformities mentioned already are present in a marked degree, varus deformity is more pronounced, the toes are very rigid and useless, and the movement of the ankle-joint is very limited, in fact the ankle-joint may be practically rigid.

Treatment.—In addition to the above procedures, excise the astragalus, put the foot up in good position and the patient will be able to walk in comfort.

VI. *The Sixth Degree.*—In the sixth stage the foot is absolutely rigid and useless and is so painful that the patient implores the surgeon to amputate the whole foot and is not willing to listen to any suggestion of less drastic treatment.

At this stage all the metatarso-phalangeal joints are dislocated with the phalanges on the dorsum of the heads of the metatarsals.

Treatment.—Do not amputate the foot but (*a*) remove the astragalus; (*b*) amputate just behind the heads of the metatarsals, turning up the ball of the foot as a flap (Fig. 407). When cutting the flap get as well forward to the roots of the toes as possible.

The painful callosities soon disappear and the result is an extremely useful foot.

These are the operative procedures but success depends a great deal on intelligent after-treatment.

As in all other deformities, the essential test of recovery is that the patient can voluntarily over-correct the previous deformity without effort. To attain this, the over-stretched extensors of the foot and dorsiflexors of the ankle must be given every opportunity for complete recovery of power.

Thus, the foot should be bandaged to a flat sole plate at night to keep the sole flat and should be kept in a right angled position or even dorsiflexed during sleep.

Boots should have stiff flat soles and should lace rather tightly over the instep to prevent the foot from humping. The forepart of the boot should be roomy so that there may be no mechanical impediment to the foot flattening out. The pain caused by callosities in the sole can be avoided by putting a bar across the sole just behind the row of callosities. This forms part of the treatment in any case, and by taking pressure off the callosities affords almost immediate relief to the patient. The callosities disappear in a very short time when relieved of pressure.

Flat-foot and Related Conditions.—1. Flat-foot, everted foot, weak foot are all terms applied to the same condition or more properly to various degrees of the same deformity. It would also be possible to classify these conditions in other ways as acute flat-foot, painful flat-foot, and painless flat-foot. Such terms, however, are of little value except to awaken the practitioner to the fact that in the different stages the appearance of the foot and the symptoms most complained of are very different; yet in all, the mechanical strains have certain features, and accordingly the methods of relieving them are framed on a common plan guided by common sense.

In dealing with knock-knee it was pointed out that the body weight is transmitted down a line from the hip through the knee to the ankle and foot. The effect on the foot depends, therefore, on its position and on the way in which this downward pressure of the body weight is met by the upward pressure of the ground on the sole of the foot.

Each foot rests on three points: the heel, the ball of the great toe and on the outer side the heads of the metatarsals of the fourth and fifth toes. In a strong foot with the transverse arch well maintained by the small muscles of the sole, this outer point of support is the head of the fifth metatarsal. In most people who habitually wear boots really a

little too narrow for the foot, the fourth metatarsal bears more weight than the fifth. As we shall see later, an exaggeration of this common fault contributes to the condition known as Morton's metatarsalgia.

The conformation of the arches of the two feet is such that when a man stands with his feet touching along their edges the feet form a dome, and the body weight is carried all round the margin of this dome. When the architecture of the foot is examined, particularly with regard to the antero-posterior arch, we find that the foot must be considered in two portions, namely, the forepart in front of the mid-tarsal joint, and that behind it consisting of the os calcis and astragalus. The results of such operations as Chopart's and Syme's amputations show that the posterior part of the foot possesses considerable mechanical stability; it is, therefore, the forepart of the foot and Chopart's joint (mid-tarsal) which suffer strain in weak and strained feet. Thus, if a patient stands leaning back with his weight on his heel he stands as he would if he had a Chopart's amputation; as he leans forward the weight comes more and more on the forepart of the foot, until the heels are raised from the ground and he must either fall or step forward.

In this forward leaning position the strain is taken by ligaments and muscles controlling the forepart of the foot. The first part of the strain naturally falling on the inferior ligaments of the mid-tarsal joint, viz., the plantar ligaments and the inferior calcaneo-scaphoid, the last suffering most as it is nearest the key of the arch.

Again the stability of the base of support depends on the breadth of the forepart of the foot. In the infant and in barefoot races the great toe appears to be turned inward. This is an effective check against capsize of the foot inward or collapse of the inner side of the arch. It is the spread of the forepart of the foot and the mobility in all its joints, especially at the mid-tarsal joint, which permits this.

This adduction of the forepart of the foot should really begin at the neck of the astragalus, and does so in the infant, the Zulu, the Indian and other races who do not hamper the foot with tight, badly designed boots.

In European races who wear modern boots the effort at getting a pointed toe abducts the forepart of the foot; this not only strains the mid-tarsal joint into eversion, but helps to account for the fact that the neck of the astragalus makes a smaller angle with the body of that bone than in the European infant or in barefoot races. It stands to reason that a boot which cramps the forepart of the foot will weaken it by depriving the small muscles of the opportunity of exercise. If, further,

it abducts the great toe and forefoot, it diminishes the stability of the tripod of support and so increases the liability to strain of the long internal arch and produces an everted or flat foot. Even the man of fashion recognizes this, for though he may wear tight boots on the smooth pavements of the town, he wears broad roomy boots when golfing, shooting or climbing mountains, for he recognizes that the stability of the foot depends on the grip the forepart gets on the ground. In diagnosing weak foot or everted foot, the shape of the foot at rest is of little importance. Some families have naturally a higher arch than others. This height of the arch should be seen on the dorsum of the foot, not as a concavity in the hollow of the instep, for this hollow should be filled with the bellies of well developed muscles and with fat.

With reference to this I may quote from a book entitled "The Northwest Passage by Land," by Viscount Milton and Dr. Cheadle, which gives an account of the crossing of the Rockies by the authors in 1863–4.

"In walking in the snow, in Indian file, we observed La Ronde's great length of stride; and Cheadle, in particular, who prided himself upon his walking powers, was much chagrined to find that he could not tread in La Ronde's footsteps without springing from one to the next. Afterward he discovered that his longest stride was only just equal to that of the little Indian boy.

"The superiority of the Indian in this respect doubtless results from the habitual use of moccasins, which allow full play to the elastic bend of the foot. This is impeded by the stiff sole of an ordinary boot. The muscles of an Indian's foot are so developed that it appears plump and chubby as that of a child. The Indian boy continually derided the scraggy appearance of our pedal extremities, and declared there must be something very faulty in their original construction."

When the patient stands on the foot the forepart should normally spread nearly ¼ in., but the arch ought to remain. If the inner ankle and the tuberosity of the scaphoid roll inward and downward toward the floor, muscles and ligaments are certainly stretched. In the matter of shape, American bootmakers are in advance of most of the English, though doubtless fashion influences this greatly.

The pains of which patients complain are due to stretching of ligaments, to pressure on the ball of the foot, to pressure of bone on bone, and to stretching of muscles.

One of the commonest early symptoms is fatigue or pain in the instep, and pressure with the finger on the inferior calcaneo-scaphoid

ligament proves that this region is tender. This is the most pronounced symptom in the acute flat-foot of rapid onset, which one sees well exemplified in our hospital nurses when they have been short handed during influenza epidemics. Nurses just convalescent from influenza were back on duty without a proper period for convalescence, with the result that in a few days some of them could not stand on account of painful feet; not only so, but the effort to keep going only led to rapid stretching of all the ligaments and the production of a real flat-foot, and all the muscles and ligaments ached. The other clinical variety sometimes referred to as painful flat-foot is simply a milder variant of this, for the patient suffers the pain of stretching ligaments but does not go on stretching the ligaments by over-work; the foot, therefore, may not appear flat.

Painless flat-foot is an end product of this process. Thus if the nurse whose arch has collapsed rapidly merely rests without putting the foot first in the corrected position, the acute process subsides and the foot recovers with all these ligaments stretched and the foot in a deformed position.

Pain across the ball of the foot is due to atrophy of the fatty pad, and the formation of callosities under the unprotected heads of the metatarsals. Such are seen in bad cases of pes cavus, and also in cases of Morton's metatarsalgia, which is always allied to flat-foot. Hallux flexus or rigidus, as will be seen later, is also an allied condition. Pain across the dorsum of the foot is generally a periostitis caused by pressure on the edge of the periosteum, just beyond the articular cartilage, when the joints are dorsiflexed a little beyond their normal range of movement. This continued periostitis may give rise to a lump of new bone and thickened periosteum, which has been erroneously described as a dislocation. This also occurs on the dorsum of the neck of the scaphoid. It is interesting to note that races who habitually adopt the squatting posture have the articular surface of the astragalus elongated forward and the corresponding surface of the tibia adapted to this increase of dorsiflexion. The pain sometimes noted under the tip of the external malleolus is found when the valgus deformity of the foot is great, and is due to pressure between this bone and the outer surface of the os calcis. It is sometimes due to a traumatic periostitis, and sometimes an adventitious bursa is formed which may become inflamed.

Pains up the leg are often due to strained muscles, which have struggled to maintain the arch when the ligaments failed to do their

duty. Sometimes they may be "referred pains" when the whole foot is aching.

Treatment.—From a proper appreciation of the mechanical causes the appropriate treatment can be deduced easily.

1. A case of acute flat-foot in which the whole deformity has come on rapidly in a few days is much too painful to touch. First, then, the patient must rest in bed for a few days, without once putting foot to the ground. This will permit of recovery from the acutely painful condition, and light massage will help. After a few days all swelling will have subsided and the foot can be inverted, placed into the fully arched position and put up in plaster for about 10 days or a fortnight. As soon as all pain has subsided the patient may begin to walk, in the plaster splint, for physiological exercise hastens repair and the plaster splint will prevent any harmful strain occurring.

2. If the foot is already flat (painless flat-foot) it cannot be so simply put back into correct position, but unless it is a very old condition with pronounced bony changes the foot can be treated as one treats a club-foot, by wrenching the foot under an anæsthetic till every short ligament is stretched and the foot is absolutely pliable. It can then be put in plaster in correct position and kept there, say 14 days, to recover from the operative interference.

It is obvious that cases of traumatic and inflammatory flat-foot will be amenable to this line of treatment. For example, a foot that has been badly twisted or has been run over by a carriage wheel will end up as a flat-foot unless the surgeon treats it at once in this position, and it saves time to put it up when it is pliable from the injury instead of letting it get stiff and then having to make it pliable with the wrench. Also the foot that results from such a condition as gonorrhœal arthritis is mechanically the same foot as an acute flat-foot. This form of so-called arthritis is really a periarthritis in which all the ligaments and connective tissues are infiltrated, soft and yielding.

In all such cases if the foot is put at once in a club-foot shoe with an inversion twist instead of an eversion twist, the foot will not get flat. If the patient has recovered with a rigid flat-foot, no time should be lost before wrenching it to make it pliable, then put it in plaster for two weeks; the patient will then be able to work in properly planned boots.

This leads us to the ambulatory treatment of these cases and all the milder varieties.

First of all the patient must carry his weight well on the outer edge of

the foot to allow the strained invertor (tibialis anticus and posticus) muscles to recover tone, and to allow stretched ligaments to undergo adaptive shortening. All that is needed is to see that the patient wears a boot with a firm flat sole, has the inner side of his heel a full quarter of an inch higher than the outer, and has the inner side of the heel extend half an inch further forward than usual. Skewing the heel (see Fig. 393) adds to the breadth of the base support, and will often obviate the necessity for an outside brace and inside T-strap (see Fig. 393) to maintain the inversion at the ankle. A small patch just behind the head of the metatarsal will help to compel the patient to turn his toes in.

As already mentioned in connection with knock-knee, the child with commencing flat-foot or knock-knee unconsciously turns the toe in to save the structures that are yielding. If this treatment is to be curative, it must be continuously and conscientiously carried out by the patient. We are in the habit of giving the following instructions:

1. Every pair of boots, shoes, slippers, tennis shoes, etc., which the patient wears must be crooked.

2. The patient must never for one instant stand barefoot on the flat of the foot, for to do so would immediately stretch structures which have begun to shorten.

3. Massage of the tibial group of muscles (invertors of the foot) is desirable.

4. The patient should never evert the foot when standing, walking or sitting. When standing and walking the feet should be parallel; when sitting the feet should be crossed and resting on their outer edge, to relax the stretched structures on the inside.

5. *Exercises.*—The commencing position must be with feet parallel. Tiptoe, keeping on the outer edge of the foot. Practise walking on the outer edge of the foot. Exercises not to be commenced in the bad cases till muscles have recovered some tone. If by any chance the patient gets out of bed in bare feet, he must walk on tiptoe. It is of the utmost importance that all exercises should be done in boots with altered heels. If this rule is not adhered to the patient will be sure to relax his muscles at some time and stretch all the ligaments by coming down heavily on his heels and so do serious harm.

Exercises alone without the other precautions will not cure bad cases, and will fail in many of the minor cases because the ligaments are stretched in the intervals between exercises.

It will be noted that we do not use sole plates or instep pads. This

is not merely because we prefer to crook the heel to divert the body weight, but because we consider instep supports wrong in principle. To obtain a cure, not merely relief, it is necessary that the muscles and ligaments of the sole should recover strength and tone. To compress them between an instep plate and the bones of the foot is the wrong way to set about this. When the boots habitually worn by the patient are not of a good shape, an entire new outfit should be ordered. While the American last is better than the English last, commonly used by makers of ready-made shoes, even the former is not perfect. The hind part of the foot and the fore part of the foot have two distinct axial lines, that of the hind part being an antero-posterior line about the middle of the articular surface of the astragalus. The neck of the astragalus is directed inward from this. The bootmaker, when taking a tracing of the foot, should be instructed to adduct the foot of the mid-tarsal joint so as to get this angle as pronounced as possible. The sole of the boot should be as broad as the foot when the weight of the body is on it. The upper of the fore part of the boot should be easy so as to leave room for the toes to exercise themselves inside the boot. In short, the only place where the boot should grip the foot is round the ankle and heel. As the small muscles recover and the arches of the foot become restored, the foot becomes "smaller" and the last may be altered accordingly when other boots are being made. A patient who has once worn properly shaped boots will never return to the other type, for the difference in comfort is so great.

After a patient has recovered, it is good to advise that one pair of walking boots with crooked heels should be kept in reserve to be worn if he intends to take a country walk longer than usual, or to relieve the feet on the slightest sign of strain in the instep.

The question may arise whether a case of flat-foot is suitable for treatment by deviation of the body weight with altered boots alone, or whether the foot should first be wrenched and put up in plaster of Paris for some time.

The rule to be followed is: if the patient can voluntarily invert the foot, then altered boots will suffice; if, however, he cannot voluntarily invert his foot, then there will be some mechanical resistance by shortened ligaments to overcome with the wrench, and also some elongated muscles which require a period of absolute rest in plaster.

A final word of warning may be given that the surgeon is not to be misled by the appearance of the foot. Members of some families have naturally a very high arch. In these cases the pain of stretching

and strained ligaments is very intense long before the foot appears flat or would be pronounced flat by any of the ordinary footprint tests.

Spasmodic flat-foot is marked by spasmodic contraction of the two peronei muscles. The condition is, therefore, a spasmodic pronation of the foot associated in many cases with pain. This condition is not to be confused with secondary adaptive shortening of the peronei in a case of flat-foot with descent of the arch and stiffness in the deformed position. The diagnosis is made on the fact that the patient is usually an adolescent and that the condition has arisen rapidly and not as a consequence of previous flat-foot, and is confirmed by the surgeon suddenly twisting the foot into the inverted position while distracting the patient's attention with conversation. By taking the peronei muscles off their guard in this way proof is given that their contraction is a spasm and not an actual adaptive shortening.

Treatment must be thorough and depends on entirely abolishing the power of contracture of the peronei for several weeks. Unless this is very completely achieved, the condition is very liable to recur. There are two methods of attack by operation:

1. Resection of about ¾ in. of each of the peronei tendons is the operation we have been in the habit of doing for many years. The foot must then be very forcibly twisted into complete inversion and fixed in that position for three weeks. The tendons always reunite; the trouble is that mere division of the tendons is not enough, for they reunite too soon and recurrence of the spasm causes reappearance of the deformity.

2. Mr. Naunton Dunn's operation abolishes the spasm by paralyzing the two peronei muscles. The procedure is to cut down on the external popliteal (peronæus communis) nerve as it winds round the neck of the fibula, and trace it down to its bifurcation into anterior tibial (peronæus profundus) and musculo-cutaneous (peronæus superficialis). The latter branch is then crushed with an ordinary pair of pressure forceps. This produces paralysis of the peronei muscles which lasts for six to eight weeks. The anæsthesia of the dorsum of the foot has never caused any trouble. The wound is sutured. In either case the wearing of a boot "crooked" on the inside to maintain inversion is desirable for some weeks after the patient gets up.

Hallux rigidus is a condition marked by limitation of dorsiflexion of the great toe at the metatarso-phalangeal joint, hence Davies-Colley described this condition as hallux flexus. The onset of this condition is insidious and is associated with some degree, first, of arthritis

and, later, of osteoarthritis of the metatarso-phalangeal joint. The patient complains of shooting pain through the joint; this is too often diagnosed as either "gout" or rheumatism. In the former condition the whole joint is tender, but in a characteristic case of hallux rigidus it will be found that tenderness is best elicited by pressure from above downward and inward obliquely across the joint and not vertically. At first dorsiflexion is limited and later the toe may be actually flexed, which of course impedes free movement when stepping off onto the other foot. The condition may arise from an injury such as "stubbing" the toe, but is very commonly associated with weak foot and everted foot.

The treatment is first of all directed to resting the joint so that the inflammatory processes may subside. This can be done by placing a bar across the sole immediately behind the metatarsal heads, so that pressure falls on the neck of the metatarsal, not on the head. A skilful bootmaker will conceal a bar in the sole, if desired, otherwise a football bar will suffice.

When there are osteoarthritic changes, this treatment is often not sufficient. It is possible to promise a complete cure by operation. This consists in excision of the head of the metatarsal along with about ½ in. of the neck.

One is often tempted to remove too little bone. This is a mistake, for it may lead to a recurrence of the pain and deformity. After two or three weeks the patient may walk with a bar on the sole behind the metatarsal heads. If there is associated flat-foot the heel should also be crooked and elongated, as already described.

Hallux valgus is sometimes a further stage of hallux rigidus, and sometimes develops without any of the characteristic features of the latter condition. The connection between pointed boots and this deformity is too obvious to need more than passing mention. It is also clear that the abducted position of the great toe is a contributory cause of the flat-foot which practically invariably accompanies it. some surgeons advise the use of a "toe post" to hold the great toe in an adducted position. This sometimes succeeds, but very often the toe post, if fixed in an effective position, is too irritating to be tolerated.

Treatment.—(1) In cases of mild deformity treat the flat-foot, set the patient to daily movement of the toes, and often a satisfactory degree of improvement results from the habitual use of well-shaped boots and the gradual restoration of function of the joint. At night the pa-

tient may wear a splint shaped like a shoe horn along the inner side of the foot. (2) In severe cases, in which the extensor and flexor hallucis muscles help to maintain the deformity, such measures are ineffective. Further, in these severe cases the joint surfaces are altered in shape, osteoarthritic troubles are often present, and in addition the well-known bursa commonly known as a bunion.

In these cases the same operation as has been advised for hallux rigidus will be found effective. A flap of fat or connective tissue should be turned in over the cut end of the metatarsal to help in the formation of a new joint. Mayo advises the use of the bunion for this purpose and makes a flap incision with the base posterior; otherwise a simple straight incision in the inner aspect of the joint suffices.

Our experience is that free removal of the whole head and part of the neck of the metatarsal gives much more satisfactory results than an attempt to restore the line of the joint by a cuneiform resertion of the neck, though there is an air of refinement about the latter operation which is very tempting. The patient can walk quite comfortably a fortnight after the operation if he has a bar on the sole of the boot, behind the joint to divert pressure.

Hammer-toe usually affects the second toe, which is dorsiflexed at the metatarso-phalangeal joint, and flexed at the first interphalangeal joint. There is frequently a corn on the tip of the toe, another under the head of the metatarsal, which is forced down out of the transverse arch, and a corn or bursa on the knuckle, which projects on the dorsum. Hammer-toe may be congenital and is often hereditary, but is usually due to tight boots. It is frequently associated with hallux valgus, as the abducted great toe crowds the second toe out of position.

Treatment.—1. *Mechanical.*—Proper boots should be worn and any tendency to hallux valgus should be treated. The hammer-toe is straightened out and fixed in a light metal splint to keep it straight. This can be worn inside the boot.

2. *Operative.*—In most cases, however, it is quicker and simpler to remove the first interphalangeal joint, and the bones must be ankylosed, otherwise the condition recurs. An appropriate splint is then applied. This operation is preferable to amputation, for hallux valgus is apt to follow the latter operation. In excising the joint we make an oval transverse incision over the prominent knuckle, entirely removing the corn or bursa if present, and then nip out the prominent angle of the interphalangeal joint with punch forceps. This procedure gives a more satisfactory result than a formal excision of the joint. When this skin

wound is stitched up, the skin on the dorsum of the toe is shortened and helps to keep the toe straight.

Morton's Metatarsalgia.—In every case of flat-foot both the transverse and longitudinal arches suffer strain, but not necessarily in equal degree. The condition known as metatarsalgia was first described by Morton in 1876, as occurring in the fourth metatarso-phalangeal joint with radiating pain into the toe and up the leg. Originally the condition was ascribed to the wearing of tight boots and the compression of nerves between the heads of metatarsals. Later investigations have shown that it is weakening of the transverse arch of the foot which is the primary fault, but the wearing of tight boots is a factor in the case for this, by preventing free play of the muscles, produces weak and flat foot. Also when the forepart of the foot is pushed into a tight boot, the toes and metatarsals must be crushed together. If the transverse arch is broken, one metatarsal head, commonly the fourth, is driven down toward the sole; sometimes it is the third, and rarely the second toe which is affected.

The fatty pad on the ball of the foot atrophies and a callosity may form under the offending metatarsal head. The real cause of the pain is nipping the nerve under the depressed bone and not between the heads of the bones as described by Morton.

The condition may occur spasmodically, the patient suffering severe stabbing pain through the metatarsal joint. This may occur in the street without any warning. The manipulations employed by patients to get relief are instructive. With all, the first great desire is to get the boot off; then some grasp the foot firmly and replace the transverse arch in proper position, others rub the foot and move the toes freely, apparently with a similar object.

One of the writers himself had a similar condition 12 months ago, which came on suddenly in the street, and recurred daily after walking about a quarter of a mile. On the second day he suspected the condition and on the third day fitted a bar in the sole of his boot with immediate and permanent relief, and the condition has not recurred.

In other cases the pain becomes more permanent, atrophic changes take place in the toe, the nail may atrophy. In some cases there is considerable œdema of the foot during an attack.

In some severe cases the patient is entirely crippled and cannot bear to put the foot on the ground. Patients may even suffer so much that they ask for amputation of the foot. The characteristic feature in all is the acute tenderness of one or more metatarso-phalangeal joints.

Sometimes two or three joints are tender but one will be found to be more acutely tender than the others.

The fact that some patients grip the foot near the *bases* of the metatarsals to get relief indicates one point of treatment, namely, to bind the foot with a strip of sticking plaster at this point, after seeing that the offending head is back in its proper place in the arch.

A bar in the sole behind the metatarso-phalangeal joints relieves the tender joint of all undue pressure, and in milder cases is curative. In cases of long duration and in those in which there are trophic changes in the skin and nail of the toe, these measures are not efficient. In such cases removal of the head of the metatarsal through a small incision on the dorsum of the foot gives complete relief in every case. After two weeks of rest in order to allow the operation wound to heal completely, the patient may walk with a bar behind the metatarsals and a low heel. This condition is more common among women than men; this is what might be expected from the fashion of high heels and pointed toed shoes, which throw a very heavy strain on the transverse arch of the foot.

PARALYTIC DEFORMITIES OF THE LOWER LIMB

Deformities Due to Spinal Paralysis of Infants (*Poliomyelitis Anterior Acuta*).—The attitude of mind of physicians and surgeons toward infantile paralysis and its consequences has in the past been most unduly pessimistic. The general view of neurologists is that in a large number of cases, fortunately, a great measure of spontaneous recovery takes place in the first few weeks of recovery from the acute attack; that in the following six or eight months some further recovery may be looked for under treatment with massage and electric stimulation; but after this little more can be done and the patient must rest content that no further recovery of muscle power is to be expected.

With the latter part of this view the orthopedic surgeon must entirely disagree. It is fortunately true that a large measure of spontaneous recovery takes place in most cases, and that in the first few months further rapid recovery may take place, but it is by no means true that further recovery is not to be expected, nor is it true that the case will not get worse, for it is after these stages that, owing to erroneous deviations of body weight and to unopposed muscular action, the worst mechanical deformities occur.

To appreciate the factors which take part in the production of a

paralytic deformity, we must consider the whole mechanical and physiological problem and not merely one isolated part. We have, therefore, to think (1) of the spinal nerve and the effect of the bacteria and their toxins which cause the disease, (2) of the secondary effects on the muscles supplied by the diseased nerve cells, (3) of the consequent aberrations of the different impulses from muscles and disturbances of the nerve muscle reflex cycle, (4) of the resulting disturbances of the balance of muscular power in the limb. (5) Having worked all these out we are left with all the ordinary mechanical causes of deviation of body weight, shortening of some structures and lengthening of others, which we have already found operative in the production of deformities not due to paralysis.

In short, the orthopedic surgeon looks on a paralyticde formity as in every way similar to the other deformities he is called on to treat, with the single additional factor of an impaired or damaged nerve supply, for which due allowance must be made, but which must be accepted merely as an annoying incident and must be cheerfully met. The neurologist from his different mental standpoint has in the past been too apt to look on the damage of a nerve cell as a grand calamity for which there is no redress, and from which there is no means of escape.

Commencing at the beginning, therefore, we find that in acute poliomyelitis the motor cells in the anterior horn of the gray matter of the spinal cord are impaired by the activities of the organism producing the disease or by the poisonous qualities of its toxins. In some cases the destruction of the motor cells is total and we have then to face the fact that certain muscles or groups of muscles are totally paralyzed, and deal with the mechanical problem thus presented. In many cases clinical experience shows that recovery from the motor paralysis is complete even in cases in which for a few days immediately after the acute onset there has been total loss of power in one or more limbs. Between these two extremes every gradation is found, and it is in these intermediate cases that the widest field is to be found for the exercise of patience and ingenuity by the orthopedic surgeon.

The important fact which must receive recognition is that a muscle that is "paralyzed" so far as performing its function is concerned, can be put entirely out of use simply by overstretching, even though there is no lesion of its nerve of supply or nerve cell. Of this an illustrative example can be most easily found in dropped wrist. We have seen cases of "drunkard's palsy" in which there could have been no pressure on the musculo-spiral nerve, the "paralysis" being entirely due to the patient

sleeping with his hand under him twisted into full flexion, the effect being to disable the extensors of the wrist by overstretching. The same effect has been produced experimentally by bandaging a wrist for 12 or 24 hours in extreme flexion. One of the writers some years ago was consulted about a case of "paralysis" of the extensors of the wrist, with the following history. The patient accidentally divided the flexor tendons of the wrist; his doctor carefully sutured all the tendons and bandaged the hand and wrist in flexion to make sure of good union. When the wound was healed both were surprised to find the patient incapable of active extension of the fingers or wrist. The treatment was simply to put the hand and wrist on a split in dorsiflexion till the overstretched muscles had taken in their slack, or to put it in technical language, had undergone adaptive shortening. When this shortening occurs contractile power returns spontaneously.

In dealing with congenital club-foot we have already pointed out that cure is not complete till the over-stretched muscles have recovered power. The doctrine that an over-stretched muscle is functionally inefficient or even "paralyzed" seems to us to be an essential fact in the creed of the orthopedic surgeon and one not yet generally acted on.

The next step is to consider what happens in dropped wrist due to pressure on the musculo-spiral nerve, the "drunkard's palsy" of the textbook. In this case efferent motor impulses are blocked by pressure on the nerve, and the extensors of the wrist consequently are in a state of flaccid paralysis. The flexors remain unimpaired, and the united action of gravity and the flexor muscles keep the extensors in the overstretched position.

These muscles then lose their function and, unless the hand and wrist are put in the dorsiflexed position, will remain powerless after the condition of nerve block has passed off. These patients usually are alarmed by the sudden palsy and seek advice before these changes have time to advance far, and the nerve block is usually only transitory.

The next stage is represented by the dropped wrist of lead poisoning; here the lesion sometimes affects the nerve trunks, but often affects the nerve cells. The active agent is a metallic poison which puts the nerve cell out of action for a time, which may be considerable; during this period the muscle is deprived of its motor stimuli, becomes overstretched, the normal reflex cycle is cut, and so it is for the time deprived of "trophic" influences. When the effect of the lead poisoning passes off from the nerve cell the muscle remains at fault, for it is not in proper tone to respond to such feeble impulses as the recovering nerve cell

first sends down to it; there being no muscle response, there are no afferent impulses from the muscle. The nerve muscle cycle is still out of order, but it is no longer the nerve cell which is at fault; the cycle is cut at the muscle. Some years ago one of us had an interesting case proving the truth of this statement. The patient, a painter aged 55, came to the out-patient department suffering from some minor injury. It was noticed that he had a double dropped-wrist, and could not even button his coat, though he could move the fingers a little. This condition had lasted five years. During the original acute stage of lead poisoning he had been treated in one of the large London hospitals, and afterward attended for a year for massage and electric treatment, apparently without much benefit. On inquiry it was found that he never had his hands put on a splint in dorsiflexion. He was persuaded to try the effect of a cock-up splint on one hand—the worse of the two. After a few weeks he had recovered so much power that a former employer gave him work. He asked permission to take the splint away with him so that he might treat the other hand in the same way, as his work would take him to another town.

The moral of this case is that all the massage and electrical treatment was thrown away, because the extensors of the wrist were hopelessly over-stretched and were in a position of such mechanical disadvantage that they could not respond to any stimulus. If they had been placed in relaxation in the first instance, they would have undergone adaptive shortening and rapidly have recovered their function; electricity and massage would have hastened this process, but if the nerve cell is not dead, spontaneous recovery is sure when the muscle is given an opportunity of shortening, but not while it is over-stretched and therefore mechanically ineffective. From the nerve cell which is temporarily poisoned by lead to that which is temporarily poisoned by bacterial toxins is not a great step. The difference really lies in the essential virulence of the poison and in the time it takes for the nerve cell to recover, if it is not totally destroyed by the poison in the first instance.

The orthopedic surgeon seldom sees cases of poliomyelitis during the acute stage; this properly falls in the domain of the physician and the neurologist. Our plea is that as soon as immediate danger to life is past, the physician should pay more attention to orthopedic considerations, for, as will be shown below, much of the resulting paralysis is due to over-stretching of muscles by gravity; for example, many cases of paralytic talipes equinus are due to over-stretching of the extensors of the toes and flexors of the ankle by pressure of bedclothes, and not

due to complete paralysis of motor cells supplying the anterior tibial nerve.

The orthopedic surgeon, therefore, regards the whole nerve muscle apparatus as one piece of machinery, whose working may be put out of gear by defect in any one part, either the spinal nerve cell, the nerve trunk or the muscle; then there is the afferent path from muscle to spinal cord, direct impairment of which does not concern us in the present discussion. The part of this cycle commonly neglected by the neurologist is the state of the muscle. Further, clinical experience has proved that the ordinary clinical electrical tests are not sufficiently exact to determine whether the loss of function of the muscle is due to true paralysis from destruction of the nerve cell or to pseudo-paralysis of the muscle itself.

A slight digression is permissible here to refer to the question of degeneration of tissues from disuse. In all instances in which we can get direct evidence of the changes there seems to be a physiological law that a disused tissue undergoes disuse atrophy. Thus if a limb be long fixed in a plaster splint, the bone loses some of its lime salts, throws less shadow in an X-ray, and the radiogram itself shows characteristic changes of desuetude. Muscle fibers waste and become replaced to a large extent by lower forms of connective tissue, which is or looks like fibrous tissue. With training, the muscle fibers left can again recover and undergo hypertrophy, just as the normal muscles of a blacksmith's arm undergo hypertrophy from constant use.

We know from experiment that if the muscles of the thenar eminence of a monkey's thumb are removed, the corresponding motor cells undergo changes known as chromatolysis, which can be seen under the microscope. Of changes of disuse in nerve fibers we have no direct evidence, but we do know that the processes of degeneration and regeneration in divided nerve fibers are associated with peculiar changes in the neurilemma cells, and that the whole process is much more elaborate than it was thought to be. It is possible, therefore, that even the nerve fibers may deteriorate from disuse and not perform their function with normal efficiency.

It follows that we are not justified in considering the state of the spinal nerve cell as the only factor of moment, or indeed as the most important factor in those cases of infantile paralysis which subsequently consult the orthopedic surgeon.

The analysis of the case should be made on the following lines:

1. The deformity which is seen is due to faulty lines of carriage of

body weight, perhaps in the first instance to pressure of bedclothes. It is maintained by shortening of muscles and ligaments on the one hand and over-stretching and weakening of muscles and ligaments on the other. In short, there are present all the elements of deformity which have already been discussed, for example in congenital club-foot. In addition to these there is a complicating factor, namely, uncertainty whether the motor cells of the over-stretched and apparently paralyzed muscle are capable of performing their function.

2. The state of the motor cells cannot be definitely determined while the muscles they supply are over-stretched. It is, therefore, first of all necessary to correct all existing deformity, place the limb in the fully corrected or in the over-corrected position to allow stretched muscles to shorten.

3. Recovery of the apparatus of the nerve muscle cycle takes time. For example, a youth of 18 years of age suffering from dropped wrist, who was paralyzed in infancy, had his hand and wrist kept continuously in the position of dorsiflexion for 15 months before the first flicker of movement could be detected in his extensor muscles. From this beginning his muscles were carefully trained and a useful hand resulted. In another instructive case it was only after two years' continuous flexion of the elbow that the first flicker of voluntary movement could be seen in the biceps muscle. We have seen several cases in which arthrodesis of the knee-joint has been too hastily performed, because subsequently owing to the continuous rest the quadriceps extensor recovered its contractile power, but by that time the joint was stiff forever, and the case was hopelessly spoiled so far as getting functional use of the knee-joint was concerned.

The lesson to be learned from such cases is that the surgeon should be in no haste to perform any operation of an irrevocable nature, but after putting the limb in the best position for recovery, should wait patiently for results before going farther. In the case of the lower limb, it is always possible to fit the child with some appliance in which he can walk after the deformity has been corrected.

4. Transplantation of tendons is the next procedure to be considered. Experience has proved that it is best not to perform any tendon transplantations in very young children, but to wait till every possible recovery of function has been obtained by corrective posture, by massage, and by careful muscle drill. We shall deal below with the forms of tendon transplantation which have been found most useful. Certain general rules may be laid down now. It is no use transplanting

a muscle unless it is a strong one. A muscle should never be transplanted with the idea that it will correct deformity; this will only lead to failure, for the muscle is almost sure to become over-stretched. All deformity should first be corrected, and tendon transplantation may then be used to equalize the balance between opposing groups of muscles. No transplantation should be performed without considering first whether the muscle can be spared from its original position.

5. Arthrodesis is an operation to produce ankylosis of a joint. This ankylosis may be either bony or fibrous. It is often useful, especially at the ankle and tarsus and sometimes at the shoulder, but is rarely useful in any other part of the body. It should never be performed in haste in a child, but should be reserved as a last resort after it is quite clear that recovery of muscle power, fortified perhaps by a judicious transplantation of muscle, will not furnish a useful limb. These considerations apply equally to children, adolescents and adults. In children there is the further consideration that an injudicious early operation in bone may interfere with subsequent growth and so give rise to difficult and intractable bony deformities.

After these preliminary remarks on principles of treatment, we pass to consider the technique and detail of the various measures in order.

Treatment of the Case at the Onset.—Spinal paralysis of infants may follow any of the acute fevers, scarlet fever, measles, diphtheria, but in its severer forms it usually depends on a distinct infection or group of infections whose bacteriology and etiology are still under investigation. There seems to be evidence that acute anterior poliomyelitis may be transmitted by contact from patient to patient, that it can be carried by monkeys, and most recently it has been suggested that it is a fly-borne disease. These, however, are not subjects for discussion in this place. The acute onset is often marked by high fever, convulsions, delirium, headache, pain in the back and limbs and great hyperæsthesia, so that the patient cannot endure being touched. In other cases the onset takes the form of an obscure fever and the practitioner makes a temporary diagnosis of influenza or perhaps rheumatic fever. After a few hours paralysis appears, affecting part or all of the body. At this stage the spinal column should be kept fixed by putting the patient on a Thomas' frame or other suitable splint to minimize the irritation of the spinal cord.

As soon as the diagnosis of paralysis is made, the orthopedic problem must be faced, and as soon as it appears that the acute disease is not to be immediately fatal the practitioner knows that more or less spon-

taneous recovery is to be expected, and it is his duty to take immediate orthopedic measures to ensure that the recovery of muscle power shall be as complete as possible, and that there shall be no residual paralysis due to over-stretching and mechanical disadvantage. The decubitus of the child must be studied, for in this way a clue to the cause of the common forms of residual paralysis may be found. Though this article does not treat of deformities of the upper limb, some reference must be made to it. When a paralyzed child is lying helpless and flaccid in bed the mother or nurse usually lays the upper limbs in one of two positions: (1) with the arms straight down by the child's sides; this position continuously stretches the biceps and brachialis anticus, but the wrist, being in mid-position between flexion and dorsiflexion, escapes distortion, hence the frequency with which we see flail elbow of the pseudo-paralytic type with a fairly useful hand and fingers. (2) The elbows are flexed and the hands crossed on the chest, usually with the wrists flexed, resulting in contracture of the biceps and brachialis anticus, and a hand disabled by a pseudo-paralytic dropped wrist.

In both, the deltoid muscle is liable to be over-stretched. Having chosen the position in which she is to nurse the child, the mother is very apt to keep always to one position. This must be carefully avoided. Care must be taken that no joint in the upper limb is left always or too long in one extreme position. At the elbow flexion is essential, for when the child gets up again gravity will help to correct any deformity.

In the lower limb the position usually adopted is slight flexion and adduction of the hip, hence the frequency of some flexion deformity, and of remaining effective power in the adductor muscles.

At the knees flexion with contracture of the hamstrings is common in cases where the true paralysis is not complete.

In the foot and ankle the pressure of the bedclothes is largely responsible for pointed foot or equinus deformity with over-stretching of the anterior group of muscles. Residual paralysis of the invertors or evertors of the foot depends first on the position into which the bedclothes are allowed to press the foot, and second on erroneous weight-bearing when the child gets up.

The writers do not wish to suggest that the toxins of the disease may not freakishly attack certain areas of the spinal cord more severely than others, but they do wish to emphasize the fact that clinical experience and the results of appropriate treatment have shown that many of the common types of paralysis of definite groups are not a true

nerve cell paralysis, but a residual paralysis due to over-stretching. The child should, therefore, be nursed on a hard flat mattress or better still in a double Thomas' frame to prevent flexion and lateral deviation of the spine. The positions of the arms and hands should be studied and carefully varied from time to time.

The lower limb should be placed in rest positions, thigh in line with the body, the knee on a back splint with a comfortable pad behind the knee to avoid the risk of going to the other extreme and producing a genu recurvatum. The foot should be put in some sort of right-angled shoe of the club-foot shoe type, and the whole limb should be rotated neither to the inner nor to the outer side. As soon as return of voluntary muscle twitches indicate that the nerve muscle cycle is beginning to work, the power of every muscle should be carefully cultivated, first by encouraging voluntary twitching and second by massage. We put these two in this order for reasons which will be explained below, when we discuss the difference between judicious and injudicious massage. The writers have abandoned electrical stimulation as a routine treatment, because the evidence that it did much real good was very slight, and because it can often be misused and is then only a trap for the unwary.

As has been already stated the orthopedic surgeon is seldom consulted in this early stage of the disease, but only after the paralysis has existed for some months. We therefore pass to a detailed consideration of the conditions he may have to treat.

In the lower limb the deformities are no longer those primary errors due to faulty decubitis in bed, but have been secondarily modified by erroneous lines of carriage of body weight. The longer the period that has elapsed since the onset the more time has there been for firm and stubborn contractures to have formed and even for changes of shape to have occurred in bone. These, however, present no special difficulties different from those found in any ordinary case of neglected congenital club-foot.

As we know that mere deformity can always be corrected, and generally by measures that are not severe, it is our practice first to form a general estimate of the muscular condition of the limb in the following way:

First by Inspection.—1. A blue, cold, puffy looking limb, with all muscles flaccid, and no contractures in any group of muscles is very unpromising, for it points to complete destruction of motor cells in a wide area of the spinal cord, with serious interference with the trophic

as well as the motor function of the spinal nerve cells. In such a case of total paralysis without any actual mechanical deformity, it is best to fit the child with a walking caliper and teach it to walk, as if in an artificial limb and order light superficial massage to improve the circulation. The mere act of partial functional use of the limb in this way sometimes produces a great improvement in general nutrition. A second examination at the end of six months may show some indication of recovery of muscle power and this must then be utilized to the full.

2. A limb in which only the foot and part of the leg looks blue and cold is a much more hopeful case and should be dealt with more as if it fell into the following class.

3. Although wasted and rather cold to the touch the skin is not blue and glazed in appearance, except perhaps in wintry weather. This general appearance indicates that the trophic functions of the spinal cells are fairly well maintained, and some confidence may be felt that there are possibilities of great improvement in motor function.

(*a*) First ask the child to raise the limb off the bed. If he cannot, place a hand under the limb, raising it off the bed, and note if the child's effort makes any difference to the weight of the limb. Ask the child to try to move the limb outward and inward. Note carefully if any twitching can be seen in the muscles round the hip. If there are any evidences whatever of muscular action, the child can be made to walk well, in splints at least, however complete the paralysis below the knee may be. If there is no power in any muscle moving the hip, then though the child can be fitted with a walking caliper he can get along only by swinging his body to jerk the limb forward, and this is always conspicuous and ugly, but infinitely preferable to crutches, for it leaves the hands free.

(*b*) Examine the quadriceps muscle. If the child can lift the leg without first rotating the thigh outward and using his adductors, the quadriceps is of course acting. In cases where this cannot be done the surgeon lays a finger on the upper edge of the patella, makes the child concentrate all his attention on his patella and then asks him to pull it up against his finger; if the slightest twitch can be felt or seen in the quadriceps muscle then the muscle is certainly not totally paralyzed and can be cultivated. Similarly place fingers on the hamstrings and feel if the patient can tighten them.

Next examine every muscle of the foot. Any faint ripple of movement in the belly of a muscle or the faintest twitch of movement in a

toe is proof positive that the paralysis is not complete and a cheerful prognosis may be given.

The absence of these signs is no proof that the muscle is not capable of recovery, but their presence is very important positive evidence.

Having formed a judgment on the probabilities of muscular recovery, the first actual treatment is to correct physical deformities.

In the foot and ankle, deformities occur chiefly at the mid-tarsal and ankle-joints, though of course all the joints in the tarsus participate. The deformity may consist of combinations of four types, calcaneus, equinus, valgus and varus. The surgeon must at once exclude paralytic talipes calcaneo-cavus, the treatment of which is fully considered below. This condition differs from the others in the fact that the calf muscles are over-stretched and it should never be mistaken for a talipes equinus, a mistake often made and the cause of much hasty and erroneous treatment. It has already been suggested that the pressure of the bed-clothes may determine a dropped foot or paralytic talipes equinus; in such cases the calf muscles will be short and the heel drawn up. With this equinus deformity there may be a valgus or varus, often determined to a large extent by erroneous lines of weight-bearing and an unequal balance of power between inverters and everters. Similarly contracture of the plantar structures determines a flexion of the mid-tarsal joint similar to that found in claw-foot. The correction of these deformities is done exactly on the lines of the correction of a congenital club-foot or a claw-foot with the wrench or the tenotomy knife, special care being taken not to divide the tendo Achillis till every resisting structure in the foot has been fully stretched or divided. In addition it is often necessary in cases of obstinate valgus to divide the middle slip of the external lateral ligament of the ankle-joint, which is frequently very short and strong if the child has walked for some time on the inside of the foot. There are similar cases of varus where part of the deltoid ligament requires subcutaneous division. When all contractions are fully overcome the foot should be put up at right angles to the leg with some over-correction of the previous deformity. If there were previously strong contractions it is as well to put the foot up in plaster of Paris, for some time. As in the treatment of congenital club-foot, recovery really depends on shortening of previously over-stretched structures and on recovery of muscle power in over-stretched muscles. In this case we must be prepared to wait a long time for the latter part, for there is or has been a definite impairment of the nervous apparatus.

In cases where strong contractions were not present, a splint of the

club-foot shoe type may be used so as to permit of some massage **without removing the splint,** for if it is important *never for an instant to allow shortening structures to be stretched* in an ordinary case of congenital club-foot, it is ten times more important in those cases where there is a definite nerve impairment to be considered.

At the knee the deformity which has most commonly to be overcome is flexion. The resistance to extension is due to two elements, shortening of the hamstring muscles and shortening of the ligamentous structures at the back of the knee-joint. It is always possible to straighten the knee gradually by stretching the hamstrings without dividing them. If there is any possibility that these muscles may be required later for transplantation into the patella, it is not advisable to divide them subcutaneously.

The method of straightening a flexed knee which has been found most effective is in a Thomas' knee splint, with extensions as in the figure shown in the section on knock-knee.

The knee is then firmly bandaged back to this splint. The nurse has orders to tighten this bandage as often as it gets the least slack. The theory of this method of attack is that by putting on a firm bandage in the straightest possible position, the knee cannot for an instant get more flexed and in fact tight structures relax a little. By keeping the bandage tight, advantage is taken of every such relaxation and so the joint is gradually straightened. The sisters in our cripple hospitals count that if the limb is straight enough to be put on to a Thomas' splint it should be straight in about three weeks. A knee flexed 30 to 40 deg. from the straight position can be put on a Thomas' splint with, in addition, a back splint. It is to be noted that this method of straightening the knee is a method of persuasion, not of force. If the nurse tries to hurry the case she is almost sure to cause pain and probably pressure sores. By making flexion impossible the knee has only the option of staying fixed or extending and it invariably takes the latter course.

The treatment of limbs too much flexed to be put on a posterior splint or Thomas' knee splint requires some care. In these cases extension by suspension will usually get the limb straight enough for a posterior splint to be put on. The point to be remembered is that for the last 30 deg. of extension a Thomas' splint can always be used, and it will succeed when any form extension will fail. Extension by weight and pulley is not efficient.

At the hip flexion deformity with lordosis is the most frequent con-

traction deformity. In severe cases it is necessary to divide the tensor fasciæ femoris about 3 in. below the anterior-superior spine of the ilium, and also any other tense structure in the neighborhood. It has been found more satisfactory to do this through an open incision rather than subcutaneously.

The patient is then put on a splint of the Thomas' frame type when, under gravity, the lordosis will gradually disappear just as in a case of tuberculous disease of the hip.

In a case, therefore, with flexion at hip and knee and contraction of the tendo Achillis, the patient requires division of the tensor fasciæ femoris, division of the tendo Achillis, and is then put on a double Thomas' frame with the knees firmly bandaged down, and right-angled shoes on the feet. If the flexion of the knees is great it must be so far overcome by preliminary treatment as to make it possible to put on a posterior splint, before attempting to put the patient on a Thomas' frame. As knock-knee deformity is common in these cases, the Thomas' frame is made with an outside bar from the "thigh wing" to the "ankle wing," and the knock-knee can be corrected at the same time by bandaging to this outside bar.

With regard to subcutaneous division of the tendo Achillis, the danger of non-union, of which some authors warn us, is not serious. We know of only three cases of non-union out of many thousands. One point, however, must be observed, a pressure pad must not be put on to the puncture as this presses in between the ends of the divided tendon and prevents the formation of repair tissue in the gap.

With regard to straightening the knee under an anæsthetic, it is common knowledge that this is much more difficult in cases of paralysis than in cases with adhesions after an inflammatory process; as has been already stated, peaceful persuasion is more effective than force in these cases.

Having corrected all fixed deformities and placed the patient on a splint with all the muscles relaxed which were previously paralyzed and over-stretched, the next stage is to wait for adaptive shortening, and for recovery of function. Massage properly controlled is a great help at this stage; careless massage may absolutely prevent recovery.

I. **Massage.**—At the outset a clear distinction must be made between massage and movement. After what has been said it should be clear that any movement, whether intentional or inadvertent, which might stretch a weak muscle will militate against recovery of muscle power, and must therefore be absolutely forbidden.

The Movement.—In the initial stages, therefore, we put absolute fixation before massage and allow massage only in those cases in which it can be performed without removing splints. Later when permission is given for splints to be removed no stretching of shortening structures is allowed. The children themselves know this, and it is amusing to see a child catch hold of his own toes to prevent foot drop the moment the last turn of bandage is removed. Such loyalty on the part of a young patient is easily obtained if every nurse or masseuse who comes near the child is herself absolutely loyal, but not otherwise.

The character of the massage is determined by the state of the muscles. In the initial stages of treatment when the muscles are over-stretched and are incapable of action it is not merely useless but actually harmful to attempt to massage the muscles themselves. To realize the ease with which the fibers of a deteriorated muscle may be damaged by very moderate muscle kneading it is only necessary to think of the extremely attenuated condition of the muscle fibers in a degenerated muscle and to think of the ease with which a strong adductor muscle can be ruptured by pressure with the thumb, for example in treating a case of congenital dislocation of the hip.

No kneading or even vibration of muscles should be allowed. Massage at first should consist of the lightest effleurage of the skin, with a very fine vibratory movement. This should amount to little more than tickling the skin and the down growing on it. The effect of such massage seems to be chiefly a reflex improvement in the circulation and nutrition of the limb. While this massage may with benefit be applied all over the limb, so far as the splints will permit, special attention should be paid to those skin areas which receive their sensory supply from the same spinal segments as furnish the motor impulses to the defective muscles. Some practitioners advocate vibratory massage over the spinal column itself; without venturing to criticize this practice in any way, we merely repeat our belief that the whole nerve muscle cycle is working in a defective manner, and we believe that by tickling the corresponding skin areas we are doing something definite to rouse the reflex activities of the dormant or sluggish areas of the spinal cord.

II. **Muscle culture** is a term which may be applied to the second stage of treatment. With complete relaxation of muscles, even if the first stage of massage is omitted, sooner or later signs of recovering muscle power will appear if the nerve cells are only in abeyance and not actually dead. From this time onward the treatment must consist of cultivating the remaining muscle, so as to make the most of it.

The first point in this process is to direct the child's attention to the visible movement of a toe, and ask him to do it again. At first he will not easily dissociate flexion from extension; for example in a case of dropped foot the child may be seen to extend a toe, yet when asked to do it again he will use the flexor. With careful daily drill he learns voluntarily to dissociate the two movements and perform either at will. In the case of the quadriceps muscle as soon as the child can twitch the patella his attention is drawn to it, and he is made to practice the movement; as the muscle gets stronger the masseuse lays a finger on the upper edge of the patella and resists the movement, carefully graduating the resistance to the power of the muscle.

During this stage muscle massage in the form of deep stroking movements, deeper and firmer vibrations over the belly of the muscle and finally pinching and kneading may be permitted, with this warning that if the muscle power on any day seems to be less than on the previous day the explanation is most likely to be rough massage, that is, that the manipulation of the previous day has been rough enough to bruise or damage some of the fragile muscle fibers, and Nature's demand is complete rest till the damage is repaired. When a masseuse learns to recognize this condition, and immediately to modify her methods she may be said to be becoming expert at paralytic work; if she cannot learn to recognize it she is better employed elsewhere.

III. **Active movement of joints** is the next stage. For example, in cultivating the anterior group of muscles in the leg there comes a stage when the child can not only extend the toes but can dorsiflex the ankle. When this power has been cultivated a little the child may be allowed to walk with proper support. The child must either have a very well-fitting boot, or a thin celluloid anklet which is worn day and night, inside the boot, or an area of skin may be excised (v. infra) to act as a splint.

At the knee a Thomas' walking caliper will in any case keep the knee straight, and the child may walk in this splint as soon as the foot is strong enough or can be supported with an anklet so as to carry body weight without being twisted into some erroneous position.

Removal of oval areas of skin over the dorsum of the ankle is an operation we often perform to guard against carelessness on the part of the nurse or mother. When a dropped foot is flexed at the ankle there is, over the dorsum or front of the ankle-joint, a fold of loose skin, which can be picked up in the fingers. The operation consists in re-

moving an oval patch of skin corresponding to this loose fold, and suturing the wound in a transverse line across the front of the joint. When the wound is healed in 10 days or so, the right-angled foot splint may be removed without the foot immediately dropping as the skin is strong enough to support the weight of the foot. If there is a little valgus deformity to be corrected, the oval is placed a little to the inner side of the front of the ankle, and to the outer side in the case of varus.

This is not a corrective operation; it in no way obviates the necessity for wearing a right-angled splint; it only guards against the disloyalty or carelessness of mother or nurse when washing the child, and in this way often is of material help in securing recovery of muscle power in cases which would otherwise have been failures merely from carelessness.



Fig. 408.—Knee cage.

When the child is allowed to walk in a walking caliper, the same care must be observed not to allow any undue strain on the weak muscles. As walking can be permitted long before the quadriceps has recovered, special attention must be given to continuing the training of this muscle. A time may come when the quadriceps is short enough and strong enough to keep the leg straight for a few seconds. The next stage is to let the masseuse put her hand under the knee, flexing it not more than 5 deg. If the child can extend the leg through this angle, another stage is reached. This movement should be practised till it can be strongly performed before allowing any further increase of movement.

In those cases in which good recovery of the quadriceps has been obtained, a knee cage with a joint may be allowed after a time in place of the caliper (Fig. 408). The joint should have a stop limiting the movement to 10 deg., 15 deg., or 20 deg. of flexion and so the range is gradually increased, till either full movement is regained, or a limit is reached beyond which the weak muscle is incapable of acting efficiently. This is shown by the muscle again showing signs of paralysis from overstretching, and is at once met by reducing the range of movement.

At the hip, exercises consist of flexion, extension, abduction and adduction, all to word of command.

In many cases the adductor muscles have escaped paralysis; consequently when the child, lying in bed, is asked to raise the limb he

first rotates the limb outward and uses the adductors as flexors of the hip in this position. Similarly when he walks even if he has some power in his iliopsoas, it is easier for him to rotate the limb outward and use his adductors to put the limb forward. This bad habit must be most persistently checked and the gymnast must in addition to massage give the child careful marching drill; this is commenced as soon as the child is allowed up in calipers.

Crutches should never be allowed; they are a positive hindrance to recovery, for the child swings both legs together in order to get about quickly, and so fails to exercise the individual muscles properly. A recent case illustrates this point. A boy of nine, paralyzed in infancy, was admitted to a cripple hospital with infantile paralysis affecting both lower limbs, also some paralytic scoliosis. He could not move his toes, the knees and hips were flexed. At the time of admission he was using crutches. After about six weeks on a Thomas frame, he could move toes and ankles and all flexion deformities were corrected. He then got up in walking calipers with a light spinal support to steady his back, which was now nearly straight. He was then drilled in walking. The interesting fact is that in the first four months his walking calipers had to be lengthened 3 in., showing how growth had taken place in response to proper physiological exercise.

This is only one more case proving the great importance of properly directed exercise to prevent and correct defective growth from disuse or misuse of a limb (Figs. 409 and 410).

Operative Treatment.—The operative measures previously mentioned were merely directed to correcting fixed deformities and clearing the ground of obstructions to recovery of muscle power and of useful function of the limb. We now pass to a consideration of those operative measures which may have to be undertaken at a later stage after careful preliminary treatment of muscles has proved that some groups of muscles are incapable of recovery, or of sufficient recovery to balance the action of their opponents.

These operations fall into four groups, of which the first two are well established and the last two are still on their trial. They are:

1. Tendon transplantations.
2. Arthrodesis.
3. Grafting of artificial ligaments.
4. Nerve grafting.

Of tendon transplantation and arthrodesis we have had more than 12 years' experience, and having passed through the initial stages of

FIG. 409.—Twins. Infantile paralysis at the age of two and a half years. Came under treatment at age of nine. Both had torticollis for which the sterno-mastoid was divided. Could just balance but could not walk before treatment.

FIG. 410.—Twins: Two years later. Now learning to walk without apparatus. Treatment, muscle training and splinting only.

only partial success, have learned from former failures some of the factors which are essential to success. The last two operative procedures will be discussed afterward.

Tendon transplantation is an operation performed with the intention of correcting erroneous balance of muscular power.

It therefore follows that a properly considered and judicious tendon transplantation can be planned and carried out only after every effort has been made to induce recovery of power in apparently paralyzed muscles. Hasty operation, as has been seen in earlier days, may be followed by recovery in the muscles supposed to be paralyzed and it is then necessary to operate again to put the transplanted muscle back in its original position.

Tendon Transplantation.—Successful results from the operation of tendon transplantation may be confidently expected if the surgeon is reasonable in his choice of cases and pays attention to the following points of technique.

1. The choice of the muscle to be transplanted. The surgeon must satisfactorily convince himself by actual observation that the muscle he intends to transplant is capable of strong voluntary contraction. There is no necessity for cutting into the muscle to observe the color of its fibers; actual strong movement is the only test. It is unreasonable to expect a muscle, which is capable only of very feeble voluntary action when in its normal position, to act more efficiently when transplanted to a new and abnormal position.

2. The new line of the muscle from its origin to its new insertion must be a fair line, the muscle must not have an angle in its course nor may it be bent round a bone nor passed through a strong membrane such as an interosseous membrane. The kink in its course will either paralyze the muscle by pressure or adhesions will form, interrupting the action of the muscle.

3. The muscle must not be twisted on its long axis, and the tendon should if possible pass through a layer of atty tissue in which a false tendon sheath is made. It is sometimes possible to pass the tendon down in the sheath or compartment belonging to the muscle which is to be reinforced. When this is practicable without producing a kink, it is a good thing to do.

4. Adhesions between the body of the muscle or the tendon and surrounding tissues must be avoided, as they impair or even annul its effective action. It must, therefore, be an absolute rule that the muscle

or tendon must not be touched in any way except at the very end where it is to be implanted into bone.

5. Implantation into bone is a great aid to success. (*a*) Whenever it is possible to get a long enough tendon, a tunnel should be bored right through the bone and the tendon pulled through and fixed on the far side, or even brought round the bone and the end of the tendon fixed to the tendon itself near the point of entry into bone. (*b*) When this is not possible, drive a strong-bladed knife through the periosteum, lifting a flake of bone with it. This makes a tunnel with a thin bony roof. A trench is then dug in the bone to receive the end of the tendon, which is fastened to the periosteum at the point of entry with stout 20-day catgut passed by means of a strong periosteum needle. Sometimes it is necessary to use a chisel and turn up a flap of bone and periosteum.

It is rarely necessary to peg down the end of the tendon with a tack or pin. This should be avoided, if possible, and never performed on the very young, but sometimes it is very difficult to get a trustworthy hold of the periosteum with a stitch. A pin is a foreign body, which, even if absolutely aseptic may give rise to some irritation or effusion; the fluid round the foreign body opens up the tissues and militates against a firm union. Further, a muscle whose insertion is the seat of an irritation will not act properly. This is a fact of common knowledge in connection with ordinary injuries and bruises about insertions of tendons and should not need further mention.

For the same reasons silk is to be avoided; we shall return to the discussion of silk as a foreign body when criticizing artificial ligaments.

6. As far as possible no skin wound should be made over the new course of the muscle as undesirable adhesions may form and hamper its action.

7. Never do any deep cutting or dissection with the knife used for the skin incision; remember that the skin nearly always contains some staphylococcus albus and that a tendon is not a vascular structure and therefore even a mild infection may cause enough tissue necrosis to prevent union of the graft. After-treatment is just as important as the actual operative technique.

8. Strain on the muscle must be avoided, first to avoid pulling the grafted tendon away from the bone, and second to avoid over-stretching the muscle which is handicapped by being in a new position, and is called on to do unaccustomed work. The limb should, therefore, be fixed in a splint till the graft is well united.

9. Muscle training in the new position is just as important. Some years ago at the Congress of Surgeons in Paris attention was drawn to the fact that although a transplanted muscle often acted well in its new position for a time, this was generally followed by a complete cessation of function. This has been observed by all surgeons, but all do not recognize that this loss of function is simply due to over-stretching; the proof of this statement is that the function invariably returns again if the muscle is kept in relaxation for a time. The lesson is that we must not expect the muscle to perform its new function all at once, but must exercise it gradually while the splint is still being worn until it is efficient in its new duties.

Very interesting questions have been raised as to the possibility of a flexor ever becoming really an extensor. It has been stated that a hamstring transplanted into the patella to reinforce a weak quadriceps extensor never contracts with the quadriceps, *i.e.*, never really acts as an extensor; on the other hand it is held that the benefit of the operation lies in the fact that the transplanted hamstring contracts during flexion and opposes its fellow hamstrings, and so saves the quadriceps from being overpowered.

This observation is quite correct up to a certain point. The natural tendency of a hamstring is to contract with the hamstring group during flexion; this tendency can, however, be overcome by very careful training, by drawing the child's attention to the transplanted tendon, by making him put his finger on it and then training him to use it as an extensor simultaneously with the quadriceps. In younger children this transference of association from the flexor group to the extensor group can usually be attained by careful and persistent training; in older patients it is not always attainable, and then the above explanation of the benefit of the operation holds good. There is an interesting stage in the process of education in which the muscle seems to hesitate whether it is to act with the extensor or the flexor group. This stage of hesitancy is precisely the stage when muscle education should be most carefully followed out, for it is an encouraging sign.

The Age for Operation.—It is undesirable to operate on children under five years of age, because there are technical difficulties in handling small and delicate tendons. Second, it is necessary to be sure that all possible recovery has taken place; therefore it is better to let some time elapse with the child walking in splints properly designed to encourage spontaneous recovery of muscle power. Third, in the whole

process of muscle training the intelligent cooperation of the child is necessary, hence undue haste in operating is never of benefit.

Technique of Operations.—The following operations have been found of most use. It should be noted that they are all of a limited nature and are intended to regulate unequal balance of power between opposing groups of muscles.

1. *Extensor Proprius Hallucis to the Head of the First Metatarsal.*—As already stated this is one of the routine procedures in the treatment of claw-foot. It may be employed in a similar manner in frankly paralytic conditions in which the "dropped-foot" deformity is mainly at the mid-tarsal joint and is of the same type as claw-foot. An incision is made along the side of the tendon over the dorsum of the head and neck of the first metatarsal bone. The tendon is gently cleared with a blunt dissector and divided. A double chromicized catgut suture is passed through the tendon near its end. The double end is passed through the loop, and the loop itself is turned over the end of the tendon; this hitch will not slip and no knot is required. A piece of gauze is wrapped round the tendon. Next a small incision is made through the periosteum on the neck of the metatarsal and a hole drilled right through the bone; the hole is enlarged with a burr to make it big enough for the tendon to be pulled through.

Now an incision ½ in. long is made in the sole, the edges of the skin are wiped with tincture of iodine to disinfect them, and even after this, care is taken not to let the ligature touch the skin. The ligature on the end of the tendon is threaded on a straight needle, which is driven right through and out at the wound in the sole.

The method of fixation of the end of the tendon has also been improved on. The best way if the tendon is long enough, is to separate the soft parts on the inner side of the neck of the metatarsal, with a blunt hook pull out the ligature and end of the tendon, and bring it up round the inner side, and stitch it to the tendon itself where it enters the bone. This makes a complete loop on the tendon, which is a very strong attachment.

If the tendon is not long enough for this, the end of it is stitched to the soft parts in the sole of the foot.

The skin wounds should be very carefully stitched edge to edge so as to get immediate primary union. Any secondary infection may mean sloughing of the tendon and total failure of the operation. To make doubly sure, the tendon is stitched to the periosteum at the point

of entry with a periosteum needle. The foot is put up in the fully corrected position till the graft is soundly fixed.

2. *Peroneus Longus or Brevis to the Scaphoid or to the First Cuneiform or to the Base of the First Metatarsal.*—This operation is performed to reinforce the inversion action of the tibiales anticus and posticus and is, therefore, of use when the peronei muscles are strong, and a valgus deformity is apt to recur after correction because the tibiales muscles cannot be efficiently developed.

The first question, therefore, is which peroneus muscle to use. The peroneus longus with its powerful pulley action round the cuboid right across the sole of the foot is a more powerful pronator of the foot than the peroneus brevis. If, therefore, the defect of the tibiales muscles is great, one can probably afford to subtract the stronger muscle from the peroneal group and add it to the tibial group. Similarly its efficiency in its new position is increased the further it is advanced. Therefore to get a maximum effect the peroneus longus will be taken right over to the inner side of the first cuneiform or even in some cases to the base of the first metatarsal. If the tibial defect is slight, and chiefly arises from the peronei over-powering tibial muscles which have really made a very fair recovery, it will probably suffice to transplant the peroneus brevis to the dorsum or to the inner side of the scaphoid.

The Operation.—A short incision is made on the outer side of the foot, and the tendon selected is divided, the peroneus brevis as near its insertion as possible, the peroneus longus as far inside the tunnel under the cuboid as possible. Close the wound and cover with gauze. Next make an incision about 2 in. long over the peronei muscles just above the upper part of the annular ligament of the ankle. A smooth dissector is passed under the muscle whose tendon was divided, and the muscle pulled out of its tunnel. Immediately wrap the muscle and tendon with gauze. Next make an incision over the point on the inner side selected for insertion; pass a long smooth blunt instrument from the one wound to the other and move it from side to side to open out a free tunnel down which the tendon is gently drawn, taking care not to twist it or bruise it at any point except the very end.

Implantation of the End.—If, on the inner side of the first cuneiform, a strong-bladed knife can be driven in the line of the tendon under the periosteum and the expansion of the insertion of the tibialis anticus, through this osteoperiosteal tunnel a director can be passed. With a small gouge, corresponding in size to the diameter of the tendon, make a trough in the bone under the raised periosteum. Pull the end of

the tendon through the tunnel and stitch to the periosteum at entrance and exit with a periosteum needle.

Closing Skin Wounds.—To avoid any accidental strain on the graft after it is made, it is wise to stitch the wound in the leg, as soon as the tendon is pulled through the tunnel before completing the graft. The operation is then finished by closing the last skin wound immediately after the graft is fixed; while this is being done an assistant holds the foot inverted at right angles to the leg so that no strain comes on the grafted tendon, and in this position bandages and splints are applied.

If the graft is made into the base of the first metatarsal or on to the tubercle of the scaphoid a hole can generally be drilled right through the bone as in (1) above.

FIG. 411.—Paralytic varus. Transplantation of tibialis anticus to outer side of foot. Showing incision over insertion of tibialis anticus tendon.

FIG. 412.—After transplantation of tibialis anticus to outer border of foot, showing power of eversion.

3. *Tibialis anticus to cuboid or base of fifth metatarsal*, is the exact opposite of (2) and the idea is to use excessive inversion power to reinforce defective eversion power. This operation has been already referred to in connection with congenital equinovarus, in which case the permanent defect of the evertors is not due to paralysis but to long-continued over-stretching; a very important parallel lesson can be drawn from this by those who care to think out the question of post-paralytic over-stretching of muscles.

The steps of the operation are the same as in (2). First cut down on the insertion of the tibialis anticus and take the tendon off its insertion as long as possible (Fig. 411). Second, after closing the first wound, cut down on the junction of the muscle and its tendon in the

lower third of the leg. Third, cut down on the point selected for insertion and make a straight free tunnel through fatty tissue from the one to the other, and pull the tendon down without twisting it, and close the wound in the leg.

Implantation of the End.—The whole of the dorsum and outer side of the cuboid as well as the base of the fifth metatarsal being covered with the matted fibers of tarsometatarsal ligaments will give great strength to the periosteum; by stabbing boldly under this a tunnel can usually be made without difficulty; if the bone is too hard turn up a flap with a chisel. The real difficulty is the shortness of the tendon of the tibialis anticus; to avoid the necessity of pegging it down and so introducing a more absorbable foreign body, it is well to be careful to dissect up some of the periosteal expansion of its insertion with the tendon and not merely divide the tendon where it appears to meet the periosteum.

The foot is of course put up in eversion. The tibialis anticus after this transplanting still acts as a strong flexor of the ankle-joint, and has proved itself a powerful evertor of the foot (Fig. 412).

The transplantations above described are all in front of the mid-tarsal joint, and all have for their purpose alterations in the distribution of muscle power acting on the mid-tarsal joint, regulating mid-tarsal foot drop, pronation or supination. They have a secondary action, it is true, on the ankle.

The operation now to be described is one aimed more directly at varus and valgus deformity at the ankle-joint, and, therefore, affects the hind part of the foot behind Chopart's joint. As we have already indicated the mechanics of this part must be considered as distinct from those of the forepart of the foot.

4. *Shifting half the tendo Achillis further on to the outer or inner side of the os calcis* is an operation to correct varus or valgus of the hind part of the foot. The occasion for the operation does not arise directly from a paralytic condition, but rather from distortion of the heel and alteration of the line of traction due to prolonged walking on one side of the foot. The operation may, therefore, be indicated in some cases of congenital club-foot, and is in every way similar to the operation for shifting half the ligamentum patellæ described under dislocation of the patella.

The Operation.—A longitudinal incision is made down the middle of the back of the tendo Achillis, the tendon is split, the insertion of the half to be advanced is separated with the periosteum from the bone. A corresponding piece of periosteum is turned off as far along the side of

the os calcis as is considered necessary to correct the line of action of the muscle; the half tendon is inserted on this raw area. If a sheet of bone is cut off with the insertion it may be pegged down in its new position. If possible, stitch with 20-day catgut in preference to introducing a non-absorbable foreign body. The foot is bandaged and splinted in the equinovalgus or equinovarus position according to the deformity to be corrected till union is secure. When the patient begins to walk, a posterior brace with a right-angled piece running forward through the heel right to the waist of the boot, will save the new attachment from sudden wrenches before it has been trained to resist strain. The heel of the boot should also be crooked on the inside, if valgus deformity is to be corrected; on the outer side, if varus is the original deformity.

5. *Flexor longus hallucis or both this and flexor longus digitorum into the tendo Achillis or os calcis*, is an operation to reinforce weak calf muscles in cases of paralytic talipes calcaneus. As pure paralytic talipes calcaneus practically does not exist but nearly always occurs as part of a paralytic calcaneo-cavus this operation is usually only part of the somewhat complicated procedure which will be described below, under arthrodesis. The technique of the tendon transplantation may, however, be given here.

An incision is made along the inner side of the tendo Achillis to expose the flexor tendons as they pass behind the internal malleolus. The tendon to be transplanted is divided, a buttonhole slit is made in the tendo Achillis near its insertion, the heel is then raised to the required position, the graft is pulled through the buttonhole and sutured to the sides of the hole and to the tendon below; it is still better to bury the end of the grafted tendon under the periosteum of the heel in the way already described. If there is some valgus deformity to be overcome, as there often is, the tendon may be implanted directly into the os calcis a little to the inner side of the insertion of the tendo Achillis. If both flexor tendons are used, the flexor longus hallucis may be grafted into the tendo Achillis and the flexor digitorum into the oscalcis.

It is seldom of advantage to utilize the tibialis posticus in this way for its normal function is too important to be dispensed with, while flexion of the toes is a less important loss.

6. *Transplantation of one or more hamstrings to the patella* in order to reinforce the action of the quadriceps extensor is an operation which has proved of very great benefit in many cases in which the quadriceps

is not totally paralyzed, but is not able to do its work alone without again falling into disuse from over-stretching.

It is no use trying this operation when the hamstring muscles are not strong, for a weak muscle would probably fail to maintain its efficiency.

Operation.—A long incision is made along the biceps muscle from the middle of the thigh to its insertion in the upper end of the fibula. The muscle is separated and its tendon divided at its insertion. An incision is made over the outer part of the upper edge of the patella. A free tunnel is made from the one wound to the other. A pair of

FIG. 413.—Poliomyelitis. Transplantation of biceps to patella. Note voluntary extension of knee.

forceps is passed up it to grasp the tendon at its very end. The tendon is pulled down the tunnel and the long wound is immediately closed with great care.

The aponeurosis of the vastus externus is buttonholed in two places by stabbing a scalpel through it. The tendon is pulled through these two, thus passing into and again out of the suprapatellar pouch of the knee-joint. The end of the tendon is then buried in a tunnel on the front of the patella. The wound is closed. The limb is bandaged and fixed on a posterior splint. As the muscular effort in straightening the knee is considerable, the most careful muscle training is necessary to ensure a good permanent result (Fig. 413).

SECTION XIII

CONGENITAL DISLOCATION OF THE HIP

By

Sir ROBERT JONES, Ch.M., F.R.C.S., Hon. F.R.C.S.I. and DAVID McCRAE AITKEN, A.M., M.B., Ch.B., F.R.C.S. (Ed. and Eng.)

During the last dozen years the radical treatment of congenital dislocation of the hip has undergone great changes, and has been established on a sound basis.

The deformity may occur as a displacement *in utero*, but probably is to be regarded as a common obstetric injury which is not easily recognized at the time, unless specially looked for. The reason for this is that in the chubby limb of an infant no obvious deformity is visible, nor is there any impairment of movement which is likely to attract the attention of the mother or nurse. Hence it is not till the child walks that its clumsy rolling gait calls attention to the fact that the hip-joint is not normal.

The recognition of the invariability of Wolff's law puts considerable responsibility on the obstetrician, for the longer the head of the femur is out of the acetabulum the longer are these structures deprived of the moulding effects of normal physiological movement. It should therefore be taught that part of the duty of the obstetrician is to determine that the head of the femur is in its proper position in every new-born child. To do this with certainty all that is needed is to place the finger below the middle of Poupart's ligament and feel the rounded head with the femoral artery pulsating in front of it. If there is a dislocation the finger sinks into an abnormal hollow, and a short examination will soon find the head of the femur, usually displaced backward on to the dorsum ilii.

Very often the surgeon does not see the case till the child has begun to walk. If the deformity is unilateral the inequality in the two limbs soon attracts the parent's attention, but if the deformity is bilateral it may still be overlooked for some time; but sooner or later the clumsy waddling gait attracts attention.

Diagnosis should not be difficult if the examination is thorough.

(*a*) There is a characteristic rolling motion in walking, which should suggest examination of the hip.

(*b*) If the deformity is the usual dorsal dislocation, there is pronounced lordosis in the lumbar region, which is very unsightly and of great importance, as we shall see when dealing with treatment.

(*c*) Measurement of the length of the limb is of value only when the deformity is unilateral.

(*d*) Movements of the limb may appear free, but there is usually some limitation of abduction and of external rotation, owing to the fact that the head is lodged in a flat, false acetabulum on the dorsum ilii.

(*e*) On testing by Nélaton's line the trochanter major is found to be above its normal position.

(*f*) The head of the femur is not in its normal position below the middle of Poupart's ligament with the femoral artery pulsating in front of it, and further, the head is found in some abnormal position, usually on the dorsum ilii.

(*g*) "Telescopic" movement at the hip-joint can usually be detected by flexing the patient's thigh to a right angle and then sliding the head backward and forward on the flat, false acetabulum.

(*h*) The trochanter major and the head can generally be distinguished as two prominences on the ilium.

(*i*) An X-ray photograph should then be taken, not for the purpose of making a diagnosis of the deformity, but to assist in the statement of a prognosis, for it enables the surgeon to form some estimate of the prominence and definition of the upper and posterior lip of the acetabulum. If this position of the rim of the acetabulum is not well defined and well formed, it is highly probable that the head of the femur will tend to slip out again, even if reduction is successfully performed, and after-treatment would have to be prolonged. If the posterior and upper edge is well formed, a more confident prognosis can be given. It is wise to give a guarded prognosis before operation. When the head has been replaced in the acetabulum the surgeon can test its tendency to slip out, and can then encourage the parents by a more confident report, if he finds cause to do so.

Treatment.—The only operative procedure now generally employed for the treatment of congenital dislocation of the hip is reduction by Lorenz's method, or some modern modification of it. The procedure has been extensively practised during the last dozen years, and many modifications of it have appeared. It is only natural that every surgeon of experience should acquire methods of manipulation of his own and that some surgeons should have devised mechanical means of doing what others accomplish with their hands. Nevertheless the

mechanical feature of the procedure is Lorenz's idea of returning the head to the acetabulum.

It may be mentioned that open operation to expose the head of the femur and the acetabulum is not now practised as a routine by any surgeon of large experience. This is an operation which should only be resorted to in rare cases in which no other procedure will give any prospect of a useful functional result.

The operation which preceded Lorenz's method was that of Pacci. Previously to 1902 Robert Jones performed this operation in a large number of cases. The functional results were often satisfactory, but not so good as those subsequently obtained by Lorenz's method.

Pacci's operation consisted in pulling the limb directly downward and then outward to stretch all short muscles and ligaments. The thigh was then flexed on the body and the limb pushed downward in order to get the head of the femur as nearly opposite the acetabulum as possible. The head of the femur was thus brought opposite the acetabulum, in the acetabulum if possible, but actual reduction was not an essential point in the procedure. The next step was to make a small incision above the head and with a chisel to roughen the upper edge of the acetabulum and the adjacent part of the head so as to excite the formation of short and strong bands of adhesions. The limb was then securely fixed in a Thomas knee splint with extensions to prevent the head from slipping upward again. Later the child walked for some months in a walking caliper in which the body weight was chiefly carried on the ring of the splint, so that the head was not driven upward by weight-bearing.

The result in a limited number of cases was distinctly good; in the others the tendency of the head of the femur to slip upward and backward soon reasserted itself.

The Lorenz Operation.—This differs from the above in the essential feature that the aim of the operation is to reduce the dislocation by actually replacing the head of the femur in the acetabulum, or as we now know, securing a good anterior reposition, as the best alternative. In the hands of the most experienced surgeons the average of good *functional* results is now about 90 per cent.; in earlier days it was not so high. Of these we think not more than 40 to 50 per cent. will be found on strict examination to be true anatomical reductions the remainder being anterior repositions.

The theory of the operation is first to overcome the resistance of all muscles and ligaments which have become short by adaptation; then

when the mobility of the head of the femur is increased in this way, to replace the head in the socket and allow the shape of the socket to improve gradually by adaptive changes, under the moulding influence of the pressure of the head of the femur.

The usual method of procedure at the present day is less severe than that originally described by Lorenz. Increased manipulative skill acquired by practice and experience enables the surgeon to lift the head of the femur over the posterior edge of the acetabulum, and then with a fulcrum behind the trochanter to abduct the limb and lever the the head forward, either into its anatomical position or into a good position of "anterior reposition." With increased experience every surgeon finds that this can be done with less preliminary overstretching of short structures than was formerly the routine.

It is right, however, to describe the original Lorenz method, for it is the pattern from which all modern methods have been derived.

The shortening of the adductor group of muscles is first dealt with. An assistant abducts the thigh so as to make the adductor muscles tense. Sudden firm pressure with the thumb over the rounded tendon of the adductor longus, at the point of junction of muscle fibers and tendon, will cause the rupture of the muscle. The same effect can be produced by a sharp firm tap with the ulnar side of the hand. Any other tense muscle bands can be severed in the same way or else stretched. Rupturing a muscle by pressure of the thumb requires some practice and depends more on knack than on force. There is very little bruising of the part if this is done skilfully.

Next the hamstrings and extensors of the hip are stretched by flexing the thigh and firmly extending the knee. The flexors are next stretched by turning the child face downward and firmly hyperextending the hip.

Having thus made a direct attack on each group of muscles, the next stage is general stretching of all ligamentous structures about the joint. This can be done usually by hand, in more obstinate cases by block and tackle attached to the limb by a skein of wool hitched above and below the knee. The counter pull may be got by a towel folded cornerwise round the groin and knotted over the head of the table. The limb is then firmly extended straight downward and in various degrees of abduction till the head of the femur comes easily down to the level of the acetabulum or the trochanter major down to Nélaton's line. The attempt may then be made to reduce the dislocation. An assistant standing on the

opposite side of the patient grasps the pelvis firmly, one hand holding the crest of the ilium with his thumb along the line of Poupart's ligament; the other hand grasps the pubis and the tuber ischii in the perineum. The assistant must keep his wrists and forearms well down out of the way while the surgeon, grasping the limb near the knee, swings the limb inward and upward to complete flexion and then carries on the circular movement, bringing the head of the bone in a circular path behind the acetabulum. With his other hand the surgeon tries to lever the head forward over the posterior lip of the acetabulum. At this stage it is frequently found that tight structures across the front of the joint prevent the head from getting out far enough to jump over the edge of the acetabulum. To stretch these structures an assistant puts his fist or some other suitable pad behind the trochanter to act as a fulcrum, and the limb itself is used as a lever to stretch these short ligamentous structures. To do this quickly and effectively requires some experience and judgment, as with the head engaged in this way against the outside of the posterior lip of the acetabulum a rough movement may cause a fracture of the neck of the femur—which is a horrible accident.

If successful in stretching these structures the surgeon may be able to manipulate the head over the posterior edge of the acetabulum. Before going any farther the anterior ligamentous structures should be still further stretched.

The surgeon can now form some estimate of the result that may be expected by slowly bringing the limb downward till the head slips out. If the head slips out almost at once, the upper and posterior lip of the acetabulum is probably not well adapted for retaining the head; on the other hand, the farther the limb can be brought toward a position parallel with its fellow of the opposite side, the more confident is the prognosis of a good anatomical result.

This test is not merely of value with regard to prognosis, but it also influences the various points of the later stages of the treatment.

The first of these points is the position in which the limb is to be fixed in plaster. The position required is one with the head well forward. To secure this the thigh is fixed in full abduction with the knee well posterior to the sagittal plane of the body and the foot still more posterior, *i.e.*, with the thigh rotated inward.

There is room for a great deal of variation in this position, depending chiefly on the surgeon's estimate of the nature of the case he is handling. Thus, if he is dealing with a poorly formed acetabulum, out of which the

head slips easily, he must get the head well forward, still more if the acetabulum or the head is so poorly formed that the head cannot be said to have engaged in the acetabulum at all. His manipulation cannot be said to have resulted in an anatomical reposition, but only in an anterior reposition. In such a case it is of the utmost importance that the head should be got well forward, so that the resulting false acetabulum may be in a sufficiently anterior position to prevent the recurrence of lordosis. On the other hand, if the head is lodged in a well-defined acetabulum it is not necessary to emphasize the forward position of the head quite so strongly. The safe rule is to keep the head well forward and the thigh well inverted; as the surgeon's experience increases he will learn when he may relax this rule.

The next point is the period during which the limb is to be kept in this "first position." The original rule was three months. Here again the surgeon's experience must guide him. If he has merely made an anterior reposition or if the acetabulum is very poorly developed, three months is not too long for the first stage of formation of a false acetabulum. If, on the other hand, the head is well lodged in a good acetabulum six weeks may suffice. When the first plaster splint is removed, the first anxiety of the surgeon is whether the head is still in position. If the rounded prominence of the head is felt in the groin all is well, and the limb may be brought down 30° or 45° and again fixed in plaster. Here again everything depends on the nature of the case. The after-treatment of a good case with the head securely lodged can be pushed through the various stages rapidly—say four plaster spicas in successive positions from the first position down to a position parallel with the other limb, at intervals of six weeks. A bad case or a mere anterior reposition, in which practically an entirely new false joint has to be made, may have to be passed very gradually through half a dozen positions and be kept at least three months in each. Nothing is ever gained by rashness; therefore in all doubtful cases exercise patience and perseverance and move by slow stages.

During each stage of the treatment the child should be encouraged to get about and to move the leg and foot. If the plaster spica is properly fitted, the hip is not likely to move to an injurious extent. The play of the muscles aids and hastens those subtle adaptive changes by which a false joint is made or a poor acetabulum is deepened and made into a better one.

There is no danger of stiffness of the joint occurring as a result of prolonged fixation. In young children stiffness is usually the result

of rough handling causing some injury of joint surfaces. In children over nine years of age the risk of a stiff joint is very real, for the whole process of manipulation is often more difficult.

In our practice at the present day, the essential part of the procedure is to flex the thigh at right angles to the body, so that the head of the femur passes down to the back of the acetabulum, then to try to lift the head over the posterior edge of the acetabulum, abducting the limb with a fulcrum behind the trochanter major so as to stretch the capsule and lever the head of the femur forward. The elaborate stretching of all structures first as in Lorenz's original method is eliminated as far as possible, only those structures being stretched which are found to obstruct reduction. The idea being to effect the reduction with the minimum disturbance of the soft parts, necessarily the skill and experience of the surgeon is an important factor.

We have now greatly reduced the period of fixation in the great majority of cases, and instead of taking 12 or 18 months, treatment is often completed in six months.

To accomplish this, a second manipulation is carried out when the plaster is changed. The object of this is to invert the limb while straightening. An assistant holds the limb above the knee and pulls on it while he very gently adducts it. At the same time the surgeon grasps the thigh just below the trochanter and by a succession of rolling movements rotates the limb inward. If rotation is found difficult a second manipulation of the same kind may be necessary when the plaster is again changed at the end of six weeks.

Care must of course be taken not to let the head slip out by adducting the limb too far or too rapidly. Judiciously employed, this method of procedure has been found a great aid in reducing the duration of treatment, and in increasing the mobility and usefulness of the limb.

FAILURES, DIFFICULTIES AND ACCIDENTS

It is generally true that the younger the patient is the easier it is to reduce a congenital dislocation, though this rule has exceptions. Up to the age of five years the surgeon will usually succeed in reduction at the first attempt. The difficulty of reducing the dislocation is greater in older children, and of those over eight or ten years only a few cases are amenable to this treatment. There are, however, some exceptions, but there is a distinct risk of the joint being stiff.

(*a*) It frequently happens that the surgeon fails to reduce the dislo-

cation at the first attempt. The cause of this failure is usually inability to lever the head over the posterior edge of the acetabulum on account of the shortness of the anterior ligamentous structures, and the fact that owing to the amount of manipulation to which it has already been subjected the child's pulse is becoming unsteady. This must be taken as a signal to desist. Structures already stretched must not be allowed to shorten again, as firm "adhesions" might thus be formed which increase the difficulty of subsequent manipulation. To prevent contraction, the limb should be fixed in extension in a Thomas knee splint. It is often advisable simply to put the child back in bed with the limb steadied by sand bags for from 12 to 24 hours, till the effects of the anæsthetic and shock have passed off, and then apply the splint. The second attempt at reduction should be made in a week or ten days. This interval allows repair of damage done without the formation of firm cicatricial adhesions. A repetition of the procedure may then be successful; if not, the surgeon should try for the best possible anterior reposition. This line of treatment is applicable to the case in which the surgeon feels he has just failed by a narrow margin but the condition of the child's pulse forbids him attempting any more stretching at that sitting.

(*b*) In other cases, however, the margin of failure is greater, either because the structures to be stretched are firmer and stronger than in the former instance or because the child seems too frail to allow very much forcible manipulation at one sitting. The anterior structures may be stretched by putting the limb in the "first position" with the head on the posterior edge of the acetabulum, and fixing the limb in that position with just a little tension on the anterior part of the capsule. The case may be left in this position for two or three weeks. During this period the short structures relax and adapt themselves to the new position, and so a new starting point is gained for the next attempt. Before making a second attempt the plaster spica should be removed and the child encouraged to move the limb about for a week. This not only restores the mobility of the hip, but allows the femur to recover to some extent from the disuse atrophy which always follows prolonged fixation in one position. If the surgeon neglects this precaution, he may have the mortifying experience of inadvertently breaking the neck of the femur, even with very gentle manipulation.

(*c*) Fracture of the neck during manipulation has been known to occur. The stage of danger is when trying to lever the head of the femur over the back of the acetabulum with the thigh abducted, or

when using this position for stretching the anterior part of the capsule. The accident happens with the head engaged against the posterior edge of the acetabulum. The danger of fracture is much greater at a second manipulation than at the first owing to wasting of the bone from disuse in the interval.

(*d*) Dislocation in the plaster spica sometimes occurs after a successful reduction. It is due, first, to a poorly developed posterior edge of the acetabulum, and second, to an error in position when putting on the plaster. While the plaster bandages are being applied the head of the femur should be kept well forward and the plaster should be well rubbed in and moulded behind the head and the great trochanter. Even if the plaster is properly applied, a subsequent crack may easily give enough play for this accident to occur. When suspected, the plaster should be removed and the dislocation very gently reduced and the limb securely fixed, remembering the increased liability to fracture.

After-treatment.—In order to minimize wasting from disuse atrophy, the child should be allowed to use the limbs even for walking whenever possible. This functional use of the limb aids in moulding the new acetabulum. Here again, however, the surgeon must exercise judgment. If he is dealing with a well-formed acetabulum, he may proceed with some measure of boldness; if, on the other hand, he is dealing with a very shallow acetabulum or with an anterior reposition, he must exercise great patience and allow time for adaptations to the new position of the limb to take place.

In the last stages in what may be called "weak results" the patient may be set to walk in a walking caliper for many months. The head of the femur cannot travel upward in this splint under the influence of body weight, and so more time is given for a new acetabulum to be formed, without unduly prolonging the stages of absolute fixation. It should be clearly understood that this is not part of the ordinary treatment; it is a precaution taken after the routine treatment has produced as good a result as can be expected.

It must be remembered that, if the surgeon fails in maintaining an anatomical reduction, he should bring the head of the bone well to the front, just below and to the inner side of the anterior-superior spine. Such an anterior reposition is often a better functional result than an anatomical reposition. It completely corrects the lordosis. Lordosis is so often associated with severe pain in the back in later life that it should in every case be corrected.

SECTION XIV

INFANTILE PARALYSIS

By

Sir ROBERT JONES, Ch.M., F.R.C.S., Hon. F.R.C.S.I. and DAVID McCRAE AITKEN, A.M., M.B., Ch.B., F.R.C.S. (Ed. and Eng.)

PARALYTIC DEFORMITIES DUE TO CEREBRAL PALSIES IN INFANTS

Among the cerebral palsies of infants, those characterized by spastic paralysis of muscles with associated deformities have proved most amenable to treatment.

The authors have been accused by neurological friends of failing to distinguish with sufficient accuracy the several varieties of cerebral palsy, and of loosely classing as "spastic paralysis" cases arising from interference with motor cells and cases of derangement of coördination and control arising from some impairment of intracranial tracts. There is probably some ground for the accusation, but the fact remains that the modes of orthopedic attack found successful in genuine cases of spastic paraplegia have proved more or less successful in other similar conditions, and have even succeeded in some cases of localized athetosis.

When discussing the possibility of recovery in cases of spinal paralysis (poliomyelitis) the whole argument turned on the fact that the spinal cell might not be killed but only temporarily disabled, and that in the meantime the whole nerve-muscle apparatus had got disordered. In the case of cerebral palsies precisely the same argument holds good, only the number of factors to be considered is increased. Etiologically the sequence of events is: *first*, an intracranial lesion which causes impairment or temporary abolition of the motor and inhibitory control by the upper neurons; *second*, as a consequence of this, disordered and uncontrolled reflex activity of the spinal nerve centers; *third*, contractures of certain groups of muscles and overstretching of their opponents; *fourth*, a disorder of the reflex and voluntary excitability of the nerve-muscle apparatus due to the contracture of one group and the over-stretching of their opponents. This fourth element is really the key to the treatment which Robert Jones first employed empirically. Its significance has been made clear only by comparing clinical experi-

ences with laboratory experiments published since the clinical treatment was first adopted.

Finally, the disuse of the whole apparatus from brain cell to muscle must be overcome by re-education. The orthopedic attack is in the reverse order, first restoring the balance between the opposing groups of muscles and at the same time abolishing the disordered reflex and voluntary excitability of the nerve-muscle units which prevents them from obeying the motor and inhibitory impulses of the brain cells, and finally, if the brain cells are not dead, they must be educated to resume that normal control of the spinal nerve centers and the muscles dependent on them.

The original cause of an infantile cerebral palsy may be found:

1. Before birth, in some failure of development of the nervous system, or in some intracranial hemorrhage or inflammatory process occurring *in utero*.

2. At birth, in intracranial hemorrhage and compression of the brain by excessive over-riding of the bones. These cases are often paraplegias affecting only the lower limbs or the lower limbs much more than the upper. The suggestion is clear that excessive over-riding may easily cause bleeding from the parietal vein. The resulting blood clot would naturally be vertically situated and so compress the leg areas of the motor cortex more than the arm areas.

3. After birth, in inflammatory processes of the nature of a polioencephalitis or a meningitis. It is interesting that there is record of different members of a family being affected by spastic cerebral paralysis and infantile spinal paralysis in the same epidemic, the inference being that the same infection caused in the one case polioencephalitis and in the other poliomyelitis.

It is often difficult when the child is seen at the age of five or more years to get a definite history whether the condition was present at birth or arose after some acute illness in infancy.

Clinically the spastic paralysis resulting from the initial lesion may be:

1. A paraplegia, in which the lower limbs are affected.

2. A diplegia, in which both upper and lower limbs are affected. These fall into two classes:

(*a*) Those in which the lower limbs are more affected than the upper.

(*b*) Those in which the upper limbs are more affected than the lower.

This distinction is important, for two reasons: The first, a simple

practical one, that when a paralyzed child is being taught to walk it is a great help if he can hold a pair of sticks in his hands; if his hands are severely paralyzed, the difficulties of education of the locomotor apparatus are greatly increased.

The second reason is that at any rate some of the diplegias in which the lower limb is more affected than the upper are due to a vertical hemorrhage which has compressed the leg areas considerably and spread down only slightly over the arm areas. Consequently the brain cells have suffered from compression only for a time, till the blood clot has been absorbed. There are grounds for suspecting that cases in which the upper limbs are more affected than the lower are more frequently due to an inflammatory lesion in which the brain cells have been poisoned by toxin and therefore more profoundly impaired; consequently the prognosis must be guarded in such cases.

The difficulty in getting accurate statistics is so great that it is impossible to venture on any dogmatic statement, but the difference in the behavior of the two types under treatment is very pronounced.

In cases of hemiplegia, in which the paralysis affects one side of the body, the function of the upper limb is often more impaired than that of the lower limb, and a great number of them can definitely be stated to have commenced after an illness in infancy.

In all types there may be more or less mental impairment. Some are imbeciles; these probably include a large number of those cases originating before birth in imperfect development; many cases due to infective intracranial processes are also mentally defective owing to the infective process having impaired the higher centers, while grave mental defect occurs less frequently in those merely due to pressure by blood clot.

As education is an important part of the treatment, serious mental defect is an impassible bar, for the child must be able to try to do things with his hands and feet. In this connection it is necessary to distinguish between real cases of mental defect, and those cases in which efforts to perform voluntary movement are broken into by sudden disorderly reflex spasms. In some instances a child may appear imbecile and unable to speak, when the real fault is that reflex spasms of the muscles of the tongue prevent distinct articulation.

Cases with incontinence of urine and fæces are not suitable cases for operation; few of them reach adult life. Cases with repeated fits or convulsions in the past, which have been steadily diminishing in frequency, are not barred to treatment.

The type of case in which it is easiest to follow the processes at work is paraplegia, due to vertical hemorrhage and compression of the head during a prolonged labor.

In the first instance the cells of the motor cortex are put out of action by the pressure of the blood clot, and associated intracranial effusion.

The infant lies in its cradle very much in the flexed position in which it lay *in utero*, and does not voluntarily kick about its legs because the cerebral motor cells are not acting; if the arm areas have been touched, it does not learn to use its hands. The child thus fails to learn

Fig. 414.

Fig. 415.

Fig. 414.—A. C. Spastic paralegia adductor strongly contracted. Walked with support only crossing knees before operation.

Fig. 415.—A. C. about three years later, showing free abduction. Strong balancing power. Note strong position of feet.

the position and use of its own limbs. Next, the flexors of the thighs, hamstrings and adductors, being in a position of advantage and, further, actually more massive than their opponents, become short while the opponents are over-stretched. The calf muscles usually contract and the foot is often in an equinovarus position.

When the child is old enough to stand, if the deformity is not too great, he has hips flexed, thighs adducted, so that the knees cross when he walks, and he cannot get his heels to the ground, but walks on tiptoe with a peculiar jerking gait owing to clonus of the calf muscles (Figs.

414 and 415). This "scissors" gait is too well known to need further description. Every degree occurs from a slight spastic gait to the case that lies absolutely helpless.

Reflexes with a lesion of the upper neuron ought to be exaggerated; yet it is often impossible to elicit a knee-jerk, due to the overstretching of the quadriceps extensor by the continued shortening of the hamstrings. Strong contractures upset the reflex picture in other parts of the limbs in the same way. One of the most characteristic signs in these cases is shown when the child is standing and is quickly lifted by the shoulders; the lower limbs immediately flex still further instead of extending under gravity. This is a reflex contraction of the already contracted muscles in response to the alteration of tension. Similarly many cases if suddenly spoken to, or if startled in any way, have a sudden reflex contraction of the contracted muscles. This state of super-excitability is also shown toward voluntary motor impulse from the brain. For example in cases in which the hands are affected, the fingers and thumb are usually flexed. If the child is asked to open the hand, the first response is usually a further flexion followed by a slow and difficult inhibition of the flexors so that the fingers extend with a peculiar weaving motion of the hand; this is again followed by sudden uncontrolled flexion.

It was two papers on experiments on the dog and cat conducted by Magnus of Utrecht, which first suggested the explanation of this, and, as will be mentioned later, indicated that Robert Jones' empirical treatment of dividing and stretching contracted muscles and aiming at first restoring balance of power, rests on a sound physiological basis. According to Magnus, the reflex response obtained in decerebrated dogs and cats will be extensor or flexor according as the extensors or flexors are first put in a state of slight tension or "tone." Further clinical observations since reading his papers show that in spastic paralysis it is the contracted muscle which responds most readily to any stimulus, whether peripheral or central, and that therefore treatment to restore equal balance is correctly directed against the ultimate fault, which must be corrected before orderly control can be obtained by re-educating the higher tracts of the nervous system.

Treatment of a Typical Case of Spastic Paraplegia.—In order to make clear the procedure here advocated, it seems best first to describe the method of dealing with a straight forward case and subsequently to discuss further procedures which have been found useful in more complicated cases, thus following the line along which the various procedures have been evolved.

Operation.—I. The strongly contracted adductors of the things must be completely over-powered. The routine operation is to make an incision about 1½ to 2 in. long over the tense adductor longus in the groin, following the line of the muscle. The muscle is seized with catch forceps and about an inch of the muscle excised; tense fibers of the adductor brevis and, if necessary, of the gracilis are dealt with in the same way. Finally, tense transverse upper fibers of the adductor magnus are divided in the depths of the wound. It has been found most convenient to divide the muscles with scissors, avoiding any vessels and nerves which are visible. Mere division instead of excision

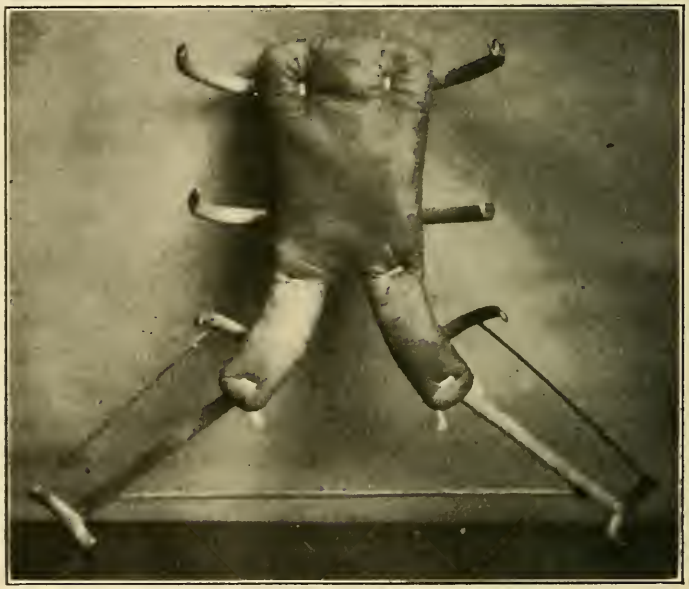

Fig. 416.—Spastic paraplegia. Thomas' double abduction frame.

is not sufficient, for the reunion is too rapid and adductor spasm is apt to recur. The wound is then swabbed with iodine and firmly plugged with gauze to arrest bleeding, while the muscles of the other limb are dealt with. The second wound is plugged, while the first is stitched up, carefully bringing the skin edges together so that the wound may be sealed as soon as possible; the second wound is then closed. Firm bandaging with plenty of cotton wool effectively prevents the formation of a hematoma. The limbs are then fixed in full abduction on an abduction frame (Fig. 416). The angle between the two limbs should be at least a right angle. It has been found that attempts to over-power the muscles by continuous stretching are unavailing except in cases of

the very mildest degree, for they lead only to a struggle between the spastic muscles and the controlling splint, which can reduce the patient to a state of dangerous exhaustion in 30 hours. In some cases during the operation where a tense band has been overlooked or not reached, it may be necessary to relax the abduction and administer a narcotic until at any rate the after-effects of the anæsthetic have passed off.

II. Flexion of the knees can often be overcome by stretching and fixation on splints. The patient cannot be comfortably fixed in an abduction frame with the knees flexed to any extent; therefore the knees should be got into a fairly straight position if possible before operating on the adductors.

Operation at the knee is transplantation of the hamstrings into the patella (v., page 645) or elongation of the muscles, never mere division, as the hamstring tendons retract too far and are lost for a future transplantation if this should be desirable.

III. The tendo Achillis should *never be divided*, as the tendon retracts too far when the foot is brought to a right angle and does not unite strongly; the result is a bad calcaneus deformity. The *operation* should always be an elongation or at any rate a mooring of the two ends so that they cannot get too widely separated. Simple mooring with strong 20-day catgut has been found amply sufficient in all ordinary cases. This operation is performed through a small incision over the tendo Achillis. Strong 20-day catgut is passed with a needle twice through the tendon and firmly knotted, both above and below the point at which the tendon is to be divided. The tendon is then divided, the foot brought to a right angle with the leg and the ends of the two pieces of catgut tied together to prevent the muscle from retracting further. Experience has shown that quite satisfactory union takes place, the strands of gut probably acting as a scaffolding for the new tissue. The operation is very simple and is quickly performed.

Progress.—The effect of dividing the big mass of adductor muscles and fixing the limbs in full abduction is very striking in cases in which athetoid movements, sudden spasm and other reflex phenomena have been prominent.

In a few days spasms and twitchings of muscles become less frequent and less violent. The child in consequence begins to rest and sleeps better. Children whose speech has been very indistinct and broken, by twitching of tongue muscles and lips sometimes rapidly learn to speak clearly.

It is not easy to explain these phenomena fully. It is clear that by

dividing the big mass of spastic adductors and so putting them out of action, a large mass of afferent impulses to the spinal cord are cut off and so the motor areas which have been kept for years unduly excited get a rest and the higher cortical centers get an opportunity to take control of the situation. We have known a child of six, a case of paraplegia with athetoid movements of the upper limbs, and almost constant twitching and grimacing of the face muscles, whose efforts at speech were quite unintelligible even to the mother, suddenly begin to speak whole sentences six weeks after operation. This indicated that the child had been receiving and storing impressions all its life, but owing to irregular output of motor energy and particularly irregular inhibitory control could not speak or use its limbs.

This case is one of many, but is particularly mentioned because it was the first of the type seen by Aitken when serving as house surgeon under Robert Jones in 1902. The child appeared an imbecile, but after watching and talking to it for some time Robert Jones said, "that child is attending to what I say and I believe is trying to answer."

These cases are among the most satisfactory to treat, and it is important to give every possible case the opportunity of recovery and not decide that the way to recovery is barred by mental defect, when the real impediment is a *secondary defect of control of the muscles.*

Routine After-treatment.—The child lies in the fully abducted position for about six weeks. Walking calipers are then fitted and the child made to move the limbs forward, outward, inward and backward to word of command, taking care that he moves only one limb at a time. The instructress helps the child by supporting the limb if the muscles are not strong enough to lift it from the bed.

The child is next set on his feet several times a day with the feet wide apart, so that he gets a broad base of support and, with a nurse on each side of him, he is made to put forward first one foot and then the other. *Crutches must never be allowed* for the child immediately discovers that he can get about quickly by swinging both legs together. He will then *never learn* to dissociate the movements of the two limbs.

Duration of this Treatment.—If the child has never walked before, it will often take 12 months of daily training to teach him to stand and balance alone. After that he has to learn to walk with two sticks instead of two nurses to support him, then with one stick and finally without any support at all.

There is nothing gained by trying to get movement of the knees till the child can walk firmly. At night splints should be worn to keep

the knees straight, as flexion deformity of the knees is a common fault, and the limbs should be tied out to the sides of the child's cot in wide abduction to keep the adductors from shortening.

Having regard to the long and tedious treatment required, a surgeon will not begin a case unless he has reasonable assurance that he will be allowed to see it through two years of treatment.

Diplegia.—The treatment of the lower limbs is the same as for paraplegia. Severe impairment of the hands and upper limbs is a great hindrance for the patient cannot help to balance himself with sticks. Therefore the state of the hands and of the child's intelligence must be carefully considered, before giving a prognosis or commencing treatment.

In the upper limb operation is rarely necessary for there are no muscles so strong that they cannot be overpowered and controlled on a splint.

The characteristic deformities are:

1. At the shoulder, adduction and internal rotation.
2. At the elbow, flexion.
3. In the forearm, pronation is often very difficult to control.
4. At the wrist, flexion.
5. In the hand, the fingers are flexed and the thumb is often turned into the palm under them.

Restoration of control of the thumb is very difficult and is essential to good function of the hand.

The hands should be put on splints with the fingers straight, the wrist dorsiflexed and the thumb extended, abducted and semi-opposed. The ideal position for the thumb is that assumed in picking up a tumbler of water, but it is very difficult to get it out as far as this on account of the very short contraction of the adductors of the first metacarpal.

As soon as the shortened flexors have relaxed and lost their spasm, the patient can raise the fingers off the splint. At first he should do this one finger at a time to word of command, without taking off the splint so as to train his control; later he has the short cock-up splint in the day time with freedom to use the fingers and thumb.

The training of the elbows and shoulders is usually not very energetic until fair movement is restored in the hand; it is not wise to burden the patient with too many new lessons at once.

Pronation deformity can usually be overcome by continuous stretching.

There is an operation to convert the pronator radii teres into a supinator by shifting its origin from the front to the back of the radius

passing the muscle through the interosseous membrane. When the operation is necessary, the muscle is so short that the mechanical difficulties in the way of making a satisfactory graft are almost insuperable. The authors, therefore, advise simple division of the pronator radii teres in very intractable cases.

Cases are rare in which flexion of the wrist can profitably be dealt with by transplantation of the flexors carpi radialis and ulnaris into the corresponding flexors. The operation should be reserved for cases in which the disability of the hand is clearly due to inequality of power of these muscles and not to other causes.

In treating cases of hemiplegia the same lines of treatment are followed. Unfortunately many of these cases are complicated by inequality of growth on the two sides, so that one leg is permanently longer than the other.

In the hand the child almost always moves the paralyzed hand simultaneously with the sound one. In some cases it seems that the unimpaired side of the brain is controlling both limbs. In some cases it is necessary to put the sound limb on a splint or even in plaster of Paris to throw its muscles entirely out of use, and so compel the child to concentrate its brain on the defective side.

As soon as the child can move the fingers at all he should be set to work at basket weaving, arranging shells in patterns or any other kindergarten occupation to train the fingers which is suited to his capacity. These children are easily discouraged and must therefore be gently dealt with by those teaching them.

In training the child, nothing must ever be done for him that he can do for himself, no matter how slow he is over it. This is more easily carried out in institutions than in private, for example in our open-air hospital to which a school is attached. When the bell rings for school, the other children will be in their places many minutes before the spastic cases can arrive, but no notice is taken of their being late, and they are never worried or made to start earlier than the others. They thus acquire a sense of independence and by practice learn to do more and more for themselves.

In the above account we have confined ourselves to a brief description of our own practice. Briefly our belief is that the continuance of the state of disability lies in the large contracted over-excitable muscles, and that these are the origin of a continuous stream of afferent impulses which keep the spinal motor system in a state of excitement and prevent the upper neuron from exercising a proper control, especially inhibitory

control. Therefore the attack should be directly on the muscles to put them out of action, so allowing the nervous system to rest.

Forster's operation of division of the posterior nerve roots has received much attention in recent years. The idea of the operation is to cut off the afferent impulses from the large spastic muscles and so give the spinal nervous system a rest before commencing re-education.

Our criticism is, first that Forster's operation involves laminectomy and opening the spinal theca is unnecessarily severe; second, we think he is cutting the nerve-muscle cycle at the wrong place, for if our interpretation of Magnus experiments and our deductions from them with regard to spastic paralysis are correct, the fault lies in the state of the muscle.

Our clinical experience is that by putting the spastic muscles out of action, by completely over-stretching them or better by dividing them, we stop the afferent impulses just as effectively as by dividing posterior nerve roots with much less risk to the patient.

As indicated in the opening paragraph, successes with straightforward cases of paraplegia have led to similar methods being applied to more complicated cases of diplegia and finally to some cases of localized athetosis, with varying success. In some cases where a patient suffers from spasmodic and uncontrolled movements of some one limb or part of a limb, a careful examination has shown that some muscle or group of muscles is short and contracted. With the idea that this contracted group of muscles was the origin of excessive afferent impulses, the suspected muscle has been divided or over-stretched and the limb fixed in plaster of Paris to bring the whole muscle apparatus to rest of course in a position in which the suspected muscle is fully stretched. Some cases have been successful, others not, and up to the present our knowledge is too little for us to say more; we can only persevere and learn from our failures, for while success encourages, it is by a proper study of the causes of failure that most is to be learned.

Arthrodesis.—Arthrodesis of joints, an operation designed to produce a firm anchylosis with the minimum removal of tissue, is in our opinion, frequently of use at the ankle and the joints of the tarsus, very rarely at the knee and never at the hip. The occasion for considering arthrodesis arises only when it is quite clear that there will not be sufficient recovery of muscle power to enable the patient to acquire a stable and useful movable joint by other means.

The operation is irrevocable and should therefore be done only advisedly after due consideration whether the patient will be better off

with a stiff joint or with a joint supported by apparatus. In making this decision the patient's station in life must be considered. Thus in the case of a "flail ankle" with absolutely no muscle power, but fairly good action at the knee, one need have no hesitation in saying that a stiff ankle and midtarsal joint will furnish the patient with a firm foot on which he can walk securely. Again in the case of limited muscular power at the ankle, in which perhaps after transplantation of muscle a balanced but rather weak foot can be obtained, the patient's position in life makes a difference; for example, a girl who will grow up in easy circumstances and never have any hard work to do, may be best off with a light aluminium brace to prevent varus or valgus at the ankle, while if she belonged to the working classes the expense of maintaining her splint, and the fact that she might have hard work to do would decide in favor of a stiff but strong foot.

In a working man a stiff foot is best; even in men of the better classes, the decision will often be made in favor of arthrodesis. For example, if the boy grows up into a young man of active habits he may prefer a stiff foot to the bother of looking after a splint, especially if his lot in life is to work in distant and less-civilized parts of the world. Arthrodesis at the ankle or foot should not be performed before the child is eight years old, first to make sure that there is no possibility of efficient recovery of muscle; second and still more important because experience has shown that irregularities of growth leading to deformities which are difficult to treat are apt to occur if the operation is performed when the patient is too young; thirdly because it is difficult to obtain osseous union in the very young. These objections disappear entirely in adolescents and young adults.

Arthrodesis at the knee should never be performed till the patient is old enough to decide for himself. There are several objections to the operation. First, it means that the femur and tibia are united into one long bone in which the liability to fracture is definitely increased. Second, the long straight limb is a nuisance to the patient in tram cars and railway trains. It is always possible to fit the patient with a splint which has a joint which can be locked for walking, and released when he sits down. Next, in a number of cases which have been operated on in childhood, definite improvement in power has occurred in the quadriceps extensor, proving that a little patience would have met with its due reward. Therefore it is wisest to let the patient decide whether he prefers a stiff knee (with its disadvantages) to the worry of maintaining a splint in working order.

The operation essentially consists in denuding the joint surfaces of cartilage, bringing the raw bone surfaces in apposition and securing osseous union. This, however, is often modified in practice, by performing the operation as a cuneiform resection of bone, so as to correct fixed bony deformity at the same time as the joint is fixed.

1. **Arthrodesis of the Ankle.**—The normal operation may be performed as follows: A free incision is made down the front of the joint to the outer side of the anterior tibial nerve. With a strong elevator all the soft tissues are separated from the bones in one layer right out to both malleoli. This leaves the whole front of the joint exposed. The cartilage covering the joint is removed with an arthrodesis chisel. This instrument is broad and thin bladed, with a slight curve like a gouge. The instrument selected should be about the same breadth as the surface to be denuded. The same instrument should be used to denude opposing surfaces so that they may approximately fit each other. The superior surface of the astragalus and the corresponding surface of the tibia are first cleared. Next the lateral aspects of the astragalus and the corresponding surfaces of the malleoli are stripped. When this has been done the astragalus will be smaller than before and the gap between the malleoli wider than before. To make sure of close apposition one of the authors gouges small strips of the denuded astragalus, packing them between the bones so as to ensure good contact and union with the tibia. The skin wounds are stitched up and then the foot is immediately put in a right-angled splint, taking care that the tibia is fixed at a right angle with the foot—to facilitate walking—as any equinus deformity prevents the heel from coming to the ground and makes the gait much less firm.

In calling the above the normal operation, the intention is not to indicate that it is the most usual operation, for in most instances there is some degree of lateral deviation—varus or valgus—which should be corrected at the same time.

A. The operation usually performed is therefore modified by taking off a wedge-shaped portion from the dorsum or side of the astragalus, so as to tilt the bone outward or inward as may be desired. In correcting a valgus deformity, for instance, the slice off the dorsum of the astragalus is thicker on the inner side than on the outer (Fig. 417). Further, it is desired in this instance to tuck the astragalus well in against the internal malleolus; therefore in the second part of the operation the surgeon would divide the external malleolus with a chisel and press it in against the astragalus to help to correct the valgus deformity. Remembering

that valgus deformity of the ankle is a much more tiresome defect than a varus deformity, the latter, when it occurs, should not be too much corrected.

No bone débris is to be thrown away or wasted—all little scraps of bone should be tucked into vacant corners to form a basis for osseous repair. Thus the normal operation is to be taken only as a model but in practice would never be actually employed for, even if there were no need for chipping off a thicker bit of bone on one side, the surgeon would chip bits of bone out of the middle or some indifferent place to pack into the corner to make sure of a strong osseous union.

It is therefore only possible to describe a model procedure which the surgeon varies whenever he desires.

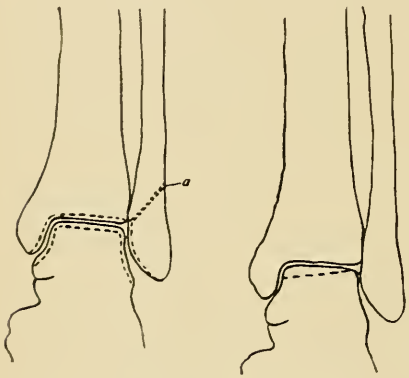

Fig. 417.—Arthrodosis of ankle. A, Tracing from X-ray plate. Single dotted line showing extent of the denuding of the cartilage. Double dotted line (*a*) showing line of section of fibula. B, Dotted line showing the direction of the bone incision for removal of wedge to correct permanent pronation.

B. Arthrodesis of the ankle from behind, or posterior arthrodesis, is a variation of the procedure indicated when the paralytic deformity is a talipes calcaneus, not equinus. This operation is frequently associated with plication of the posterior part of the capsule, shortening of the tendo Achillis, and transplantation of flexor hallucis and the peroneus longus into the tendo Achillis, and removal of an area of skin over the tendo Achillis. These are all the operations which may be performed in cases of paralytic talipes calcaneo cavus, which will be discussed fully below.

The incision, at the back of the joint, depends to some extent on the subsidiary measures to be adopted.

After the soft parts are cleared off the bone, the cartilage is removed as already described and the operation completed, the tendo Achillis being shortened by plication, preferably to give additional security. The foot is fixed on a splint with the heel raised to the appropriate position.

Arthrodesis of the midtarsal joint is also an operation most commonly employed in connection with talipes calcaneo cavus, though it is frequently indicated in pes cavus of paralytic origin, in which the muscles available for use in front of the midtarsal joint are not sufficient to prevent dropped foot at this joint.

As in all other cases of operation on bone in orthopedic surgery, it is assumed that the surgeon has already corrected all deformity due to contraction of soft structures in the sole by stretching them.

In many cases there will remain some deformity, the correction of which is obstructed by bone; in such cases the arthrodesis will be extended to include a greater or less cuneiform osteotomy. To correct cavus the base of the wedge would be along the dorsum of the foot. In many cases there is also adduction (varus) or abduction (valgus) of the forepart of the foot; in such cases more bone would be removed on the outer or inner sides of the foot respectively, so as to correct the second deformity at the same operation.

The incision therefore should be a free longitudinal one, on the side of the foot where the surgeon intends to remove the greatest thickness of bone, or, if desired, incisions may be made along both borders of the foot; in adults this gives good access. With a blunt dissector all the soft parts are lifted in one sheet, exposing the bones completely.

The necessary removal of cartilage or of cartilage with a wedge of bone is then made. The wounds are stitched, the foot bandaged in the corrected position, and kept there on a splint till union has taken place.

Arthrodesis of the knee-joint, to be secure, must consist of more than a mere removal of cartilage, for the rounded condyles would not fit the top of the tibia. The operation, therefore, follows the line of a very limited excision with the saw; the synovial membrane and patella, being healthy, are left untouched. We have already indicated that this operation should not be performed in children.

1. A "flail knee" can always be secured in a walking caliper. When the patient gets older and worries about the awkwardness of a straight leg in tram cars, he may have a hinge with a sliding lock which can be handled through the clothes.

2. If the foot is strong, a knee cage such as is used in cases of internal derangements of the knee will often suffice to steady the knee, It is fitted with a lock in extension.

These appliances may be used in succession in cases in which the extensors of the knee are recovering.

Arthrodesis at the hip is an operation for which there does not seem to be any indication excepting where both hips and spine are badly affected.

It has already been pointed out that the worst cases of paralysis of

muscles controlling the knee and foot can be fitted with a walking caliper, so that the patient can walk.

It is possible to fit a case with paralysis of all the muscles at the hip with a walking caliper; the patient can then stand on the limb. Further, by swinging the trunk he can hitch the leg forward aided by sticks and so walk enough to make himself independent of a constant personal attendant, even if both limbs are totally paralyzed.

It may be laid down as a rule that every case of poliomyelitis which can sit up straight can be taught to balance and to walk in calipers with one or with two sticks—crutches should be unnecessary.

In such a case any partial recovery of muscles of the lower limb—even though inefficient for the purpose of moving a joint—increases the power of the patient to balance himself when standing.

Paralytic talipes calcaneo cavus is a deformity which merits a separate description, not only because it is a combination of two opposite deformities, but because the treatment necessary to secure a good result is complicated. In many of the types of deformity to which reference has been made it has been possible to presume that the weaker group may recover efficient power under suitable treatment by rest and position. In calcaneo cavus, however, two opposing groups of muscles have both failed to act effectively, for the fore part of the foot is dropped in front with flexion at the midtarsal joint—due to weakness in extensors of toes—and the heel with the hind part of the foot is dropped behind, due to weakness of the muscles inserted into the tendo Achillis. The heel is thus brought nearer to the ball of the foot, and the structures in the sole have undergone adaptive shortening which, in some cases, produces a very severe and troublesome cavus deformity.

Fig. 418.—Paralytic calcaneo cavus. Before and after, note dropped heel and its correction.

The appearance of the case thus points to real impairment of the nerve cells in the spinal cord involving both groups of motor cells, and it is not surprising that the condition has always proved very intractable to treatment by apparatus. A mistake still made with too great frequency is to confound this deformity with a simple talipes equinus, as cases still appear in clinics on whom some surgeon has hastily performed a tenotomy of the tendo Achillis.

The condition should not be mistaken for pes cavus or claw-foot,

for the dropped heel is characteristic (Fig. 418); the axis of the os calcis may be nearly in line with that of the tibia.

The treatment of the two component parts of the deformity should be kept quite distinct. They are: (1) extreme cavus or plantar flexion at the midtarsal joint; (2) calcaneus or dorsiflexion at the ankle-joint. Thus the former is a deformity between the fore and hind parts of the foot and the latter between the hind part of the foot and the leg. The theory of attack is first to correct the cavus; the foot then being straight, the heel is drawn up and the foot brought down at right angles to the

FIG. 419.—Paralytic talipes calcaneo cavus. Before treatment. Annie C. Note: (1) extreme flexion at midtarsal joint. (2) Extreme degree of calcaneus.

leg so that the patient may walk fairly on the sole and not on the point of the heel.

I. (*a*) By subcutaneous tenotomy of tight structures in the sole of the foot, and by wrenching, correct the cavus deformity at the midtarsal joint. If this can be done completely, the foot can be bandaged up against the front of the leg. (*b*) Fix the midtarsal joint by arthrodesis. In practice this is seldom a pure arthrodesis but a cuneiform resection of bone, because in neglected cases the osseous deformity is too great to permit complete correction by wrenching and tenotomy only. The center of the incision along the inner border of the foot should be over the most prominent point of the deformity. In the case illustrated it will be seen that nearly all the scaphoid has been sacrificed.

FIG. 420.—Paralytic calcaneo cavus. Annie C.

FIG. 421.—Paralytic calcaneo cavus. Annie C.

When this fixation is complete, cavus deformity cannot recur, and the second part of the operation may be undertaken after an interval of four weeks (Figs. 419, 420, 421, 422 and 423).

FIG. 422.—Paralytic talipes calcaneo cavus. After first operation. Annie C. Note: A cuneiform resection has been performed in the region of the midtarsal joint in this case sacrificing nearly all the scaphoid. Note also that to get the sole flat and to make sure of union the foot has been put in extreme dorsiflexion.

FIG. 423.—Paralytic talipes calcaneo cavus. After second operation. Annie C. Note: The correction of position of the heel also note, that a considerable part of the dorsum of the astragalus has been removed behind. This series has been published, Am. J. Orthopedic Surg., April, 1908.

II. (*a*) If there is no power in the calf muscles, perform a posterior arthrodesis of the ankle-joint, removing from the dorsum of the astraga-

lus sufficient bone to allow the foot to be put at a right angle to the leg. Details of the operation of arthrodesis at the ankle are given above.

(*b*) If there is some power remaining in the calf muscles, there is a possibility of increasing it by exercise; therefore arthrodesis of the ankle is not indicated.

Instead:

1. Remove an oval area of skin behind the ankle-joint of such size that the edges can be brought together in a transverse line, when the foot is brought down to a right angle.

2. Cut down beside the tendo Achillis and with the foot at right angles plicate the posterior ligament of the ankle-joint.

3. Shorten the tendo Achillis; if the tendon is rather attenuated, plicate it rather than sacrifice any tissue.

4. Wherever possible transplant the flexor longus hallucis and peroneus longus into the tendo Achillis.

Fix the foot on a splint in a slightly equinus position to take strain off the shortened structures.

Massage and education of the calf muscles may be commenced after three weeks. About six weeks after the operation the patient may walk either in a plaster-of-Paris or celluloid shoe, or in a boot with a posterior brace and a right-angled bar running forward through the heel to the waist of the boot, which prevents sudden accidental stretching of the shortened tendon. Later, stretching of the tendo Achillis can be best prevented by stiffening the tongue, or fitting a metal tongue in the boot, and raising the heel of the boot.

On the Use of Silk as Tendon Extensions or as Artificial Ligaments.—In spite of all that has been said, and proved both experimentally by Anger and Glück and clinically by Lange and his followers on both sides of the Atlantic, it will be found on a strictly critical review that the disadvantages of silk are great. Lange, who has had a large experience, tells us that artificial silk tendons become enveloped in, permeated by, and in some instances replaced by new connective tissue which has the microscopic appearance of true tendon.

The writer's experience of silk is that it is a foreign body; if aseptic, it is enveloped in new connective tissue which must also permeate the strands of the ligature, but when any irritation, quite apart from septic infection, occurs, the foreign body, instead of being encapsuled in new fibrous tissue, is really encysted. That is to say that a serous exudate is formed which opens up the meshes of the new connective tissue, sepa-

rating the fibers from the ligature and leaving the latter lying loose in a little pocket of serum.

Experience showed that silk as a suture material for attaching transplanted tendons to their new insertions was untrustworthy, not because the ligature was itself weak, nor because of sepsis, but because the silk, acting as a foreign body, worked loose and so loosened the whole graft, so that the silk had to be removed; moreover, in these cases the insertion was liable to stretch and so render the transplantation less efficient. Of the use of silk as artificial ligaments, our personal experience is small and not satisfactory. It is interesting to note that Rich of Tacoma reports that he had to remove the silk in 18 out of 40 cases, though there was an infection in only two of the cases. On the other hand, Lange, Tubby, Plummer, Ryerson, Allison and others have reported success. Again, in an interesting summary in favor of the use of artificial ligaments, Bradford and Soutter, to prove the strength and permanency of the ligament, state "that in a child of eight the muscles largely recovered their function," and that "in a man of 23 years, one year after the operation, not only was a foot drop prevented, but some restoration of function was furnished." These cases serve only to confirm the advantage of preserving so-called paralyzed muscles from undue strain. The ease with which silk ligaments can be fixed in bone would give this method of relieving muscles of strain an important place in orthopedic surgery if we could be sure that the material would not act as a foreign irritant body. It might be pointed out that the same tendency to work loose is seen when screws or nails are used in bone, and the whole tendency of modern surgery is to avoid the introduction of non-absorbable material, and to go farther and use for all purposes of grafting homogeneous tissues derived from the patient himself.

With regard to using silk elongations in the transplantations of tendons, all the objections we have just raised apply; further, it should be unnecessary, for if the surgeon first corrects the deformity fully, he should always be able to get a tendon long enough for his purpose and so avoid a technique which, though successful in many instances, is not sufficiently trustworthy for a routine procedure.

In cases where portions of tendons have been torn out by machinery the position is entirely different, but even here it is best to replace the lost portion with homogeneous tissue if possible.

This leads us to a much more fascinating subject, namely, the use of tendons as artificial or supplementary ligaments.

Tendon Fixation.—Operation in order to utilize tendons as ligaments to give stability to insecure joints was first suggested by Tilarius. The great merit of the procedure is that the artificial ligament consists of the patient's own tissue devoted to a new purpose, and this does not involve the introduction of a foreign body.

Thus, for example, if the tibial muscles are hopelessly paralyzed, the foot will necessarily be displaced into a valgus position. To steady the ankle-joint the tibialis anticus is exposed above the ankle, its tendon is pulled on till the deformity is entirely corrected, then firmly fixed down to the tibia. It may or may not be advisable to divide the tendon. In a "flail ankle" we often utilize the tibialis anticus and peroneus longus to maintain the ankle at a right angle. The tibialis anticus is cut just above the annular ligament and passed through a tunnel under the periosteum after having been pulled sufficiently to maintain the ankle well flexed. To overcome inversion the peroneus longus is divided above the malleolus. The tendon is again exposed just as it passes under the sole. The tendon is easily pulled through from the opening through which the tibialis anticus was exposed down to the incision on the outer side of the sole, and the peroneus longus is drawn through this new tunnel and fixed to the periosteum or through a tunnel of bone in the tibia. Other operations for equinus or varus deformities of the foot may be planned on the same pattern. This operation involves total sacrifice of the function of the muscle; it may therefore only be performed when it is absolutely certain that the muscle is incapable of performing any useful function whatever.

Nerve Grafting.—Nerve grafting as a means of giving relief in cases of infantile paralysis is a method of treatment which has recently been put in practice by several surgeons.

Of the relief afforded by tendon transplantation and arthrodesis it has been possible to write with some authority, based on many years experience.

In writing of this new method we can discuss only the possibilities. It was a careful study of failures in tendon transplantation which led to improvement in technique and in after-treatment; we must therefore be prepared to examine the question of nerve grafting in a strictly critical spirit in order to find where the technical difficulties lie, and where fallacies may be detected.

Suture of a divided nerve with successful functional result was performed as long ago as 1835. Since then the operation has been performed as a primary and secondary procedure many times. Degenera-

tion and regeneration in nerve trunks has been assiduously studied, and a consideration of the conclusions drawn from this study shows that there cannot be a wider step between suturing a divided nerve and grafting one nerve into another.

For sake of clearness in argument, let us assume that the case is one of loss of power in the tibialis anticus, extensor proprius hallucis and extensor longus digitorum, and peroneus tertius; the deformity would probably be a dropped foot or pure equinus when sitting and valgus when standing, due to defect of the tibialis anticus, and the case would be called one of paralysis of the anterior tibial nerve (N. peronæus profundus).

The theory of nerve grafting would be to connect the bundle of paralyzed nerve fibers in the external popliteal nerve (N. peronæus), with unimpaired motor fibers in the internal popliteal nerve (N. tibialis), by a nerve-grafting operation in the popliteal space.

Stöffel has shown that the branches of distribution of nerves can be dissected out well up the main trunks as distinct bundles; in the case of the popliteal nerves well up in the thigh. Further he maintains that their relative positions in the nerve trunks is fixed and constant. If this statement is correct, a successful and correct operation demands of the surgeon an exact knowledge of the internal topography of the nerve trunks so that he may with certainty unite motor bundle to motor bundle. Even so, the technical difficulty of being sure of the exact position after the nerve is exposed in an operation wound seems at first insuperable; history, however, proves that mere difficulties can be overcome by improved technique.

Given a successful graft of motor bundle to motor bundle, there seems to be no reason why regeneration processes should not take place. Moreover, arguing by analogy, from the rearrangement of coördination that takes place in cases of transplantation of tendons, there is no reason why the nerve cells should not learn to coördinate and act properly in relation to their new muscular connection.

Whether the number of motor cells so connected with the distal part of the paralyzed nerve would possess enough "nerve power" to control a whole group of muscles without cutting off nerve supply to their own proper muscle group is a question which cannot yet be answered. The only argument we can offer is that most tissues in the body can be trained to do more work than they usually perform.

Among those who have contributed to the study of this subject Hans Spitzy takes a prominent place, for his numerous publications

during the past 10 years are full of evidence of careful observation and assiduous work, and even when we feel bound to disagree with his arguments we have to admit that they provoke us to fresh thought.

About 50 cases of nerve crossing for paralysis have now been reported and more or less success has been claimed in a number of them. The reports of success, however, are open to one serious objection, namely, that part of the treatment has been to put the limb after operation in a position in which the paralyzed muscles are relaxed so as to avoid pulling on the nerve ends and so pulling on the graft.

The reason is excellent, but it introduces the fallacy that it is precisely in this position that spontaneous recovery may take place if the paralysis happens to be a pseudo-paralysis from over-stretching, and this cannot be excluded by a report that electrical reactions show "degeneration." Some of the cases of recovery of function may be genuinely due to the nerve graft, but it cannot be proved unless about a year's strict conservative treatment had failed to show any signs of spontaneous recovery. On the other hand, Warrington and Murray in Liverpool report failure in five cases after operations conducted under most careful control.

Arguing from past experience in tendon grafting, the conclusion must be at present the cautious Scotch verdict of "not proven." Failure proves nothing, for it may be due to some technical flaw in the operation; one success in a case in which no fallacy could be suggested would be convincing. For the last four years the writers have been watching the cases in three hospitals for a perfect test case, and have not yet found it.

Either the cases have been those (1) in which both flexors and extensors have been severely paralyzed and therefore it was not reasonable to expect the less paralyzed nerve to be able to do double duty; or (2) in which some degree of recovery has been obtained by conservative methods, which of course are capable of considerable amelioration by the methods already described, and therefore would not furnish conclusive proof if nerve grafting were performed.

It still remains an open subject for research and study, to show how far nerve grafting may be usefully employed, not only to restore function in muscles completely paralyzed but perhaps to reinforce the nerve supply of groups of muscle whose function is seriously impaired.

If in theory and principle an operation seems sound, failure should set us to think of possible flaws in technique, while maintaining an open but critical attitude of mind.

SECTION XV

OPERATIONS ON THE LOWER EXTREMITY

AMPUTATIONS

By

J. F. BINNIE, A. M., C. M., F. A. C. S.

Amputations and disarticulations of the toes are so similar to those of the fingers that the same description may apply to both (see p. 317).

Amputation through the Foot.—When operating for injury or disease of the anterior part of the foot, save, if possible, the tarsometatarsal articulations.

Metatarsal Amputation.—Hold the foot in plantar flexion. Note the base of the first and of the fifth metatarsal bones. Between these two points make the incision *ABC*, Fig. 424, on the dorsum of the foot. Reflect with the flap *ABC* all the soft parts and expose the metatarsal bones near their bases.

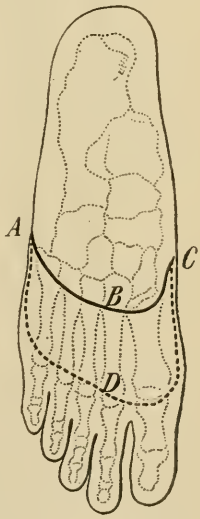

Fig. 424.—Metatarsal amputation.

Similarly make and reflect the long plantar flap *ADC*. Saw through the metatarsal bones transversely. Attend to hemostasis. Close the wound. The resultant scar is dorsal.

Lisfranc's classical operation is the same as the above except that in it, the tarsometatarsal joint is disarticulated, a very difficult procedure.

Syme's Amputation.—Beginning at the point of the external malleolus make an incision downward, to the sole of the foot. Continue the cut across the sole and up on the inner side to end about ½ in. below the internal malleolus. The cut penetrates to the bone. Unite the upper ends of this V-shaped incision by a cut straight across the front of the ankle.

Bend the foot forcibly downward. Open the ankle-joint freely and divide the lateral ligaments. Bend the foot more and more downward and so separate the surfaces of the ankle until the *tendo Achillis* is exposed. Divide this close to the *os calcis*. Dissect the heel flap from the

os calcis from above downward leaving the flap as thick as possible and *un*punctured. Remove the foot. With a saw remove both malleoli. Pull the divided nerves as far as possible out of their sheaths and cut them off short. Attend to hemostasis. Close the wound.

Amputation of the Leg.—A good stump after a leg amputation is one on which the weight of the body may be borne without pain and which is long enough so that it can be fitted comfortably and efficiently into the bucket of an artificial limb. Various osteoplastic methods of treating the divided end of the bone have been devised (Bier and others) so as to obtain a lack of tenderness, but the Hirsch and Bunge aperiosteal procedure is so easy and efficient that it is rapidly superseding them. The avoidance of painful stump neuromata is best accomplished by pulling the divided nerves as far as possible out of their sheaths and, after cutting them, letting them retract far from the site of the amputation. It does not seem to matter much whether the scar of the skin, incision is situated over the end of the stump or not. After the wounds are healed it is important to massage the stump and especially to subject it to a certain amount of therapeutic abuse by bumping it with moderate force against some smooth hard object. After a comparatively short period of such treatment the stump will be ready for the fitting of a simple "peg leg" and later of a more ornate artificial limb.

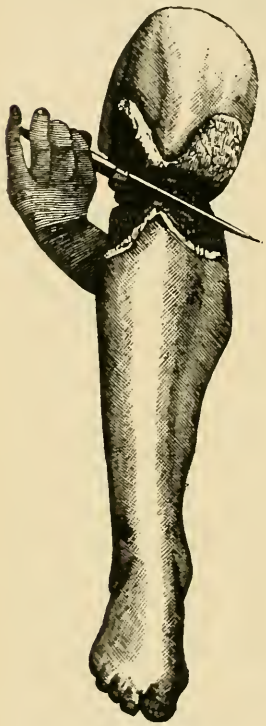

Fig. 425.—(*Farabeuf.*)

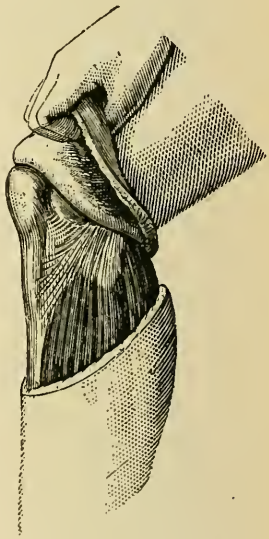

Fig. 426.—(*Farabeuf.*)

Amputation by Lateral Flaps.—Support the leg free from the table. With a scalpel trace out a U-shaped flap on the inner side of the leg (Fig. 425). The incision begins in the median line in front and ends at a corresponding point behind. Trace an identical flap on the outer side of the leg. Reflect these flaps, consisting of skin and superficial

and deep fascia, upward. The combined length of the flaps should be equal to one and one-half times the diameter of the limb at the point of bone section. At a level about 1½ in. lower than the line of proposed bone section, which will be opposite the base of the skin flaps, divide the muscles circularly (it is well to divide the posterior muscles at a lower level than the anterior to allow for their greater retraction).

Divide the interosseous ligament. Divide the periosteum around the bones at a level about ½ in. *above* the line of bone section and separate it from the bones *downward*. Retract the soft parts upward by means of a three-tailed cloth, the middle tail of which is pulled through the interosseous space. Saw through the tibia and fibula. The line of section of the fibula should be slightly higher than that of the tibia. With a curette remove the marrow from the bones for a distance of about ½ in. (Hirsch and Bunge). Attend to hemostasis. Treat the divided nerves in the manner already described. Close the wound, generally with deep and superficial sutures so as to leave no dead spaces. Apply dressings. A posterior splint is usually comforting to the patient.

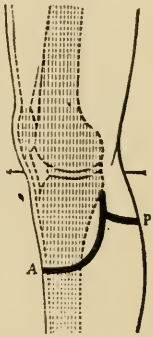

FIG. 427.—(*Farabeuf.*)

The above is a classical method of amputating the leg but in actual practice the surgeon must generally modify his incisions to suit the individual case.

Disarticulation at the Knee.—Note the level of the joint. On the anterior surface of the leg mark a point at a distance from the joint line equal to the diameter of the leg. On the posterior surface of the leg mark a similar point, one-half the diameter of the leg below the joint line. Make an oval incision through the skin and deep fascia round the limb and passing through the points marked on the anterior and posterior surfaces. Reflect the skin and fascia upward until the joint is exposed (Fig. 426). Disarticulate. Attend to hemostasis. Approximate the middle of the anterior to the middle of the posterior part of the skin and fascial flaps. Apply sutures so that the resultant scar is posterior and transverse. An almost identical operation is performed when the articulation is exposed by means of formal flaps (Fig. 427).

Amputation Beside the Knee.—*Carden's Amputation.*—Reflect the flaps of skin and fascia outlined in Fig. 428. Divide the deep structures by a circular sweep of the knife applied immediately above the patella. Saw through the femur immediately above its articular cartilage.

Gritti's osteoplastic operation is exactly the same as Carden's *except* that the patella is reflected in the anterior flap and its articular surface is sawed off (Fig. 429). When the wound is closed the cut surface of the patella is fixed against the cut surface of the femur.

Sabanejeff's Osteoplastic Operation.—Outline the anterior flap as in Carden's method but let its lower point be well below the patellar tubercle. With saw and chisel cut off and reflect in one piece with the skin flap, a portion of the anterior and upper end of the tibia. Complete the operation. In closing the amputation as in Carden's wound apply the bone in the anterior flap to the divided end of the femur.

FIG. 428.—Cardin's amputation. (*Moullier.*)

Amputation of the Thigh.—The old method of amputating by transfixation is particularly suitable in the thigh but almost any method of operating is good provided that the divided bone is well covered by well-nourished flaps. The patient rests with his buttocks on the lower edge of the table. Elevate the limb to render it anæmic. Apply an elastic constrictor high up on the thigh. Have an assistant hold the limb in a convenient position free from the table.

With the left hand retract the skin upward. Opposite the place chosen for bone section introduce a long amputating knife at a point in the middle of one side of the thigh and pass it through the limb in front of the femur to emerge through the skin at a point immediately opposite to its insertion. Cut downward and then forward to form a flap equal in length to the diameter of the limb at the site of bone section.

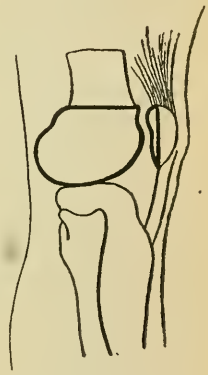

FIG. 429.—Gritti's operation. (*Stewart.*)

Through the original wound once more make the knife transfix the limb but make it pass behind the bone. Cut downward and backward to form a flap equal in length to half the diameter of the limb. Retract the soft parts to a point about ½ in. *above* the chosen site of bone section. Make a circular incision through the periosteum and reflect it *downward* for ½ in. (Hirsch). Divide the bone with a saw. With a sharp spoon remove the marrow for a distance of about ¼ in. (Bunge).

Attend to hemostasis. Pull the severed nerves out of their sheaths

as far as possible and divide them. Close the wound with deep and superficial stitches. The resultant scar is transverse and posterior.

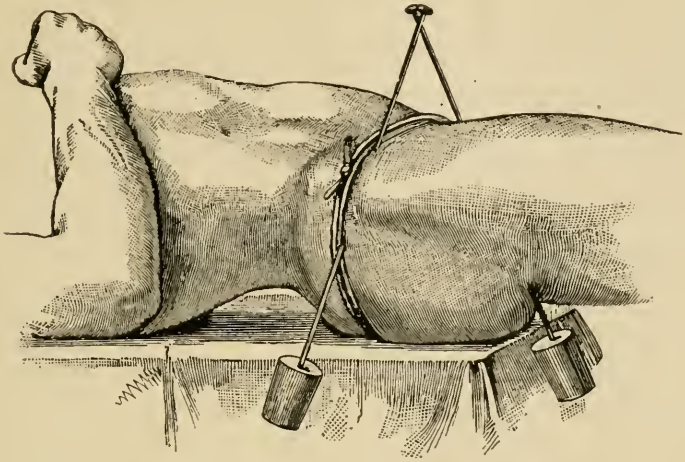

FIG. 430.—(*Jacobson.*)

Amputation or Disarticulation at the Hip.—*Methods of Temporary Hemostasis.*—1. *Wyeth's Pins.*—Provide two mattress pins each 1 ft.

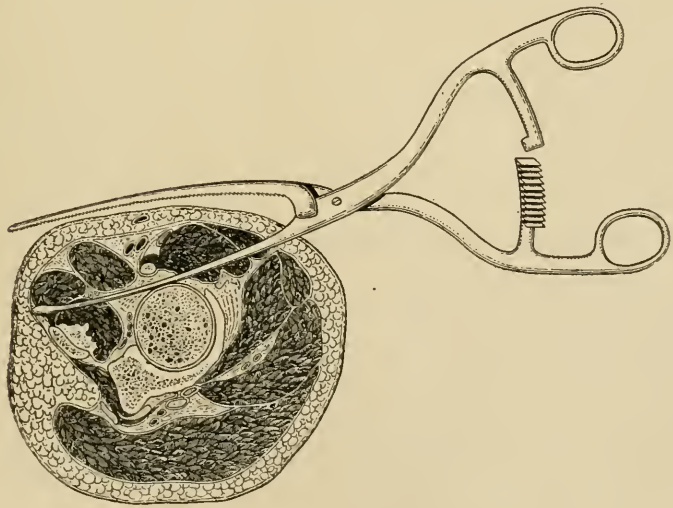

FIG. 431.—(*Thomas.*)

long and 3/16 in. thick. Insert one pin 1/4 in. below and slightly internal to the anterior superior iliac spine. Make it pass somewhat superficially through the tissues external to the hip to emerge on a level

with the point of insertion (Fig. 430). Insert the other pin through the adductor longus ½ in. below the perineum to emerge 1 in. below the ischial tuberosity. Protect the points of the pins with corks. Apply an elastic constrictor tightly around the limb above the pins.

2. *Lynn Thomas' Forceps.*—These forceps are like very long and strong intestinal clamps but one blade is provided with a sharp point. Introduce the pointed blade 1½ in. below the anterior superior iliac spine and pass it in front of and in contact with the femur to emerge at the posterior scroto-femoral junction. The other blade applies itself to the skin of the front of the thigh. Close the blades and so control the femoral vessels (Fig. 431).

3. *Macewen's Method.*—Compression of the Aorta.—Arrange the patient exactly as he is to lie during the operation. Place a platform or steady stool by the left side of the table of such height that an assistant standing on it can lean over sidewise and with his right elbow fully extended lay his closed fist in the aorta immediately to the left of the umbilicus. The assistant placed as above, facing the patient's feet, stands on his left foot, his right foot crossing the left, leans on his right fist and so compresses the aorta with the minimum of fatigue.

The writer can vouch for the simplicity and efficiency of the method; he can also vouch for the fatigue of the assistant at the close of the operation.

4. *Momburg's method* of controlling the circulation in the lower half of the body ("Zentralblatt für Chir.," 1908, No. 23) is applicable not merely to operations about the hip-joint, but to interilio-abdominal amputations as well. Apply a rubber tube (as thick as a man's finger) under full tension, two to four times around the waist of the patient between the iliac crest and the lowest ribs. Watch the femoral pulse; as soon as it is no longer palpable, enough constriction has been applied. As soon as the operation is completed, apply an elastic bandage to both limbs from the feet up if the operation has been on the pelvis, or to the remaining limb if one has been amputated. Elevate the limb. Remove the constrictor from around the waist. Gradually remove the elastic bandage from the limb so as to permit the circulation to be resumed by degrees in the lower part of the body lest too great a strain be suddenly put on the heart.

External Racquet Incision.—Place the patient on his back with the buttocks resting on the extreme edge of the table. An assistant supports and manipulates the leg as may be necessary. Flex, slightly adduct and rotate the thigh inward. Make a longitudinal incision from

a point about 2 in. above to a point 6 in. below the tip of the trochanter major. This cut penetrates to the bone along a line near the posterior edge of the trochanter. Divide the muscular attachments of the trochanter and expose the joint. Separate the soft parts from the femur (hugging the bone during this step) throughout the whole length of the wound. This is most difficult at the trochanter minor and the linea aspera. Dislocate the head of the bone through the wound.

If temporary hemostasis has not already been secured:

(*a*) With a forceps passed through the wound, perforate the tissues on the inner side of the thigh and draw through two portions of stout rubber tubing. Tie one of these tightly round the anterior, the other round the posterior tissues (Senn). This insures hemostasis during the rest of the operation.

(*b*) Grasp the tissues of the anterior part of the thigh between the blades of a Lynn Thomas clamp. This secures the principal vessels. If desired, clamp the posterior tissues in a similar forceps.

(*c*) Have an assistant grasp the tissues anterior to the wound in the fingers. This is very fatiguing to the assistant and hence somewhat insecure.

At the lower end of the vertical incision divide the skin and deep fascia all round the thigh and reflect them up for 2 in. Divide the muscles and complete the amputation. Attend to hemostasis. Close the wound by deep and superficial sutures after providing for drainage. The wound lies as remote as possible from the nates and genitalia.

Wyeth's Amputation.—Introduce Wyeth's pins (p. 685). Apply an elastic constrictor above the pins. About 2½ in. below the lesser trochanter make an incision through the skin and superficial fascia around the thigh. Reflect these structures upward to the level of the lesser trochanter and here divide the muscles circularly. On the outer surface of the thigh make a vertical incision down to the bone from near the elastic constrictor to the circular cut. Ligate all the visible blood-vessels. Separate all the soft structures so as to expose the hip-joint. Divide the capsular ligament. Cut a notch in the cotyloid ligament to admit air to the joint. By manipulation expose the ligamentum teres and divide it. Dislocate the head of the femur using the limb as a lever. Slowly remove the constrictor; pick up and ligate all bleeding points. Close the wound after providing for drainage.

Anterior Racquet Incision.—If one dislikes using means for temporary hemostasis (many surgeons do) one may make a 4-in. vertical incision downward from a point just below the middle of Poupart's

ligament and through this expose and tie the femoral vessels. The amputation is completed through an obliquely circular incision at the lower end of the vertical one. All bleeding vessels are secured as soon as they are divided. The results of hip disarticulation by any of the classical methods are very bad, when they are done for sarcoma of the femur. This is due to the fact that sarcoma early involves the muscles, especially the adductors (Quenu et Desmarest, "Rev. de Chir.," 1903, No. 5).

The writer suggests the following operation through an *anterior racquet incision:* Use Momberg's method of temporary hemostasis. Ligate the femoral vessels and make an incision around the thigh as described in the previous paragraphs. Reflect the skin flaps to the iliac crest, the rami of the pubis and ischium, the ischial tuberosity, etc. Separate the muscles from their origins on the outer surface of the pelvis and dissect them down until the hip-joint is completely exposed. Divide all the muscles coming to the femur from within the pelvis. Disarticulate and remove the limb. While attending to hemostasis look out particularly for the gluteal and sciatic vessels before removing the Momberg constrictor.

Interilio-abdominal Amputation.—(*Jaboulay's Operation*).—*Step* 1.—Beginning at the symphysis of the pubis, make an incision parallel to and below Poupart's ligament. Continue the incision the whole length of the crest of the ilium. Expose the peritoneum without opening it and separate it by gauze dissection from the underlying structures until the common iliac vessels are exposed. Doubly ligate and divide the common iliac artery. Do the same to the external iliac vein.

Step 2.—Make a circular incision through the skin and subcutaneous tissues completely round the thigh at the junction of its middle and upper thirds. From a point in the middle line of the anterior surface of the thigh make an incision upward and inward reaching from the circular incision to the pubis. From the same point make a similar incision up to the anterior superior spine. These two cuts meeting the cut made in Step 1, surround a triangle of tissue which must be sacrificed, and outline a very large posterior, cuff-like flap. Reflect the cuff-like flap of skin and subcutaneous tissue so as to expose the whole base of the thigh and its pelvic connections.

Step 3.—Retract the spermatic cord (or round ligament) inward and upward. Separate the rectus and pyramidal muscles from the pubis on the affected side. With a stout knife divide the symphysis. Separate the corpus cavernosum and the muscles and fascia from the ischio-

pubic rami. Abduct the thigh forcibly so as to make the symphysis gape. Separate from the bone the soft structures arising from the inner surface of the ilium, as the thigh is more and more abducted. If these structures are involved remove them also. Divide the psoas. Expose and divide the sacro-iliac articulation from within outward. Divide the structures emerging through the sciatic notches. When this is done it is easy to remove the limb and corresponding portion of the pelvis.

Step 4.—After reviewing the wound, cover it by the large cuff-like flap.

Various modifications of the above operation have been attempted. At the best it is a most formidable procedure. If the disease is sarcoma, recurrence is almost sure to take place should the patient survive the operative ordeal. When the operation seems indicated for tuberculous disease of the hip involving the ilium, most surgeons would operate in two or more stages, for instance: (*a*) Amputate or disarticulate at the hip-joint. This *per se* might so increase the resisting power of the patient by removing a great source of absorption that nature might possibly cure the patient. (*b*) At a later stage the surgeon may remove part or all of the ilium as may be indicated.

SECTION XVI

LOWER EXTREMITY

By

J. F. BINNIE, A.M., C.M., F.A C.S.

OPERATIONS ON JOINTS

The Hip-joint.—*Introduction of a Trocar and Cannula into the Hip-joint.*—The trocar must be 2¾ to 3½ in. long and of a caliber suitable for the free passage of the fluid to be drawn off or injected.

The patient lies flat on his back; the thigh is adducted and rotated slightly inward. Place the finger at the tip of the trochanter major midway between its anterior and posterior borders. Guided by the finger introduce the trocar immediately above the trochanter and steadily push it inward, at a right angle to the axis of the femur, until its point strikes bone (the head or neck of the femur). Keeping the point of the instrument in contact with the bone, strongly abduct the limb and push the trocar cautiously upward and inward until bone is again encountered. The point now lies between the femoral head and the edge of the acetabulum. Withdraw the trocar and push its cannula further into the joint. If there is much fluid in the joint, stop pushing the cannula forward as soon as the fluid escapes freely through it. If some therapeutic agent is to be injected, attach a syringe previously charged with the agent and complete the injection. The materials most commonly injected are: formalin glycerin 2 per cent.; iodoform glycerin 10 per cent.; Murphy's solution (iodoform 10 per cent.; formalin 2 per cent.; glycerine q. s.); carbolic solution 5 per cent.

In traumatic dry arthritis Rovsing advises the injection of about 20 cc. of sterile vaseline. The injection is contraindicated if *turbid* fluid escapes through the cannula.

In simple traumatic hydrops the solution of carbolic acid is sometimes useful. When the disease is tuberculous, one of the iodoform emulsions is used. In pyarthros Murphy aspirates the joint and then fills it with formalin glycerin which ought to have been prepared at least 48 hours previously. After injection the limb ought to be subjected to traction by weight and pulley.

Arthrotomy of the Hip.—*Anterior Incision.*—From a point about 1 in. below and a finger breadth internal to the anterior-superior iliac spine, make an incision for 3 or 4 in. along the inner border of the sartorius. Retract that muscle outward; expose and retract outward the tendon of the rectus femoris; expose and retract inward the iliopsoas muscle. The joint capsule is now visible. Flex, abduct and rotate the thigh *outward*. Incise the capsule. Explore the joint.

Posterior Incision.—Langenbeck's Method. Place the patient in the latero-ventral posture. Flex the hip to an angle of 45 deg. From a point about 2 in. *below* the tip of the trochanter make an incision, in the mid-line of the trochanter and in the axis of the femur upward for about 4½ in. (Fig. 432) and directed toward the posterior-superior iliac spine. Divide the tendon of the gluteus maximus on the trochanter in the line of the skin wound and continue this deep cut upward by splitting the fibers of the muscle. Retract the edges of the deep wound; penetrate the subjacent fat; expose the pyriformis muscle (anterior and inferior) and the gluteus medius (anterior and superior); penetrate between these two muscles and so expose the joint capsule. Incise the capsule.

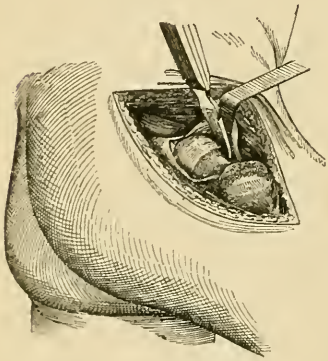

FIG. 432.—(*Labey.*)

Arthrotomy is usually undertaken for purposes of exploration and drainage.

Arthrectomy.—*Anterior Incision.*—Barker's Method. Make a 4-in. incision downward and slightly inward from a point ½ in. below and external to the anterior-superior iliac spine. The upper part of the cut runs along the external border of the sartorius; the lower part lies between that muscle and the tensor vaginæ femoris. Retract the sartorius and rectus femoris inward and so expose the joint capsule. Incise the capsule along the line of the femoral neck. Explore the joint. So far the operation has been merely an arthrotomy.

Exploration shows that the femoral head must be removed. Divide the neck of the femur with a saw or osteotome; remove the head of the bone. (Removal of the normal bone is very difficult *but* where tuberculosis demands its removal it is usually easy to do so. Occasionally, however, the femur may be so fixed to the cotyloid cavity that its head can be removed only by chiselling.) Dissect away all evidently diseased synovialis. Explore the acetabulum and remove all disease with

chisel, curette or other suitable instrument. If no secondary pyogenic infection is present, fill the cavity with iodoform glycerin or iodoform formalin-glycerin and close the wound without drainage. If secondary infection is present drainage will be necessary. Usually no splint is required immediately after the operation but if there is a tendency toward displacement, distraction by weight and pulley may be useful. Barker advises that, when the wound is in a fair way to heal, one should apply a double Thomas' splint so that the patient may be moved into open air without disturbance.

External or Langenbeck's Incision.—König's Method. The exposure of the joint is the same as in Langenbeck's arthrotomy except that the incision is about 5 in. in length. The knife penetrates to the bone in the first cut. With long bladed retractors open the wound widely. Divide the joint capsule and the periosteum of the trochanter major in the line of the wound. Do *not* divide the trochanteric muscular insertions but with a broad chisel cut off the anterior and posterior margins of the trochanter to which they are attached and retract them upward with these shells of bone. Cut off the remainder of the trochanter flush with the neck of the femur. Pass a Gigli saw around and divide the neck of the femur. Remove the head of the bone with a large and powerful elevator. Sometimes this is easy, often difficult and sometimes there is so much bony change and ankylosis that it must be cut out with a chisel. Cutting away a portion of the posterior-superior rim of the acetabulum aids greatly.

Thoroughly examine the exposed bones and remove any diseased tissue. Excise all diseased synovialis. [If disease has penetrated the pelvis and caused an iliac abscess, open this by an anterior incision above Poupart's ligament (extraperitoneally of course), evacuate its contents, clean its walls, fill with iodoform formalin-glycerin and close with sutures.]

After removing all diseased tissues irrigate thoroughly with hot water; swab with tr. of iodine; dry with gauze and introduce a tube or cannula into the cavity. Close the wound with deep and superficial sutures. Through the tube fill the cavity with Beck's bismuth paste or iodoform formalin-glycerin. Remove the tube and close its track with one or more sutures. Apply dressings. After-treatment consists in applying extension by weight and pulley, in obtaining immobilization by means of a double abduction splint for six or eight weeks. After three weeks, if all goes well, begin gentle passive motion and

after eight weeks permit the patient to go about on crutches. For many months it is well to keep up extension at night.

Rutherford Morrison's Operation.—Through a convex incision above the trochanter major divide all the muscles inserted into the trochanter. Dislocate the head of the femur through the wound. Remove all the capsule, synovial membrane and articular cartilage. Do *not* remove the head of the bone unless it has become a sequestrum. Close the wound completely. Immobilize.

Arthroplasty.—In cases of anchylosis of the hip a useful mobile joint may often be obtained by means of arthroplasty.

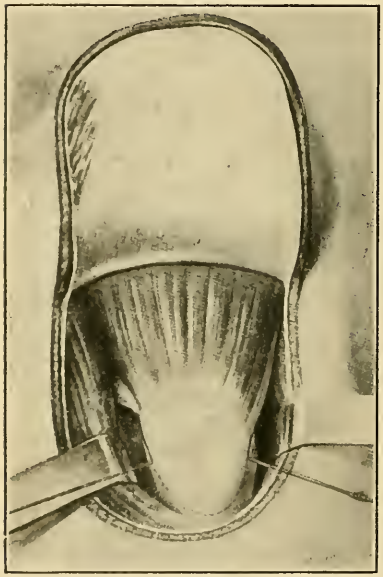

Fig. 433.—(*J. B. Murphy.*)

J. B. Murphy's Operation (Journal A. M. A., May 20, 27; June 3, 1905).—By a V-shaped incision outline a flap of skin and fascia lata, the base of the flap being 4 in. above and its apex 2 in. below the trochanter major (Fig. 433). The base of the flap is 5 in. wide. Reflect the flap upward thus exposing the trochanter. By means of an appropriate needle pass a Gigli wire saw round the base of the trochanter and divide it transversely (Fig. 434). Retract the trochanter, with its muscular attachments, upward. Incise the joint capsule and separate it from the ilium completely. Chisel the femoral head and any osteophytes which may be present, from the acetabulum in such a manner as to preserve the head of the femur as much as possible (Fig. 435). With an appropriate spherical reamer smooth and deepen, *i. e.*, reconstruct, the cotyloid cavity (Fig. 436). With a cup-shaped reamer smooth the head of the femur. Dissect the fascia lata and some of the fat from the V-shaped flap, leaving the base intact. Line the acetabulum with the base of the newly formed fascial flap and fix the latter *in situ* by a few sutures. Return the head of the femur into the cavity. The apical portion of the fascial flap protrudes from the new joint. Suture this portion of the flap to the periosteum and capsule attached to the femoral neck. This is important as every part of the articulating surfaces should be covered with fascia. Replace the mobilized trochanter and fix it in

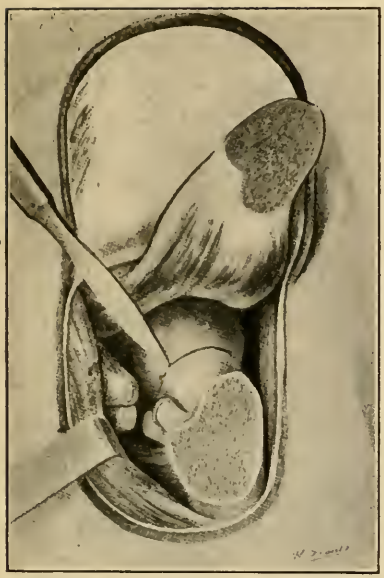

FIG. 434.—(*J. B. Murphy.*)

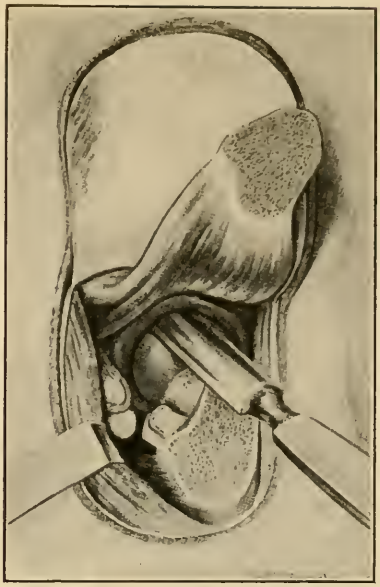

FIG. 435.—(*J. B. Murphy.*)

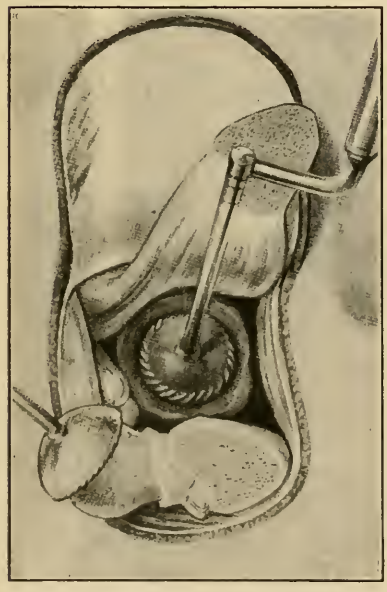

FIG. 436.—(*J. B. Murphy.*)

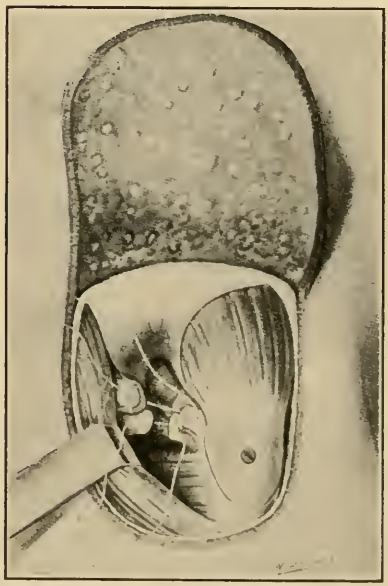

FIG. 437.—(*J. B. Murphy.*)

position with a couple of wire nails (Fig. 437). Apply dressings. Apply an abduction splint to both limbs and use traction by weight and pulley on the affected limb. It may be necessary to perform one or more tenotomies or myotomies before a good position is obtained.

Robert Jones' Operation.—Suitable in bony anchylosis following tuberculosis or sepsis and in *malum coxæ senilis* where the body weight acting on the head of the bone and articular friction keeps the disease active.

The principle of the operation is to produce a new joint without

FIG. 438. FIG. 439.

FIGS. 438 AND 439.—R. Jones' operation. (*Jones.*)

disarticulating the head of the femur. The shock is less than when the head of the bone is excised.

Make a 6 in. longitudinal incision along the outer surface of the upper end of the femur. One-half of this incision is above and one-half is below the mid-point of the upper border of the trochanter. The lower half of the cut penetrates to the bone. Retract the soft parts. With a saw or osteotome divide the base of the trochanter transversely and reflect the trochanter with its muscular attachments upward (Fig. 438). Divide the neck of the femur close to the head of the bone. Exert strong extension on the femur. Apply the cut surface of the

mobilized trochanter to the cut surface of that part of the femoral neck which is continuous with the head of the bone and fix it there with a nail or screw (Fig. 439). This fixes the trochanter to the head of the femur which is still in the acetabulum. Close the wound with deep and superficial sutures. Occasionally it may be necessary to remove more bone from the upper end of the femur.

Operative Reduction of Old Dislocations of the Hip.—1. *Posterior Dislocations.*—From the lower margin of the great trochanter make a long incision upward and backward toward the posterior-superior iliac spine. Penetrate the gluteus maximus by separating its fibers throughout the length of the wound. This exposes the head of the femur. The pyriformis, obturator internus and gemelli muscles are found tense and obstructing both reduction and access to the cotyloid cavity. Forcible rotation of the flexed knee may so stretch these muscles as to permit of their retraction or they may be divided (to be subsequently repaired by suture) and retracted.

As soon as the cotyloid cavity is exposed, remove from it any fragments of bone or masses of fibrous tissue which may prevent reduction. It may be necessary to excise part of the wall of the cavity before it is possible to reduce the dislocation. By means of rotation replace the head of the femur in the cavity. Repair all divided structures. Close the wound with or without drainage. The after-treatment consists in extension by weight and pulley plus immobilization in a double abduction splint.

2. *Anterior dislocations* may be treated in much the same fashion as are the posterior.

As has been pointed out by Mr. Fagge in his article on dislocation of the hip, a very crippling displacement may be converted into a less crippling anterior one by manipulations such as Lorenz advises in congenital luxations.

The Knee.—*Puncture of the knee* is most commonly practised to withdraw effusions or as a preliminary to lavage and the injection of various therapeutic agents.

At a point a little above and external to the patella, introduce a trocar and cannula downward and inward as if the aim was to strike the articular surface of the patella. Withdraw the stilette. Permit the effusion to escape. (If nothing further is required withdraw the cannula and apply dressings).

With a common glass syringe attached to the cannula by rubber tubing fill the joint with salt solution. Disconnect the syringe from

the cannula and let the solution flow out. Repeat the lavage as often as may be necessary. If the disease is simple hydrops articuli, many surgeons follow the lavage by injecting about 3 drams of 5 per cent. carbolized water. If the disease is tuberculous, one may inject a few drams of a 10 per cent. or 20 per cent. suspension of iodoform in glycerin, or of iodoform in a 2 per cent. solution of formalin and glycerin. As a preliminary to any operation on the knee, *e.g.*, suture of fractured patella or excision of a semilunar cartilage, Murphy always injects enough of a 2 per cent. solution of formalin in glycerin (at least 48 hours old) to mildly distend the joint. The injection produces a mild arthritis which he thinks acts as an immunizing agent against infection during the major operation performed about a week later.

In painful, dry arthritis Rovsing punctures the joint and injects 10 to 20 cc. of vaseline, unless *turbid* fluid has escaped through the cannula.

After completing the injection remove the cannula, apply dressings. Keep the patient in bed for a few days and then let him go about on crutches.

In empyema of the knee Murphy is a strong advocate of aspiration and repeated injections of formalin glycerin. In the after-treatment, extension by weight and pulley is essential.

Arthrotomy may be performed for the following purposes: (*a*) exploration, (*b*) the removal of effusions, *e.g.*, blood, pus, etc., (*c*) as a preventive measure after infected or suspected wounds, (*d*) as a substitute for puncture and injection, (*e*) removal of foreign bodies, (*f*) as a step in other operations on the joint.

Antero-lateral Incision.—Make a slightly curved incision one finger-breadth to the side of the patella, beginning opposite the lower end of that bone and extending to a point about two fingerbreadths above the patella. When the synovialis is exposed, make a small cut into it for exploratory purposes, this opening in the synovialis to be enlarged if necessary. If a single incision is insufficient a similar one may be made on the opposite side of the patella.

When pus is present it may be necessary to make one or more counter-openings posteriorly as follows: pass a forceps through the antero-lateral wound, through the joint and make it elevate the soft parts on the outer side just anterior to the hamstring, thus avoiding the external popliteal nerve; on the inner side it may pass between the tendons. Cut through the elevated skin with a knife so as to expose the end of the forceps; grasp a rubber tube in the forceps and pull

the tube through the wound. In draining any joint it is wise to have the tube reach to but not through the synovialis as the latter strenuously resents the presence of a foreign body.

Postero-lateral Incisions.—*External Incision.*—Extend the knee. Make a 2½ in. incision immediately anterior and parallel to the tendon of the biceps. This cut divides the skin and fascia and extends nearly down to the head of the fibula. Expose the biceps tendon by slightly flexing the knee. Retract the tendon backward and expose the posterior border of the external condyle of the femur. Open the capsule of the joint. Explore and, guided by the finger or some suitable instrument, enlarge the wound as much as may be necessary.

Internal Incision.—Extend the knee and flex the thigh on the pelvis. See and palpate a longitudinal groove beside and behind the internal condyle. The inner border of the groove is formed by the gracilis, the outer by the semitendinosus. Opposite the knee-joint make a longitudinal incision in the groove. Divide the skin and fascia; expose the sartorius and, half hidden by it, the gracilis. On the outer, *i.e.*, the popliteal side of these structures, note the narrow tendon of the semitendinosus and more deeply the large semimembranosus tendon; retract these forward. Open the joint on the posterior border of the internal condyle of the femur.

Arthrectomy.—*Excision of the Knee.*—Access to the knee may be obtained by lateral incisions (see Arthrotomy); by a horseshoe incision which divides the *tendo patellæ* and permits the reflection upward of a flap containing the patella; by a transverse incision over the patella, division of the patella by a saw and reflection upward and downward of two flaps each of which contains one-half of the patella.

When the joint has been exposed note the extent of the disease. Excise the synovialis by sharp dissection. Divide the ligaments and dislocate the joint so as to complete the removal of all diseased synovialis. If diseased foci are present in the bone remove such either by cutting them out with a gouge or by resecting the ends of the bone. If bony anchylosis is desired, the articular cartilage must be removed from the femur, tibia and patella whether diseased or not. Any cavities left in the bone may be filled with Mosetig's bone plug (iodoform 60, spermaceti and ol. sesami āā 40. Heat slowly to 100°C. in a flask on a water-bath; keep at this temperature for 15 minutes, allow to cool and solidify while being shaken constantly. Before using melt and heat to 50°C.). If the ends of the bones are resected be sure that the lines of section are such that when the sawn ends of the femur and tibia are

approximated the patient will have a straight or slightly flexed knee without *genu valgum.*

Close the wound with or without drainage. Apply large dressings. Immobilize on a posterior splint. Elevate the limb to an almost vertical position for 24 or 48 hours. If a tourniquet has been used do not remove it until the dressings and splint have been applied.

Bony anchylosis of the knee in faulty position may be treated by osteotomy above or below the knee or both above and below, or by arthroplasty.

Arthroplasty.—Before deciding on operation, one must note if the muscles which should move the knee are destroyed or insufficient; if the periarticular tissues are changed into a mass of scar tissue; if the disease

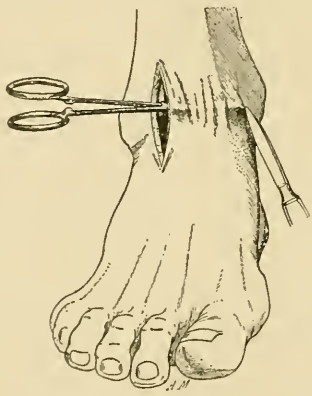

FIG. 440.—(*Labey.*)



FIG. 441.—(*Labey.*)

causing the anchylosis remains uncured; if the general condition of the patient is poor. Any of these conditions negative operation.

Murphy's Method.—Make an external longitudinal incision from a point 6 in. above to one 3 in. below the joint. Do not incise the deep fascia except where it is necessary to open the joint and overcome the anchylosis.

Make a 4 in. vertical incision over the inner side of the joint. Free the patella from the femur but do not divide the *ligamentum patellæ* or the quadriceps tendon. Thoroughly remove the lateral ligaments. With a chisel divide all bony anchylosis and sculpture the ends of the femur and tibia to more or less of their natural shape. Dissect downward a large flap of fascia lata *plus* a thin layer of muscle from the outer surface of the vastus externus. The flap must be long enough and wide enough to *completely* cover the sawn surfaces of the femur. Spread the

flap over the lower end of the femur and fix it in place with a few sutures. Place a smaller flap between the patella and the femur. Close the wound. Dress. Apply a posterior splint. Distract the joint by weight and pulley extension. Begin massage and very gentle passive motion after one week.

Ankle-joint.—*Arthrotomy.*—Arthrotomy for drainage of the ankle requires no particular description. Figs. 440 and 441 explain themselves.

Arthrectomy.—König's Method.—From a point on the anterior margin of the tibia about 2 in. above the ankle joint and immediately internal to the extensor tendons make a cut downward and forward over the inner side and neck of the astragalus to end in front of the prominence of the scaphoid.

On the outer side make a similar incision ending on the outer side of the cuboid at the level of the astragalo-scaphoid joint. Elevate the whole bridge of tissues between these cuts from the bones.

If the disease is tuberculous examine the joint, remove by dissection the anterior synovialis and, if a partial operation will suffice, remove any diseased bone with a chisel or sharp spoon. If a large focus is present in the astragalus, remove that bone and through the resulting gaping wound explore and excise any further disease. If, before the astragalus is excised, it is evident that the malleoli ought to be removed, proceed as follows: through the incisions already described introduce a broad chisel and cut a thin shell of bone from the superficial surface of each malleolus. These shells of bone are left attached above by their periosteum, below by the lateral ligaments. Retract the shells of bone and excise the remainder of the thickness of the lower ends of the tibia and fibula. Remove any diseased tarsal bones.

Close the wounds after providing for drainage or filling the cavity with Mosetig's plug. Press the mobilized shells of bone slightly inward. Dress. Immobilize. As anchylosis is desired, the after-treatment consists of rest until union is firm.

THE THORAX

SECTION XVII

THORACIC SURGERY

By

HOWARD LILIENTHAL, A.B., M.D., F.A.C.S.

AND

JOHN C. A. GERSTER, A.B., M.D., F.A.C.S.

ANATOMY AND PHYSIOLOGY OF RESPIRATION, FORCED RESPIRATION, DIFFERENTIAL PRESSURE—ITS APPARATUS[1]

Respiration consists in the gaseous exchange between an organism and its environment. In mammals there is both external and internal respiration.

External respiration consists in the absorption of oxygen and elimination of carbon dioxide which takes place in the lungs between the air in the alveoli and the blood in the pulmonary capillaries.

Internal respiration consists in a similar exchange in the capillaries of the systemic circulation between the blood and the tissue cells.

The Thorax as a Closed Cavity.—The thorax is a cavity entirely shut off from the outside and from the abdominal cavity. In this cavity lie the lungs and various viscera such as the heart, thymus and other mediastinal structures.

The lungs may be considered as two large, membranous sacs, whose interior communicates freely with the outside air through the trachea and glottis, while the outside of the sacs is protected from atmospheric pressure by the walls of the chest. The atmospheric pressure on the interior surfaces of the lungs expands these structures under normal conditions until they fill that part of the entire thoracic cavity not occupied by other organs. However, as the size of the chest cavity varies with respiration, that of the lungs must change accordingly; so that at all times the lungs fully fill up every part of the cavity not otherwise occupied (Fig. 440). If the wall of the thorax is opened at any point so as to make communication with the outside air, or if the wall

[1] In this section only a brief review of the most important physiological and anatomical facts can be made. For fuller details the reader is referred to Howell's Physiology, from which most of the facts in this synopsis have been taken.

of the lung is pierced so that the air can communicate with the pleural cavity from the inside, then the lungs promptly shrink in size, since the atmospheric pressure is then equalized on the outside and the inside of the sacs.[1]

The normal position of the thorax is that position present at the end of a normal expiration. Starting from this position, any enlargement of the thorax constitutes an *active inspiration*, while any diminution of the thorax from this position constitues an *active expiration*. After active inspiration or expiration, as soon as the muscles relax, the elasticity of the thorax will cause it to return to the normal position. Such a return naturally evokes a passive expiration after active inspiration, and conversely, passive inspiration after active expiration. The elasticity of the distended abdominal wall and expanded lungs are also factors in this elastic recoil.

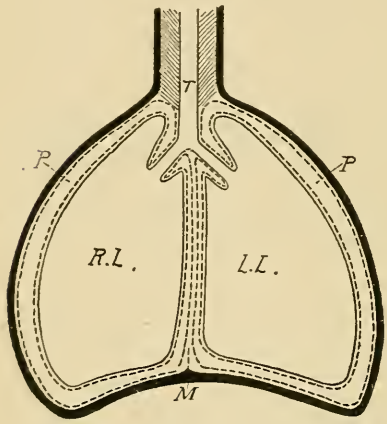

Fig. 440.—Schema to indicate the relations of the parietal and visceral layers of the pleural sacs, and the position of the mediastinal space: *P*, the potential pleural cavity in each sac; *M*, the mediastinal space: *R.L.* and *L.L.*, the cavity of the right and the left lung, respectively; *T*, the trachea. The outlines of the pleura on each side are represented in dotted lines. (*Howell.*)

The Normal Respiratory Movements Consist of an Active Inspiration Followed by a Passive Expiration.—*Inspiration is produced* by (1) contraction (descent) of the diaphragm, and by (2) elevation of the ribs, by levatores costarum, intercostales externi, scaleni, sternomastoidei, pectorales minora and the serrati postici superiores.

The muscles of expiration may be divided into two groups: those of the abdominal wall (recti, obliqui and transversales), whose contraction causes the diaphragm to ascend into the thorax, provided the glottis is open, and the depressors of the ribs (intercostales interni, triangulares sterni, intercostales lumborum). The serrati postici inferiores and quadratus lumborum are so placed that they may depress the ribs. It has been suggested (not actually proven) that in forced inspiration they antagonize the tendency of the diaphragm to pull the ribs inward.

As said before, *normal breathing* is an active inspiratory and a passive expiratory movement.

[1] See remarks on pneumothorax, page 707

Difficult or labored breathing presents a sharp contrast to this. As soon as the breathing movements become at all forced, the action of the above-named inspiratory muscles is increased in intensity, and the other inspiratory muscles, all elevators of the ribs, come into play. Quiet breathing, in man at least, is mainly diaphragmatic or abdominal, while dyspnœic breathing is characterized by a greater action of the elevators of the ribs. When dyspnœa reaches a certain stage, the expiration also becomes active or forced. The expiratory act is hastened by a contraction of the abdominal muscles or of the depressors of the ribs, and indeed, the action of these muscles may compress the chest beyond its normal position, so that the expiration is followed by a passive inspiration which brings the chest to its normal position before the next active inspiration begins.

Accessory muscles of inspiration are those controlling the size of the glottis and alæ nasi.

Terms.—By *vital capacity* is meant the quantity of air that can be breathed out by the deepest possible expiration after making the deepest possible inspiration. An average figure for the adult man is 3700 cc.

Dead Space.—Since the reserve supply of air in the lungs may amount to 2600 cc., while the new air breathed in at each inspiration amounts to only 500 cc., it would seem at first that the alveolar air is not very efficiently renewed by a quiet inspiration. The actual amount of ventilation effected depends on the capacity of the bronchial tree, sometimes known as the "dead space" of the lungs, since the air filling this space is not useful in the respiratory processes.

It is estimated that one-sixth of the total lung tissue is sufficient to sustain life.

Intrathoracic Pressures.—The *normal negative pressure* varies between 4.5 mm. Hg. and 7.5 mm. Hg., readings taken at the end of expiration and inspiration respectively.

With the glottis firmly closed, the intrathoracic pressure may be lowered 30 to 80 mm. Hg. by a strong inspiration while it may be raised 60 to 100 mm. Hg. by a strong expiratory effort, such as we see in straining or coughing.

The *increased pressure* from the compressed air in the lungs is felt upon the organs in the mediastinal spaces. The large veins especially are affected, and the flow in them is partially blocked, as is shown by the swelling of the veins in the neck outside the thorax. The maintenance of such conditions for a considerable period may seriously affect the circulation.

These temporary phenomena become permanent when obstruction to the great veins in the mediastinum is due to stenosis or to pressure from tumors or effusions.

Forcible inspirations with the glottis open may lower the intrathoracic pressure 30 mm. Hg.

The negative pressure in the thoracic cavity naturally has its effect upon the mediastinal contents, especially upon the veins.

The large veins in the neck and axilla are under the pressure of one atmosphere exerted through the skin, and the same is true for the inferior cava in the abdomen. But within the thorax the superior and inferior cavæ and the right auricle are under a pressure of less than one atmosphere. This difference in pressure must act as a constant condition favoring the flow of blood to the heart. At each inspiration, blood is "sucked" from the extrathoracic into the intrathoracic veins. So far as the inferior cava is concerned, this effect is augmented by the simultaneous increase in abdominal pressure, for, as the diaphragm descends, it raises the pressure in the abdomen as it lowers the pressure in the thorax.

The respiratory center is situated in the medulla. Carbon dioxide is the true stimulant of the respiratory center—not lack of oxygen. Within wide limits the respiratory center is indifferent to excess or lack of oxygen.

The following comprises the barest outline of Mosso's theory of acapnia[1] adopted by Yandell Henderson. The exaggerated breathing of pain withdraws an undue amount of carbon dioxide; there is apnœa, and death may occur from lack of oxygen. In other words, the heart will fail from *lack of oxygen* if there is not enough carbon dioxide to excite the respiratory center. To prevent this, a mixture of both oxygen and carbon dioxide is employed to inflate the lungs when shock is present.

That Henderson's theory of acapnia does not explain all aspects of surgical shock is well summarized in editorials in The Journal of the American Medical Association, Feb. 8, and March 29, 1913, and by A. R. Short, British Journal of Surgery, July 19, 1913, p. 114, also by Janeway and Ewing, Annals of Surgery, Feb., 1914. (See also remarks on Differential Pressure below.)

Dyspnœa.—By the term of dyspnœa in its widest sense we mean any noticeable involuntary increase in the force or rate of the respiratory movements. Such a condition may be caused either by stimulation of the sensory nerves, particularly the pain nerves, or by increased venosity of the blood. The dyspnœic movements naturally show many degrees of intensity corresponding with the strength of the stimulus, and sometimes the initial stages are designated as *hyperpnœa* while the term dyspnœa is reserved for the more labored breathing in which the expirations are active and forced.

[1] Yandell Henderson, Am. Jour. Physiol., Nov., 1910.

Apnœa.—This is a cessation of breathing movements due to lack of stimulation of the respiratory center. It may be brought about by rapid and prolonged ventilation of the lungs.

Death from Asphyxia.—*The ordinary symptoms described are from anoxæmia—that is, lack of oxygen—not from the accumulation of carbon dioxide.*

Death from increased percentages of carbon dioxide is not preceded by convulsive movements as seen in lack of oxygen, but appears as a fatal narcosis.

Innervation of the Bronchial Musculature.—It has been demonstrated[1] that the bronchial musculature is supplied through the vagus with motor and inhibitory fibers, bronchoconstrictor and bronchodilator fibers, as they are usually called. Stimulation of the constrictors causes a narrowing of the bronchi, and therefore increases the resistance to the inflow and outflow of air.

The pressure changes in the thorax are registered upon the sensory nerve endings in the bronchial mucosa, and reach the central nervous system through the main trunk of the vagus. The variations in pressure, positive and negative, evoke corresponding changes in the vagus tone.

By **pneumothorax** is meant gas, usually air, in the pleural cavity. This may come from an opening in the thoracic wall, respiratory tract or œsophagus. When infectious material comes into contact with the pleural surfaces, an exudate promptly appears. The condition when gas (air) and serum are present in the pleural cavity is termed hydropneumothorax—pyopneumothorax if the effusion is purulent.

Unilateral Pneumothorax.—If a wide opening be made in one side of a healthy thorax, the lung collapses around the structures at its hilum; there is extreme dyspnœa, to which is quickly added intense cyanosis; there is deep shock; the pulse is full and slow, respiration also slow and deep; finally there is cessation of both pulse and respiration. It is said that left pneumothorax is more poorly borne than right.

With *bilateral pneumothorax*, convulsive efforts at forced respiration are rapidly followed by death from asphyxia.

If *adhesions* are present, they will prevent the complete collapse of the lung. There is then a partial pneumothorax.

Influence of Various Factors in Production of Pneumothorax.—*The size of the opening* in the thoracic wall is of much importance.

[1] Acc. to Walther, Deutsche Zeitschr. f. Chir., Bd. CXIX, p. 253.

(*a*) If the opening in the pleura is smaller than that of the glottis, only small amounts of air can pass through the opening. During inspiration there is still negative pressure on the affected side (Fig. 441*a*), and during expiration there is positive pressure on both sides (Fig. 441*b*).

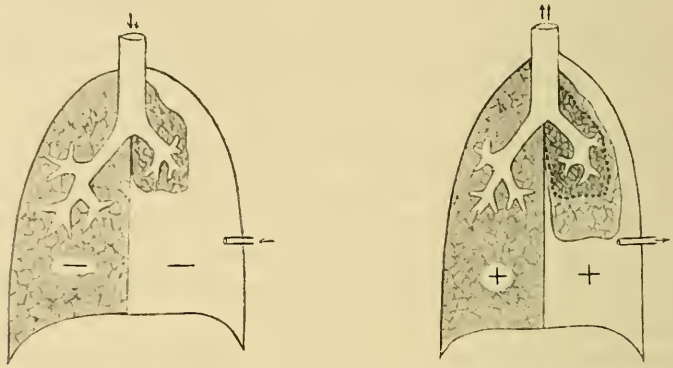

(*a*) Inspiration. (*b*) Active expiration.

FIG. 441.—Respiratory mechanism in pneumothorax with small opening. (*Garré.*)

Hence the mediastinum will not deviate to one side or the other. A small amount of air from the sound side will slightly distend the partially collapsed lung.

(*b*) If the opening is large, the lung promptly collapses and the mediastinum is drawn over to the unaffected side during inspiration

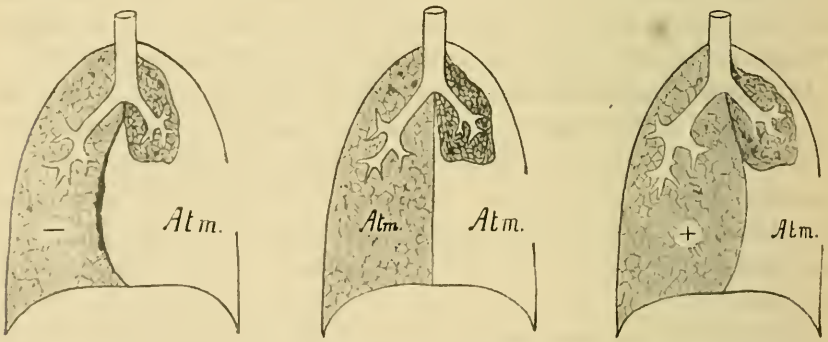

(*a*) Inspiration. (*b*) Normal expiration. (*c*) Forced expiration.

FIG. 442.—Respiratory mechanism in pneumothorax with large opening.

(Fig. 442*a*), and pushed over to the opened side during expiration (Fig. 442*b*); in other words, there is both insufficient inspiratory and expiratory movement of the sound side.

When the mediastinum is rigid, as in empyema, this mediastinal

fluttering does not usually occur upon opening the chest wall for drainage. The prevention of this mediastinal motion is of the greatest importance. The mere steadying of the mediastinum by seizing its wall with a forceps, or by drawing upon it using the lung as a tractor, suffices. The alarming symptoms promptly subside. By laying the patient upon the affected side, the weight of the heart and lungs steadies the mediastinum, the air rushes out, if the opening is adequate, and the last of it is expelled by straining or coughing. Of course laying the patient upon the sound side will give rise to a recurrence.

Molecular cohesion of moist pleural surfaces, especially between base of lung and diaphragm, is another factor which opposes collapse of lungs when an opening in the pleura takes place.

Tension Pneumothorax (*"Spannungspneumothorax"*).—When a valve-like opening is present which admits air with each inspiration and allows none to escape in expiration, the pleural cavity is gradually pumped full of air, pressure steadily rises, as in large exudates, with displacement of the mediastinum to the opposite side.

The gas in a closed pneumothorax is eventually absorbed. Oxygen of the air is rapidly absorbed—nitrogen much more slowly.

Differential Pressure.—For most operations upon one side of the chest differential pressure is a convenience, not a necessity. Steadying the mediastinum by traction on the lung or postural treatment is usually all that is required.

For operations upon the heart, œsophagus, or mediastinum, differential pressure is absolutely necessary, because of the possibility of bilateral pneumothorax through the accidental wounding of both pleuræ.

The present forms of differential pressure apparatus are too complicated and cumbersome; the general tendency is toward simplification.

A brief consideration of the various methods may be introduced by the remark that their theoretical differences have slight practical importance.

1. **Negative Pressure Cabinets.**—Here the patient's body lies in a cabinet while his head projects through its wall (Fig. 443). An air-tight collar prevents leakage. Negative pressure within the cabinet prevents collapse of the lungs when the thorax is opened.

Objections: (1) Cramped space for operator and assistants; (2) usually poor ventilation; (3) impossibility of transporting the apparatus; (4) cost.

2. **Positive Pressure Apparatus.**—(*a*) *Cabinets.*—The arrangements are just the opposite of those in the negative pressure cabinets, for the head lies within a cabinet in which positive pressure is maintained while the body lies in the open air (Fig. 444).

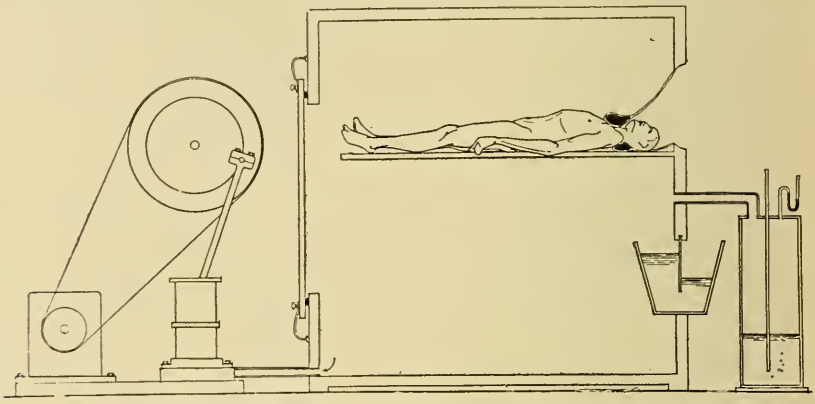

FIG. 443.—Negative pressure cabinet (patient's head outside).

Small positive pressure chambers, just large enough to contain the patient's head and anæsthetist's hands, have the objection that should vomiting occur its control would be difficult. Chambers large enough

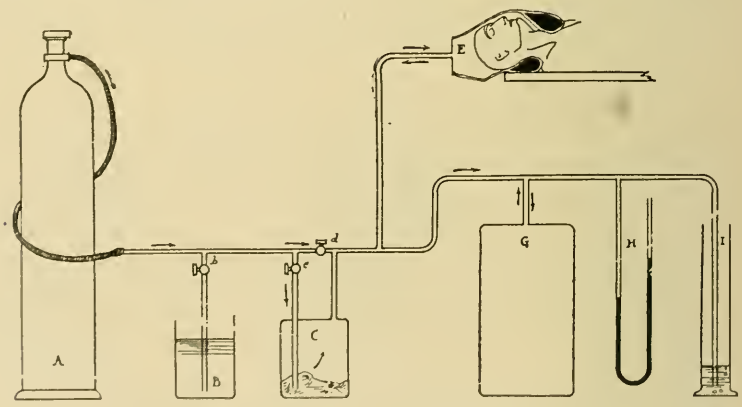

FIG. 444.—Positive pressure cabinet (patient's head inclosed—body outside).

to hold the anæsthetist as well as the patient's head do not have this disadvantage (Fig. 445).

Willy Meyer's universal cabinet consists of two chambers, one within the other. The smaller one (positive pressure) accommodates the anæsthetist and the patient's head; in the larger one (negative pressure)

are the operator and assistants and the patient's body. Here control in cases of vomiting is excellent. *Objections:* Cost; lack of portability.

(*b*) *Masks* of which the best example is Tiegel's, have the advantage of portability but the disadvantage that vomiting necessitates removal of the mask with consequent cessation of differential pressure. As a

FIG. 445.—Positive pressure cabinet large enough to accommodate anæsthetist. (*German Hospital, New York City.*)

matter of fact, however, vomiting rarely occurs under this type of narcosis.

(*c*) *Intrapharyngeal Anæsthesia.*—Zaaijer (Zentralblatt f. Chir., 1913, p. 1737) has found that in dogs it was perfectly feasible to maintain positive pressure by means of tubes introduced into the pharynx through the nostrils. The air escaped through the gap between the soft palate and the epiglottis. The respiratory movements continued, although both sides of the chest were opened. A sound could be passed into the esophagus without disturbing the air pressure.

Upon an anæsthetized patient with the tubes in place, it was found that with the mouth closed, air escaped through a water safety valve during expiration; while with the mouth open, a positive pressure of 6 mm. of water could easily be obtained. In other words, it was not necessary to introduce the intratracheal tube in every case in which positive pressure was desired.

Here it is important to mention the recent devices of Dr. Karl Connell of the Roosevelt Hospital, New York. His so-called anæsthetometer[1] will deliver into the patient's pharynx or trachea mixed air and ether vapor in regulated quantities and proportions. Thus we may supply air sufficient for respiration with just enough ether to maintain light and even anæsthesia (Fig. 447).

Surgical anæsthesia depends on the establishment in the blood and tissues of a definite ether tension, corresponding to about 15 per cent. of ether vapor in the alveolar air. This the Connell machine maintains with nicety.

(*c*) **Intratracheal Insufflation.**—With the patient in general narcosis a tube smaller than the trachea (say 24 French) is introduced down to the bifurcation, (26 cm. from front teeth) then drawn back 3 cm.; air escapes up the trachea alongside of the tube.

Advantages: (1) Minimal amount of ether. (2) Safety from vomiting (the current of air returning up the trachea absolutely prevents material in the pharynx from entering the air passages). (3) Cheapness. (4) Portability.

Objections: (1) Difficulty in the introduction of the tube especially in alcoholics and individuals with short thick necks. (2) Danger of rupture of the lungs or stomach because of the plugging of a bronchus by the tube or its introduction into the œsophagus. Both types of accident have actually happened with apparatus in which no safety valve had been provided.

DETAILS OF INTRATRACHEAL INSUFFLATION ANÆSTHESIA

Apparatus.—Source of Air. A number of engines are on the market. The one we have been using was devised by Dr. Charles A. Elsberg of New York (Fig. 446). The full description will be omitted; but in every apparatus there must be: an air pump, an air filter, a manometer, a safety valve of ample size which releases at 20–30 mm. of mercury, and an auxiliary foot or hand bellows.[2] *No operation under intratracheal anæsthesia should be commenced until one is sure that the auxiliary bellows is in perfect working order* (see Figs. 446 and 453).

[1] Connell, Surg., Gyn. and Obst., August, 1913, p. 245.
[2] Air tanks with reducing valves have been tried and abandoned.

There should be tubes of woven silk like the straight woven catheter. The diameter of the tube should not be more than half that of the trachea. From 22 to 24 French will be satisfactory in most cases. The catheters made for the purpose are marked with a ring 12 cm. from the tip, the distance of the glottis from the teeth and another ring 26 cm. from the tip, the distance of the bifurcation from the teeth. The catheters are to be chilled in a pan of ice.

There should be a direct laryngoscope with proper electrical connection (Figs. 448 and 449).[1] According to Jackson (Surgery, Gynecology and Obstetrics, October, 1913), the patient, previously narcotized by the ordinary inhalation method, should lie upon his back, the head being hyperextended (Fig. 450). The anæsthetist, holding the speculum in the left hand and standing to the left of the patient's head



Fig. 446.—The Elsberg apparatus for intratracheal insufflation anæsthesia.

(Fig. 451), introduces the spatular end of the instrument over the dorsum of the tongue. With the right index-finger the patient's upper lip is at the same time drawn aside so as not to crush it between the speculum and the teeth. When the epiglottis is seen, the tip of the instrument is guided over it and is then lifted upward with a motion as if to suspend the head of the patient by the tip of the speculum. It is most important *not to use the teeth as a fulcrum,* in fact, one must regard the speculum not as a lever but as a retractor. The proper motion lifts the hyoid bone and exposes the opening of the larynx. The excursions of the vocal cords should be plainly visible. Under guidance of the eye, a chilled catheter held in the right hand is now

[1] Those intending to make use of the method should practise introduction of the tube in cases in which there is no actual need for intratracheal anæsthesia. No harm can come from intelligent experiment in the ordinary run of surgical patients.

passed through the chink of the glottis down into the trachea.[1] As soon as the tube has entered the trachea, there is a peculiar, characteristic, hollow, spluttering breathing.

The speculum is now removed and the tube introduced further until it meets with an obstruction, the bifurcation; it is then withdrawn about 3 cm. A small rubber coated clamp secures the catheter (Fig. 452) and at the same time prevents its being bitten by keeping the teeth separated. The pumping apparatus should now be connected with the catheter; should there be a little delay here, it will do no harm, since the patient may still be narcotized by inhalation narcosis if necessary without disturbing the catheter. Should the patient react before the pumping engine is connected, he may phonate, but this does not mean that the tube is not in proper position (Fig. 453).



Fig. 447.—Connell's anæsthetometer. Blowing apparatus on shelf.

As soon as the engine has been connected, the patient's epigastrium should be exposed to make sure both by inspection and by percussion that the stomach is not being distended. Rupture of that organ has actually occurred through the tube's being introduced into the œsophagus by mistake.[2] Air escaping with a belching sound is the signal for immediate withdrawal of the tube.

Shallow breathing or even apnœa with deep narcosis in spite of a low manometer reading indicates too large a tube, while a light anæsthesia with high pressure suggests that the tube is too small. Once a minute or even oftener, the air current should be turned off for a few seconds to permit collapse of the lungs.

[1] Some operators find it possible to introduce the catheter into the larynx without the aid of direct vision, using a guiding tube for the purpose; moreover, if one has long fingers and the requisite skill, the introduction may be performed without instruments. This is easiest in children; however, the method is unsafe except in the hands of the most expert.

[2] This deplorable accident occurred in another clinic. In the early days of the method at our own clinic a rupture of pulmonary tissue from too high pressure took place. There was a subcutaneous emphysema extending up to the patient's eyes; eventually the air was absorbed without ill effect. Nowadays such accidents are guarded against by ample safety valves which promptly release at 25 to 30 mm. of mercury.

At the conclusion of the operation the ether may be turned off while air is permitted to flow for a few minutes; this quickly clears the lungs of anæsthetic vapor and causes the patient to arouse with great rapidity.

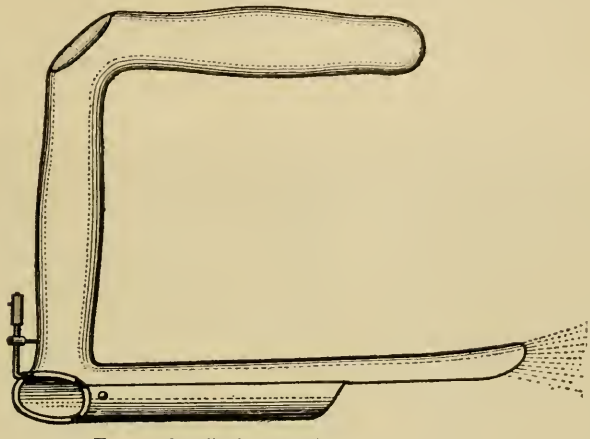

FIG. 448.—Jackson's direct laryngoscope.

The disadvantage of all forms of differential pressure apparatus consists in the obstruction to the intrathoracic circulation, especially in the pulmonary veins and capillaries. Janeway and Ewing have shown that the carbon-dioxide content of the blood had very little to do with the

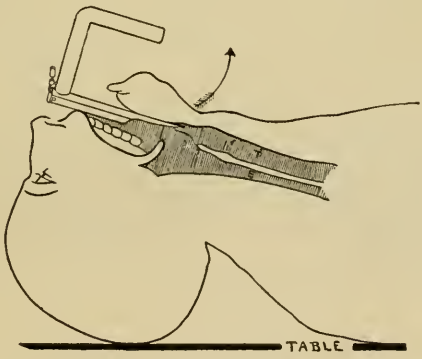

FIG. 449.—Same *in situ*.

production of shock; in other words, the shock produced by hyperrespiration was not lessened or prevented by maintaining the normal balance between the oxygen and carbon-dioxide content of the blood.[1] Formerly it was believed that the diminished amplitude of the respira-

[1] Very few physiologists have accepted Henderson's adoption of Mosso's theory of acapnia.

tory movements in differential pressure permitted a steady, almost imperceptible accumulation of carbon dioxide; to prevent this the air current was interrupted at intervals of a few seconds, thus imitating in a crude fashion the alternate expansion and collapse of the lungs in normal respiration. It was observed that the animals did much better under this treatment (or when the pressure was slight enough to permit of voluntary respiratory movements) than when simple inflation of the

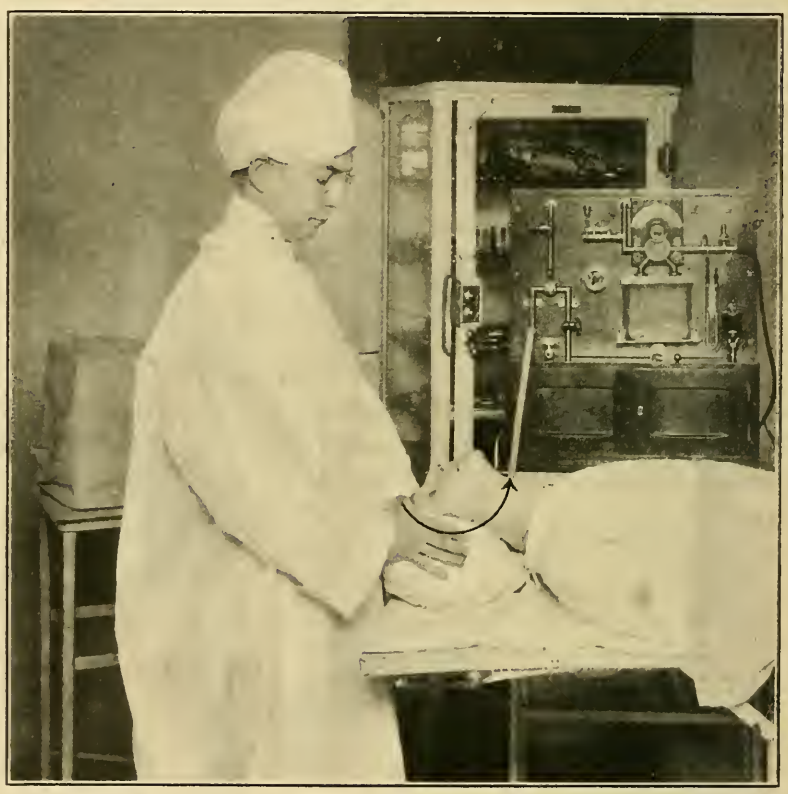

Fig. 450.—Hypertension of head previous to introduction of Jackson direct laryngoscope. (*Jackson.*)

lungs by a steady stream of air held them immobile. We now realize that the benefit derived from intermittent collapse of the lungs is due to the momentary relief it affords from circulatory obstruction.

In normal respirations there is a greater degree of obstruction to the flow of blood in the lung capillaries after long deep inspirations than after small shallow ones.[1]

[1] Cloetta's article in Pflüger's Archiv. f. d. ges. Physiol., Bd. CLII, p. 339, 1913, gives an exact account of the influence of pulmonary elasticity upon pulmonary circulation.

In operations of short duration this factor is of no consequence but in longer operations it is of the utmost importance. Heart failure has come on as late as a week or 10 days after operation.

Some of the Boston surgeons have observed the following: when the pulse becomes poor in the course of a lengthy operation, if work is suspended and the chest temporarily closed, the circulation picks up again. The operation is then resumed, to be again discontinued

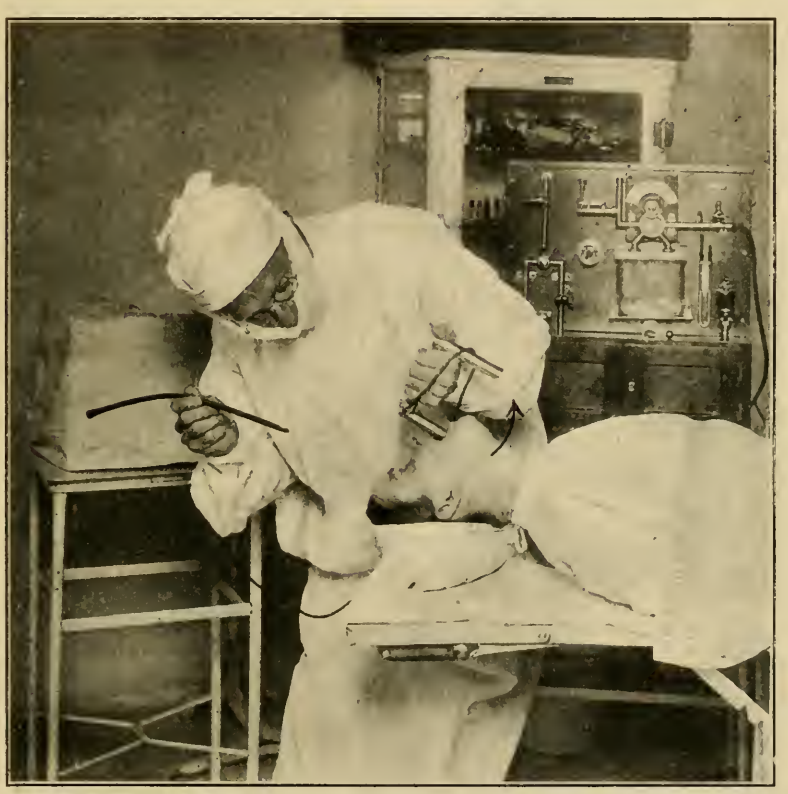

FIG. 451.—Direct laryngoscope *in situ* (see also Fig. 449); intratracheal tube about to be introduced. (*Jackson.*)

when the pulse becomes poor. Apparently the temporary closure of the chest removes, to a large extent, the obstruction which the use of differential pressure sets up in the capillary circulation of the lungs.

Garré, Willy Meyer and others all realize that in operations of long duration under differential pressure certain unknown factors exist and that these must be sought in order to enable us to work with intelligence.

Garré says: "There is no doubt that long operations under differential pressure are accompanied by dangers which so far have not been

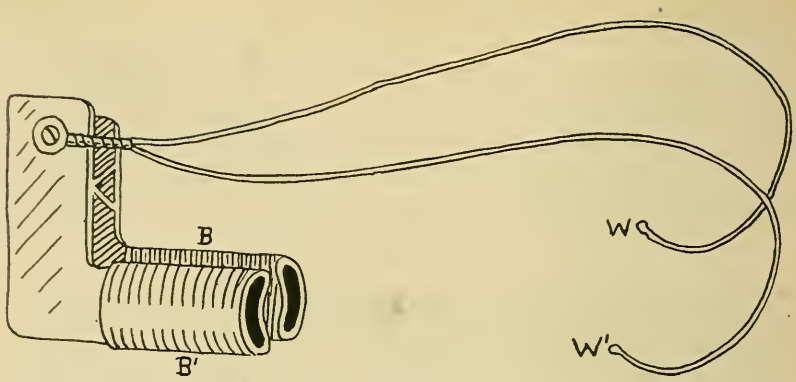

FIG. 452.—Elsberg's clip for holding the intratracheal tube in place. The rubber covered arms *BB'* lie between the teeth and hold the tube between them. The wires *WW'* fit over the ears like the wires of spectacles.

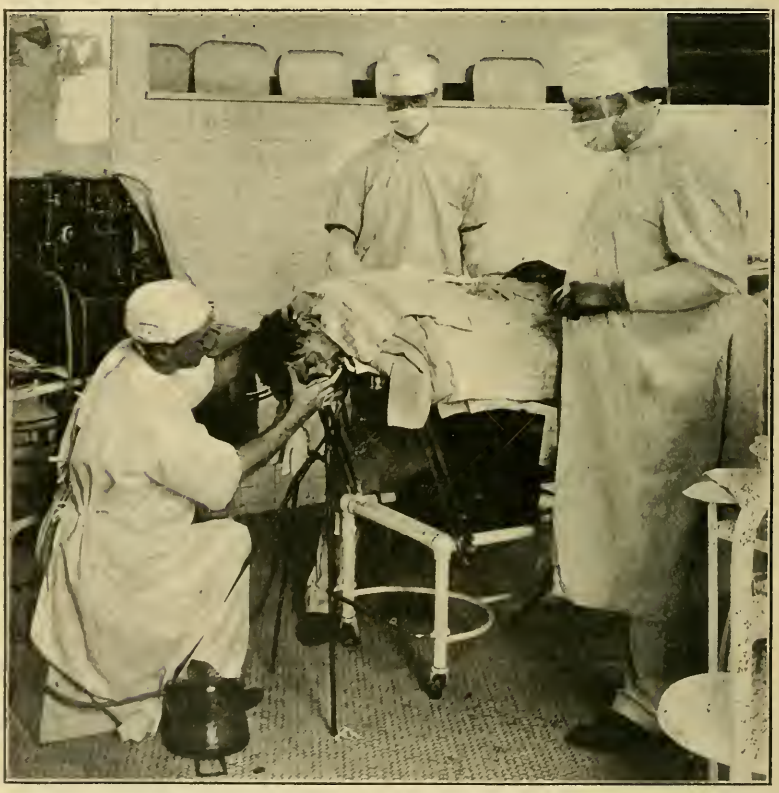

FIG. 453.—Intratracheal anæsthesia just before operation is begun. (In this instance patient is lying face down.) Note auxiliary foot bellows (at anæsthetist's feet) connected and instantly available in case of failure of the motor. Elsberg machine in background. (*Jackson.*)

accorded proper recognition. Many operators must have had the experience that after a long operation under differential pressure, death occurred either toward the end of the operation or shortly after its conclusion and that this fatal outcome could not be attributed to narcosis, hemorrhage or aspiration. Ignorance of the cause of death has led these cases to be classified as 'fatal shock.' The blood pressure sinks steadily, the pulse rate is lowered while respiration is unaffected."

TRAUMATA OF THE CHEST

Contusion of the thorax implies more or less injury to the intrathoracic organs with little or no injury to the chest wall. In rupture of the lung in children, the thoracic walls often remain intact because they are so elastic. Closure of the glottis at the time of impact predisposes to rupture of the lung. In certain chests the sternum may touch the vertebral column without fracture and without breaking the ribs.

Pneumothorax may follow any severe contusion of the chest. Laceration at the root of the lung—usually the anterior aspect—is to be feared when there was deep inspiration with closed glottis at the moment of impact.

Ecchymosis due to hemorrhages from the jugular distribution follows strong compression of the thorax from without while the glottis is closed. It has been known as Perthes' disease because Perthes has written much on the subject. The ecchymoses are found over the entire head and its contained cavities and the hemorrhages may extend to the upper part of the thorax. The exact cause of the condition is a matter of controversy. The prognosis is favorable. Articles dealing with this condition have been written by C. ten Horn in the Archiv. Klin. Chir., Bd. 106, p. 82, and by Lange in the Deut. Zeit. f. Chir., CXX, 1 and 2. To both these articles voluminous bibliographical references are appended. Lange calls attention to the medicolegal importance in differentiating the phenomena from those of strangulation. The autopsy findings have much in common. Intraocular and cerebral hemorrhages are rare because of the normal counterpressure of intracerebral and intraocular tension.

By *concussion of the thorax* is meant a condition following an injury to the chest in which nothing, even in the fatal cases, is found to account for the grave symptoms. At the time of the injury it may be impossible to differentiate concussion from contusion, the subsequent course of events alone revealing the true state of affairs.

Fractures of the Ribs.—Koenig has compared fracture by direct violence to a stick broken across the knee, while fracture by indirect violence has been likened to a stick whose two ends have been approximated until it broke near its center. Thus by direct violence the rib is made convex toward its inner side until it breaks (Fig. 454). The outer surfaces are impacted while the inner surfaces gape. Most lung and pleural injuries from broken ribs follow direct violence. Indirect violence increases the natural outward convexity of the rib until it breaks (Fig. 455). The inner aspect is impacted while the outer gapes. Rupture of lung tissue, if present, is usually at some other point than near site of fracture.

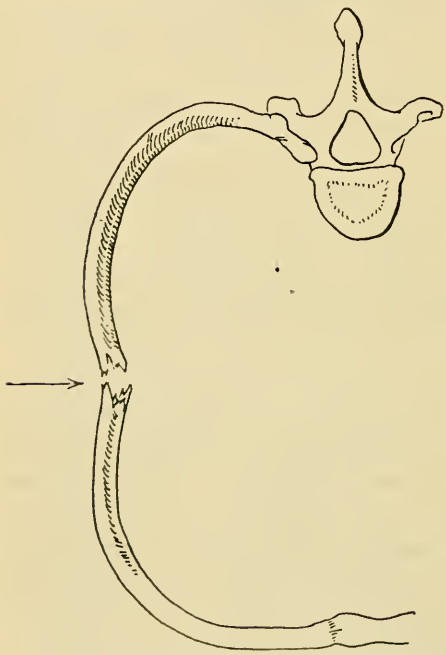

Fig. 454.—Fracture of rib by direct violence; rib made convex toward its inner side at site of trauma until it breaks.

The treatment of uncomplicated fracture of the ribs consists in immobilization by strapping with adhesive plaster. Complications accompanying fracture of the ribs (emphysema, hemothorax, pneumothorax, etc.) will be referred to in discussing penetrating wounds of the thorax.

Laceration of the lung is due to the *violence causing* fracture of the ribs, not usually to the fragments themselves. As before mentioned, laceration of the lung may occur without fracture of the thoracic wall.

Fractures of the sternum and costal cartilages follow direct violence. Their reduction may be effected by placing the patient in a position of extreme thoracic opisthotonos; this is particularly useful in fracture of the sternum. Messner (*cit.*, after Paget) threw cold water into a patient's face, and as he gasped reduced the displaced ends of a broken costal cartilage. Many fractures of costal cartilages or sternum cause no serious inconvenience. Open operation is indicated only when there is great distress.

Wounds of the Thorax.—1. Non-penetrating wounds. (*a*) Aseptic wounds require a dry compressive dressing (see also *gunshot wounds*).

(*b*) Infected wounds, especially stab wounds, should be laid open without delay to prevent the rapid spread of suppuration along the fascial planes.

Auto-transfusion of Extravasated Blood from the Thoracic or Abdominal Cavity.—The practical point whether auto-blood-transfusion is feasible after extravasated blood has been harbored some time in the cavities of the body may be affirmatively answered. Its continued presence eliminates coagulation (auto-hemolysis) and the retransfer of the blood to the same individual does not dispose to either thrombosis or ferment intoxication.

Technic.—The blood in the thorax or abdomen is scooped up with a large metal spoon coated with paraffin. The blood is filtered through paraffined gauze, and collected into a paraffin-coated flask in a water bath at body temperature. If much blood is available the pure blood itself is used; otherwise Ringer's solution is added as a diluent. To obviate possible coagulation sodium citrate 2 per Mille is added. The blood is then injected intravenously with the aid of a Percy (Chicago) glass tube. (Ruck-transfusion des Koerpereignen Blutes bei den schweren Massenblutungen der Brust and Bauch hoehle, Prof. Henschen, Zurich, Sauerbruch Klinik. Zeit. f. Chir., 1916, p. 201. An extensive bibliography accompanies this paper.)

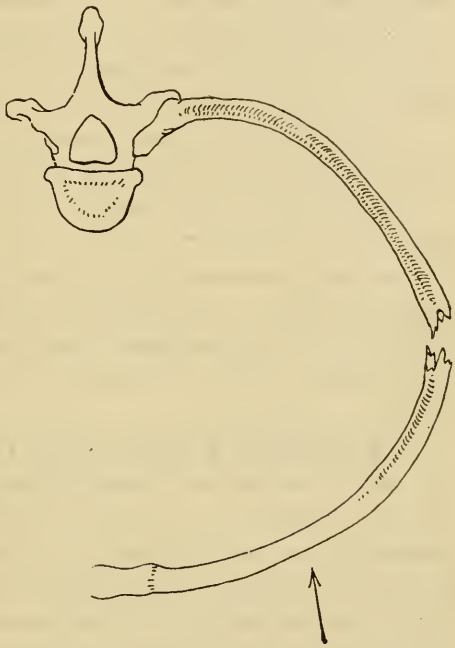

Fig. 455.—Fracture of rib by indirect violence; increase of natural outward convexity until breaking occurs.

Epinephrin Intratracheal Stimulation.—An editorial in the Journal of the American Medical Association, LXVII, p. 816, on the work of Auer and Gates, calls attention to the possible value of epinephrin injected with a fine hypodermic needle into the trachea just below the cricoid cartilage as a valuable stimulant in desperate cases in which on account of great cardiac weakness the veins are not easily accessible for intravenous medication. Three to 5 cc. of the fluid are used at one dose.

Gunshot Wounds.—Many so-called "contour wounds" are in reality straight paths through the soft parts at the moment of injury which become crooked channels upon change of position. Usually the wound of entrance is in the nipple region, and the wound of exit or the subcutaneous location of the bullet is in the back. Their direction depends on the position of the patient's arm, the tension of the muscles and the direction of the bullet. Many lung wounds heal without reaction. The wound of entrance is small, the wound of exit is large. Wounds made at close range, of which in times of peace self-inflicted wounds (suicide) are the most common, show powder burns.

It is safe and wise in all gunshot wounds to give a prophylactic injection of tetanus antitoxin, provided the patient has not received a horse-serum injection within the previous month.

Wounds of the internal mammary artery are usually accompanied by perforation of the pleura; hence the bleeding is inward.

Wounds of the intercostal arteries may be grouped under the same heading. Before the days of differential pressure, numerous devices were proposed for effecting hemostasis by pressure upon the bleeding points. They should all be discarded on account of their uncertainty. The treatment in all cases is to enlarge the wound, resecting adjacent ribs if necessary to expose the bleeding points and to ligate.

2. **Penetrating Wounds of the Thorax.**—It is often impossible to tell which organs have been injured. In the majority of cases not only the lungs but also the diaphragm, abdominal organs, heart, pericardium or mediastinum are wounded. The recent researches of Lawrow[1] show that in stab wounds of the thorax which presented slight symptoms, the mortality of non-operative treatment was 14 per cent. while those cases presenting grave symptoms, in which operation was especially indicated because of the probability of wounds of other organs beside the lung, gave a mortality of 36 per cent.

Simple *wounds of the pleura*, if located over the thickly muscled part of the thorax, may not give rise to pneumothorax. Wounds near the sternum where the layer of soft tissues is thin are more apt to gape, thereby determining a pneumothorax. Naturally, lung adhesions may partially or completely prevent the occurrence of a pneumothorax.

Injury to the *lung* may cause pneumothorax, hemothorax, or both.

(*a*) Hemorrhage from wounds of large pulmonary vessels is rapidly

[1] Lawrow, Bruns. Beitr. z. klin. Chir., LXXVI, p. 545.

fatal. Wounds of smaller vessels will cause the gradual development of a hemothorax with symptoms of internal hemorrhage.

(*b*) Pneumothorax.

1. The air which has escaped from small superficial wounds of the lungs may be absorbed within 24 hours.

War Surgery of the Chest.—During the present European conflict much has been observed and there has arisen a considerable bibliography. A standardization of treatment, however, has not yet been formulated.

We have noted a tendency to temporize and to avoid radical surgical procedures. From a fairly extensive civil experience in these cases we believe that so-called conservatism is probably carried too far. We believe that with proper attention to the anæsthesia, to the maintenance of increased air pressure within the pharynx or trachea and with the help of a powerful rib-spreading retractor cases of gunshot wounds of the thoracic viscera may be treated by radical surgical repair with a decided improvement in mortality statistics and in the time of disability.

Seelig, reviewing the conclusions of Balfour J. Hull (M. J. Seelig, Surg., Gyn. and Obst., September, 1916, p. 368) concludes that there is a trend to conservatism in the treatment of thoracic wounds in contrast to the increasingly radical treatment of abdominal injuries. He notes, however, many suggestions in favor of early or late operative treatment, especially when hemothorax is present.

The cases resolve themselves roughly into two important groups: first, those in which the injury is obviously so serious that the patient is non-transportable; and second, those in which transportation is possible. Naturally it is only in the latter that extensive operations are admissible. Don (Brit. Med. Jour., June 10, 1916), has found that in some of these cases collapse of the lung and washing out of the clot is possible in advance dressing stations and small field hospitals. He states that the motions of the diaphragm prevent spontaneous hemostasis by intermittent suction upon the bleeding vessels. He therefore proposes collapse of the lung by a temporary opening and at the same time he washes out the clot. Infection is rare. The operation is performed in general or local anæsthesia. A small stab wound is made in an intercostal space, a tracheotomy tube is guided along the knife and the knife is then withdrawn. The inner tube is now inserted or a soft catheter may be used to facilitate evacuation. The lung collapse minimizes the tendency to hemothorax. The trachea tube is turned

so that its inner end points upward and the tube should be removed at the end of 24 to 48 hours according to the amount of blood lost.

In an article on penetrating wounds of the lungs and pleura Rudolf (J.A.M.A., LXVII, 908) believes that air entering the chest from without is more likely to create infection than is the air from injured lung. He calls attention to the well-known fact that a hemothorax may result from an injury to the parietal vessels. While small collections of blood which are not infected may disappear spontaneously, operation is absolutely indicated in infected hemothorax and in all extensive lacerations with the presence of projectiles. Piery (Lyon Medical, May, 1915) reports on 53 cases of penetrating thoracic wounds associated with hemorrhage and calls attention to the fact that pneumonia follows. Delayed resolution and relapse are especially noted. He treated his cases medically by rest, ipecac and digitalis. He defers the extraction of bullets as long as possible but would operate in the presence of infection.

In 107 cases of thoracic wounds produced by all varieties of fire arms, Howard, of Iowa City (J.A.M.A., LXVI, 2030) has had a mortality of but 7 per cent. He has divided his cases into the following groups: First, those without physical signs. Second, those with simple pneumonia or serous effusion. Third, those with complicating mediastinitis. Fourth, infected hemothorax.

The physical signs frequently suggested consolidation on account of the large amount of fluid compressing the lungs. Cardiac dyspnœa was frequent and pneumonia on the opposite side was noted. Secondary hemorrhages were rare. There were three cases of fibrinous pericarditis and one of pneumo-pericarditis. He treated the infected cases by free drainage and the uninfected ones by aspiration and oxygen replacement.

It is our opinion that in doubtful cases a long intercostal incision with the application of the rib-spreading retractor will permit of free exploration and probably in many cases of radical repair of visceral injury. In recent cases, before adhesions have formed, some form of intrapharyngeal or intratracheal positive pressure anæsthesia is necessary.

Stab wounds of the chest involving the diaphragm are considered by C. C. Green (J.A.M.A., LXVII, 178). He reports six cases of his own with two fatalities. The injury to the diaphragm was encountered during the progress of operation for the relief of intrathoracic hemorrhage. He quotes Magoula's statistics of 20 per cent. mortality in the

uncomplicated cases and 64 per cent. in the complicated ones. One-hundred and ninety cases were collected showing the prevalence of diaphragmatic hernia in 92 per cent. on the left side.

Intercostal Diaphragmatic Hernia.—Wolf discusses injuries of the thorax and diaphragm (Deut. Zeit. f. Chir., CIV, p. 69) dividing them into the percutaneous and subcutaneous varieties. The diaphragmatic injury should be approached by way of the wound when one exists but in the suspected subcutaneous injuries a surgical wound must be made and the author believes that statistics favor the transpleural over the transperitoneal route, the mortality in the former being 5.2 per cent., of the latter, 28.5 per cent. Transpleural operation also has the preference assigned to it by Neugebauer with 9.6 per cent. and 50 per cent. respectively. These operative wounds of the pleura should be closed without drainage after the injury to the diaphragm has been repaired.

The treatment of thoracic wounds was discussed at the Reunion Medico Chirurgical de l'Armee and was reported in the Journal of the American Medical Association, LXVI, 1562. Maisonstet pointed out that three important symptoms of thoracic injury are asphyxia, hemorrhage and sepsis. Asphyxia is rarely observed because it is so rapidly fatal. In hemorrhage hemoptysis occurs in 6 per cent. of the cases. Pneumothorax is frequent, parietal hemorrhage rare. Infection arises from projectiles or from additional lesions. Encysted fragments caused late infections in 8 per cent. of the cases. At the wounds of exit there are frequently fractures of the ribs. The general line of treatment is absolute immobilization with the administration of morphine, ergotin and emetin, at the first-aid station if possible. Transportation must be deferred until shock disappears. Camphorated oil and subcutaneous saline are good stimulants. Progressive pneumothorax calls for puncture but puncture is contraindicated in non-progressive or fixed pneumothorax. After the eighth day the slow withdrawal of fluid is less dangerous than in the early days following the injury.

Surgical Treatment.—Thoracotomy.—Infections generally show themselves between the eighth and the twelfth days. The seventh day is considered favorable for operating in the case of bullet wounds and the fifteenth day in shrapnel injuries. Fuster stated that he believed thoracic wounds were benign in comparison to abdominal injuries and has seen good results from medical treatment chiefly with emetin, 0.03 grams a day for eight days. The patients should be sent to the ambulance station at the rear.

Picqué called attention to a class of benign cases in which there is

recovery without clearly defined pleuro-pulmonary symptoms or after spontaneous regression following slight effusion. The cases most commonly seen are the completely perforating bullet wounds and the completely perforating shrapnel injuries complicated by pneumothorax and pyothorax.

Treatment.—Puncture or Pleurotomy.—In 48 cases of pneumothorax 31 recovered following repeated puncture while 17 required pleurotomy. The presence of bullets or other projectiles is so likely to provoke septic infection that their extraction should be undertaken.

Burkhardt and Landois (Gunshot Wounds of the Thorax with Associated Injuries, Burkhardt and Landois, Muench. Med. Wochens., 1915, p. 1057) consider particularly shots of the tangential variety. The term is borrowed from the tangential gunshot wounds of the skull, the term being opposed to the rarer diametric shots.

Tangential shots are subdivided into those having a gutter wound of the soft parts with fracture of the ribs and those with a tunnelization of the skin and fracture of the ribs. Infection is greater in tangential shots because the cellular plains are more extensively injured and the fractured ribs badly comminuted. In the diametric (penetrating) wounds the injured lung is relatively immune to infection. In tangential shots the destruction of the ribs favors an open pneumothorax and eventually empyema. The mechanism of respiration is damaged because of extensive injuries and consequently bilateral pulmonary complications are secondary in a larger number. In tangential shots adjoining viscera of the abdomen are affected by indirect violence. These injuries are lacerations or hemorrhages of the organs. Tangential shot wounds of the lower half of the thorax are important because of the proximity of the abdominal contents. Both pleura and abdomen may be injured by the same projectile.

Moynihan (Brit. Med. Jour., March 4, abstracted in J.A.M.A., LXVI, 1167) in dealing with thoracic gunshot wounds believes in the thorough exploration of large penetrating injuries. He considers Dakin's solution best for subsequent irrigation. (The writers of the present article, from experience with Dakin's solution in recent surgical wounds of the chest, have concluded that it is too irritating to be used in these circumstances although in chronic suppurative pleurisy not connected with the bronchial system there is no objection to its use. If the irritating chlorine gains access to the lumen of the smallest arteriole dangerous spasmodic coughing is set up.) Moynihan emphasizes the value of the outdoor treatment of septic patients of this

class. He also shows that vaccines are unavailing in the absence of free drainage but that they are helpful when drainage is adequate. He is convinced of the value of streptococcus vaccine and predicts better results with its freer use. He also approves of treatment locally with Wright's solution.

Projectiles in the Lungs and Their Extraction.—Marquis makes rœntgenography his important point in determining the method of procedure. If it is evident that adhesions are present he prefers fixation of the lung to the chest-wall so as to avoid the extension of infection. In the absence of adhesions he exteriorizes the lung, operates and closes the chest without drainage, the pneumothorax being spontaneously and rapidly absorbed. In five cases the projectile was extracted. In one case extraction had to be abandoned because the body was located in a greatly retracted lung, and in another instance a shell fragment was firmly adherent to the pericardium and was therefore not removed (J.A.M.A., LXVII, 1314).

Mintz (Ruski Vratch, XV, No. 4, reported in J.A.M.A., LXVI, 1434) removed two bullets from the pericardium, one from the lower lobe of the lung, one from the pleural cavity. He does not believe that intrathoracic adhesions constitute a contraindication to successful operation. Suppuration and death followed in two instances in which bullets were not removed from the lung.

Pauchet prefers regional and paravertebral anæsthesia in operations for the extraction of projectiles from the lungs (Presse Medical, Nov. 20, 1916, XXIV, p. 513).

In the matter of local anæsthesia Couteaud and Bellet (Bull. de l'Acad. de Med. Paris, July 18, LXXVI, No. 29) are also favorably impressed after an experience of 30 cases in which projectiles were extracted from the lung. They state that pneumothorax can be better controlled and that the shock is minimized, that ribs may be resected without dread of pneumothorax. In eight of their cases there had been no adhesions and the projectile was extracted after anchoring the lung to the chest-wall. They advise flooding the field of operation with mild antiseptic.

Hemothorax.—Unterberger, in the Deut. Med. Woch., 1915, p. 187, treats of wounds of the lungs. He concludes that bullet wounds of the lung are less dangerous than shell wounds because fragments of shell are more apt to become lodged in the tissues. His report covers 63 cases and one bayonet wound. He believes in the conservative expectant treatment of hemothorax, even trying to avoid puncture to relieve

pressure. He admits, however, that occasionally puncture is necessary and that it aids in a timely recognition of empyema.

J. R. Bradford (reported in the J.A.M.A., LXVI, 774, No. 10; originally reported in the Lancet, Jan. 29, 1916) has something to say on hemothorax. His opinion is that 25 per cent. of the cases are infected and that in 20 per cent. of these the infection is from the lungs, and in 80 per cent. from the exterior. He believes that repeated exploratory puncture is necessary to make the diagnosis. He also calls attention to alarming symptoms which sometimes occur suddenly after a preceding period of appârant well-being, these symptoms being suggestive of secondary hemorrhage. Post-mortem examination in such cases showed that the gas bacillus infection was the true cause. The treatment is by early drainage.

Pneumothorax due to anaerobes is apt to be mistaken for ordinary pneumothorax. Pneumonia and pericarditis are complications. If we are to reduce the mortality in these cases recognition and drainage must be prompt.

Dr. Jas. H. Kenyon (Ann. Surg., December, 1916, p. 728) reports a case of traumatic hemothorax complicated with subcutaneous emphysema cured by syphon drainage, the special feature of which is the air-tight fit of a small (¼ in.) drainage tube, introduced into the chest through a minute incision in the fifth interspace. The tube is of one piece and is long enough to terminate below the level of sterile water in a bottle beside the bed. The tube was removed on the third day because no more fluid was discharged. The patient was well in 16 days.

In the discussion Dr. W. S. Schley referred to his (Am. Jour. Med. Sc., 1908) application of this method in empyema of non-traumatic origin. He used the Politzer bag to secure aspiration and thus made this an ambulatory method of treatment.

Ad. Schmidt, in the München. Med. Woch., 1915, p. 873, has had experience with the method described by Torck (see Oxygen Replacement During Aspiration, in this article) and is favorably impressed by it. In the case of hemothorax several sittings are employed. Stepp, in the same Journal, p. 1043, fears to employ the method because in one case complete pneumothorax followed its application.

2. Wounds of the bronchi. Here with each respiration air is pumped into the thorax. A valvular action of the lips of the wound prevents escape of the air. If the air escapes into the pleural cavity, as the pressure steadily increases, the mediastinum is pushed over to the opposite side, as in the case of large effusions. This condition is called

by the Germans, "*Spannungspneumothorax*," that is, tension pneumothorax. If there is a wound of the parietal pleura, the air escapes under pressure and spreads under the skin, giving rise to subcutaneous emphysema. On the other hand, if air from a wounded bronchus escapes into the cellular tissue of the mediastinum, it compresses the structures contained in the mediastinum. Then there are signs of the most intense distress; extreme dyspnœa, shallow respiration and deep cyanosis of the face and neck with enormous swelling of the veins which stand out like cords in the neck. The air appears in the neck at the episternal notch with the crackling of subcutaneous emphysema and spreads from that point to the head and over the rest of the body (see Figs. 469, 470, and 471). The pulse, which at first is slow and full due to vagus irritation, later becomes irregular, small and frequent.

From the foregoing we see that a tense subcutaneous emphysema always indicates injury to the lung (König). Moreover, the emphysema associated with extreme dyspnœa and oppression is not the cause of the symptoms, but with these is itself a symptom of pneumothorax. If emphysema is moderate and does not progress, it is of no significance. (For treatment of mediastinal emphysema see below.)

For the discussion of the symptoms and physical signs of pneumothorax the reader is referred to works on internal medicine.

Hemoptysis is significant of lung injury. The spasmodic cough, which the patient tries to control, may arise from irritation of the parietal pleura or of the respiratory mucous membrane.

Treatment.—*Rupture of the Lung.*—The indications are very difficult to make. Many apparently hopeless cases recover under expectant treatment; others die. The prognosis in such exsanguinated patients is very bad, for one cannot be sure of finding or controlling the hemorrhage at operation.

Expectant treatment of thoracic contusion, compression, or penetrating wounds. Absolute quiet for from two to six weeks, no talking, no movement of the patient, plenty of morphine and a light diet, constitute the essentials. No transportation should be permitted. If the patient is moved from his house to the hospital, the unavoidable jarring may turn the tide against him. Clean penetrating wounds require dry compressive dressing; infected wounds, revision and drainage. (See also section on War Surgery, p. 723).

Palliative Treatment.—When great distress is present, aspiration should be performed. Withdraw just enough of the pleural contents

to relieve the symptoms. If the pleural cavity refills and the symptoms again become alarming, it may be worth while to repeat the aspiration. If a fracture of the rib is present and continuous aspiration is indicated because of tension pneumothorax, it is well to make the drainage opening over the site of fracture, thereby preventing further extension of the subcutaneous emphysema.

Fig. 456.—Intercostal incision for exploratory thoracotomy (low) or transpleural laparotomy. (*Sauerbruch.*)

Radical Treatment.—Should the character of pulse and respiration become worse, and the cyanosis and anæmia increase in spite of palliative treatment, immediate thoracotomy is imperative. The same indications hold for secondary hemorrhage.

Careful hourly observation is absolutely necessary to reach a correct determination whether to operate or not. The nervous symptoms immediately following injury such as pallor, dyspnœa, clammy skin and tremor, should not mislead one into unwarranted haste in operating.

Principles of Emergency Exploratory Thoracotomy (*see also general operative procedure*).—*Anæsthesia.*—General anæsthesia is indispensable for most intrapleural operations in order to eliminate the involuntary straining of the patient which accompanies any irritation of the parietal pleura during consciousness.

Incision.—It matters little how an adequate exposure is gained; whether by an osteoplastic flap, or by a large intercostal incision. There must be room enough to get at the lung, to withdraw it in part and to inspect its entire surface.

For injuries over the lower lobe, an intercostal incision in the sixth or seventh space (Fig. 456) with the aid of a spreader (Figs. 457–458) will usually give the best exposure in the least time.

To expose the region of the upper lobe, a curved incision with its convexity downward begins in front, about the second interspace,



FIG. 457.—Sauerbruch's rib spreader.

and sweeps around the chest below angle of scapula running up again parallel to the vertebral column. This allows the scapula to be swung

upward before incising the third intercostal space. A spreader (Figs. 457, 458, 485) is the most convenient means of maintaining retraction.

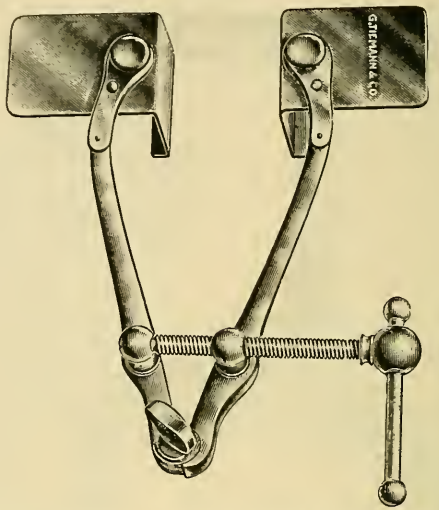

FIG. 458.—Lilienthal's rib spreader. Interchangeable blades of various sizes and shapes.

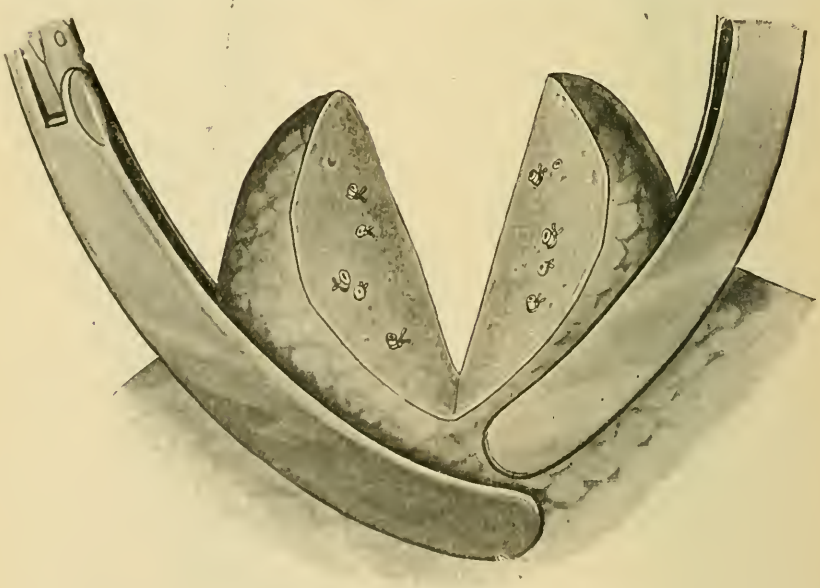

FIG. 459.—Temporary hemostasis obtained by application of flexible-bladed clamps to lung tissue. (*Sauerbruch.*)

One of the writers (Lilienthal) approaches the upper lobe through a 6th or 7th interspace incision carried upward from its posterior end along the

border of the Scapula. Section posteriorly of 3 or 4 ribs as in Torek's incision (see p. 767, Fig. 488) gives ample exposure.

FIG. 460.

FIG. 461.

FIGS. 460 AND 461.—Simple suture of lung. (*Sauerbruch.*)

Differential pressure (*e. g.*, intrapharyngeal forced anesthesia) is necessary because by its means the size of the lungs may be varied to suit the operator's convenience.



FIG. 462.

FIG. 463.

FIGS. 462 AND 463.—Suture to assure coaptation of serous surfaces. (*Sauerbruch.*)

The wounds of the lung are readily revealed by the bloody foam which appears. Wounds of the lung are seen best with the lungs

FIG. 464.—Garré-Talke method of lung suture.

partially distended because, on the one hand, the fully collapsed lung shows little or nothing while, on the other, only a small part of the fully distended lung is visible at the thoracic wound.

Upon *opening the pleural cavity* for rupture of the lung, much blood

escapes. Small wounds are readily closed by approximation of the serous coat with needle and catgut in a manner similar to intestinal suture (Fig. 460–461).

Large wounds are more difficult to close. Temporary hemostasis may be obtained either by:

(*a*) Compressing vessels at the lung hilum, with rubber ligature or soft clamp, or,

(*b*) By applying soft clamps to the lung tissue parallel to the mouth of the visceral wound (Fig. 459).

The torn edges of the wound are trimmed, and the mouths of vessels and bronchioles are ligated.

To avoid stitches tearing through the friable lung tissue, it has been found convenient (Tiegel) to pass heavy sutures of magnesium wire through the lung substance parallel to the margins of the wound. These act as stays for the transverse stitches, and assure

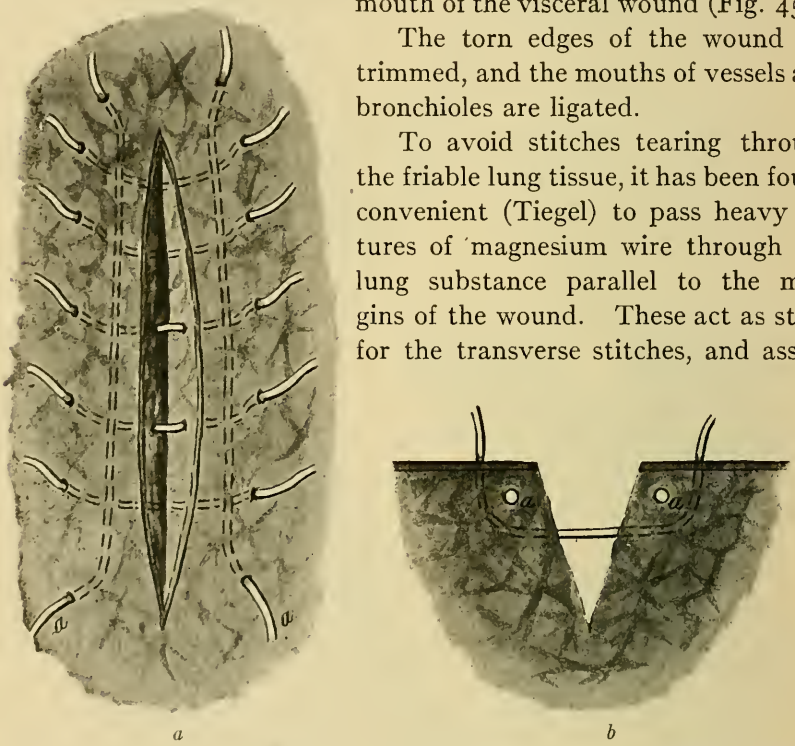

FIG. 465.—Tiegel's method: Magnesium wires are passed parallel to margins of wound; these afford support for transverse coaptation sutures.

coaptation of the deeper parts (Fig. 465). An approximation suture of the serous surfaces covers over the deeper tension sutures. Inflation of the lung is now permitted. Should small leaks occur, they are of no consequence. Do not attempt to close them, for the sutures will tear out, making the leak worse. Wounds of larger bronchi are closed with sutures which do not penetrate the mucosa; over this suture line, adjacent tissue is fastened as a reinforcement. (See also technique for treatment of bronchial stump under Pneumectomy.) The bronchi

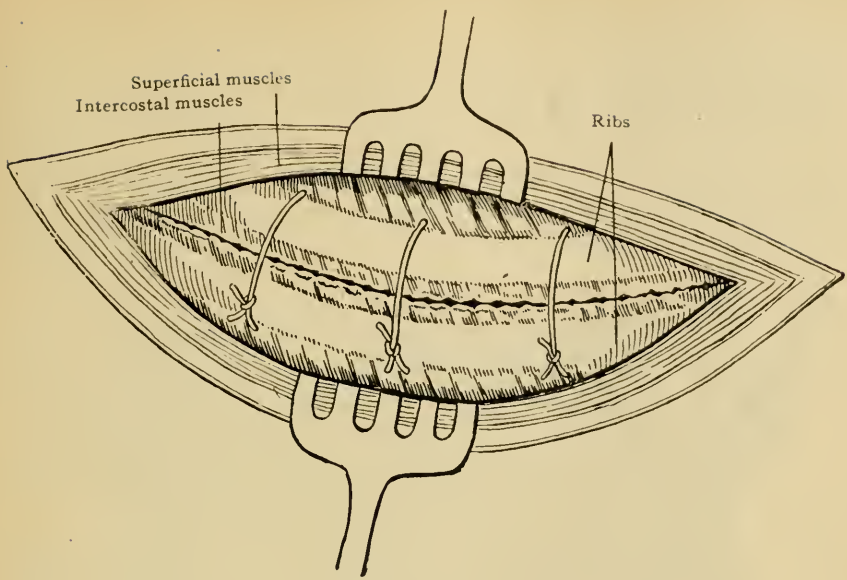

FIG. 466.—Pericostal suture. (*After Sauerbruch.*)

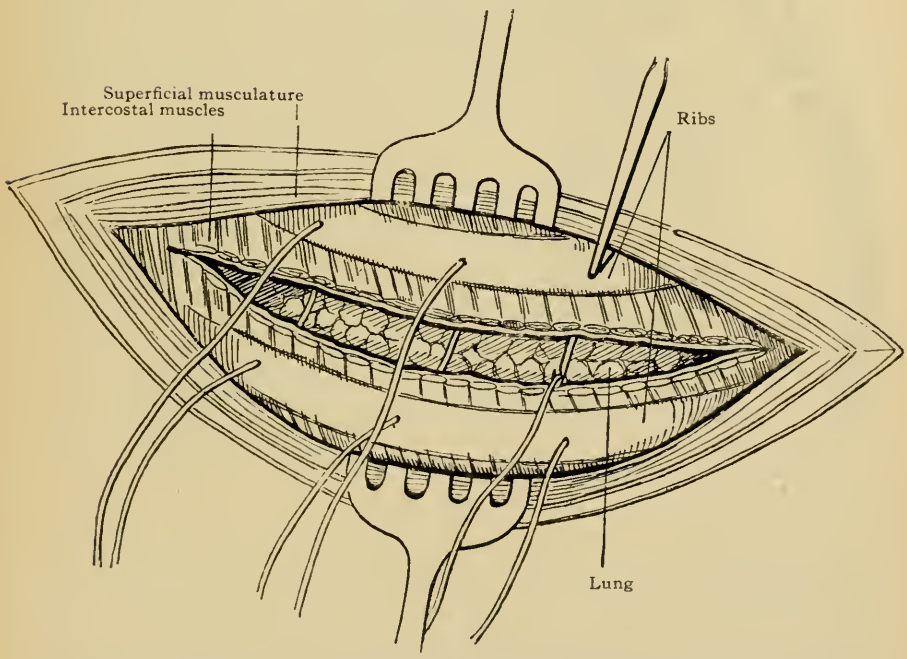

FIG. 467.—Percostal suture. Note fine hook drawing last suture through its hole in upper rib. (*After Sauerbruch.*)

lie posterior to the vessels, hence are more accessible from the posterior aspect of the lungs.

Special Remarks.—*Wounds of the lung near the hilum* may be difficult to treat. The chances of hemostasis without ligature are better here than in wounds of large vessels belonging to the general circulation, because the blood pressure in the lesser circulation is but one-third that of the greater. Tamponade with a piece of muscular or connective tissue from the chest wall maintained in place by one or two sutures, may be effective when ligation is not feasible. Tiegel's work clearly demonstrates how rapidly wounds of the lung heal. Within three days after infliction of large wounds, the lungs withstood 30–60 mm. Hg. pressure.

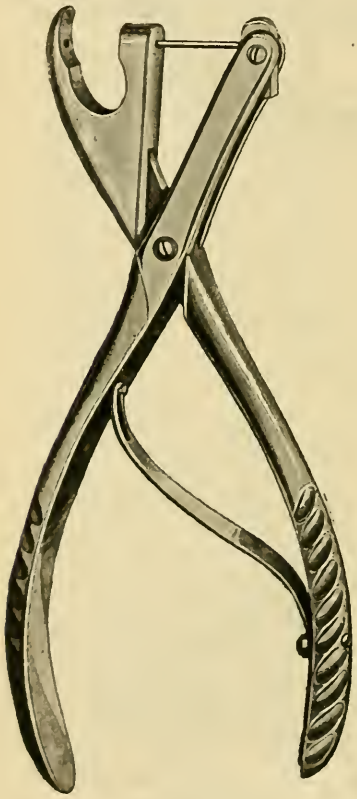

Fig. 468.—Friedrich's rib punch used in percostal suture (see Fig. 467).

Closure of Thorax.—Either pericostal (Fig. 466) suture or percostal suture (Fig. 467) must be used. In the latter, holes through the ribs can be rapidly made by Friedrich's special punch (Fig. 468). All sutures should be passed before tying is begun.

Just before the last sutures are tied closing the pleural cavity, the lungs must be distended sufficiently to fill the chest completely, thus expelling all air and avoiding the establishment of a post-operative pneumothorax. Experience has shown that the presence of air in the pleura after operation predisposes to infection probably more than any other factor.

Drainage is to be avoided when possible. It has been the frequent experience of most surgeons to find an effusion filling the pleural cavity within 24 hours after any extensive intrathoracic operation. This should be removed by aspiration. Repeated once or twice this will usually suffice to relieve the symptoms of oppression. *The application of positive pressure at the time of aspiration has been found to be of distinct benefit.* Unless severe infection occurs, the remainder of this exudate disappears within five or six days.

Naturally, if an empyema should develop, the usual drainage must be instituted. If there is undoubted infection, it is better to close the original wound completely and to drain through a counter opening. To avoid pneumothorax, drainage must be one of two types:

(*a*) Valvular drainage, which permits the pleural contents to escape, but checks the entrance of air. This requires frequent removal of fibrin which tends to clog the valve for the first 48 hours.

FIG. 469.—Mediastinal emphysema. Note extreme emphysema of trunk and head. (*Tiegel.*)

(*b*) Continuous suction drainage. This is easily improvised by using a tube which leads from the thorax to a wash bottle connected up with the ordinary household vacuum cleaner. Too great suction must be avoided, otherwise the mouth of the tube will be plugged by lung tissue, preventing the escape of secretions or of air. For further details of drainage see page 760 *et seq.*

Mediastinal emphysema may be treated by Tiegel's[1] method. A man had sustained five broken ribs and a ruptured lung. The emphysema of the trunk and head was extreme (Fig. 469). Tiegel made a 4 cm. incision down to the trachea in the episternal notch, and applied continuous suction by means of a glass bell placed over the wound (Fig. 470). Suction—30 mm. of water—was maintained for five days and the patient recovered (Fig. 471) without requiring any further treatment.

Transpleural Laparotomy.—When injury of the lung is complicated by wounds of the diaphragm, stomach, spleen or other organ,

FIG. 470.—Mediastinal emphysema. Some time after. Suction was continuously applied by means of a glass bell placed over 4 cm. wound reaching down to trachea. (*Tiegel.*)

an incision in the sixth or seventh intercostal space will enable the operator not only to repair a wound of the lung, or of the heart and pericardium, but also, by enlarging the wound in the diaphragm in the direction of its muscular fibers, he can reach and repair damage of the abdominal viscera. Thus Sauerbruch was able to remove a ruptured spleen with more ease by this route than by laparotomy. The greatest care must be taken to close wounds of the diaphragm in order to avoid hernia through that structure.

[1] Tiegel, Archiv f. klin. Chir., C. I. No. 4.

In transdiaphragmatic operations Henschen advocates the sensory blocking of the phrenic nerve by an injection of novocain rather than the permanent exclusion of the phrenic impulses by division or crushing of the nerve. The danger of pneumonia due to an immobile diaphragm following extensive operations must be borne in mind. One of the writers (Lilienthal) in a case of obstinate singultus apparently left sided in character, exposed the left phrenic nerve in the neck and

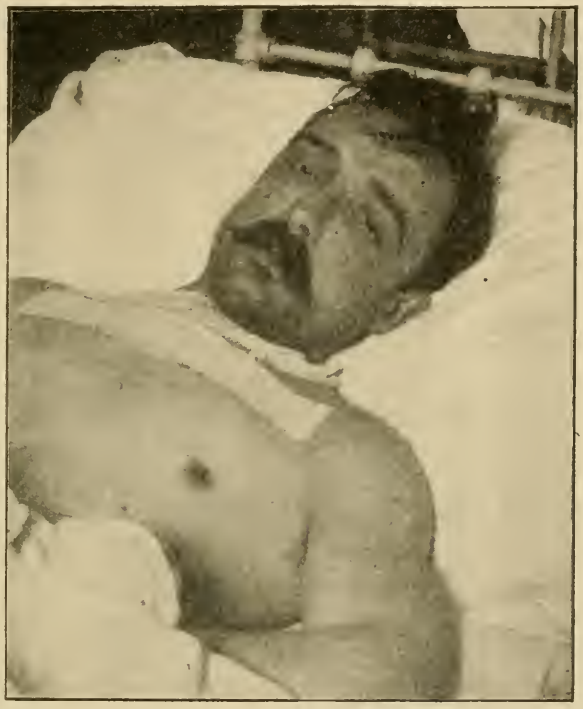

FIG. 471.—Mediastinal emphysema. Patient convalescent after 5 days of continuous episternal suction. (*Tiegel.*)

injected 95 per cent. alcohol into its sheath. Complete relief of the singultus followed.

Hernia of the lung indicates only a gap in the parietal pleura. It prevents pneumothorax. If the wound is aseptic the lung can be replaced and the pleura closed. The protruding lung may retract or if tightly constricted it may become necrotic. A pulmonary fistula is apt to develop when the necrosed tissue separates.

When plastic closure cannot satisfactorily be made, free transplantation of fascia, bone or periosteum is indicated.

Hernia of the lung is discussed by Joseph Auerbach (Deut. Zeit. f. Chir., 1909, bd. VII, p. 89). He adheres to the classification of Morell-Lavalle made in 1847. First, congenital; second, traumatic with (*a*) prolapse, (*b*) genuine hernia. The third form is called spontaneous. It is supposed to occur from a tear in the muscles or from some pathological cause intermittent or continuous. The diagnosis is made by exclusion. Small herniæ undergo spontaneous reduction and because of the absence of the strangulating symptoms peculiar to abdominal hernia the prognosis is on the whole more favorable than in the latter. The treatment is by strapping the chest with adhesive plaster. Old herniæ, however, are usually only partially reduced. Thoracoplastic operations may have to be performed. An extensive literature is given in this article.

Burns require no special mention. Those involving chest wall are usually very severe.

The scarring after such burns is very marked. Contractures of the axillary folds may require plastic operations. The Z method is very useful for correcting such deformity.

GENERAL OPERATIVE PROCEDURE

1. **The Preparation of the Patient.**—A careful comparison of physical signs, X-ray findings, and observation of the clinical course, must be made in establishing both the diagnosis and the operative indications. After this, *if conditions permit*, several weeks' time should be taken toward putting the patient into the best possible physical condition for his operation. Special stress should be laid upon bringing the cardiac efficiency up to the highest possible standard.

2. **Position of the Patient.**—For operations on the front of the chest the patient lies on his back; while for operations on the side or the back of the chest, he assumes a semi-reclining position, well side down. By placing a firm elastic pillow under the sound side just below the axilla, interference with respiratory movements is minimized (Fig. 472).

3. **Anæsthesia.**—(*a*) *Local anæsthesia* should be employed in all extrapleural operations. The German authors prefer ½ per cent. novocaine.

It is important to bear in mind the three well-known points upon the chest wall where the sensory branches of the intercostal nerves perforate:

(1) Close to the vertebral spines; (2) in the angles between the

insertions of the serratus magnus, (3) 2 cm. lateral to the edge of the sternum.

The procedure of blocking the nerves varies at different points in the thoracic wall. Thus at the angle of the ribs the needle should reach

FIG. 472.—Position for operation on side or back of chest. Note pillow just below axilla on sound (lower) side. (*Sauerbruch.*)*

the center of the intercostal space (see Fig. 473), since this corresponds to the location of the nerve trunk before its division; while in the axillary line from the same puncture opening, the needle must seek branches

* In the modern American tables the bridge is used.

along the upper and lower margins. Two intercostal spaces must be blocked for the resection of one rib.

Besides blocking the nerves it is necessary to infiltrate the soft parts of the operative field.

(*b*) *General anæsthesia* is absolutely required for all extensive intrapleural operations. The opening of the thorax in unanæsthetized patients has caused reflex cessation of the heart's action and invariably

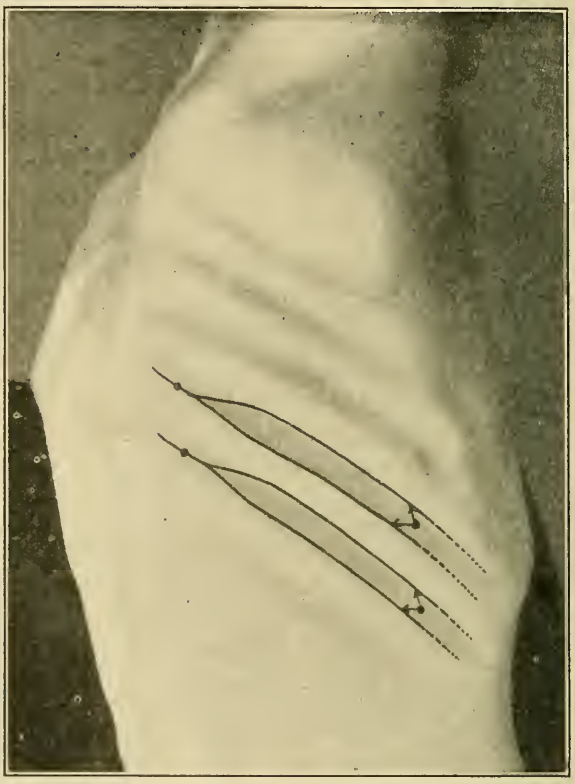

FIG. 473.—Local anæsthesia of thoracic wall. Dots (see text) indicate points for blocking intercostal nerves, at angles of ribs, in axillary line. (*Schumacher.*)

causes profound shock with corresponding lowering of blood pressure. Even with the greatest good will and fortitude of a conscious patient, handling of the pleura causes reflex spasmodic straining (the *Pressatmung* of the Germans). This increases the obstruction in the lesser circulation and throws much additional work upon the right ventricle.

Choice of the Anæsthetic.—Intrapharyngeal administration of ether is our preference (p. 712). Should the differential pressure mo-

mentarily cease for some reason or other, it is well to close the wound in the thorax with gauze compresses and manual pressure until the apparatus is started again.

The Operation.—The formation of osteoplastic flaps may be required in operating for tumors, echinococcus cysts, injuries and foreign bodies. Garré warns against removing ribs or costal cartilages from in front of the heart because of the danger of painful pulsating scars or adherent pericardium. From the average horizontal incision four ribs can usually be resected. The "vertical" incision (at right angles to the ribs) has the advantage that it may be extended in either direction. Simple intercostal incision (in the seventh space) often suffices for exploration (see above). A spreader is most convenient for keeping the wound open. Resection of the first rib will be described in discussing the operative treatment of lung affections.

Once within the thorax an operator is always impressed with the great difference between the appearance of the organs in life and as they are seen post-mortem. The vessels, especially the veins, are three times larger in life than they appear after death.

Shock.—As said elsewhere in this article, the utmost gentleness is indispensable for successful surgery within the thorax. In Flint's valuable contribution[1] it is shown that packing of the lungs or traction upon them, or ligation of the root of the lung promptly causes a fall in blood pressure, the degree of which is directly proportionate to the amount of force employed.

The opening in the pleura must be made slowly, under a differential pressure of 5 mm. of mercury. This allows the lungs partly to collapse. There is no danger to the patient's life. Bernard LePlay and Mantoux[2] have shown that one-sixth of the total lung capacity is sufficient to maintain life. The production of shock by long-continued differential pressure has already been mentioned, pp. 715, 717.

The operative treatment of lung injuries has been dealt with on p. 729. The drainage of lung abscesses, extirpation of one or more lobes, etc., etc. are treated on p. 775. Never irrigate the newly opened pleural cavity.

Drainage.[3]—Some effusion will occur after any extensive intrathoracic operation, probably from the unavoidable drying and handling of the pleura.[4]

[1] Flint, Jour. A. M. A., 1912, Vol. LIX, p. 760.
[2] Jour. de Phys. et de Path. Gen., Jan. 15, 1913, Vol. XV, No. 1.
[3] See also pp. 761, 1016, 1017, 1018 and 1019 for remarks on drainage.
[4] Carrel has used sheets of Chinese silk impregnated with paraffine oil or vaseline to protect the pleura.

Simple aspiration one or two days after operation usually suffices when no marked infection has taken place. The rest of the serous exudate is absorbed within a week.

It is most desirable to close the thorax completely and to avoid drainage whenever possible. Permanent drainage of an uninfected thorax is almost sure to be followed by infection; such infections have a very high mortality.

Three varieties of drain may be mentioned (see also p. 761): (1) The usual drainage tube whose mouth is covered by a thick layer of loose gauze; (2) some form of valvular drainage; and last, (3) constant suction drainage. The first of these does well enough for an ordinary well-encapsulated acute empyema. Valvular or constant suction drainage is essential to prevent pneumothorax in cases in which the lungs are not adherent.

Both these latter forms of drainage require constant intelligent care to insure their proper function. The drain frequently becomes clogged with fibrin or dried pus. The constant suction must not be too strong, otherwise the lung will be sucked tightly against the mouth of the tube, will plug it and the adjacent pleural surfaces will adhere. Retention is then sure to follow.

Transpleural drainage of liver abscesses and subphrenic abscesses requires no special remark except to mention that avoidance of pleural infection is the essential factor in this procedure. After pus has been gained by exploratory aspiration, the thoracic wall is mobilized over the particular region by resection of two or three ribs (about 3 in. of each). The costophrenic sinus is obliterated by taking deep sutures on a stout full-curved needle which grasps diaphragm as well as mobilized thoracic wall with each bite. This chain suture describes an oval with the puncture wound as its center. If possible, it is better to wait 6 to 12 hours before opening the abscess in order to allow of a firm agglutination of the sutured pleural surfaces.

Closure.—In discussing injury of the lung we stated that either pericostal or percostal suture could be used in closing the chest, and that post-operative pneumothorax should be avoided by maximally inflating the lungs just before the last suture is tied.

Post-operative pain is usually more severe after thoracotomy than after laparotomy, and requires morphine during two to three days. A firm elastic sustaining bandage which leaves the well side free is of great aid in lessening pain.*

* Adhesive plaster strips are valuable here.

THORACIC WALL AND MEDIASTINUM

A. **Inflammations.**—Furuncles and carbuncles are not of major importance except in the aged or diabetic; neither are acute phlegmons, except those in the subpectoral region.

Cold abscesses usually originate from tuberculous or syphilitic foci in the ribs, costal cartilages or sternum. These have been known to extend downward beneath or into the sheath of the rectus. It may be difficult to differentiate between lipoma and cold abscess, except by exploratory aspiration.

The treatment of cold abscess of the thoracic wall is identical with that suitable for superficial cold abscess in general.

Actinomycosis of the thoracic wall requires no special mention. (For details consult works on general surgery.)

Mediastinitis may follow infected wounds in this region. It is also observed after tracheotomy when the fascial planes of the neck become infected and the infection spreads downward, or after rupture of the œsophagus or lung. It is a condition which causes pressure upon the mediastinal structures, notably the veins, and gives rise to high fever and profound prostration. Acute mediastinitis is very often fatal no matter what treatment is instituted. Trephining the sternum and placing the patient in a prone position to facilitate drainage should be done to satisfy one's surgical conscience. Permanent suction drainage may be useful.[1]

Posterior Mediastinitis. Operation.—Gaudiani, in the Annals of Surgery, May, 1916, p. 523, reports ten cases of this interesting disease. Five of these were cured by an operation in the left side of the neck with blunt dissection passing down along the œsophagus. Two cases were cured by the combined neck and dorsal operation. Three of the patients died, two of them following the cervical and one following the combined operation. The dorsal operation consists of resection of ribs and sometimes even of transverse processes of the vertebræ with blunt displacement of the pleura. The dorsal operation is to be preferred in the case of infection located low in the mediastinum below the arch of the aorta from the fourth to the fifth dorsal down. All abscesses situated above the fourth dorsal may be successfully opened and drained through a left cervical incision although secondarily a dorsal mediastinotomy may be necessary. Abscesses originating in the superior part of the mediastinum have, according to Von Hacker,

[1] Lilienthal, Surg., Gyn. and Obst., May, 1915, p. 592.

little tendency to spread downward. Because of the lessened density of the cellular tissue above the heart infection easily migrates toward the neck.

B. **Tumors of the Chest Wall.**—(*a*) Of the benign tumors few require special mention. Lipomata have been known to extend beneath both the pleura and the skin, having a collar-button shape on cross section, the stem of the button lying between two ribs.

Enchondromata are most frequently encountered in patients between the ages of 30 and 40. The prognosis is doubtful because from the histology we cannot know whether any given tumor is benign or malignant.

(*b*) *Malignant Tumors.*—Primary sarcomata are rare. They are usually fibrosarcomata or chondrosarcomata.

Of secondary malignant tumors the most important are local recurrence in the chest wall after amputation of the breast for carcinoma. Both primary and secondary tumors have been known to become adherent to the lung after involving the pleura and to grow into the lung by direct extension.

Treatment.—Resection[1] of the chest wall well beyond the growth is the correct procedure in almost all cases. Mere size is no contraindication so long as there are no signs of secondary involvement of the mediastinum.

Technique.—In Parham's classic monograph[2] on tumors of the thoracic wall although he quotes (1) Muller's case where traction upon the tumor of a lung relieved the distress of pneumothorax (p. 53) and (2) Murphy's experiment of steadying the mediastinum with a forceps (p. 124), yet he himself merely advises suture of the lung to the opening in the thorax (pp. 125–126) apparently for occlusive purposes. By employing differential pressure and general anæsthesia the operation is made easy and safe. There is no shock upon opening the pleura. The soft parts are incised down to the ribs well away from the tumor. A convenient intercostal space is laid open, and the presence or absence of adhesions is ascertained. If they are not present, the ribs are divided at a distance from the tumor by means of a sharp bone shears until both incisions meet. An assistant compresses the bleeders. If the lung is involved, a wide section is cut out and the defect closed with suture.[3] After removal of the tumor, the bleeding vessels are

[1] The monograph of Lund of Boston, Annals of Surgery, Aug., 1911, brings this entire subject up to date.

[2] Transactions of Southern Surg. and Gyn. Society, 1898.

[3] See Repair of Lung Injury, under Traumata of Chest, p. 734.

caught and ligated. Closure of the defect is made by a suitable plastic of the soft parts. In primary carcinoma of the breast or local recurrences involving the chest wall, it is convenient to close the gap left after resection by using the breast of the opposite side, which is fashioned into a flap with its pedicle upward. The entire breast is

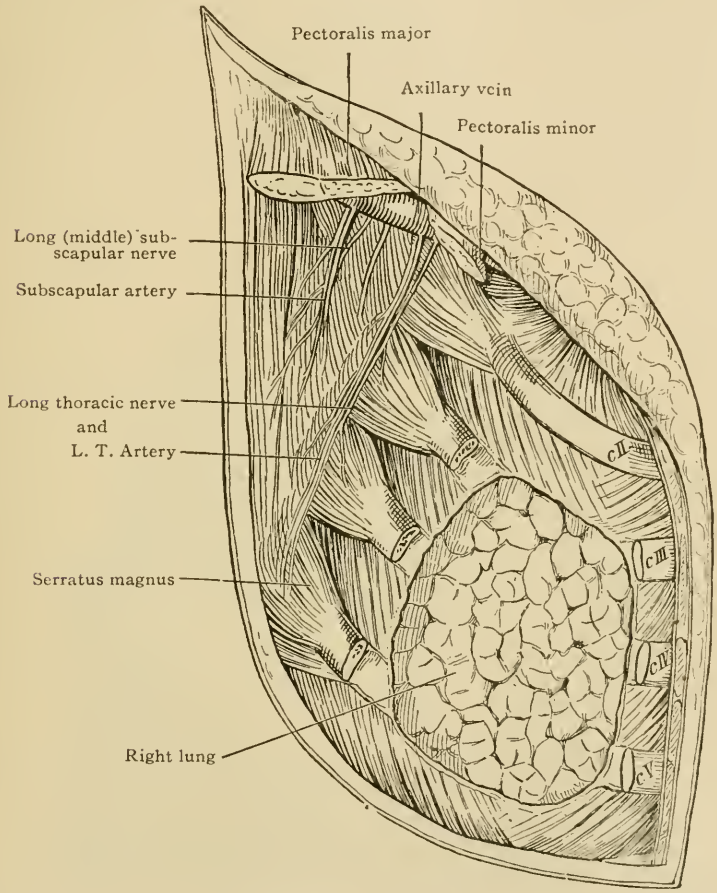

FIG. 474.—Defect of thoracic wall after resection for carcinoma adherent to ribs. (*Sauerbruch and Schumacher.*)

raised off the chest wall and swung over the opening on the opposite side. An excellent example of this is recorded by Sauerbruch and Schumacher (Figs. 474, 475, 476).

The lungs are inflated to fill the entire thorax, and a deep row of interrupted sutures anchors the fatty subcutaneous breast tissue to the thoracic wall. A superficial line of skin sutures assures exact ap-

proximation. The defect on the healthy side is closed by a suitable plastic operation or by skin grafts.

The Thymus and its Tumors.—James Ewing of New York, in the April, 1916, number of Surg., Gyn. & Obst., p. 461, presents an exhaustive and valuable paper with extensive literary references. He states

Fig. 475.—Patient in whom a defect of thoracic wall (Fig. 474) (after removal of carcinoma adherent to ribs) was closed by freeing the opposite breast (Fig. 476) and suturing it over the gap. (*Sauerbruch and Schumacher.*)

that the thymus is derived from the third and fourth branchial clefts, its foundation being the same as or closely related to that of the parathyroid. Hence we find parathyroid rests in the thymus and *vice versa*. The thymus body belongs to the chromaffine system. Its weight at birth is from 2 to 14 grams, average 7.7. In the adult from

20 to 28 grams. Cysts form in the thymus from several sources. They may come from the epithelial canals of the embryonal thymus, there may be dermoid cysts, invasion and distension of Hassall's corpuscles by lymphocytes, cystic lymph angeioma. The thymus is also the seat of primary tumors. Lymphosarcoma or thymoma, carcinoma, spindle-celled sarcoma or myxosarcoma. Carcinoma is commonest after 50 years of age. Carcinoma is regarded as an involution process, highly malignant and rapidly fatal from asphyxia. The constitutional symptoms of affections of the chromaffine system are not observed. In seven cases it was associated with myasthenia gravis. The apparent occurrence of metastatic foci in the skeletal muscles and in the organs appears to favor the view that some thymic tumors are indications of an infectious granuloma.

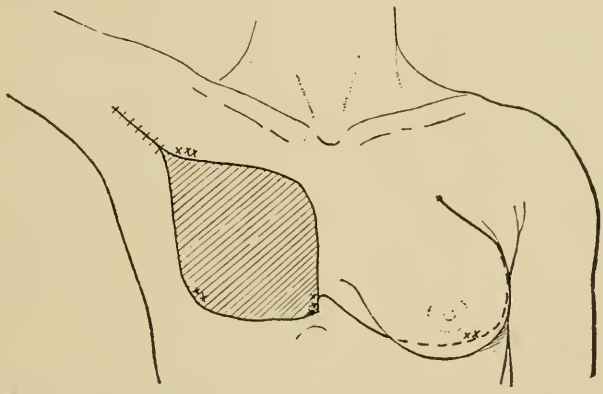

Fig. 476.—Diagram of plastic necessary after removal of right breast (shaded area) to close defect in thoracic wall (see Fig. 474). (*Sauerbruch and Schumacher.*)

Mediastinal Tumors.—Primary tumors may be carcinomata, arising from the bronchi at the hilum of the lung, or primary lymphosarcomata of the bronchial glands. Dermoids of the anterior mediastinum are not infrequent. A serohemorrhagic exudate of the pleura and early dyspnœa are symptoms common to malignant tumors of the lungs and of the mediastinum. The blood frequently shows eosinophilia.

Opening of the anterior mediastinum is necessary for (1) removal of an enlarged persistent thymus, (2) injury of vessels, (3) removal of operable tumors for temporary relief from the symptoms caused by inoperable tumors pressing upon the vessels and trachea. According to the advice of Sauerbruch, also of Rehn, a *longitudinal splitting of the sternum* affords more room and permits enlargement of the wound in a more satisfactory manner than lateral intercostal incision with trans-

verse division of the sternum. According to Sauerbruch, operations in the anterior mediastinum seem to predispose to the development of thrombi. Needless to say, injury with rupture of walls of the venous trunks in this region may permit the formation of air emboli.

Fig. 477.—Longitudinal mediastinotomy; introduction of fingers behind sternum. (*Sauerbruch and Schumacher.*)

Technique.—The incision begins over the first sternocostal articulation, and runs downward to the level of the third rib, where it bends outward in the fourth intercostal space to the right or the left, as the case may be. The soft parts are divided down to the infrahyoids above

and to the sternum below. The right index-finger is introduced into the episternal notch and, hugging the posterior aspect of the sternum, is gradually inserted downward. The pleura is exposed in the third intercostal space after blunt separation of the pectoralis major and intercostal muscles. The internal mammary vessels are ligated and divided; the left index-finger is now introduced through the third interspace and, hugging the posterior aspect of the sternum, proceeds upward until it meets the right index coming from above (Fig. 477). This pushes the vessels of the mediastinum out of harm's way. The sternum is then divided longitudinally with a parrot-beak rongeur. The cut surfaces are covered with gauze and retracted to either side. The structures in the anterior mediastinum are now accessible.

Fritz Koenig reports (Bruns Beitr. z. Klin. Chir., Bd. XCIV, heft 3, 1914, p. 538) a case in which the sternum was divided longitudinally after the manner of Milton, driving in two wedges of ivory in order to maintain the space gained and filling the opening with soft muscle tissue. The posterior periosteum of the sternum was not divided, however, and although there was temporary improvement the benefit was not for long. The pressure for which relief was sought in this case was one of mediastinal tumor.

In a case of persistent thymus the gland should be shelled out from within its capsule in order to avoid dangerous hemorrhage. As regards the treatment of injury to vessels or of tumors, each case is a rule unto itself.

Rehn, of Frankfort, employs a mediastinal exposure for the Trendelenburg operation and in operations for the repair of injuries of the heart, in pericardial plastics and in operations upon the anterior mediastinum. He modifies Miltons's operation by splitting the sternum from below upward. If the thorax is elastic, vigorous retraction of the divided halves will afford sufficient room. If not, the sternum can be divided transversely at the upper end of the vertical split. With this approach, there is the least danger of injury to the pleura (see also below under Trendelenburg's operation).

Dysphagia and Dyspnœa Lusoria (*i.e. dysphagia and dyspnœa caused by a lusus naturæ or freak of nature*).[1]—The right subclavian artery sometimes takes its origin from the arch of the aorta *to the left* of the left subclavian artery. It then runs to the right, arching slightly upward at the level of the manubrium sterni, usually between the œsophagus and the vertebral column, or between the trachea and

[1] Girard, Verhandlungen Deut. Gesel. f. Chir., 1913.

œsophagus, very rarely in front of the trachea. Beyond the median structures its course is the usually accepted one.

In Girard's two cases the artery lay in front of the trachea, and by its pressure caused dyspnœa. Girard attached the artery to the sternum by a musculo-tendinous loop from the left sterno-mastoid with its base below. The dyspnœa was relieved.

Trendelenburg's Operation for Embolism of the Pulmonary Arteries.—According to Trendelenburg,[1] the large emboli which cause complete occlusion and lead to death within one or two minutes are not common. More frequently (50 per cent.) the occlusion is partial, and death follows in from 10 minutes to one hour after the onset of the symptoms. Roughly speaking, this leaves about 15 minutes at the disposal of the operator. The operation is indicated in most cases when, in spite of embolism, life is maintained long enough to permit surgical interference. It is taken for granted that the nursing staff is thoroughly acquainted with the symptoms of pulmonary embolism, that the necessary operating room outfit has been sterilized so as to be instantly available, and that a proper operating staff is ready at all times.

Mahler's symptom (a zigzag ascent in the pulse rate), which was at one time supposed to presage the occurrence of an embolism, has been shown to be valueless.

Technique.—A horizontal incision begins at the margin of the sternum and runs 10 cm. outward along the second rib on the left side. A vertical incision crosses the inner end of this and runs along the left margin of the sternum from the level of the first rib down to and even beyond the third costal cartilage.

The two triangular flaps of the skin and muscle thus formed are pulled aside. The second rib is divided at the outer end of the horizontal incision; its stump is luxated forward and divided close to the sternum. The pleura, which usually has been torn by this time, is laid open 1 cm. external to the sternum from the first rib above to the third costal cartilage which is divided, care being taken to avoid the internal mammary artery. By holding the lung aside and allowing it to collapse, the pericardium and left phrenic nerve are seen in the mesial aspect of the wound. The pericardium is seized with mouse-tooth forceps anterior to the phrenic nerve at the level of the third rib—not higher on account of the danger of going above the point of reflection of the pericardium—and opened upward and backward and downward to afford easy access to the main trunk of the pulmonary

[1] Verhandlungen der Deutschen Gesellschaft fur Chirurgie, 1908.

artery. The operation up to this point can easily be accomplished within five minutes. A special instrument shaped like an aneurism needle (Fig. 478*b*) is now introduced into the sinus pericardii from the left

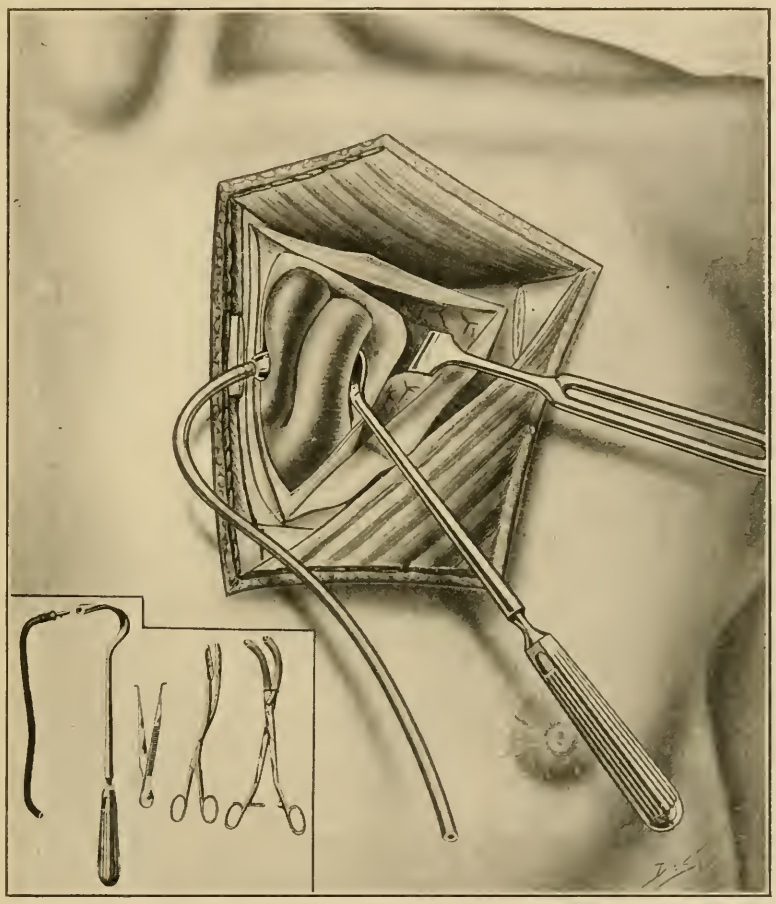

a *b* *c* *d* *e*

FIG. 478.—Trendelenburg's operation for removal of pulmonary emboli. Trendelenburg's special sound (*b*) has been passed around behind arterial pedicle of heart (through sinus pericardii), into its hollow point metal plug of elastic tube (*a*) is inserted and locked. Sound is then withdrawn leaving elastic tube encircling pulmonary artery and aorta. *c*, Thumb forceps with tips turned out—they distract margins of wound (480*a*) or, by insertion at angles, raise pulmonary arterial wall facilitating lateral application of rubber covered clamp (*e*) (see Fig. 480). *d*. Special forceps for extraction of emboli (see Fig. 479).

around behind aorta and pulmonary artery to the right, so that its point appears again at the left margin of the sternum. Into its point is screwed a small button fastened to a length of rubber tubing (Fig. 478*a*). The aneurism needle is now withdrawn and removed. Down-

ward and outward traction on the rubber tube brings the pulmonary artery and aorta forward and occludes their lumina more or less, depending on the degree of traction. With moderate traction and partial occlusion the serosa over the anterior outer aspect of the pulmonary artery is bluntly split by tearing with two anatomical forceps,

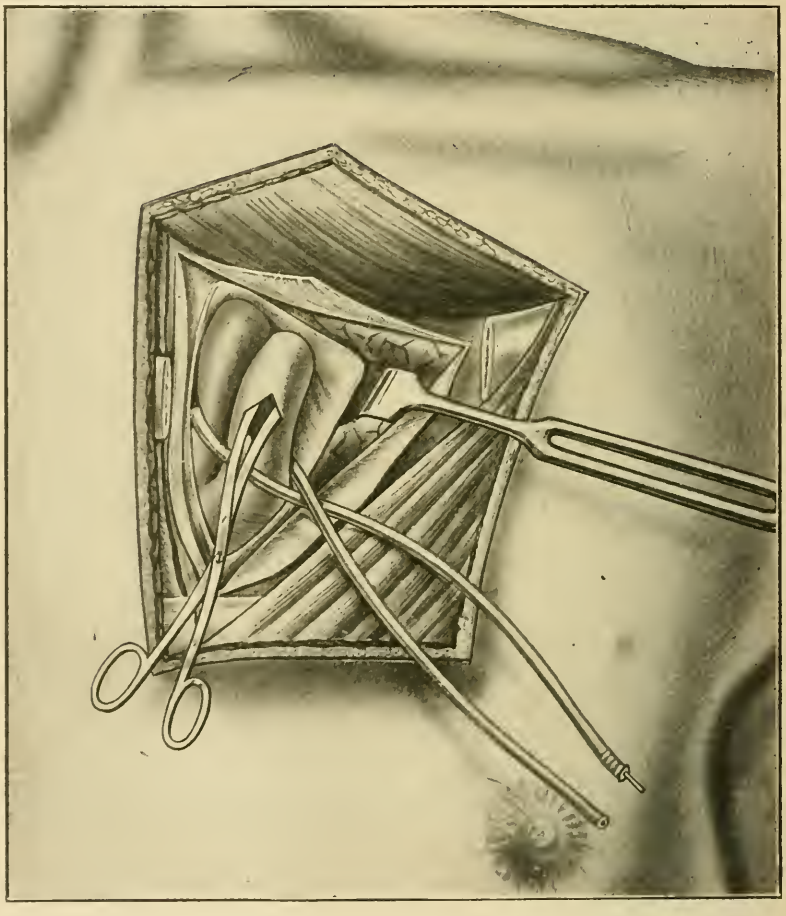

FIG. 479.—Extraction of clot in pulmonary artery. Note elastic tube *in situ*—in this illustration it is not pulled tight.

and the wall of the vessel is exposed. Complete occlusion is now made and the pulmonary artery is opened longitudinally for ¾ cm. A specially shaped dressing forceps (Fig. 478*d*) with a blunt nose to avoid seizing the arterial wall is introduced into the main artery toward the bifurcation (Fig. 479), and any blood clots which are present are gently grasped and removed. The angles of the wound are now picked up

with a special forceps (Fig. 478*c*), so that the edges of the wound lie parallel, and a clamp (Fig. 478*e*) is applied longitudinally to the arterial wall (Fig. 480). The rubber constrictor is now relaxed and circulation in the somewhat narrowed pulmonary artery is resumed. The circulation must not be interrupted longer than 45 seconds or the cerebral

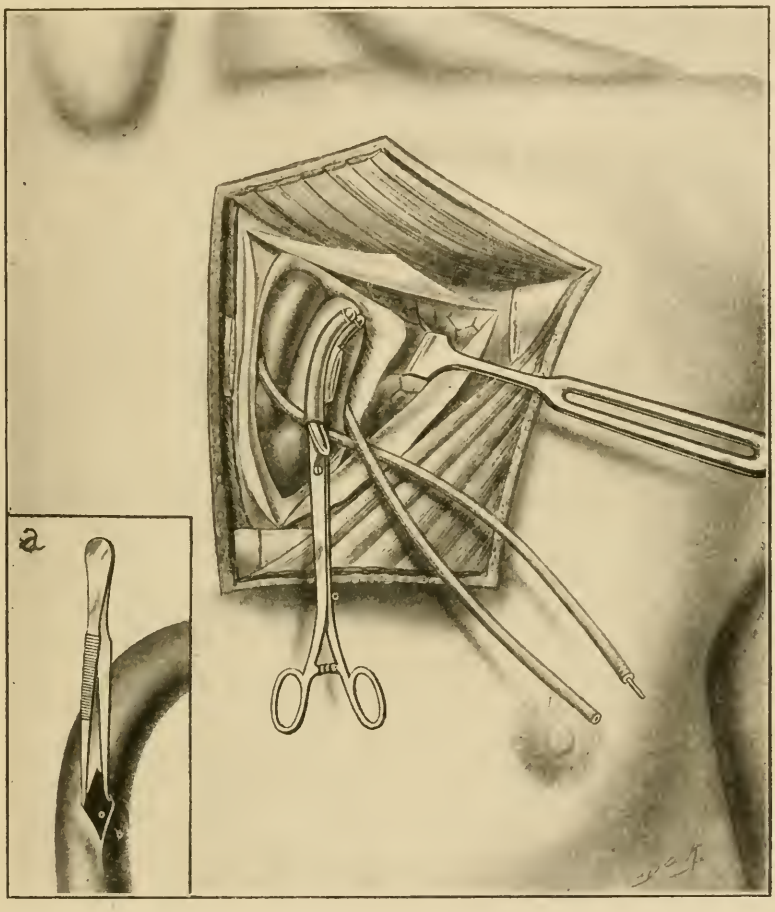

FIG. 480.—Rubber covered clamp applied laterally to wall of pulmonary artery closing wound but permitting passage of blood. Insert (*a*) shows special thumb forceps widening wound; if inserted at angles of wound, they hold up arterial wall facilitating lateral application of clamp as shown above.

centers will suffer irreparable damage. Fine sutures of interrupted silk close the wound in the pulmonary artery; as this vessel is in constant motion, momentary traction upon it facilitates the correct placing of sutures. The pericardial and chest wounds are then closed in the usual manner.

Addendum.—According to the latest advices, Trendelenburg's operation is best performed under differential pressure (intrapharyngeal tube or tubes introduced through the nostrils suffice—Zaaijer). Longitudinal splitting of the mediastinum (Milton, Rehn) gives the quickest exposure, and manual compression of the cavæ as they join the right auricle (Sauerbruch, Jeger, Rehn) is simpler and less shocking than compression of the arterial stem of the heart as originally done.

PLEURA

A. **Infections.**—1. Acute empyemata are frequent sequelæ of pneumonias, less often of wounds of the chest or rupture of superficial tuberculous foci of the lung.

2. Chronic infection. A chronic empyema cavity has rigid walls which are lined with granulation tissue. The contracted lung lies against the mediastinum, and is prevented from expanding by the inelastic wall of inflammatory tissue which covers it.

Polyserositis is a type of chronic infection which is not preceded by any acute process. Briefly, this is a chronic productive inflammation of the lining membrane of the serous cavities mostly affecting the pleuræ, the pericardium, and the peritoneal covering of the liver and spleen. The chief symptoms are those due to accumulations of fluid in the abdomen and chest. This necessitates repeated aspiration. (For *permanent drainage* see p. 761.)

B. **Tumors.**—1. Primary tumors of the pleura are rare. By the time they are discovered, operative treatment is usually out of the question.

Secondary tumors are extensions from a local recurrence in the chest wall after amputation of a carcinomatous breast or are extensions from tumors of the ribs, or they are secondary to primary or secondary tumors of the lung. A serohemorrhagic exudate is nearly always present with malignant involvement of the pleura and, conversely, the insidious appearance of a pleural effusion which aspiration reveals to be bloody is almost pathognomonic of cancer.

C. **Operations upon the Pleura.**—*Aspiration.*—The needle should avoid the lower border of the rib, because of the vascular and nervous elements in this region. The tissues should be drawn taut, before puncture is made, in such a manner that after the needle is withdrawn the holes through the various tissue planes will not lie in the same line, thus avoiding leakage.

The character of the physical signs, including the radiograph, will largely determine the site of puncture. When a free effusion is present, the eighth or ninth interspace in the posterior axillary line is a suitable location.

Technique.—Aspiration should be made slowly and should cease as soon as any symptoms of discomfort or distress appear. Among the important and unexpected complications following aspiration may be mentioned sudden œdema of the lungs and general convulsions. (Zesa's article in the Deutsche Zeitschr. f. Chir., Bd. CXIX, p. 76, is the most recent contribution on this subject.)

When the heart has been pushed out of its usual position for a long time, aspiration at times has actually proven more dangerous than free incision, possibly because the suction which tends to draw the organ quickly and forcibly back toward its normal place injures diseased great vessels or dislodges coagula so as to cause embolism. After drainage by incision, the return of the heart is much more gradual because the air rushing in takes the place, to a great extent, of the exudate.

Oxygen Replacement During Aspiration.—Davies[1] states that if during paracentesis, whenever there is the slightest symptom of distress, 100 cc. of oxygen are allowed to flow into the chest, the paracentesis can be performed with the minimum of discomfort to the patient. Two needles are employed: the lower one for aspiration, the upper, inserted a few spaces higher up, for the gas. The fluid is drawn off until discomfort begins, then withdrawal is stopped and about 100 cc. of gas are introduced. This alternate removal of fluid and replacement by gas is continued until no more fluid can be obtained. As the oxygen is absorbed, the lung is gradually drawn over to its proper position. If it is desired to further delay absorption of gas, nitrogen, instead of oxygen, should be used.

The method has been employed on the Continent.[2]

Nystrom (Hygiea, p. 849, 1913) reports upon 14 cases of empyema in which aspiration followed by injection of formalin in glycerin proved to be valueless.

Aspiration with admission of air accomplishes the same purpose as the oxygen replacement just described, but in a far simpler fashion. Torek[3] outlines the technique as follows: The patient is laid horizontally

[1] H. M. Davies, British Journ. of Surgery, 1913, Vol. I, No. 2, p. 228.
[2] Schmidt, Med. Klin., Nov. 9, 1913.
[3] Torek, on Thoracic Surgery, Johnson's Surgical Therapeusis, Vol. III, p. 526.

across two beds so that the seat of operation corresponds to the space between the beds. After trocar puncture of the pleural cavity, the patient is turned so that the site of puncture becomes the lowest point of the thorax. The fluid at first will flow in a continuous stream; then, as the pressure from within diminishes, the stream will halt on inspiration until, during an inspiration, some air finds entrance, after which the flow again improves. This continues until there is no fluid left in the pleural cavity; the trocar is then removed and the wound sealed by a small dressing. During this whole procedure the patient experiences no discomfort. The air is absorbed in a few days. . . . "It was thought at first that the air entering the pleura had to be sterilized, but the fear of air infection of the pleura is just as groundless as the fear of air infection of the peritoneum proved to be years ago."

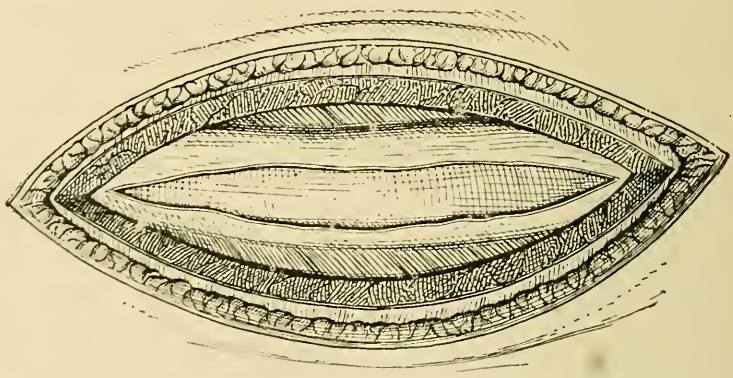

FIG. 481.—Resection of rib; longitudinal incision in periosteum which has been freed. (*Sauerbruch and Schumacher.*)*

Thoracotomy for Empyema.—This operation has been known since the time of Hippocrates. Drainage may be obtained either through a simple intercostal incision or through a larger opening after resection of one or more ribs. Unless there are special indications to the contrary, the opening should be made through the eighth or ninth interspace in the posterior axillary line, or after resection of the corresponding ribs.

Simple intercostal incision requires little mention, except to say that the drainage it affords is usually inadequate. It is useful as a temporary measure in patients with large effusions who are too weak to stand a rib resection at the moment.

* This figure shows the skin incision in the line of the rib, not across it as recommended in the text.

Resection of One or More Ribs.—The skin incision should be at right angles to the direction of the ribs. The soft parts are divided down to the periosteum. The periosteum is longitudinally incised midway between the upper and lower borders of the rib for a distance of 1 to 1½ in. At the ends of this horizontal cut, vertical cuts are made from the upper to the lower borders of the rib. With a raspatory the periosteum is separated from the outer surface of the rib (Fig. 481); the separation is continued around to the posterior aspect of the rib by carefully hugging the bone, thereby avoiding a premature tear in the

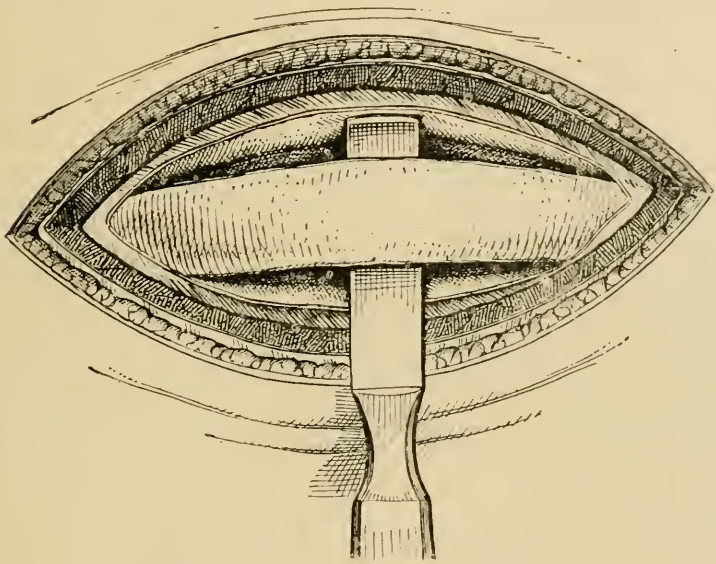

FIG. 482.—Resection of rib; raspatory (hugging bone) is freeing posterior aspect of rib from periosteum. (No vertical (transverse) incision of periosteum has been made as recommended in text.) (*Sauerbruch and Schumacher.*)

pleura. After the periosteum is completely free in one spot from the posterior aspect of the rib, it is easy enough to slide the raspatory or an elevator from side to side, thereby stripping free the posterior aspect of the rib (Fig. 482). Almost any bone forceps will do for dividing the bone at either end of the wound.[1] Any bony spicules on the rib ends are removed with a rongeur. The periosteum covering the pleura is now exposed to view. Instead of *immediate incision*, aspiration should be made again to make sure that the pus lies just beneath the pro-

[1] 1. When many ribs are to be divided Wilms's bone cutter is of great aid. It makes for speed (Zentr. f. Chir., 1913, p. 388).

2. It is well to cover ends of the ribs with iodoform gauze; this prevents local infection of rib ends with establishment of obstinate bone sinuses long after the empyema has healed.

posed opening. A number of times it has happened that an abscess of the lung has been mistaken for an empyema of the pleura, and by opening the pleura an acute pneumothorax was unexpectedly established causing dangerous shock to the patient.

When the second aspiration reveals pus, a grooved director whose end has been filed across so that it will follow down the shaft of the needle is inserted alongside the needle down into the pleural cavity. The needle is withdrawn and in its place the point of a dressing forceps is introduced along the grooved director; the blades being separated on withdrawal, a sufficient pleural opening is made. Before opening widely, it is well to cover the instruments and the hands of the operator with a towel to prevent the pus under tension from being projected into his eyes. This is most apt to happen when the patient coughs. The opening in the chest wall is gradually widened, and the pus is al-



FIG. 483.—Tiegel's valve drain.

lowed to flow out *slowly*. It is well to introduce the finger and search for large masses of fibrin which are so frequently present in empyema, and also to be sure that the opening just made, drains the cavity's most dependent point. A ring ovarian clamp is very convenient for seizing and extracting the fibrin masses.[1]

Two short fenestrated rubber tubes of ample caliber are pinned together. They should reach just beyond the parietal pleura and no further; that is, they should be from 1 in. to 1½ in. long. Besides the safety pin which holds the tubes together, two additional safety pins should be used, one through each tube and lying at right angles to the long axis of the wound. A split gauze compress protects the skin from these safety pins. A voluminous gauze dressing is held in place by a bandage. This circular bandage is prone to slip downward. To keep it in place it is well to suspend it from the shoulders.

[1] Robinson has suggested inflation of the lungs by positive pressure in empyema to see whether they are capable of distention or whether they are bound down.

A convenient method of doing this is to place two long strips of bandage material one over each shoulder next to the skin—these extend well below the waist line both in front and behind. The circular bandage covers them as well as the gauze dressing; after the bandage is completed, the strips are drawn tight and are then brought upward outside the circular bandage, and tied just above its upper margin thus preventing the dressing from slipping downward with displacement of the drainage tubes.

Valvular drainage has been employed for over 40 years. There are innumerable varieties. Tiegel's valvular drain is very good (Fig. 483). Another very simple one is Thiersch's, consisting of a soft collapsible rubber tube fastened to the more rigid drainage tube in the empyema opening (Fig. 484). A simple form of valvular drainage was reported by F. B. Lund of Boston.[1] A rectangular flap of skin having its hinge uppermost, is fashioned sufficiently large to overlap two ribs. The upper rib is resected and the pleura is opened in the usual manner at this point, a large sized drainage tube is obliquely cut so that its inner end lies flush with the inner aspect of the chest wall; its outer end is also obliquely trimmed so that it lies flush with the outer aspect of the true thoracic wall (not the skin). The tube is held in place by a few stitches joining its lower margin to the lower margin of the wound. The hinged skin flap is now allowed to fall into place. It acts as a valve, preventing the ingress of air and permitting the egress of thoracic contents. Intelligence and constant care are necessary when valvular drainage is employed. For the first day or two the fibrin must be cleaned from tubes and valves every two or three hours.

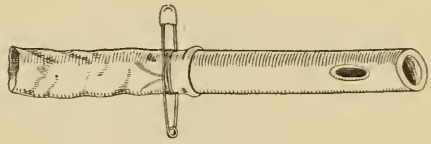

Fig. 484.—Thiersch's valvular drain—a soft collapsible rubber tube is drawn over outer end of stiffer drainage tube.

Continuous suction was first employed by Playfair in 1873. On p. 737 we have mentioned a convenient way of using a vacuum cleaner connected with a wash bottle for this purpose.

Schmerz (Zeit. f. Chir., January, 1916, p. 1) trephines a rib, then explores with an aspirating syringe and on finding pus thrusts a drain tightly stretched over a probe into the pleural cavity. The tube is coupled with a vacuum bottle. The advantages claimed are, that no air enters the chest, that the evacuation of pus is under negative pressure throughout the treatment, that contact of the wound with the pus is

[1] Amer. Surg. Assoc., 1914 meeting.

avoided, and finally, that ambulatory treatment is possible. In cases of long-standing empyema Schmerz recommends rib resection and drainage into a vacuum bottle by means of a rubber stopper through which an L-shaped glass tube projects into the pleural space.

Ribs have been trephined for drainage purposes since the time of the ancients. Recently Robinson of Boston has suggested screwing a short metal tube with a thread on its outer surface into such a trephine opening. The objection to this has been the danger of establishing a localized, obstinate osteomyelitis.

On the other hand *permanent subcutaneous drainage* in the serous effusion of polyserositis or cancer of the pleura is most desirable and may readily be established by trephining the ribs. The soft parts including skin are closed and heal by primary union; a channel is thus established between the pleural cavity and the subcutaneous lymphatics. How long it functionates is not known.

Empyema cavities should rarely if ever be irrigated.

At the 1915 meeting of the American Surgical Association Lilienthal advised exploration of the thorax and mobilization of the confined lung at the primary operation for empyema. Or the operation may be performed in two stages if the patient's condition immediately threatens life, the first stage being a small intercostal incision. Occasionally this minor procedure will be followed by recovery. If not, the exploration and mobilization are performed through a long intercostal thoracotomy in the seventh or eighth interspace. A rib retractor is put in, the chest visually explored and the lung mobilized by incising the confining membrane of the pleural exudate and peeling it away, removing as much only as can be easily reached. As a rule, adhesions between lung and costal pleura should not be disturbed because of the danger of hemorrhage.

The wound is closed by approximating the divided muscles (latissimus dorsi and serratus magnus) with chromicized catgut, and suturing the skin with silk, leaving space for drainage, with or without tubes according to circumstances. There should be expansion of the lungs by blowing exercises as soon as possible after the operation.

Twenty-three cases with 17 per cent. of deaths were reported—an unusually low mortality.

At the 1917 meeting of the same body Lilienthal gave the statistics of 100 consecutive unselected cases of empyema, including those empyemas resulting from perforation of liver abscess, from pyemia, from ruptured lung abscess, etc.—with a mortality rate of 23 per cent.

FIG. 485.—The chest is open, the rib spreader in place. The scalpel is making the incision through the layer of dense exudate which confines the lung.

FIG. 486.—The fingers are separating the layer of dense confining exudate from the visceral pleura. The lung protrudes below. (This is, of course, diagrammatic.)

FIG. 487.—With the scissors incisions are made in the exudate to permit a freer expansion of lung.

FIGS. 485 TO 487.—Lilienthal's major intercostal thoracotomy and lung mobilization. (*Annals Surg.*, Vol. 62, 1915, p. 309.)

An improvement of 5 per cent. over 299 cases in 10 years reported by Wilenski (Surg., Gyn. and Obst., May, 1915) from the same institution —Mt. Sinai Hospital—and a gain of one week in average hospital residence. And, most important, there was not a single case of collapsing thoracoplastic operation against about 15 per cent. in former years. (See also Lilienthal and Ware, Med. Record, July 15, 1916.)

Old Empyema Cavities.—Obliteration in one of two ways has been the aim of all operations for the cure of old empyema cavities; either the lung was freed from the mass of thickened membrane binding it down so that it expanded again and filled out the cavity up to the chest wall (Delorme, Fowler); or that portion of the chest wall overlying the cavity in question was deprived of its ribs (Schede, Estlander) so that it could sink in, allowing the sides of the suppurating cavity to lie in contact. These operations and many more can be found in any standard textbook of surgery. The modern methods of mobilizing the chest wall are fully discussed under the title of "collapse therapy" (p. 779). As to decortication we shall merely mention a point recently made by Ransohoff,[1] namely, that numerous incisions through the thickened membrane covering the lung give almost as much freedom as the more difficult, tedious and dangerous decortication. As each incision is made, one can see the margins of the wound gape and the underlying lung tissue expand correspondingly. In addition to the longitudinal incisions, an equal number of horizontal or cross-hatching incisions will still further release the confined lung. Lilienthal has operated in more than six cases without rib resection. Exposure for the mobilization and decortication is made by a long intercostal incision with division of ribs upward or downward from the posterior angle of the wound so that the rib spreader can be inserted. The chest-wall flap takes its normal position after the intrathoracic work has been completed and is held by sutures. Drainage is necessary. The results show no marked deformity of the thorax.

In an interesting paper on the treatment of chronic non-tuberculous empyema, Robinson (Surg., Gyn. & Obst., May, 1916, p. 557) enumerates the errors which contribute to the mortality. First, too large operations in one stage; second, overestimating the resistance of the patient; third, operation being continued until shock appears; fourth, undue loss of blood; fifth, expenditure of too much time; and sixth, an unskillful anæsthesia. Robinson believes that there can be no standard operation for the obliteration of a chronic empyema cavity. He

[1] Amer. Surg. Assoc., 1914.

speaks in favor of a sequence of operations beginning with the simplest. The X-ray is valuable to control progress. The general type of the operation is that of Wilms's osteoplastic method with final muscle implantation.

There should be from one to six months interval between operations.

Transpleural Operations upon the Œsophagus.—Nowhere in the body is there more need for the utmost gentleness and asepsis than in transpleural operations upon the digestive tract. The high mortality in operations upon mediastinal structures has been due to either shock or infection.

To combat the *shock*, it is proposed to block the vagus with cocaine or some other drug in the region of the aortic arch and hilum of the lung.

Roith (Zent. f. Chir., 1913, p. 556) reports three cases in which he blocked both vagi in the neck below the origin of the superior laryngeal nerve. The only noticeable effect was transient paralysis of the recurrent laryngeal nerve.

Heller (Deut. Gesell. f. Chir., 1913) blocks the vagi in the region of the lung hilum and arch of the aorta by applying a 1 per cent. novocain-adrenalin solution. He has found in animals that bilateral blocking of the vagi caused no ill effects and prevented reflex cessation of the pulse and respiration, following trauma.

To avoid *infection* the œsophagus should not be opened within the thorax unless one is prepared to remove it *in toto*, because so far, no reliable method of aseptic closure exists.

Transpleural operations upon the œsophagus have been performed for the relief or cure of two conditions: (1) diverticula, from benign obstruction at the cardia (intractable cardiospasm) or cicatricial stenosis; (2) carcinomata.

(1) *Diverticula* have been temporarily relieved by a longitudinal plication (Willy Meyer in cases of cardiospasm[1]) or, by bringing the fundus of the stomach up through a separate opening in the diaphragm and uniting it with the dilated pouch of the œsophagus. In the latter case, the chances for success are better than after resection, since both hollow viscera are covered with serous membrane (the dilated œsophagus by the pleura) and there is no tension on the suture line; however, the danger of infection at operation is very great—much more than with

[1] In cases of cardiospasm symptomatically relieved by the passage of bougies, X-ray examination has shown that the dilatation of the œsophagus above the cardia does not disappear although it causes no symptoms.

A. V. Lambert's method.[1] Here preliminary gastrostomy is made. At a second laparotomy the diaphragm is split, exposing the diverticulum; the margins of the diaphragmatic wound are then sutured to the diverticulum. A clamp, with blades closed, is introduced into the stomach through the gastrostomy opening, the handles left projecting. The blades are now separated and one of them is introduced through the narrowed œsophageal opening under guidance of the hand within the abdomen. Tight closure of the blades leads to the creation of an adequate opening in due course of time.

Zaaijer drained a diverticulum of the œsophagus by a series of three operations absolutely avoiding infection of the pleura with œsophageal contents.

In this case there was not only inanition but also putrid stagnation in the pouch with high fever.

The first operation was a gastrostomy. A few weeks later when the patient's nutrition had improved, an extensive resection of the ribs was made posteriorly, mobilizing the thoracic wall and bringing it nearer to the diverticulum. The pleura was now opened and the lower part of the diverticulum covered with mediastinal pleura was exposed. The parietal pleura was sutured in such a manner that a portion of the unopened diverticulum was rendered accessible for subsequent incision, at the same time closing off the general pleural cavity. The skin wound was closed except over the diverticulum where a packing was placed. Twelve days later, with colored fluid in the œsophagus, a fine aspirating needle located the œsophageal lumen which was then opened. Much foul material escaped from the ulcerating cavity. The temperature subsided and the patient recovered. Later[2] the diaphragm was split and the œsophagus anastomosed to the stomach. For a time all went well. Then hematemesis set in, gastroenterostomy did not check the hemorrhage; finally it was ascertained that the bleeding came from the suture line uniting the œsophagus to the stomach. This anastomosis was laid open, the bleeding stopped but the patient began to fail; an uncontrollable diarrhœa set in and she died of inanition and a terminal pneumonia.

(2) *Carcinomata of the Œsophagus.*—The most frequent site is the middle third, next the lower third and lastly the upper third.

Carcinomata of the *lower third* show greater tendency to early metastasis than do those in other locations.

All methods of anastomosing the upper end of the œsophagus with

[1] A. V. Lambert, Ann. of Surg., Sept., 1913, p. 415.
[2] Zaaijer, Zentralbl. f. Chir., 1913, p. 1883.

the lower end, or with the stomach, after resection for carcinoma, have failed. The line of union has leaked and the patients died. Further, where both ends of the œsophagus have been closed after resection (nutrition by gastrostomy), *the upper blind end of the œsophagus has invariably leaked.* The lower end has never shown a tendency to leak. Therefore, *it is essential to remove the upper blind end of the œsophagus from within the thorax.*

The first successful case of resection of the thoracic portion of the œsophagus for carcinoma was performed by Franz Torek at the German Hospital, New York, on March 14, 1913.

A woman, 67 years old, had a carcinoma of the œsophagus beginning just below the lower border of the transverse portion of the arch of the aorta, extending from there downward for about 1¾ in., as shown by stereoscopic X-ray plates. A preliminary gastrostomy was made some time previous to resection of the œsophagus.

Fig. 488.

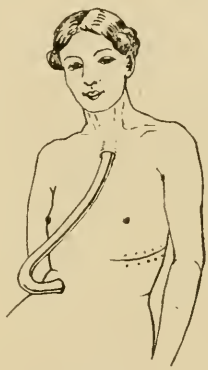

Fig. 489.

Fig. 488.—Rear view of Torek's patient showing healed scar of incision through 7th intercostal space and prolonged upwards close to spine.

Fig. 489.—Front view showing tube leading from lower end of œsophagus above, down to gastrostomy opening below. Note anterior end of intercostal incision.

Torek obtained his exposure by an incision carried through the whole length of the seventh intercostal space, from the posterior end of which it was extended upward by cutting through the seventh, sixth, fifth and fourth ribs near their tubercles (Fig. 488). A drawing shows the posterior aspect of the scar, the upper end of which is almost at the level of the shoulder; another drawing (Fig. 489) shows the front end of the incision.

Extensive adhesions between the lung and the parietal pleura were found, the greater part of the lower lobe being attached both to the costal and the diaphragmatic pleuræ. The firmest adhesions were at the apex. All these were separated. The tumor was fairly fixed in the

position described above, namely, just below the lower border of the transverse portion of the arch of the aorta. It was slightly movable. The portion of the œsophagus just below the tumor, between it and the diaphragm, was exposed in the usual manner by incising the pleura, drawing the vagi aside, and lifting the œsophagus out of its bed. At the site of the tumor, dissection of the vagi was more difficult. Some of the branches crossing in front were cut, to permit liberation of the tumor without undue roughess. The pulse never wavered durig this procedure, remaining between 93 and 96. Vagus collapse did not occur.

The dissection of the œsophagus behind the arch of the aorta offered great difficulties. These were finally overcome by dislodging the aorta and lifting it forward, a procedure made possible by ligation and division of a number of its thoracic branches (intercostals). The tumor was attached to the left bronchus, which sustained a longitudinal cut during the progress of separation. The cut in the bronchus was afterward sutured with silk.

The œsophagus was now free from a point about an inch above the diaphragm, up to about an inch above the arch of the aorta. Resection of the carcinoma *in situ* could, therefore, have been easily performed. This was not done; instead, the œsophagus was dissected loose from its attachments all the way up to the neck, doubly ligated, and divided with a cautery at a safe distance below the carcinoma. Then the œsophagus, with the tumor, was brought out through an incision in the neck at the anterior border of the left sternocleido-mastoid muscle. The ligation of the lower stump had been made after first crushing the œsophagus at that site. This stump was invaginated like an appendix stump, but with two successive purse-string sutures of silk.

Then the thorax was closed, silk threads being used to hold the seventh and eighth ribs together, chromicized catgut for the muscles, and silkworm-gut the skin. No drainage was employed. The œsophagus was now hanging out of the wound in the neck. A transverse incision was made in the skin of the chest at a place where measurement showed the free end of the œsophagus would lie after the carcinoma was cut off. This corresponded to the second intercostal space. The skin between the incision in the neck and the new incision was tunneled, the œsophagus drawn through, the carcinoma cut away, and the fresh rim of the œsophagus sutured to the skin. The neck wound was closed.

The incision through the skin and muscles at the beginning of the operation was made under local anæsthesia. The general anæsthesia was given by Meltzer-Auer intratracheal insufflation.

The pulse was regular and of good quality throughout the operation except when the aorta was pulled over for the purpose of suturing the

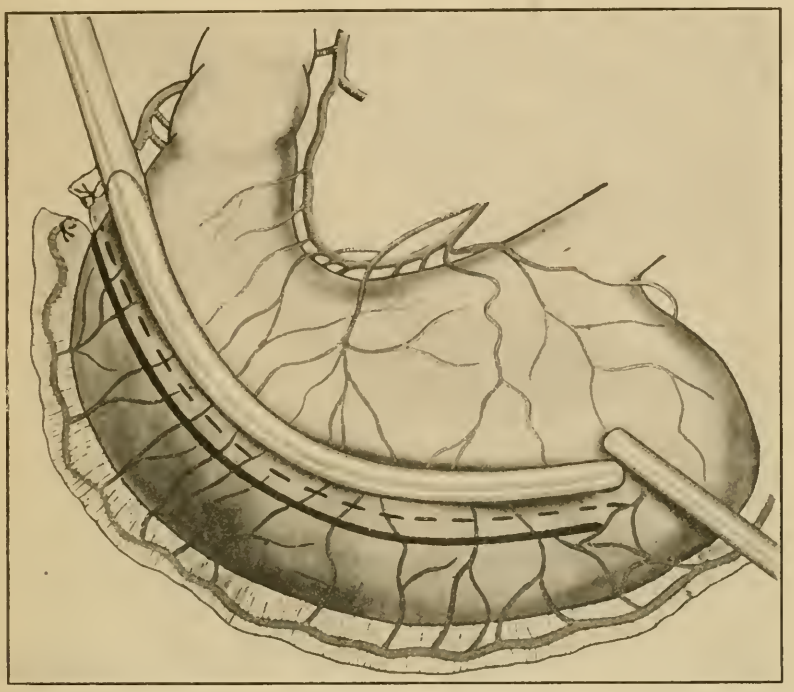

FIG. 400.—Jianu's gastrostomy—tube fashioned from greater curvature of stomach. (*After Willy Meyer.*)

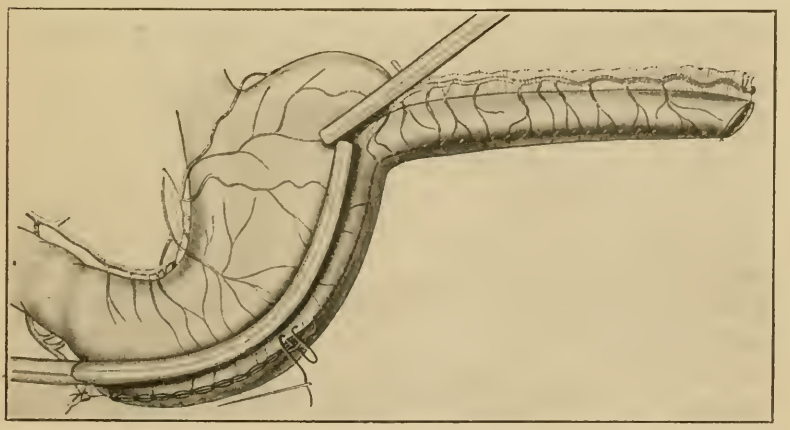

FIG. 491.—Jianu's gastrostomy. Newly formed tube turned away from stomach. (*After Willy Meyer.*)

cut bronchus. At that time it became weak, but improved unde stimulation.

The tumor proved to be a squamous-celled epithelioma.

After operation the patient was nourished through her gastrostomy until the eighth day. Then the free end of a long gastrostomy tube was introduce into the cut end of the œsophagus for the purpose of feeding the patient. The patient now swallows semi-fluid material such as bread, cereals, potatoes, eggs, or spinach, the food traversing the mouth, pharynx, upper end of œsophagus and rubber tube to enter the gastrostoma.[1]

Willy Meyer holds that a Jianu gastrostomy (Figs. 490 and 491) should precede resection of the œsophagus. Briefly, this consists in fashioning a tube from the greater curvature of the stomach, leading it

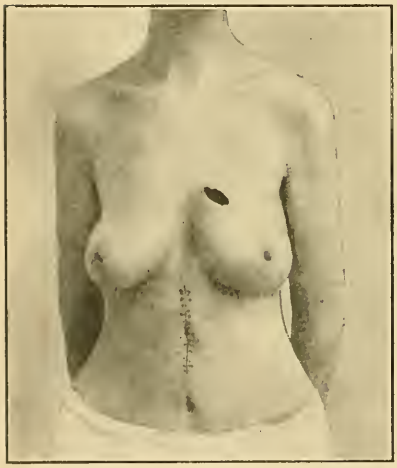

Fig. 492.

Fig. 493.

Figs. 492 and 493.—Two of Willy Meyer's patients with Jianu gastrostomy openings on the chest-wall.

upward on the chest wall under skin or muscle. The mouth of such a tube reaches to the third rib without tension. (Two of Meyer's cases are shown in Figs. 492 and 493.) The peristaltic action of this tube often leads to extrusion of gastric contents upon the chest wall. Should the ends of œsophagus and gastrostomy fail to meet, the gap is to be eventually bridged by a suitable skin plastic.

Zaaijer was the first to successfully resect a carcinoma of the cardia.

A short synopsis of his case follows because he obtained his results in a different way from Torek.

Zaaijer's patient was a man of 54 who gave a four month's history of progressive difficulty in swallowing. An obstruction was present 45 cm. from the teeth. The œsoph-

[1] Torek's patient—personal communication—was well 30 months after operation.

agoscope revealed smooth mucous membrane—the site of the stricture could not be seen. Three separate operations were made.

1. On November 15, 1912, through a median epigastric incision, a preliminary gastrostomy was established in the pyloric region. At the same time it was ascertained that conditions at the cardia did not contraindicate a radical procedure. A movable tumor the size of a pigeon's egg was felt; it extended to the hiatus of the œsophagus.

2. On December 10, 1912, from an incision parallel to the ribs, an extensive subperiosteal resection of the ribs was made upon the left side from behind their angles to the costal cartilages. The sixth to the twelfth ribs were resected, 24, 21, 24, 21, 22, 18 and 14 cm. being respectively removed. An attempt to suture a rent in the pleura failed—the stitches tore out. The opening was successfully closed by suturing adjacent muscle and fascia over it. Following this operation there was great dyspnœa with moist râles over the whole left lung. Active stimulation with digalen and camphor, and application of positive pressure with oxygen, succeeded in lessening the patient's distress. His respiratory equilibrium gradually re-established itself. Because of this experience, Zaaijer advises not to resect the twelfth rib or at least not until some time later.

NOTE.—Simple division of several ribs is not a good procedure. The respiratory movements grind the divided ends against each other. The patients have the same pain that they would have from fractured ribs. Respiration is embarrassed and adequate expectoration is prevented. On the other hand, after multiple resection of ribs there is far less pain, consequently the respiratory movements are practically unhampered.

3. On January 9, 1913, under differential pressure, an incision was made which began in the left hypochondrium arching backward and turning upward in the posterior axillary line to end a little higher than the angle of the scapula. The peritoneum and pleura were both opened; there was much clear yellow fluid in the pleural cavity. The periphery of the diaphragm was incised, allowing the left hand to be introduced into the abdomen. With the right hand in the pleura, the findings at the preliminary exploratory laparotomy were confirmed. The tumor was freely movable; there was a small, hard node in the lesser omentum close to the tumor. (At this stage in a previous operation for carcinoma conditions were found to be inoperable and the wound was closed, the patient making an uneventful post-operative recovery.)

The left pleura over the œsophagus was incised; in freeing the œsophagus bluntly, the right pleura was torn. Dissection was continued, the œsophagus was freed and a gauze tape was passed around it as a tractor. The central part of the diaphragm was split in the direction of its fibers toward the œsophagus. The œsophageal ring was excised under careful hemostasis, a long artery forceps seizing the peripheral margin of the diphragm before each successive cut was made. This was the most difficult part of the whole operation.

The œsophagus and stomach were now somewhat movable. The lesser omentum was divided between a number of ligatures, and the gastrosplenic ligament was also ligated and divided. The stomach was now freely movable, two clamps were applied to it, well away from the tumor, and between them the stomach was divided with the actual cautery. The upper clamp, with the tumor and the œsophagus, was wrapped in gauze and laid aside. The stomach was closed with suture and dropped back into the peritoneal cavity.

The pleura over the œsophagus was split upward and by blunt dissection, it was so completely freed that its healthy portion above the tumor readily reached to the skin of the back the tumor protruding from the wound. The anterior branch of the vagus was divided in the course of dissection; the posterior branch was not seen.

In the bed of the œsophagus the left pleura and mediastinal connective tissue were sutured over the tear in the right pleura. Exact closure of the diaphragmatic wound was made by two rows of interrupted sutures. Even after this the posterior portion of the diaphragm remained lax.

Differential pressure was increased and as the left lung was inflated the œsophagus lay between the two lobes almost of its own accord. At a point 4 cm. above the tumor, the œsophagus was sutured to the parietal pleura *without tension*. The pleural and peritoneal cavities were closed. Just beyond the suture line of the œsophagus to the pleura, a heavy ligature fastened it to the skin under tension, and just beyond this two clamps were applied between which it was divided by the actual cautery.

Complete asepsis was thus maintained throughout the entire operation.

Many other methods suggested for removing the thoracic œsophagus have not been successfully carried out upon living human beings. Prominent among these are the following:

Rehn, Jr., suggests passing a sound up to the point of division (in resection of the œsophagus), fastening the cut end to the sound and invaginating it downward into the stomach. If pulled from below up, in this manner, the œsophagus tears itself from its surroundings, while if pulled from above down, a narrow film of muscular wall is left behind. This does not disturb the nerves and vessels close to the œsophagus.

Denk states that with one hand in the abdomen through a wound in the diaphragm, and one in the neck, the fingers not only touch but overlap. He advises loosening the œsophagus by this method, and maintains that, except in carcinoma at the level of the tracheal bifurcation, the entire œsophagus can be mobilized. It is then divided at either the upper or lower wound and withdrawn from the thorax under aseptic precautions.

Both of these methods appear at present to be more suitable for demonstration upon cadavers and animals than upon patients.

Transpleural laparotomy for repair of injuries and transpleural drainage of liver abscesses or subphrenic abscesses have been referred to on p. 738.

LUNGS

Œdema of the Lungs.[1]—Matsuoka from observations based on experiments with Starling's heart-lung preparation concludes that obstructive œdema takes place when certain limits of combined arterial pressure and venous inflow are exceeded. Obstruction of the aorta favors the production of œdema since a relatively smaller amount of venous inflow is sufficient to cause the condition.

The principal factors in the transudation of œdematous fluids into the alveoli are, great increase of pressure in the pulmonary circulation, however brought about, and excessive passive dilatation of the lung capillaries.

Gaseous metabolism and energy consumption of the heart are decreased in obstructive œdema and complete stoppage rapidly takes place.

Matsuoka suggests as a remedy the inhalation of oxygen preceded by venesection, because it is difficult to supply oxygen in sufficient quantity to œdematous lungs.

A. **Infections.**—(1) *Acute infections* rarely present conditions suitable for surgical interference. Post-pneumonic lung abscesses and those

[1] Œdema of the Lung Based on Observations with Starling Heart-Lung Preparation, J. Path. & Bact., 1915, XX, p. 53.

caused by foreign bodies usually reach a fairly chronic stage before they cause sufficiently well defined symptoms to furnish diagnostic clues.

The prognosis of acute post-pneumonic abscesses which are drained is not bad. The same is true of acute abscesses with gangrene of the lung when drainage is established before the process has become disseminated through aspiration.

Abscess of the lung from a foreign body deserves special mention. The lodging of a foreign body in a bronchus usually leads to a localized abscess of the bronchiectatic type around it, and then to the formation of secondary abscesses in the neighborhood. These are often larger than the primary focus. An obstinate, purulent, putrid bronchitis, confined to one lobe, especially the right lower, is very suggestive of a foreign body as its cause, even if the same is not visible by the X-ray. Quincke advises the establishment of a bronchial fistula below the right scapula to prevent the further formation of bronchiectatic cavities. Such a fistula should not be closed when the secretion is putrid. It acts as a safety valve by preventing retention.

The earlier the operation, the better the prognosis.

(2) *Chronic Infections.*—In certain cases of tuberculosis or bronchiectasis with *preponderant unilateral involvement*, "collapse therapy" (see below) has been of distinct value.

Certain types of emphysema have also shown themselves amenable to surgery (see below).

General Remarks.—Accurate records must be kept of the daily amount of sputum expectorated, temperature curve, variations in body weight and any changes in physical signs, if one is to arrive at a correct indication for treatment and, further, if one is to know whether such treatment is doing any good.

As regards sputum, it is important to note whether greater amounts are expectorated at certain times and in certain positions, *i.e.*, more when patient lies on one side than the other. One must also ascertain whether the physical signs and the X-ray picture change before and after copious expectoration. Certain patients expectorate foul material at one time and odorless material at another. An intelligent patient may be able to tell from which side or even from which part of the thorax the foul expectoration comes. Let the individual study himself in this respect. Much help may be gained thereby in establishing a diagnosis.

It may be said, as a general rule, of cavities in the upper lobe that position has no influence upon the character or amount of expectora-

tion, while with cavities of the lower lobe it is frequently found that expectoration is periodical, perhaps absent for hours, and is made worse by a prone position or by lying on one side rather than on the other.

Quincke has pointed out that when an empyema has ruptured into the lung there is no pneumothorax, because the part of the lung which is perforated is atelectatic. The pus from such an abscess shows only one kind of organism, even months after perforation, whereas the pus from lung abscesses always shows countless varieties of organisms.

Never make an exploratory puncture for a lung abscess through the unopened chest wall. Infection of the pleural cavity and even sudden death have followed this procedure. Such a puncture should only be made after exposure of the lung at operation and after the rest of the pleural cavity has been protected against infection.

Lung fistulæ from tuberculosis, bronchiectasis or multiple abscesses of the lung should be let alone, for they constitute safety valves.

A simple way of recognizing whether a fistula is pulmonary or pleural is to have the patient expire as deeply as possible and then to lay the wet palm over the opening. After several deep inspirations and expirations remove the hand toward the end of expiration. If air escapes, the fistula is pulmonary.

Plastic closure of lung fistulæ is indicated when secretion is scanty.

Majewski (Zentralblatt f. Chir., 1913, p. 845) suggests the establishment of a bronchial fistula in low obstruction of the trachea by mediastinal tumor or aneurism when tracheotomy is of no avail, in other words, allowing the patient to breathe partly through a bronchial fistula.

Actinomycosis of the lung always gives a bad prognosis. If the process is localized, extirpation is indicated. Fistulæ rarely afford adequate drainage. They should, therefore, be enlarged.

Ecchinococcus of the Lung.—The right lower lobe is most frequently involved. The X-ray and complement reaction are valuable aids in diagnosis. Once this is established, there should be no delay in operating. The utmost care must be taken to avoid infection of the pleural cavity by ecchinococcus fluid. Therefore exploratory aspiration must not be attempted (see p. 779).

Emphysema is in many instances associated with rigidity of the costal cartilages; owing to this the amplitude of respiratory movements is greatly diminished, which in turn accounts for the dyspnœa which promptly appears upon the slightest exertion. Often patients have had to give up their vocations solely on account of this symptom.

Freund's treatment consists in division of the costal cartilages close to the sternum.

The operation should be limited to those forms of emphysema with the thorax held in the inspiratory position.

The normal vital capacity of 3500 to 4000 cc. (upright position), which is reduced in emphysema to between 2400 and 1500 cc., is largely regained after operation.

The operation is contraindicated in the presence of bronchiectasis; or when the emphysema is associated with spasm of the inspiratory muscles in nervous, cardiac or renal asthma; and, finally, in paralytic or senile rigidity of the thorax.

Bronchiectasis is discussed on p. 802.

B. **Tumors of the lung** (*parenchyma*) are almost unknown. They usually are malignant. Often tumors springing from the bronchi or mediastinal lymph nodes invade the lung tissue. As a rule, by the time their pressure is demonstrable they are no longer suitable for radical surgical treatment.

Metastases of the lung secondary to malignant foci elsewhere are usually bilateral, and inoperable. As said before, secondary involvement of lung by direct extension of a tumor of the thoracic wall has been successfully treated by wide resection of lung tissue with subsequent suture.

C. **Operations upon the Lung.**—(1) *Repair of wounds* has been discussed in the section on injuries of the thorax.

(2) *The Search for, and Treatment of, Suppurating Foci of the Lung in Gangrene, Solitary Lung Abscess and Similar Conditions.*—Elsewhere in the body, after incision and drainage of an abscess, its walls usually collapse of their own accord. In the lung, however, anatomical conditions prevent the collapse of an abscess cavity, thus unfortunately insuring the prolonged continuation of the suppurative process.

It is therefore essential not only to establish drainage, but also to render it possible for the abscess walls to approximate.

The different methods for permitting collapse of lung cavities whose walls are elastic, and for actual compression of cavities with rigid walls, are enumerated under "Collapse Therapy in Pulmonary Tuberculosis."

Drainage of Lung Abscess.—The patient should be placed in a position which causes least coughing. He should cough so as to empty the cavity completely just before the operaton is begun. Local anæsthesia

should be employed whenever possible. The chief danger of general anæsthesia is the aspiration of bronchial secretion into healthy portions of the lung with consequent broncho-pneumonia.

Differential pressure apparatus should be in readiness.

Resect a thoracic window 10 × 6 cm. for exploratory purposes, enlarging it according to location of the suppurating focus. Rather resect one too many than one too few ribs.

There is no certain way of diagnosing lung adhesions except by actual exploration.

If adhesions, are present it is well to palpate the lung through the pleura in the hope of localizing the abscess. If this fails, then insert a needle through the adherent area and aspirate in various directions remembering that secondary bronchiectatic cavities usually lie behind and below. If the partly emptied abscess is found, it can be opened immediately; if not, wait a day for it to fill up and then aspirate again.

If adhesions are not present, under primary anæsthesia and positive pressure, the pleura is opened and the lung is rapidly and gently palpated in search of the focus. In case this is found, the parietal pleural opening is made to correspond with the location of the abscess, the lung is sutured to the parietal pleura, or suture is combined with tamponade to wall off the rest of the pleural cavity.

Should the abscess not be found, the lung is sutured to the opening in the chest wall. Adhesions which are artificially produced by suture or tamponade are never as firm as those caused by inflammation. Therefore, in suturing the lungs and intercostal tissues, to protect the pleural cavity, be sure that enough ribs are resected so that the thoracic wall shall follow retraction of the lung sufficiently to prevent undue tension upon the suture. Use a running suture in which the stitches overlap each other (Fig. 494).

Eight to 14 days later when adhesions are firm, and there is no danger of soiling the pleura, aspirate again. This time the abscess should be as full as possible so as to facilitate its location by the needle.

Drainage should not be made at the most superficial point, but rather through considerable thickness of lung tissue, so as to favor subsequent healing.

When pus is found by exploratory aspiration, Garré advises the gradual introduction of a dressing forceps[1] through the lung tissue, alongside the needle, stretching the tissue, then proceeding a little deeper, until finally the abscess is reached. The cavity is now opened widely

[1] Others prefer the Paquelin cautery for opening abscesses in the periphery of the lung and reserve the dressing forceps for use near the lung hilum.

and sponged clean. Gangrenous tissue which has not separated is left undisturbed for fear of hemorrhage. Strands across the cavity usually represent vessels which are to be divided between ligatures. With a headlight, the wall of the cavity should be examined for openings into the adjacent cavities and these must be widened. As said elsewhere never irrigate the pleural cavity or a lung abscess. In both old and recent literature there are plenty of examples of a fatal issue, suffocation or aspiration pneumonia following this procedure. Be careful not

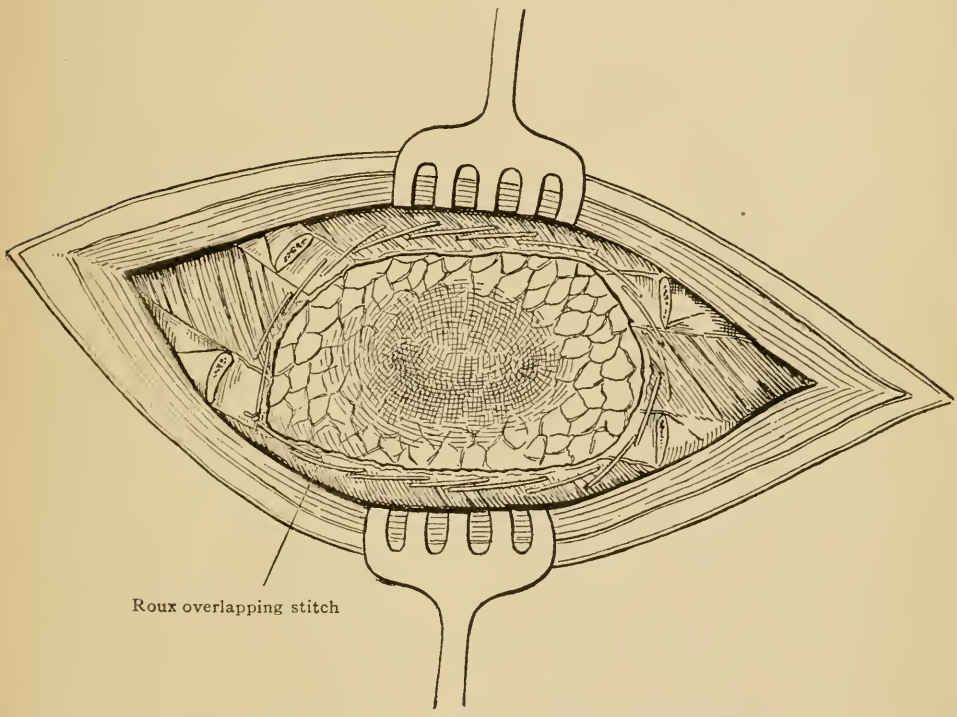

FIG. 494.—Suture of parietal pleura to lung around a lung abscess. Note use of Roux's overlapping stitch. (*Sauerbruch and Schumacher.*)

to allow any gauze packing to lie in the bronchus either at operation or at subsequent dressings, on account of the persistent cough caused by its irritating presence.

Recently formed cavities often heal with remarkable speed.

Chronic rigid-walled cavities must be opened widely by removing as much as possible of their superficial walls. This should be accomplished in two stages: (1) suitable thoracotomy under local anæsthesia, resection of ribs, suture of pleura and lung, all with the abscess as empty

as possible; (2) exploratory aspiration and drainage of abscess. Here no anæsthesia is necessary.

Subsequent resection of adjacent ribs may be required to effect complete collapse. If such a cavity opens into a large bronchus, there may be extreme dyspnœa and distress. Van Stockum (*cit.* after Garré) relieved this condition by covering the wound with rubber tissue.

Subsequent dressings must be carefully managed. The depths of the wound are lightly filled with gauze while its superficial part is firmly packed. This keeps the wound wide and plugs the lung opening, aiding the patient to cough out secretions. The dressings should be changed frequently enough to prevent retention.

Should a bronchial fistula develop, a plastic closure can be made later.

At this time be careful not to remove the thickened pleura, but save it for closing the defect. Free an area of this thickened pleura two fingers in breadth with the fistula at its center, close with layer suture and cover with a flap of suitable soft tissue. (The scapula has been successfully used to cover over the mouth of a pulmonary fistula by A. G. Gerster.)

Foreign Body in the Lung or Large Bronchi.—The following procedures have been suggested:

(1) Bronchoscopy and extraction.

(2) Inferior tracheotomy combined with bronchoscopy through the tracheotomy opening.

(3) Intrathoracic tracheotomy, also combined with bronchoscopy.

(4) Bronchotomy of the main bronchi through the posterior mediastinum (Schwartz) is to be condemned because of the fatal mediastinitis which is almost sure to follow from the unavoidable soiling.

(5) Pneumo-bronchotomy is indicated when the foreign body lies near the periphery of the lung. (See operation for lung abscess, p. 775; also pp. 773 and 774.)

(6) Instrumental extraction under guidance of the X-ray and fluoroscope has been done. It is not safe. There is too great likelihood of more trauma.

Of all these methods simple bronchoscopy is the least dangerous and the most uniformly successful. The subject is too large to be fully treated here but we may say that in skilled hands the field of bronchoscopy takes in not only the discovery and extraction of foreign bodies but also the diagnostic visual exploration of a great part of the bronchial tree. The instruments have been devised by Killian, Brünings, Jackson, Yankauer and others.

Green and Le Wald (Ann. Surg., June, 1916, p. 656) urge the advantages of the Rœntgen-ray and the bronchoscope preliminary to removal by the mouth. Failing removal through the mouth bronchoscopy through a tracheotomy should be attempted; and also the old-fashioned method of urging the patient to cough so as to expel the object through the tracheotomy wound held widely opened should be tried. Early removal is most important so as to avoid subsequent bronchopneumonia and lung abscess. Even though the foreign body has finally been extracted, the lung suppuration is not necessarily cured.

Satisfactory closure of a wound in a large bronchus is very difficult. Do not use through-and-through sutures. Instead, the peribronchial tissue should be united with fine silk and this suture line covered with lung tissue, or with a piece of transplanted fascia.

Operations for Echinococcus Cysts of the Lung.—*Technique.*—After provisional resection of the ribs and opening of the pleura, the lung is palpated and sutured to the pleural wound as nearly as possible over the cyst. The lung tissue is carefully divided until the cyst wall is reached. The cyst is then opened, emptied of its contents and stripped of its inner capsule, leaving the outer fibrous capsule. In non-suppurating cases Walther injects 1 per cent. formalin before opening the cyst, and five minutes later he incises the cyst and obliterates it by suture. By this method he has obtained primary union in cysts of small size. Larger ones have been gradually reduced in size by daily aspiration, so that they were completely emptied by the fifth or sixth day. This permits a gradual collapse of the walls. Small, centrally located cysts should be left until they become of good size, because of the danger of hemorrhage while searching for them in this region. Infected cysts should be opened, and the edges of the sac sutured to the margins of the thoracic wound. They are then packed and allowed to granulate from the bottom.

The Collapse-therapy of Pulmonary Tuberculosis.—This is a new field in which the data are insufficient for drawing definite conclusions. We therefore give the reader the concisely stated opinions of some of the pioneers.

Clinical experience has shown us that when the affected lung is at rest in severe *unilateral pulmonary tuberculosis,* the quantity of the sputum diminishes, there is less cough, the temperature becomes lower, and the patient's weight increases. Pathological examination of diseased lungs which have been collapsed for some time has shown

that a plentiful production of connective tissue has encapsulated and obliterated the foci of disease.

Indications.—Only by repeated observations over an adequate length of time can one determine whether any given case is suitable for collapse-therapy.

The method is indicated in unilateral pulmonary tuberculosis. The opposite side must be comparatively healthy; that is, there must be no recent acute foci. The presence here of chronic slowly progressing foci is, however, not a contraindication.

The types suitable for treatment are:

(1) Recent acute forms of pulmonary tuberculosis.

(2) Older types with a tendency to shrinkage.

(3) Purulent exudates of tuberculous origin. Aspiration and the maintenance of pneumothorax is the method of choice. When this is ineffectual, thoracoplasty may be necessary.

(4) Isolated apical tuberculosis. (For treatment see p. 791.)

(5) Repeated severe hemorrhages with unilateral involvement.

Tuberculosis of the larynx is not a contraindication, nor is high fever with profuse expectoration.

An old, non-progressive process involving even as much as one-third of the opposite upper lobe with no cavity formation does not contraindicate this form of treatment.

Factors opposing the production of lung collapse are:

(1) Large adhesions to the chest wall; these prevent pneumothorax.

(2) Cavities with rigid walls.

(3) Openings into the large bronchi, which naturally cannot collapse and therefore remain open.

Collapse-therapy is *contraindicated* in the presence of tuberculosis of the intestine; even very small foci in the lower lobe of the opposite side; chronic or acute disease elsewhere in the body; and lastly, a general condition which is too poor to justify any operative interference (Garré and Quincke).

Various Means of Causing Lung Collapse:

A. Artificial pneumothorax (Forlanini).

B. Extrapleural thoracoplasty (Friedrich, Wilms, Sauerbruch).

C. Digital loosening of parietal pleura through an intercostal incision, compressing lung by extrapleural introduction of fat or other material within the thorax (Tuffier).

D. Phrenicotomy (Stuertz).

E. Transpleural ligation of pulmonary artery (Sauerbruch).

A. **Artificial Pneumothorax.**—Briefly, the method consists in filling one side of the chest with nitrogen, a neutral gas which is slowly absorbed (oxygen is too rapidly absorbed) replenishing this from time to time so as to maintain the condition until the tuberculous foci have been thoroughly walled in by scar tissue. At least two years are required for completing the cure. In a personal communication to Lilienthal, Kenneth A. J. Mackenzie, of Portland, Ore., stated that he had made animal experiments with paraffin oil to determine its toleration in the thoracic cavity, concluding that the oil was well borne. Lilienthal then suggested its use to replace the gas in an artificial pneumothorax, hoping thus to create a condition of permanent collapse without the necessity for repeated operation because of the absorption of the nitrogen. He has tested the method in a case of lung suppuration following tonsillectomy in which complete artificial pneumothorax had been produced. No disturbance followed the procedure. After a suitable time has elapsed it is proposed to withdraw the oil by aspiration. It is the method of choice when no adhesions exist. Artificial pneumothorax in properly selected cases is increasing in popularity and may be considered a valuable procedure in progressive cases of tuberculosis which do not respond to ordinary sanitarium treatment regardless of the stage of the disease. The accidents, some of them absolutely unavoidable, have among their number the production of spontaneous pneumothorax which may be due to a ruptured adhesion and which may result in empyema as a complication. An extensive bibliography on this subject will be found in an article by Waldren (J.A.M.A., LXVII, 1798). Even when these are present, however, it may be possible to loosen them by gradually increasing the tension of the gas which is injected at some non-adherent point, but if this is not done cautiously, the lung has been known to tear with consequent tuberculous pyopneumothorax or gas embolism. Although many signs and tests are mentioned for determining the presence or absence of adhesions there is in reality no absolutely accurate way of ascertaining conditions except by actual inspection or palpation through a small incision exposing the parietal pleura.

Artificial pneumothorax possesses the advantage over the other collapse measures in that it is temporary, not permanent. In other organs, cessation of function is accompanied by atrophy plus loss of power to regain previous functional activity. With the lung at rest,

NOTE.—Garré states that artificial pneumothorax is an excellent palliative measure for the pain of pleurisy, especially that of carcinomatous origin.

this is not so. Forlanini had two patients in one of whom he maintained an artificial pneumothorax for two years, in the other for seven years. He then allowed the gas to become absorbed and established the pneumothorax upon the opposite side, *permitting the lung which had been put at rest for so long a time to do all the work of respiration.* In



FIG. 495.—Robinson's pneumothorax apparatus. (*Arch. Int. Med.*, April, 1912, IX, p. 452.)

other collapse-methods when once the lung is rendered inactive it must remain so.

Any number of variations of the original apparatus have been made; the Robinson machine has been tried and found satisfactory (Fig. 495).

Technique.—The site of injection should be at a point where no adhesions exist, usually the fifth, sixth or seventh space in the anterior axillary line. Avoid the neighborhood of the heart or diaphragm. Also avoid any place where râles are heard. The patient's position

should be such that the puncture opening will be at the highest point of the chest. This will cause the gas as it is injected to remain directly around the puncture opening and push away the adjacent lung from the point of the needle.

Two methods of injection are in vogue: one is simple puncture (Forlanini) with its dangers of perforation of the lung with hemorrhage or gas embolism; the other, more rational way (Brauer[1]), is to make a small incision down to the pleura which is exposed (Fig. 496) and then puncture under the guidance of the eye. This minimizes the chances of injury to the lung. It is necessary only at the time of the first operation not at subsequent ones.

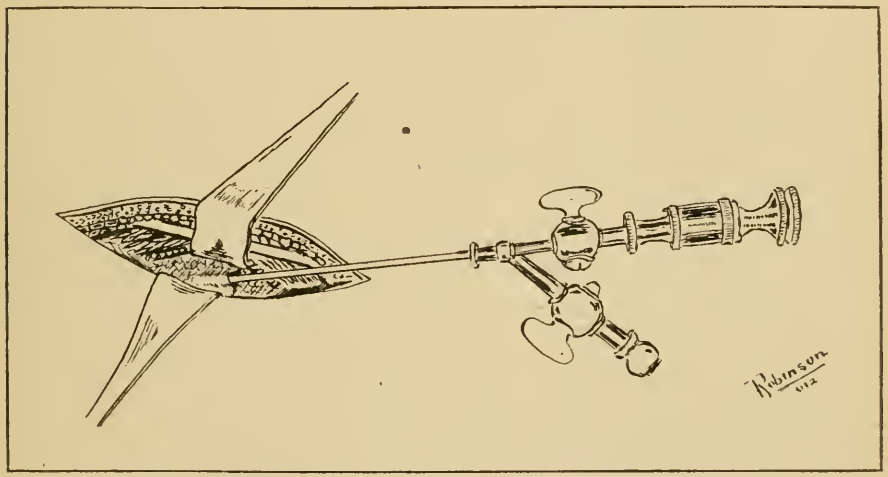

FIG. 496.—Artificial pneumothorax. Pleura exposed through small incision. Puncture under guidance of eye to avoid injury to lung. (*After Robinson.*)

One should be largely governed by the subjective sensations of the patient. Local anesthesia is therefore indicated, but a morphine injection shortly before the operation may tend to lessen the patient's apprehension. When the needle has perforated the pleura inject a few more minims of the local anæsthetic. The manometer shows characteristic variations sinking to 0 on inspiration and rising to +3 mm. to +6 mm. of Hg. on expiration when the needle is in place and without such manometric variation *no injection should be made.*[2] Quincke advises injections of 50 to 100 cc. of oxygen before admitting any nitrogen to the pleural cavity. He argues that even if the lung itself

[1] Beitr. z. Klin. d. Tuberkulose, 1909.

[2] A water manometer is used because it registers variations of pressure more promptly and, because of its wider excursions, much more plainly then a mercury manometer.

has been perforated by the needle point the oxygen is quickly absorbed, and there will be less danger of fatal pulmonary embolism.

Upon the slightest indication of distress injection must instantly cease. If the distress subsides after a few moments, one may cautiously inject a little more. If this causes aggravation of the symptoms, it is well to withdraw the gas little by little, letting out just enough to ease the patient. The symptoms of so-called pleural shock observed at paracentesis of the pleura are now often recognized as the symptoms of air embolism.

At the first sitting 500–1000 cc. of nitrogen are usually injected; the second follows in a day or two. The intervals are gradually lengthened as the nitrogen-absorbing power of the pleura lessens, so that finally injections need only be given once every three or four weeks.

The X-ray forms an indispensable guide to conditions produced in the chest by this form of treatment. The degree of pneumothorax and the presence or absence of adhesions which have been stretched like bands between the surface of the lungs and the parietal pleura can readily be estimated with the fluoroscope.

The pneumothorax is maintained until the foci become walled off by a capsule of dense fibrous tissue; as said above, this usually requires two years or more.

It is sometimes possible to stretch adhesions gradually by raising the pressure to 20, 30, or even 45 mm. Hg. Naturally there is some pain accompanying this procedure.

In certain instances the unavoidable additional work thrown on the opposite lung by unilateral pneumothorax has resulted in an exacerbation of tuberculosis in the over-active lung. While this is true of recent processes, old processes tend to become more and more encapsulated.

Artificial pneumothorax may be used as an aid to the other means of bringing about collapse and compression of diseased lung tissue (see other methods described below).

Extrapleural thoracoplasty is indicated when artificial pneumothorax is impossible because of adhesions.[1]

The extrapleural thoracoplasty of Sauerbruch or Wilms does not cause the complete collapse obtained by artificial pneumothorax. According to Cloetta's findings, the lung's circulation is most plentiful at a

[1] The density of lung adhesions is an unknown quantity. Attempts to loosen them by artificial pneumothorax or by open operation have resulted in tearing open cavities and causing empyema of the pleura.

pressure of 3 mm. Hg. Hence thoracoplasty tends to give practical cessation of function with marked retraction and maximal circulation.

Sauerbruch who has had such brilliant results with this operation,[1] states that the cases he selected consisted solely of those in which the prognosis was bad. Only those individuals who showed a steady downward progress in spite of all hygienic and therapeutic measures were selected for operation.[2]

Various Methods Employed.—While *total removal of the bony constituents of the thoracic wall* (Friedrich) effectually collapsed and compressed the lung, it left the mediastinum without adequate support. Consequently the opposite lung could not expand or contract properly, and the patient suffered constant dyspnœa.

The *methods of Wilms and of Sauerbruch* are practically the same. They consist in removing portions of the ribs close to the angles behind and close to the sternum in front (Figs. 497 and 498). This permits the chest wall to move *en masse* toward the median line, collapsing the lung and yet affording support for the mediastinum.[3] The details of this procedure are as follows:

The *position of the patient* is the semi-upright posture mentioned under "General Operative Procedures." The head is bent forward and the arm of the affected side is extended anteriorly, and held in this position by an attendant.

Anæsthesia.—0.5 per cent. novocain-adrenalin solution is recommended by Sauerbruch; 100 to 200 cc. of this may be employed without fear. Linear infiltration of the skin is followed by blocking the nerves as described above.

The *location of the incision* will depend upon the portion of the lung to be collapsed. The typical incisions are the paravertebral and parastèrnal.

The paravertebral incision (Figs. 499 and 501) runs from the fourth to the eleventh ribs. The soft parts are bluntly separated toward the front. The periosteum is split and the rib is resected. It is best to begin at the lowermost rib and resect 10 to 12 cm. from angle of rib outward to the posterior axillary line, lessening the amount removed from each successive rib as the operation proceeds upward. If the

[1] Sauerbruch and Elving, Ergebnisse der Inneren Medizin u. Kinderheilkunde, 1913, Band 10, p. 869.

[2] Sauerbruch conducts the surgical clinic at Zurich. The patients referred to him for operation have all been under the prolonged and competent observation of the expert internists at Davos and other nearby sanatoria for tuberculosis.

[3] Sauerbruch first does the paravertebral operation and observes its effect. If collapse effect is insufficient, he then makes the parasternal operation. Wilms does both at the same time.

condition of the patient is still good by the time the fourth rib is reached, the incision may be continued upward and the uppermost ribs exposed and resected. The muscles attached to the scapula may be drawn aside

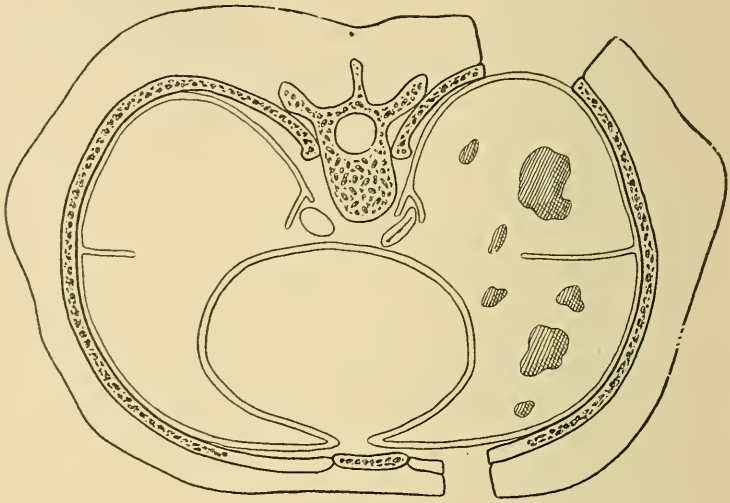

Fig. 497.

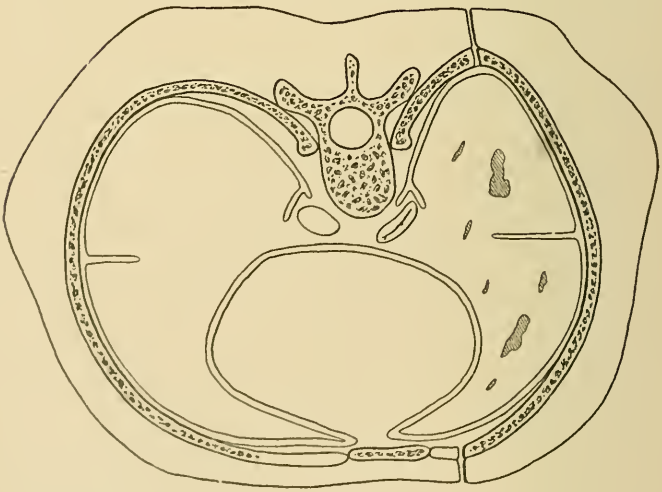

Fig. 498.

Figs. 497 and 498.—Extrapleural thoracoplasty. 497, Before; 498, after closing gap left by resection of ribs. (*Wilms.*)

or cut across. If the scapulo-thoracic muscles are separated in the direction of their fibers in two or three places, sufficient room may be obtained for reaching ribs without cutting across muscular fibers.

After resection of the ribs the soft parts are reunited with catgut, the skin is closed with a running silk suture taking alternate small and large stitches, the lower angle of the wound is drained, and an elastic compressive dressing is applied to the affected side of the thorax. the well side being left free.

Fig. 499.—Extrapleural thoracoplasty. Paravertebral operation. (*Sauerbruch.*)

In the parasternal operation (Fig. 500) the patient lies upon his back with arm abducted. The incision runs inward along the lower margin of the clavicle, then bends downward over the costal cartilages to the third rib. The pectoralis major is divided along this line and drawn aside. To afford easier access to the first rib, the second rib is first extensively resected. Sauerbruch advises the following technique.

After division of the periosteum along the lower margin of the

first rib, the rib is divided by a narrow groove made by removing the bits of tissue with a small narrow Lüer rongeur. The subclavian vein is then pushed aside and upward with the left index-finger, which holds it in this position to guard it from injury. As much rib is then removed as is feasible with the rongeur; the third and fourth ribs are then cut away in the usual manner. Muscle flaps are interposed between the divided ends to prevent union.

When the first rib is very deeply situated, it may be divided by a Gigli saw passed around it with an aneurism needle. Should the degree of collapse still be inadequate, part of the clavicle may readily

FIG. 500.

IG. 501.

FIGS. 500 AND 501.—500, Parasternal and 501 paravertebral incisions. (*Sauerbruch.*)

be resected. Should the fragments of the divided bone over-ride one another, the shortening and the collapse effect are still further increased.

In any type of extrapleural thoracoplasty, injury of the pleura is not of frequent occurrence, because of its thickened character. Nevertheless, differential pressure apparatus should always be at hand in case such a complication should arise.

Speed is a prime requisite. The entire operation should never consume more than 40 minutes. Sauerbruch takes from 20 to 25 minutes, as a rule. Most of the time is taken up in the careful closure of the wound. Performing this operation in several stages will lessen the danger.

Extrapleural thoracoplasty by the osteoplastic resection method of Wilms has been performed under morphine and scopolamin narcosis

with negative pressure apparatus and reported by Zinn and Muhsam (Berlin. Klin. Woch., 1915, p. 71). There was a 50 per cent. mortality in the six cases thus operated upon.

After-treatment.—A somewhat exhausted patient should be actively stimulated. When the respiration is embarrassed, an elastic compressive dressing over the resected lower ribs affords much relief (Fig. 502). The patient is most comfortable sitting with the foot of the bed raised,

FIG. 502.—Front and rear views of elastic compressive dressing over affected side after extrapleural thoracoplasty. (*Sauerbruch and Schumacher.*)

breathing and expectoration being easier in this position. For the first few days after operation, a nurse must watch both day and night for the slightest rattling indicating an accumulation of secretion. As soon as this is heard, the patient must be made to expel the mucus to avoid the danger of aspiration into an uninvolved part of the lung.

At first there is apt to be high temperature and almost no sputum. A few days later there is a plentiful amount of sputum. From now on, the height of the temperature and amount of sputum run a parallel

course. In favorable cases the temperature gradually subsides. A fever which persists longer than 12 to 16 days after operation is of bad prognostic significance. As the temperature and amount of sputum decrease, the appetite and general condition improve, as shown by the increase in weight. The patients should get up as soon as they feel able—usually by the end of the second week.

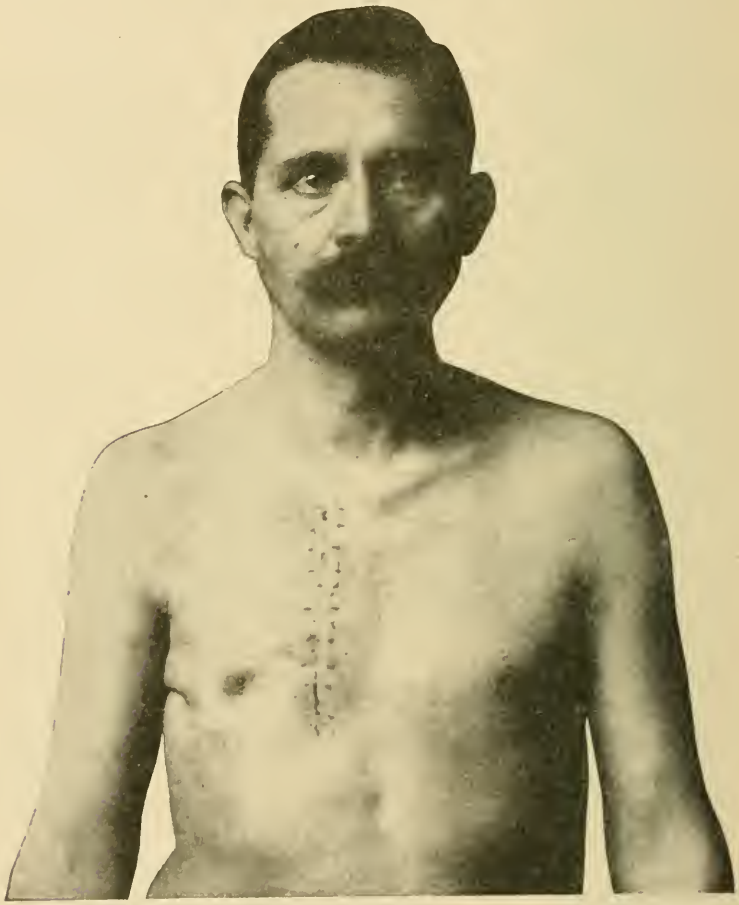

FIG. 503.—Five weeks after extrapleural thoracoplasty of right side. (*Patient of Wilms.*)

There is little deformity after paravertebral or parasternal thoracoplasty (Fig. 503). There may be a slight lateral curvature of the spine, but this is not sufficiently marked to be of practical importance.

Combinations of Methods.—The methods adopted should fit the individual case; no general rule is possible.

In a purulent exudate of tuberculous origin, aspiration plus the pro-

duction of more or less pneumothorax was ineffectual in one of Sauerbruch's cases. He, therefore, performed an extensive paravertebral resection of the ribs (I to X). After mobilization of the chest wall, the exudate was removed secondarily. The result was excellent.

Experience has shown that localized collapse of a diseased cavernous upper lobe frequently led to infection through aspiration of a healthy lower lobe on the same side. Conversely, it was found that putting a healthy lower lobe at rest had a beneficent effect upon a diseased upper lobe.

Under all circumstances the lower lobe should first be allowed to collapse by pneumothorax, thoracoplasty, or phrenicotomy before attempting to collapse the upper lobe (Sauerbruch).

In isolated apical tuberculosis both Sauerbruch and Wilms advise collapse of the lower lobe by artificial pneumothorax followed by collapse of the apical part by means of a suitable plastic operation.

NOTE.—Resection of the ribs in the axillary region, a technically easy procedure, does not cause an adequate shrinking of the chest cavity.

Collapse-therapy for repeated hemorrhages is not always successful because of the difficulty of effecting adequate compression of cavities with rigid walls.

In rigid-walled cavities additional compression may be obtained by depressing the scapula under the projecting vertebral ends of the ribs and fixing it in this situation. This will, however, be followed by some limitation of the movements of the shoulder.

In one instance Garré opened the chest and packed the lung against the mediastinum, suturing the base of the lung to the dome of the diaphragm.

Sauerbruch mentions a case in which there was extensive fibrosis of the lung with cicatricial contraction, which pulled upon the trachea causing it to kink; this gave rise to extreme dyspnœa. A suitable thoracoplasty allowed the lung to sink inward, and relieved the tracheal angulation.

C. **Tuffier's Method.**[1]—To obliterate an apical cavity without opening the pleura, Tuffier[1] strips the parietal pleura from the ribs and vertebral column, beginning his separation in an intercostal space, usually the second. The fibrous bands between the pleura and ribs are weak and easily broken; those between the pleura and spinal column are firm and proportionately hard to overcome. Compression of the lung is obtained by plugging the space thus created between the

[1] Semaine Med., 1891, p. 202. Also, Z. f. C., 1913, p. 1286.

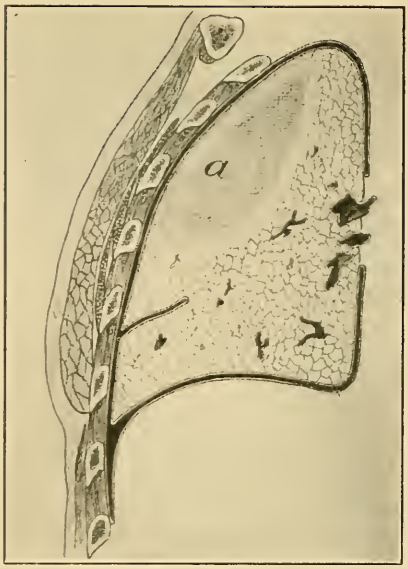

FIG. 504—Schematic representation of a diseased apex. (*Tuffier.*)

FIG. 505.—Extrapleural compression of the lung after freeing of the parietal pleura. (*Tuffier.*)

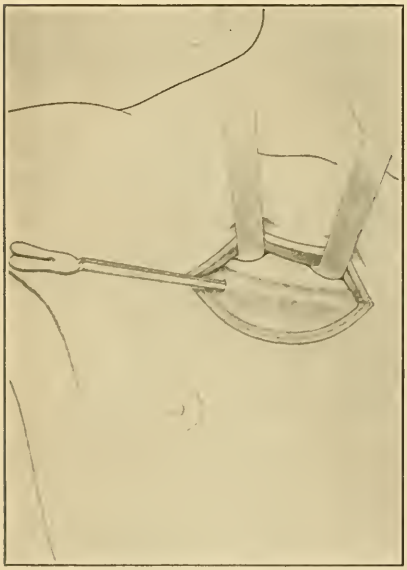

FIG. 506.—Exposure of second interspace. (*Tuffier.*)

FIG. 507.—Finger introduced after division of intercostal muscles. (*Tuffier.*)

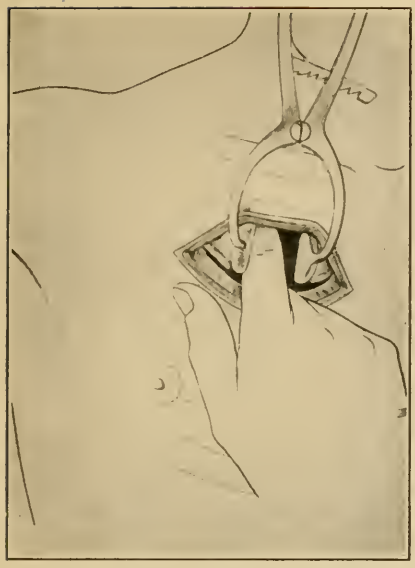

FIG. 508.—As more pleura is freed a spreader is inserted to keep the ribs apart. (*Tuffier.*)

FIG. 509.—Insertion of a funnel through which fat or other tissue is packed. (*Tuffier.*)

FIG. 510.—Funnel as it is actually used —a greased cloth keeps air from drying the tissues. (*Tuffier.*)

FIG. 511.—Greased cloth which keeps air from drying the freed parietal pleura. (*Tuffier.*)

parietal pleura and the ribs with adipose tissue or any other suitable material (Figs. 504–511, inclusive).

According to Lenormant (Presse med., 1913, p. 786), Tuffier began his extrapleural compression of the lung in 1910. The five cases he showed at the International Congress in Brussels in 1911 were all cases of gangrene or abscess. Tuffier began to use this procedure in tuberculosis only in 1912. Sauerbruch, Baer, Jessen, Tavel and others have used the method with success.

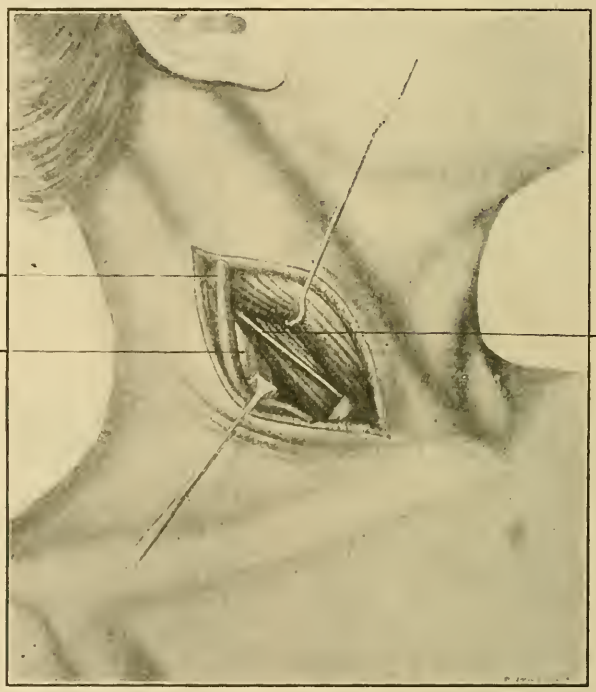

FIG. 512.—Phrenicotomy. Exposure of phrenic nerve in neck. (*After Ochlecker.*)

Do not try to separate the apex of the lung from the parietal pleura, because of the danger of injury to the subclavian vein. It is better to use a suitable thoracoplasty (Garré and Quincke).

D. **Phrenicotomy.**—Phrenicotomy is done to insure inactivity and partial collapse of the lung by paralysis of one-half of the diaphragm.

Technique.—With the head turned to the opposite side, an incision is made along the posterior margin of the sterno-mastoid muscle. The external jugular vein is retracted or divided, the sterno-mastoid is drawn over mesially, and the phrenic nerve is seen running downward

and forward on the surface of the scalenus anticus forming an acute angle with the brachial plexus (Fig. 512).

Stuertz (Deutsch Med. Woch., 1911, p. 2224) was the first to advocate cutting the phrenic nerve in order to afford complete rest to the affected lung. Friedrich divided the nerve when thoracoplasty was inadequate for his purpose.

According to Oehlecker (Zentralblatt f. Chir., 1913, p. 852) the phrenic nerve contains sensory as well as motor fibers. These supply the under surface of the diaphragm as well as its upper surface and the corresponding region of the pericardium (Fig. 513). The production of referred pain in the shoulder from irritation of the phrenic by lesions in

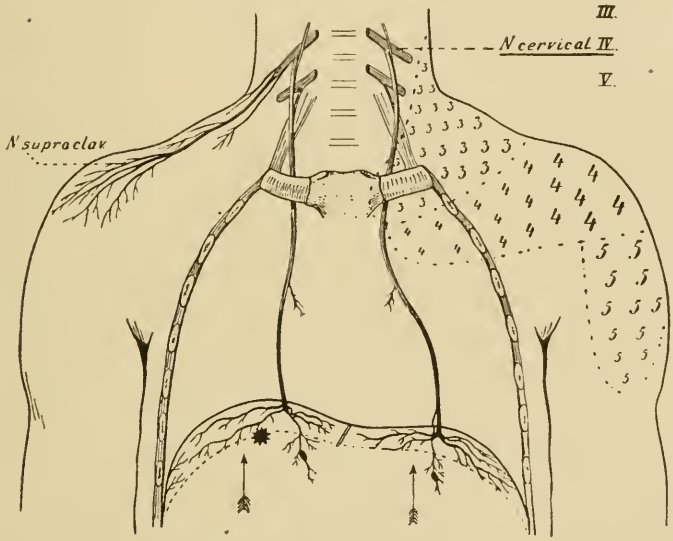

Fig. 513.—Origin and distribution of phrenic nerve. To illustrate production of shoulder pains from irritation of phrenic nerve in morbid subphrenic conditions. (*Oehlecker.*)

the thorax or upper abdomen is explained in the accompanying diagram. As proof of this he cited two cases in which the nerve was divided under local anæsthesia for chronic tuberculous empyema with persistent pain in the shoulder. The pain was instantly relieved by division of the nerve, and furthermore pinching of the central nerve stump promptly evoked the typical shoulder pain (Fig. 513).

After phrenicotomy, X-ray shows the diaphragm on the affected side higher than usual, and motionless in this position.

Transpleural Ligation of the Pulmonary Artery (Sauerbruch).—This is indicated when one lobe only is affected, and in the absence of adhesions.

(When cavities are dense walled or the entire lobe is affected, an extrapleural thoracoplasty is the best treatment.)

The patient is placed in a semi-reclining position and the trunk is bent over a cushion. Thoracotomy is done through the fifth interspace.

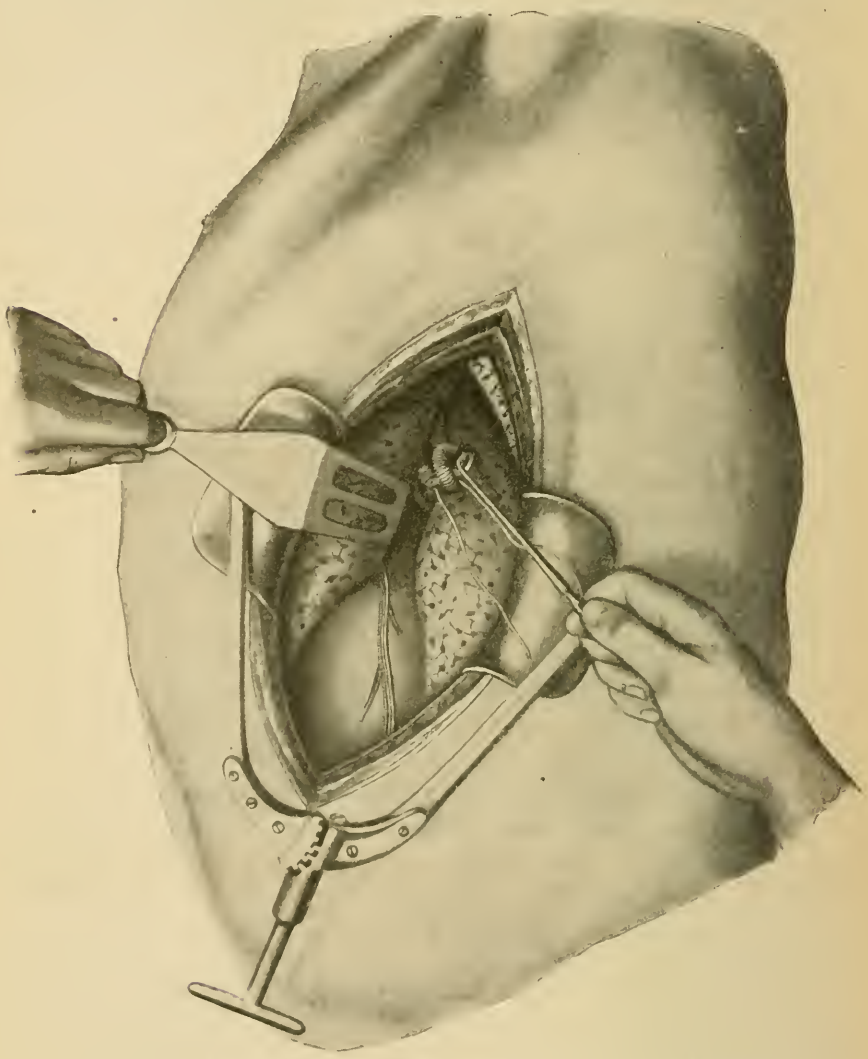

FIG. 514.—Transpleural ligation of pulmonary artery. (*Sauerbruch and Schumacher.*)

The upper and lower lobes are separated in the interlobar fissure. The differential pressure should be low, about 5 mm. Hg. The relation of structures at the hilum is *artery, bronchus vein,* from above downward. The artery, which is uppermost, is raised up on a blunt hooklet, a

ligature is passed with an aneurism needle and the artery is tied (Fig. 514). When the pulmonary artery divides nearer to the heart, a number of its branches must be secured.

After ligation the lobe shrivels to a mass of dense connective tissue.

Interlobar adhesions are frequently found, their extent and density being subject to wide variation. If they are very dense, it may be impossible to reach the vessels at the hilum. Furthermore, variations

FIG. 515.—Extirpation of entire left lung. Patient alive and well 20 years after. (*Macewen.*)

in division of the pulmonary artery are quite frequent and leave the surgeon in doubt as to the completeness of his operation, namely, whether all the vessels have been tied which should have been tied.

These obstacles suggested to Willy Meyer (Annals of Surgery, Aug., 1913, p. 201) the idea of ligating the left or right pulmonary arteries before their division into branches, viz., their intrapericardial ligation. Up to now this operation has not been carried out in man.

Pneumectomy.—In August, 1913, MacEwen of Glasgow showed a man in sound health from whom he had removed a tuberculous lung at a series of operations more than 20 years ago (Fig. 515).

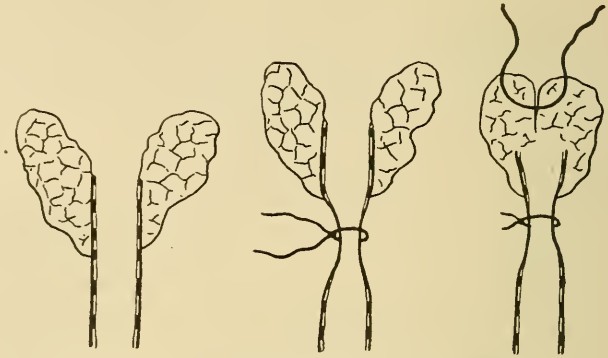

Fig. 516.—Tiegel's method of closing bronchial stump.

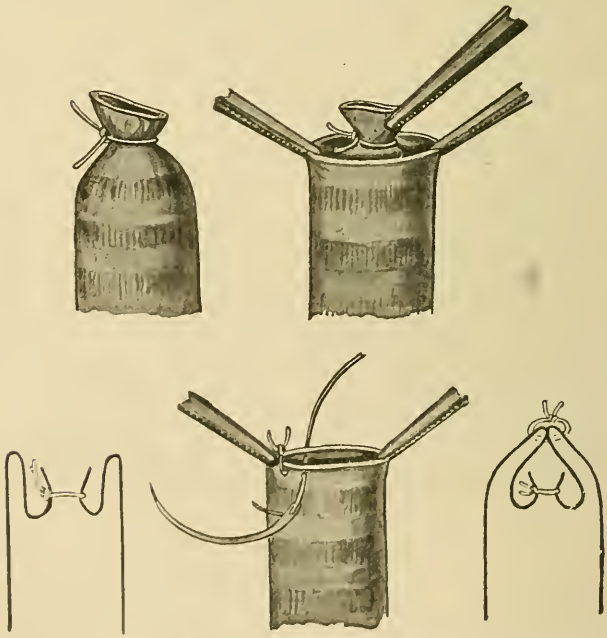

Fig. 517.—Willy Meyer's method of closing bronchial stump.

There are two mechanical conditions to which attention must be brought. First, at the time of operation as soon as the bronchus has been ablated, it tends to retract into the mediastinum as Sauerbruch says, like a turtle's head into its shell.

In a normal hilum, this danger is very great, but when the lung hilum is fixed by infiltrating adhesions, the tendency of bronchial retraction into the mediastinum is not so marked.

A second danger is leakage from the bronchial stump several days after operation. Simple circular ligature invariably cuts through. Tiegel sutures lung tissue over the stump of the bronchus (Fig. 516). Willy Meyer[1] treats the bronchus like an appendix stump (Fig. 517).

Both of these methods should be combined whenever feasible.

Sauerbruch advises a preliminary artificial pneumothorax, and the actual extirpation some weeks later.

Tuffier's Extrapleural Resection of Lung.[2]—This operation deserves special mention. It is indicated in early apical tuberculous consolidation. The parietal pleura is exposed through an intercostal incision of the second interspace. It is stripped from the inner aspect of the thoracic wall by very gentle repeated pressure of the fingers, the incision being kept open by a spreader. In this way the entire apex of the lung covered by its costal pleura is freed. A stout encircling catgut ligature is tied beyond the diseased portion and the apex cut away. The lung is simply released, the stump not touched with antiseptic or cautery, and dropped back beneath the ribs. The chest wound is closed in the usual manner, leaving a dead space formerly occupied by the diseased apex. Within a few weeks the lung and pleura expand so that breath sounds are heard again above the clavicle.

It appears to the writers that the chemical disinfection of the stump in this operation could do no harm and might add an element of safety. Tuffier (Rev. de therapeut., p. 649, 1913) believes that the resection of diseased tuberculous apices will be the operation of the future. He believes that even if many small foci remain behind, there is every likelihood of their being encapsulated after removal of the principal focus at the apex.

Division of the first costal cartilage in early apical tuberculosis was proposed by W. A. Freund in 1858. He believed that by this means the aeration of the lung apex would be improved. Of later years this operation performed now with the aid of local anæsthesia has again come into favor.

The incision is made parallel to the upper margin of the clavicle and then downward along that side of the sternum. The clavicular portion of the pectoralis major is separated from the sternal portion,

[1] Carrel in a personal communication states that in his operations on animals he crushes the bronchus, ligates and carbolizes the stump.

[2] International Congress of Surgery, London, 1913.

and the cartilage is divided with a rongeur, after division and retraction of the perichondrium. A muscle flap is interposed between the ends to prevent union.

The technique of *Freund's operation for emphysema* (the indications for which have been already touched upon, page 775, is as follows:

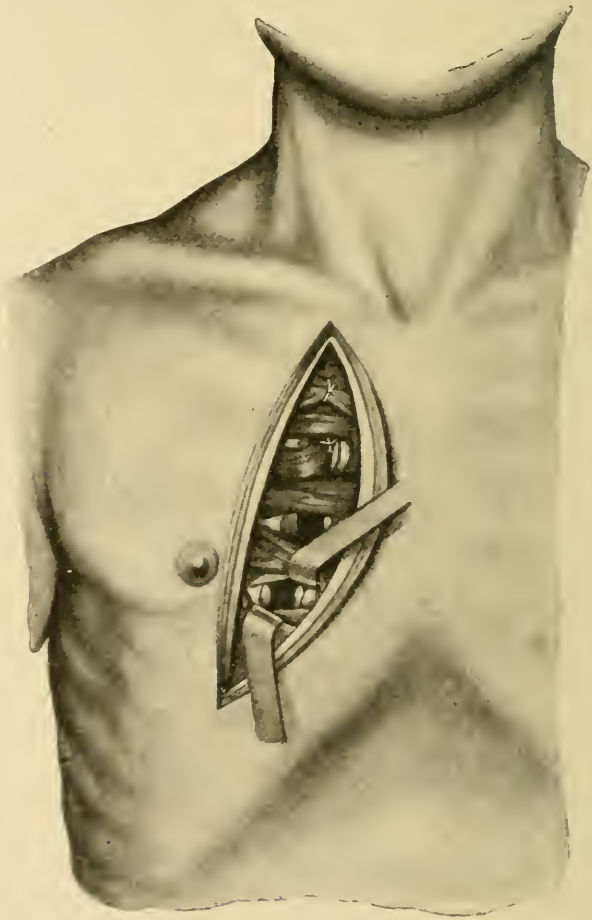

FIG. 518.—Freund's operation for emphysema. Resection of 3 cm. from each of 2nd to 5th costal cartilages. Flaps of muscle turned in to prevent regeneration and subsequent reunion. (*After Sauerbruch and Schumacher.*)

Under local anæsthesia, the second to the fifth costal cartilages are resected for a distance of 3 cm. The unilateral operation is often sufficient. Great care must be exercised in avoiding injury to the friable pleura. To prevent regeneration and subsequent union, the flaps of muscle are interposed between the cut ends of the cartilages or the

perichondrium is seared with the Paquelin cautery (Fig. 518). Usually it is unnecessary to divide the first rib.

It is remarkable to see how the thoracic play begins as soon as cartilages have been divided.

FIG. 519.

FIG. 519.—Case of F. W., 4 years old, one year after the extirpation of right lower lobe for diffuse bronchiectasis following aspiration of some pieces of nut more than a year before. Empyema followed the operation. The necrosed stump came away without air leak. Note symmetry of body.

A firm compressive elastic bandage is applied after the wound has been dressed.

Samuel Robinson of the Mayo Clinic has been working along the "two stage" line in lobe-excision. At the meeting of the Section on Surgery of the American Medical Association in June, 1917, he reported

successful cases in which the extirpation had been preceded by an operation to secure adhesion of the healthy part of the lung to the chest wall. At the subsequent stages, in spite of the fact that open mask anæsthesia was employed, there was no respiratory or cardiac embarrassment. The results in the cured patients show external thoracic deformity following the multiple rib resections. The principle of securing adhesions between healthy lung and costal pleura before undertaking lobe resection is a sound one though it is not always applicable.

Fig. 520.

Fig. 521.

Figs. 520 and 521.—Case of Dave J., 19 years old, one year after resection of middle lobe for bronchiectasis. Bronchial fistula closed spontaneously a few months after operation. Note symmetry and also function of arms and shoulders.

Bronchiectasis treated by any other method than extirpation of the diseased part will show, perhaps, some improvement but there will be no cure. With extirpation of the bronchiectatic tissue a complete cure may result. The operation is formidable but in the absence of too diffuse an involvement we have found it worth while. It promises far more than the other methods of operative therapy or their combinations, namely, (1) artificial pneumothorax, (2) external thoracoplasty, (3) ligation of a branch of the pulmonary artery.

One of the writers (Lilienthal) has performed extirpation in five

cases. Four patients are well, and one died.* The fatality resulted from a mediastinal flutter following the extirpation of the entire right lower lobe. There were two cases in which extirpation of the right lower lobe was followed by complete recovery. One of the patients had diffuse bronchiectasis (Fig. 519), and an other had indurative pneumonia with miliary abscesses. Another patient recovered after resection of the middle lobe for bronchiectasis (Fig. 520 and 521), and the case of the last one, a woman 36 years old, is not yet finished.† In all these operations the anæsthetic was administered by the intrapharyngeal method and the pedicle was treated by preliminary crushing with clamps, then ligation in sections with chromicized catgut. The cut stump was then touched with pure phenol. The mediastinum was supported by fastening a suture through the pedicle to the thoracic wall. The pedicle, itself, however, was not drawn to the ribs but was merely steadied by the ligature until adhesions formed between lung and parietal pleura. In two of the cases there were temporary bronchial fistulæ.

"There is no case of bronchiectasis in which a complete cure has resulted from a pleural injection of gases or fluid" (Frazier., Prog. Med., March, 1913, p. 71).

Robinson of Rochester, Minn., advises artificial pneumothorax as a preliminary step to excision in bronchiectasis.

* Other cases, since this paper was written, will be reported later. The mortality appears to be about 40% but the "cured" patients are well.

† Now well for 1½ years.

INDEX

A

Abbe. X-ray ulcers, 7
Abduction frame, 662
Abnormal subclavian artery, 751
Abscess, Brodie's, 485
cold, lower limb, 472
hand, 234
hip, tuberculosis, 515
ischiorectal, 471
liver and subphrenic transpleural drain, 744
lower limb, 471
lung, 772, 775
lung, exploratory puncture, 774
mediastinum, 745
palmar, 237
thoracic wall, 745
tuberculous knee, 524
Absence, bones, arm, 309
tibia and fibula, 592
Acapnia, 706
Acetabulum, fracture, 397
Acidosis, gangrene, 561
Acromion, fractures, 32
Active movements, joints, 633
Actinomycosis, lung, 774
Acute arthritis, shoulder, 316
bursitis, shoulder, 317
rheumatic synovitis, 499
synovitis, 487
Adductors, thigh, division of, 662
rupture, 334
Adenopathies, groin, 445
Adhesion molecular pleura, 709
Adiposis dolorosa, 440
After treatment, congenital dislocation, hip, 655
elbow, 129
hip, 396
operation, semilunar cartilage, 435
spastic paraplegia, 664
Pott's fracture, 578
tendon transplantation, 638
thoracoplasty, 789
Age for operation, tendon transplantation, 639
Albee. Operation, tuberculous hip, 521
Albert's disease, 554
Alcohol injections, spastic paralysis, 295
Alexander. Volkmann's contracture, 22
Allison. Silk tendons, 677
Altschul. Sarcoma, bone, 456
Amputations. Carden's, 683
cinematic, 320
gangrene, 561
Gritti's, 684
in sarcoma, bone, 456, 458
interilio-abdominal, 688
interscapulo-thoracic, 289, 323
Lisfranc's, 681
lower extremities, 681
Marjolin's ulcer, 462
neuroma, 442
Sabanejeff's, 684
stump, 682
Symes, 681
upper extremities, 319
Wyeth's, 687
Anastomosis, arterio-venous, 559
nerve, 8
œsophagus to stomach, 766
Anatomic neck, humerus, fracture, 38, 62
Anatomy, tendon sheaths, 228
Anchylosis, elbow, 329
hip, 694
knee, 700
shoulder, operation, 327
wrist, 331
Auerbach. Hernia lung, 740
Anesthesia, chest operation, 740
exploratory thoracotomy, 730
intrapharyngeal, 711
intratracheal, 712
local arm, 26
chest wounds, 727
disarticulation shoulder, 323
operation, lung abscess, 776
palsies, 12
Anesthetometer, 712

Aneurism, arterio-venous, 558
bone, 288, 458
brachial, 17
groin, 444
lower extremity, 562
popliteal, 460
upper extremity, 241
Aneurismorrhaphy, 565
Angel-wing paralysis, 307
Anger. Silk tendons, 676
Angle carrying arm, 40
Ankle, abduction fracture, 370
arthritis deformans, 530
arthrodesis, 668, 669, 675
arthrotomy, 707
bursæ, 553
Charcot's disease, 536
deformities, paralytic, 629
dislocation, 409
diseases of, 494
flail, 678
gonorrhœal arthritis, 510
plication ligaments, 676
syphilis, 504
tenosynovitis, 556
tuberculosis, 525
tumors of, 466
Aorta, compression, 686
Ape hand, 15
Apnœa, 707
Apparatus, artificial pneumothorax, 782
differential pressure, 709
intratracheal, anesthesia, 712
Zandler's, 299
Arch foot, strains, etc., 609
Arm, amputation, 321
arthropathies, 208
bone cysts, 182
bursæ, 19
carrying angle, 40
deformities, 305
diseases, 149
fractures, 35
gangrene, 249
gonorrhœal arthritis, 189
injuries to muscles, 20
muscles, diseases, 215
osteomyelitis, 160
paralyses, 291
rickets, 308
traumata, 1
tuberculous arthritis, 192
Arm, traumatic neuritis, 16
tuberculous osteitis, 172
tumors, 255
vessels, injuries, 16
Arrest, growth upper extremity, 292
Arsenic, sarcomata, bone, 459
Arterial suture, 18
thrombosis and embolism, 560
Arteries, arm, ligature, gangrene, 16
injuries to, fracture, humerus, 61
lower extremity, ligation, 564
Arteriorrhaphy, arterio-venous aneurism, 558
Arterio-thrombosis, 560
Arteriotomy embolism, 561
Arterio-venous aneurism, 558
arm, 244
groin, 444
Arteriosclerosis, lower extremity, 559
Arteritis, lower extremity, 557
Artery, brachial, thrombosis, 17
intercostal, wounds, 722
internal mammary, wounds, 722
pulmonary, embolism, 752
ligation, 780, 795
subclavian, aberrant, 751
ligature, gangrene, 16
preliminary ligation, 321
Arthralgia, 491
Arthrectomy ankle, 527, 701
elbow, 328
hip, 692
knee, 525, 699
shoulder, 324
wrist, 329
Arthritis, acute, lower limb, 487
ankle, 494
arm, 168, 169, 188
deformans, 528
arm, 202
degenerative, 528
dry, 691, 698
gonorrhœal, 507
arm, 189
gouty, 545
hip, 497
knee, 491, 497
neuropathic arm, 208
pneumococcal, 506
rheumatoid, 345
shoulder, 316
syphilitic, 501

Arthiritis, syphilitic, arm, 201
hip, 501
tuberculous, arm, 192
typhoid, 505
Arthrodesis, 625, 667
ankle, 675
midtarsal joint, 673
shoulder, 301, 327
Arthroplasty, elbow, 303, 329
hip, 694
knee, 700
shoulder, 66, 327
wrist, 331
Arthrotomy, ankle, 701
elbow, 328
hip, 692
knee, 494, 698
sabre-cut, shoulder, 326
shoulder, 324
Articular capsule, sarcoma, 466
lipomata, 460
rheumatism, acute, 499
Artificial ligaments, 677
elbow, 303
pneumothorax, 780, 781
Ashurst. Elbow injuries, 54
Asphyxia, 707
Aspiration, after chest operation, 744
chest wounds, 725, 726
hip joint, 691
knee, 697
oxygen replacement, 728
pleura, 756
shoulder, 324
Astragalectomy, claw foot, 607
Ataxia, hereditary, 604
Atrophy upper extremity, 292
Auer and Gates. Epinephrin, 721
Automobile fracture, 87
Auto-transfusion, extravasated blood, 721
Avulsion arm, 3
tendons, 25
Axhausen, arthritis deformans, 529
Axillary folliculitis, 151

B

Baer's membrane, shoulder, 327
Bands, metal, aneurism, 565
Bar on sole, metatarsalgia, 618
Bardenheuer. Treatment, fracture, 363
Barker. Arthrectomy hip, 692
Barlow's disease, bone cysts, 453
Beattie. Infection from tonsils, 499
Beck's paste, 485
Beitzke. Arthritis deformans, 529
Bennett's fracture, 92
Bergermann. Ganglia, 468
Bernheim. Vascular suture, 18
Beurmann. Sporotrichosis, 159
Biceps, dislocation, tendon, 61
Bier's hyperemia, 333
ankle, 527
intravenous anæsthesia, 26
osteoplastic amputation, 682
Bigelow. Dislocation, hip, 394, 395
Bilateral pneumothorax, 707
Billings. Arthritis deformans, 203, 205
Birth palsy, 291, 295
Bismuth paste, 485
Blastomycosis, arm, 156
Blocking phrenic nerve, 739
Blood, auto-transfusion, 721
Blood in joints, 544
Bloodgood. Bone cysts, 187, 454
Brachial thrombosis, 17
Myositis ossificans, 22
Sarcoma, arm, 280
Blood-vessels, arm, injuries, 16
ligation, gangrene, 16
injuries, fracture, clavicle, 29
fracture, humerus, 61
lower extremity, 557
Bodies, floating joints, 540
rice, tendon sheaths, 556
Body, foreign, in lung, 778
Boils, lower limb, 471
upper extremity, 149
Bone, abscess, 485
aneurism, 288, 458
arm, absence of, 309
cysts, 453
arm, 182
distortion, arm, 308
felon, 232
foot, exostosis, 469
grafts, 454, 459
leg, tumors of, 465
lower limb, diseases of, 479
metastatic tumors, 456
methods of filling cavities, 485
occupational changes, 345
pulsating tumors, 458

Bone, sarcoma, arm, 285
statistics, 456
Boots, errors in, 609
for flat-foot, 613
Bothriocephalus liguloides, arm, 217
Botryomycosis, 159
Bow-leg, 589
Brace, club-foot, 601
hip disease, 520
knock-knee, 584
tuberculous knee, 524
Brachial neuralgia, 252
paralysis, 10
plexus, fracture, clavicle, 29
injuries, 10
Bradford. Hemothorax, 728
Silk tendons, 677
Bramann. Arterio-venous aneurism, 244
Brodie's abscess, 486
Bronchi, foreign body in, 778
suture of, 734
wounds of, 728
Bronchial fistula, establishment of, 774
Bronchiectasis, 802
Bronchus, wound, suture, 779
Bruises, arm, 1
Bryant's triangle, 392, 479
Bubo, tropical, 573
Buchanan. Vascular suture, 18
Bullet, chest wounds, 727
in lung and pleura, 727
in pericardium, 727
wounds, arm, 17
Bunge. Amputation, 682, 683, 684
Bunion, 554
Burkhardt. Chest wounds, 726
Burns, chest, 740
upper extremity, 5
Bursæ, disease lower extremity, 547
knee, 551
lower limb, 340
popliteal space, 460
upper extremity, 19, 211
Bursal cysts, lower limb, 448
Bursitis, ankle, 553
arm, 19
lower extremity, 547
limb, 341
shoulder, 317
subacromial, operation, 326
Butlin. Amputation, sarcoma, bone, 459
Buttocks, tumors of, 439, 447

C

Cabinets, differential press, 710
Calcaneal spur, 469
Caliper, walking, 633
Callus, hands, 475
softening of, 579
tender, 579
Caminiti. Wounds, muscles, 21
Cancer, arm, 272
Marjolin's ulcer, 461
X-ray, 274
Capacity, vital, thorax, 705
Carbolic injection, joints, 691, 698
Carbon dioxide and respiration, 706
Carcinoma, arm, 512
cardia, resection, 770
groin, 445
hip, 448
lower limb, 461
metastatic, bone, 456
œsophagus, 766
thymus, 749
toe, 469
X-ray, 6
Carden's amputation, 683
Cardiac dyspnœa, wounds, chest, 724
Cargile membrane, neurorraphy, 8
Caries carnosa, arm, 174
sicca, arm, 194
Carpal bones, dislocation, 139
Carpometacarpal dislocation, 142
Carpus, fractures, 90
Carrel. Transplanted vein, aneurism, 565
Vascular suture, 18
Carrying angle arm, 40
Cartilages, costal, fracture, 720
knee, derangements, 421
loose in joints, 538
tumors, arm, 266
Casamajor. Brachial paralysis, 10
Cavities, rigid lung, 777
Celsus. Dislocation shoulder, 113
Center, respiratory, 706
Cerebral palsies, deformities, 657
paralysis, 291
Cervical nerve roots, injuries, 10
Championniere. Treatment, fracture, 362
Charcot's disease, 501
joint, 531
Charley horse, 21

Chauffeur's fracture, 87
Chest, traumata, 719
wall, tumors, 746
war surgery, 723
Children, fracture, clavicle, 29
Choice anæsthetics, operations, chest, 742
Chondrodystrophia, 486
Chondrosarcoma, arm, 288
leg, 465
Chronic bursitis, shoulder, 317
gonorrhœal arthritis, 510
osteomyelitis, 485
Cinematic amputation, 320
Circulation, collateral, arm, 16, 243
leg, reversal, 559
Circumflex nerve injuries, 12
Citrated blood, 721
Clark. Brachial paralysis, 10
Clavicle, dislocations, 97
fractures of, 27
Clavus feet, 477
Claw foot, 603
hand, 15
Cloetta. Thoracoplasty, 784
Closure, chest wounds, 744
Club foot, congenital, 593
paralytic, 629
shoe, 598
hand, 309
Coccygodynia, 579
Coccyx, fracture, 580
Codman. Arthrotomy, 326
Injuries, supra-spinatus tendon, 325
Codman's bursitis, 214
shoulder, 19
Cole. Infection from tonsils, 499
Coley. Myositis ossificans, 222
Coley's toxins, 579
sarcoma, bone, 459
Collapse therapy, tubercular lung, 779
with oil, 781
Collateral circulation, arm, 16, 243
Colles' fracture, 78
Complement fixation test, gonorrhœal, arthritis, 512
Complications, dislocation, elbow, 136
hip, 397
knee, 406
fracture, clavicle, 29
humerus, 61, 64, 68
injuries, elbow, 50
operation, semilunar cartilage, 435
Compound dislocation, shoulder, 122
subastragalus, dislocation, 410
Compression, nerves, arm, 9
root lung, 734
Concussion, thorax, 719
Condyles, humerus, fracture, 44, 47, 48
Congenital absence, radius, 309
club foot, 593
defect, tibia, fibula, 592
dislocation, hip, 647
knee, 589
patella, 587
elevation, scapula, 305
osteoma, 453
Connell. Anesthetometer, 712
Couteaud. Chest wounds, 727
Continuous suction drain, 761
chest, 737
Contracted foot, 603
Contracture, Dupuytren's, 313
spasmodic, upper extremity, 295
spastic paralysis, 657
Volkmann's, 22, 51, 227
Contusion, thorax, 719
Contusions, arm, 1
nerves, 9
Cooper, Sir Astley. Dislocation, elbow, 128
Hip, 390
Shoulder, 114
Coracoid process, fracture, 33
Corns, feet, 477
Coronoid process, fracture, 44, 49, 57
Correction, club foot, 602
Costal cartilage division, tuberculous lung, 799
fracture, 720
Cotton. Dislocation, patella, 400
shoulder, 106
subastragaloid dislocation, 414
Coup de fouet, 334
Coxalgia, 514
Creaking joints, 541
Crile. Disarticulation, shoulder, 323
Crutch paralysis, 14
Culture muscle, 632
Cuneiform osteotomy, club foot, 601
Cuneo. Neuromata, 442
Cutaneous tuberculosis, arm, 155
Cyanosis, arteriosclerosis, 559
Cyst, echinococcus, lung, 779
Cysticercus, arm, 218

Cysts, bone, 453
arm, 182
bursal, lower limb, 448
echinococcic, arm, 218
epithelial, arm, 254
sebaceous, lower limb, 439
thymus, 749
Czerny. Sarcoma, bone, 459

D

Dakin's solution, chest wounds, 726
Dangers, differential pressure, 715
gangrene arm, 16
Dangle arm, 303
Davies-Colley. Hallux rigidus, 615
Davies. Oxygen replacement, 757
Davis. Arthritis deformans, 203
Paraffin cancer, 273
Death from asphyxia, 707
Defect, tibia and fibula, 592
Deformities, arm, 305
cerebral palsies, 657
foot, 593
lower limb, 577
paralytic, lower limb, 619
upper extremity, 291
Deformity, bones, arm, 308
fracture, clavicle, 28
hip, tuberculosis, 517
Madelung's, 309
median paralysis, 14
paralytic hip, 630
silver fork, 79
tuberculosis, knee, 523
Degeneration, tissues from disuse, 623
Delorme's operation, 764
Deltoid paralysis, 13, 61, 291
Denk. Œsophagectomy 772
Derangements, cartilage, knee, 421
Dermatitis, X-ray, 6, 274
Desfosses. Treatment, burns, 5
Diabetic gangrene, 561
Diagnosis, acute osteomyelitis, 481
aneurism, arm, 242
arthritis deformans, 207
bone cysts, 454
Colles' fracture, 87
congenital dislocation, hip, 647
dislocation, ankle 412
fibula, 409
hip, 392
Diagnosis, dislocation, knee, 406
shoulder, 108
erysipelas, arm, 153
fracture, acromion process, 32
elbow, 41, 45, 47
humerus, 68
upper humerus, 36, 38
gonorrhœal arthritis, 510
hemarthrosis, 544
infectious hip, 489
injuries shoulder, 60
injury semilunar cartilage, 429
lung, infections, 773
myositis ossificans, 222
sarcoma, arm, 282
articulation, capsule, 466
bone, 456
specific bone, disease, 181
syringomyelia, 539
synovitis, knee, 493, 498
tabetic foot, 537
tuberculous ankle, 525
arthritis, arm, 198
hip, 518
Diaphragmatic hernia, 725
wounds, 722, 724
Differential pressure, 709, 733
dangers, 715
Digits, fusion of, 311
Diplegia, infants, 658
Disability, after Colles' fracture, 85
from unreduced dislocated hip, 398
Disarticulations, lower extremity, 681
upper extremity, 319
Discussion, treatment thoracic wounds, 725
Disease, Albert's, 554
ankle, 494
bones, lower limb, 479
bursæ, arm, 211
lower limb, 547
Charcot's, 531
hip, 497, 514
knee, 491, 497
lower extremity, 471
lymphatics, lower extremity, 570
muscles, arm, 215
Osgood's, 486
Perthes', 719
Raynaud's, 250
Schlatter's, 486
tendons, lower extremity, 556

Disease, upper extremity, 149
vascular, lower extremity, 557
v. Recklinghausen's, 442
Dislocation, ankle, 409
both hips, 397
carpometacarpus, 142
carpus, 139
clavicle, 97
coccyx, 580
congenital, hip, 647
elbow, 50, 125
fibula, 408
fracture, elbow, 40
habitual, shoulder, 309
hip, 389
complications, 397
old unreduced, 398
irreducible elbow, 135
knee, 405
congenital, 589
long tendon, biceps, 67
lower extremity, 387
metacarpophalangeal, 146
old hip, operation, 697
os magnum, 140, 142
patella, 587, 400
phalanges, 114, 147
pisiform, 142
radius, 45, 50
sacro-iliac, 387
scaphoid, 140
semilunar bone, 141
cartilage, knee, 421
shoulder, 63, 103
compound, 122
gangrene, 17
irreducible, 123
subastragaloid, 414
tarsal bones, 419
tarso-metatarsal, 420
tendons, 337
thumb, 142
ulna, 45
ulnar nerve, 15
unciform, 141
wrist, 136
Distortion, bone, arm, 308
Diverticula, œsophagus, 765
Division of tendons, 25
Don. Wounds, chest, 723
Dorsal, dislocation, hip, 390
Drain, suction chest, 737
Drain, transpleural, liver and subphrenic abscess, 744
valvular, chest, 737
Drainage, abscess lung, 775
after chest operations, 743
elbow, 328
empyema, 758
hip, 490
knee, 494, 698
permanent subcutaneous, chest, 762
shoulder, 324
wounds, lung, 736
Drehmann, Volkmann's paralysis, 53
Dropped wrist, 621
Drummer's paralysis, 25
Drunkard's palsy, 621
Dry gangrene, arm, 249
Duchenne. Claw hand, 15
Dumreicher. Dislocation, elbow, 129
Dunn's operation, spasmodic flat-foot, 615
Duplay. Dislocation, shoulder, 120
Dupuytren's contracture, 313
fracture, 412
Dysphagia lusoria, 751
Dyspnœa, 706
lusoria, 751

E

Echinococcic cysts, bone, 453
lung, 779
Ecchinococcus, arm, 217
lung, 774
Ecchymoses, jugular, 719
Education, cerebral palsies, infants, 659
Elbow, arthroplasty, 329
disarticulation, 321
dislocation, 50, 125
fractures, 39
injuries about, 44
joint, operations on, 328
paralysis, 302
miners', 20
sprain, 45
tennis, 24
topography, 40
treatment, injuries, 53
tuberculosis, 194, 196, 315
Electrical burns, 6
Elephantiasis, 574
Elevation scapular, congenital, 305
Elsberg. Insufflation, anesthetic, 712

Ely. Arthritis, type II, 528
Tuberculosis, hip, 515
Embolism, lower extremity, 560
pulmonary artery, 752
Emetin, chest wounds, 725
Emphysema, chest wounds, 728
Freund's operation, 800
lung, 774
mediastinal, 738
wounds, lung, 729
Empyema, exploratory operation, 762
knee, 698
pleura, 756
thoracotomy, 758
treatment, 728
Enchondroma, arm, 266
chest wall, 746
Endo-aneurismorrhaphy, 248, 565
Epinephrin, intratracheal stimulation, 721
Epiphysis, head, femur, separation, 377
humerus, separation, 36, 59, 63
lower humerus, separation, 44, 46
Epithelial cysts, arm, 254
Epithelioma, lower limb, 461
Erb's paralysis, 10, 253
Ergotin, chest wounds, 725
Erysipelas, arm, 151
lower limb, 471
Erysipeloid arm, 153
Estlander's operation, 764
Etiology, tuberculous knee, 522
Everted foot, 608
Ewing. Acapnia, 706
Tumors, thymus, 748
Examination in infantile paralysis, 627
Excision, aneurism, 564
ankle, 701
chronic ulcers, 474
elbow, 328
hip, 692
knee, 699
local, sarcoma, bone, 457
lung, 798
muscle, thigh, sarcoma, 451
neuromata, 442
segment adductors, thigh, 662
semilunar cartilage, knee, 432
shoulder, 324
fracture, 65
toe nail, 479
varicose veins, 569
wrist, 316, 329
Exercises after myotomy, 297
for flat-foot, 613
Exostoses, arm, 268
cartilaginous, arm, 266
femur, 452
foot, 469
traumatic, thigh, 450
Exploration, chest wounds, 726
Exploratory operation, empyema, 762
puncture, lung abscess, 774
thoracotomy, 730
Extensor longus pollicis, rupture of, 25
proprius hallucis, transplantation, 640
popliteal nerves, injuries, 341
External semilunar cartilage, injury, 427
Extracapsular fracture, femur, 376
Extravasated blood, autotransfusion, 721
Extremity, lower, amputation, 681
diseases, 471
dislocation, 387
diseases, lymphatic, 570
fractures, 345
operation, joints, 691
traumata, 333
tumors, 439
upper, fractures, 27
operations, 319
traumata, 1

F

Failures, treatment, congenital dislocation, hip, 653
Fascial sarcoma, arm, 276
Fat, disfiguring, 439
extrapleural implantation, 780, 791
implantation, elbow, 329
shoulder, 327
Fatty tumors, arm, 262
Felon, 227
Femoral hernia, 443
Femur, acute osteomyelitis, 483
fracture, upper end, 376
osteotomy, 585
shaft, fracture, 380
tumors, of, 452
Fibroma, knee, 460
lower limb, 439
Fibrous osteitis, arm, 182
Fibula, dislocation, 408
tumors of, 465
Filaria Bancrofti, 574

Fingers, amputations, 319
dislocation, 144, 147
fracture, 93
fusion of, 312
grafting of, 5
infections, 227
snapping, 24
supernumerary, 311
trigger, 227, 313
tuberculosis, 176, 316
wounds of, 3
Finney. Finger grafting, 5
Myositis ossificans, 22, 223
Fistula, bronchial, artificial, 774
Fistulæ, lung, 774
Fixation tendons, 678
Flail ankle, 678
joint, shoulder, 301, 325, 327
Flat-foot, 608
spasmodic, 615
Flexed knee, 630
Flexor longus hallucis, transplantation, 644, 676
Floating bodies in joints, 440
patella, 492
Flotow. Charcot's dislocation, 533
Folliculitis, 151
Foot, amputation, 681
claw, 603
club, congenital, 593
deformities, paralytic, 629
dislocation, 414, 419
exostosis, 469
flat, 608
tabetic, 537
tumors of, 466
Forceps, Lynn Thomas', 686
Forcible rectification, club-foot, 596
Forearm, absence, bones, 309
amputation, 320
fractures, 40
Foreign body, abscess, lung, 773
in lung or bronchi, 778
Forlanini. Artificial pneumothorax, 780, 781
Formalin gelatin, bone cavity, 485
glycerin, 691, 698
injection, 337
Forster's operation, spasticity, 667
Fowler's operation, empyema, 764
Fractures about knee, 585
acetabulum, 397
Fractures, Bennett's, 92
carpus, 90
chauffeur's, 87
clavicle, 27, 100
coccyx, 580
Colles', 78
coracoid, 33
costal cartilage, 720
dislocation, elbow, 40
elbow, 39
treatment, 54
femur, 376
forearm, 40
general considerations, 345
glenoid, 34
humerus, 35, 58
old, 64
lower extremity, 345
malunion, 579
mechanics of, 354
metacarpal, 92
necessity, complete reduction, 349
neck, femur, 376
os magnum, 91
patella, 384
phalanges, 93
Pott's, 370
after treatment, 578
radius, 41
ribs, 720
scaphoid, 90
scapula, 32
semilunar bone, 91
cartilage, knee, 422
shaft, femur, 380
shoulder, treatment, 61
softening of callus, 579
spontaneous, bone cysts, 454
sternum, 720
ulna, 40, 41, 50
upper extremity, 27
Frame, abduction, 662
Fraser. Tuberculous hip, 515
Frazier. Bronchiectasis, 803
Freund. Emphysema, 775
Freund's operation, emphysema, 800
tuberculosis, lung, 799
Friedreich's ataxia, 604
Friedrich's punch, 736
Friedrich. Thoracoplasty, 750, 785
Function, after nerve suture, 8
bones, lower limb, 374

Furuncles, lower limb, 471
upper extremity, 149
Fusion digits, 311
Fuster. Chest wounds, 725

G

Gaudini. Mediastinal operations, 745
Ganglia, foot, 466, 468
Ganglion, 289
periosteal, 480
Gangrene after ligation, subclavian, 16
vessels, arm, 16
lower extremity, 564
arm, 249
ischemic, 224
lower extremity, 561
lung, 775
Garré. Abscess, lung, 776
Chest operations, 743
Differential pressure, 717
Osteomyelitis, 485
Sarcoma, articular capsule, 466
Tuberculosis, arm, 200
Gas bacillus, chest wounds, 728
Gastrostomy, Jianu's, 770
Gaylord. Bone aneurism, 288
Genu valgum, 580
Girard. Abnormal subclavian artery, 752
Gland, thymus, 748
Glenoid, fractures of, 34
Glioma, arm, 265
Glück. Silk tendons, 676
Gluteal aneurism, 562
Goldthwaite. Hypertrophic arthritis, 528
Goldthwaite's operation, slipping patella, 588
Goldthwaite. Recurrent dislocation, patella, 404
Gonorrhœal arthritis, 507
arm, 189
chronic, 510
hip, 487
synovitis, ankle, 496
knee, 493, 497
tenosynovitis, 238, 557
Gouty arthritis, 545
Grafting, nerve, 303, 678
fingers, 5
Grafts, bone, 454
Green stick fracture, arm, 41, 43
clavicle, 29
wounds, diaphragmatic, 724
Griffin clutch, 15
Griffith. Injury, semilunar cartilage, 427
Gritti's amputation, 684
Groin, neoplasms of, 443
Growth, arrest of, upper extremity, 292
Gumma, arm, 154
muscles, arm, 216
Gummata, knee, 504
Gummatous periostitis, arm, 180
Gunshot wounds, arm, 3
chest, 722

H

Habitual dislocation, patella, 400, 404
shoulder, 121, 309
Hacker. Abscess, mediastinum, 745
Hacker. Charcot's hip, 534
Hallux flexus, 611
rigidus, 611, 615
valgus, 554, 555, 616
Hall. Wounds, chest, 723
Halstead's bands, aneurism, 565
Hamburger. Sporotrichosis, 158
Hammer toe, 617
Hamstrings, transplantation, 644
Hand, amputation and disarticulation, 319
ape, 15
claw, 15
club, 309
infections, 234
palsies, 303
tuberculous, 316
wounds of, 3
Handley. Lymphangioplasty, 575
Hannemüller. Sarcoma, ankle, 466
Head, ecchymosis from compression, thorax, 719
Heart, wounds, 722
Heel, bursitis, 553
dropped, 673
Heinrich. Traumatic sarcoma, 451
Heller. Vagus blocking, 765
Hemangioma, arm, 256
Hemarthros, 544
Hemorrhage, intracranial, infant, 658
wounds, lung, 722
Hemostasis, amputation, shoulder, 321
temporary hip amputation, 685
wounds, lung, 734
Hemophilic joint, 544

Hemoptysis, 725
Hemothorax, 723, 727
Henderson, Yandall. Acapnia, 706
Henschen. Blocking phrenic nerve, 739
Hernia, intercostal, diaphragm, 725
lung, 739
muscles, 21
thigh, 449
Hey. Internal derangement, knee, 421
High scapula, 305
Hildebrand. Ischemic myositis, 225
Hip, arthrodesis, 671
bursæ, 548
Charcot's, 533
congenital, dislocation, 647
disarticulation, 685
disease, 514
dislocation, 389
gonorrhœal arthritis, 509
joint, infectious, 487, 497
operations on, 691
tumors of, 448
measurements, 392
old dislocation, operation, 697
paralytic deformity, 630
syphilis, arthritis, 501
tuberculous, 514
Hirsch. Amputation, 682, 683, 684
Hochenegg. Dislocation, shoulder, 119
Hoefftcke's splints, 351, 365
Hofmeister. Dislocation, shoulder, 119
Holcombe. Aneurism, arm, 241
Hollow foot, 603
Hood, Wharton. Muscle rupture, 335
Treatment, sprains, 339
Horsley. Nerve suture, 9
Horsley's wax, bone cysts, 455
Housemaid's knee, 552
Howard. Wounds, chest, 724
Humerus, deformities of, 308
dislocation, 103
excision upper end, 325
fractures of, 35, 58
treatment, 61
shaft, fracture, 66
tuberculosis, 315
Hunter's operation, aneurism, 564
Hutchinson. Congenital syphilis, knee, 504
Hyde and Montgomery. Treatment, callosities, 476
Hydroadenitis, 151
Hydrops articuli, 498
traumatic, 691, 698
knee, syphilis, 503
Hygroma, subdeltoid, 212
Hyperemia, arthritis, arm, 317
Bier's, 333
ankle, 527
boils, 150
hand, 238
Hypernephritis, metastatic bone, 456
Hyperpnœa, 706

I

Immobilization, hip, 520
Implantation, fat, shoulder, 327
vein, aneurism, 565
Incision, exploratory, thoracotomy, 730
hip, Langenbeck's, 692, 694
Torek's, 733
Indications, amputation, gangrene, 561
method, operation, sarcoma, bone, 457 *et seq.*
operation, paralysis, arm, 305
tuberculosis, lung, 780
treatment, flat-foot, 614
old dislocation, hip, 399
tuberculosis, hip, 519
tarsus, 527
Infantile cerebral palsies, deformities, 657
palsy, deformities, 619
Infections, ankle, 494
arthritis deformans, 529
bone, 479
focal, arthritis deformans, 207
hip-joint, 497
knee, 491, 497
lower limb, 471
lung, 772
lymphatics, lower limb, 571
mediastinum, 745
pleura, 756
rheumatism, 499
tendons, lower extremities, 556
thoracic wall, 745
wounds, 725
veins, 567
Infective arthritis, lower limb, 487
diseases, arm, 150
tenosynovitis, 227

Ingrowing toe nail, 478
Injections, alcohol, spastic paralysis, 295
hip, 691
into elbow, 328
into shoulder joint, 324
knee, 697
J. B. Murphy, 337
Injuries, arm, 1
muscles, 20
blood-vessels, fracture, clavicle, 29
to blood-vessels, fracture, humerus, 61
brachial plexus, 10
bursæ, lower limb, 340
lower extremity, 333
muscles, lower limb, 333
nerves, Colles fracture, 86
fracture, clavicle, 29
lower limb, 341
upper extremity, 7
shoulder, diagnosis, 60
supraspinatus tendon, 325
tendons, lower limb, 335
vessels, arm, 16
Injury, semilunar cartilages, knee, 421
nature of, 425
Inoperative, sarcoma, bone, 459
Insufflation, intratracheal, 712
Intercostal diaphragm, hernia, 725
incision, exploratory, 730
Interilio-abdominal, amputation, 688
Intermittent synovitis, 498
Internal derangements, knee, 421
Intracapsular fracture, femur, 376
Intracoracoid dislocation, 111
Intrapericardial ligation, pulmonary arteries, 797
Intrapharyngeal anæsthesia, 711, 733
Interscapulo-thoracic, amputation, 323
Intrathoracic pressure, 705
Intratracheal insufflation, 712
stimulation, epinephrin, 721
Intravenous anæsthesia, 26
Iodoform emulsion, shoulder, 325
glycerine, 691, 698
Irreducible dislocation, elbow, 135
shoulder, 123
Irrigation, chest wounds, 726
Ischæmic myositis, 22, 51, 224
paralysis, 291, 298
Ischiorectal abscess, 471
Ivory plugs, bone, 454

J

Jaboulay's amputation, 688
Jackson. Arthritis deformans, 203
Janeway. Acapnia, 706
Janeway and Ewing. Carbon dioxide and shock, 715
Jianu. Gastrostomy, 770
Joint, ankle, infections, 494
arm, diseases, 188
capsule, shoulder, injury, 11
Charcot's, 531
creaking, 541
hemarthros, 544
hip, infections, 487, 497
knee, 491, 497
lipomata, 543
loose bodies in, 540
lower extremities, operation, 691
limb, infections, 487
midtarsal, arthrodesis, 673
occupational changes, 345
shoulder, operations on, 324
paralysis, 301
syringomyelia, 538
Jones, R. Arthrodesis, elbow, 303
Congenital dislocation, hip, 649
Dislocation, shoulder, 107
Injuries, semilunar cartilage, 427
Myositis ossificans, 223
Operation, malum coxæ senilis, 696
Position, elbow, 54
Spastic paralysis, 657, 661
Volkmann's contracture, 22
paralysis, 53
Jössel, dislocation, shoulder, 121

K

Kanavel. Infections, hand, 233, *et seq.*
Kaposi. Bone cysts, 454
Keen. Diagnosis, injuries, shoulder, 60
Kenyon. Hemothorax, 728
Keratoma, 475
Key. Arteriotomy, 561
Klar. Dislocation, clavicle, 102
Klumpke's palsy, 254
Knee, amputation, 683
arthritis deformans, 530
arthrodesis, 668, 671
bursæ, 551
capsule, plication, 588

Knee, Charcot's disease, 534
congenital dislocation, 589
disarticulation, 683
diseases, 491, 497
dislocation, 405
gonorrhœal arthritis, 510
housemaid's, 552
internal derangement, 421
-joint, operations on, 697
tumors, 460
knock, 580
paralytic deformity, 630
splint, Thomas', 586
syphilis, 502
tuberculosis, 522
Knock knee, 580
and dislocation, patella, 400, 587
Kocher. Disarticulation, thumb, 319
Dislocation, hip, 394
shoulder, 116, 124
Excision, ankle, 527
König. Arthrectomy, ankle, 701
hip, 863
Dislocation, shoulder, 118
Emphysema, wounds, lung, 729
Fracture, ribs, 720
König, Fritz. Milton's operation, 751
Tuberculous arthritis, arm, 192
knee, 522
Körte. Bone cysts, 454
Krogius. Operation, recurrent dislocation, patella, 404
Kronlein. Dislocation, knee, 405
Kuttner. Sarcoma, ankle, 466

L

Laceration, lung, 719
Lambert A. Œsophagus, diverticulum, 766
Lambotte. Fracture, scaphoid, 91
Treatment, fracture, 361
Lambotte's fixateur, 63
Laminectomy, spastic paralysis, upper extremity, 295
La Mothe. Dislocation, shoulder, 113
Landois. Chest wounds, 726
Lane. Arthritis deformans, 529
Lane, L. C. Traumatic sarcoma, 451
Lane's law, growth, bone, 346
Lange. Perthes' disease, 719
Silk tendons, 676
Langenbeck. Arthrotomy hip, 692
Lannelongue. Arthritis arm, 168
Laparotomy, transpleural, 738
Law. Growth of bone, 346
Wolff's, 584
Lawrow. Wounds, thorax, 722
Lead poisoning, wrist drop, 621
Lecene. Sarcoma, thigh, 451
Le Conte. Interscapulo-thoracic amputation, 323
Leg, amputation, 682
bones, tumors of, 465
bow, 589
milk, 568
ulcers, 472
Lengthening muscles and tendons, 298
tendo Achillis, 663
Lenormant. Tuffier's operation, lung, 794
Le Play. Shock operation, chest, 743
Lexer. Bone cysts, 155, 454
Osteomyelitis, 481
arm, 168
Transplant, vein, 565
Ligaments, ankle plication, 676
artificial, 677
Ligation, aneurism, lower extremity, 564
common femoral, 564
external iliac, 564
preliminary subclavian artery, 321
pulmonary artery, 780, 795
subclavian, gangrene, 16
Lilienthal. Bronchiectasis, 802
Exploratory operation, empyema, 762
Injection, phrenic nerve, 739
Lilienthal's rib spreader, 732
Limp, arteriosclerosis, 559
Line, Nelaton's, 392, 479
Lipectomy, thighs, 439
Lipoma, arm, 262
chest wall, 746
Lipomata, joints, 543
knee, 460
lower limb, 439
Lisfranc's amputation, 681
Local anæsthesia, arm, 26
chest operation, 740
disarticulation, shoulder, 323
Locking joints, 541
of knee, 424
Loos. Rupture, muscles, 22
Loose bodies in joints, 540
Lorenz. Congenital dislocation, hip, 648, 649

Lower extremity, amputation, 681
deformities, 577
dislocations, 387, 471
diseases, lymph, 570
embolism and thrombosis, 560
fractures, 345
gangrene, 561, 562
traumata, 333
tumors, 439
Lund. Valvular drain, 761
Lung abscess, 772, 775
emphysema, 774
fistulæ, 774
foreign body in, 778
gangrene, 775
gunshot wounds, 772 *et seq.*
hemorrhages, 722
hernia, 739
infections, 772
laceration, 719 720 *et seq.*
œdema of, 772
projectiles in, 727
resection, 798
root, compression of, 734
rupture, 729
tuberculosis, collapse therapy, 779
Lupus, arm, 155
Luxatio erecta, 112
Lymphadenitis, 572
Lymphangiectasis lower limb, 447
Lymphangioma groin, 444
Lymphangioplasty, 575
Lymphangitis lower extremity, 571
Lymphatics, disease, lower extremity, 570
Lymphosarcoma groin, 445
thymus, 749

M

MacEwen. Compression, aorta, 686
Pneumectomy, 798
MacEwen's osteotomy, 404
Mackenzie, K. A. J. Injections, oil, in pleura, 781
Madelung's deformity, 309
Magnesium, wire sutures, lung, 734
Magnus. Spastic paralysis, 661
Magoula. Wounds, diaphragmatic, 724
Mahler's symptoms, pulmonary embolism, 752
Maisoustet. Treatment, chest wounds, 725
Majewski. Establishment, bronchial fistula, 774
Makins. Injuries, sciatic nerve, 343
Malgaigne. Dislocation, shoulder, 118
hip, 389
Malignant chondroma, 270
nævi, arm, 261
tumors, arm, 272
chest wall, 746
Malposition, fracture femur, 379
Malum coxæ senilis, 696
Malunion fracture, shoulder, 64
Malunited fracture, 579
elbow, 58
Manheimer. Sarcoma, bone, 459
Mantelli. Sarcoma, femoral vessels, 451
Mantoux. Shock, operations, chest, 743
Marjolin's ulcer, 461
Marquis. Wounds, lung, 727
Marsh, Howard. Derangements, knee, 421
Knee, splint, 431
Martin, A. M. Derangements, knee, 421
Masks, differential pressure, 711
Massage, 631
treatment, fracture, 362
Matas. Aneurism, arm 241, 246, 248
Aneurismorrhaphy, 565
Operation, popliteal aneurism, 460
Matsuoka. Œdema, lungs, 772
Mayo. Hallux valgus, 617
Mayo, C. H. Varicose veins, 569
Measurement, lower extremity, 479
Mechanics of fractures, 354
Median nerve, injuries, 14
Mediastinal emphysema, 738
tumors, 749
Mediastinitis, 745
wounds, chest, 724 *et seq.*
Mediastinum, operations on, 745
in pneumothorax, 708
wounds, bronchi, 729
Melanotic sarcoma, 441
Melanocarcinoma, arm, 261
Messner. Fracture, costal cartilage, 720
Metacarpo-carpal disarticulation, 319
Metacarpo-phalanx, disarticulation, 319
Metacarpals, fracture, 92
phalanx, dislocation, 146
tuberculous, 316
Metastatic tumors, bone, 456
Metatarsal amputation, 681
Metatarsalgia, 609, 611, 618

Myer, Willy. Cardiospasm, 765
Closure, bronchus, 799
Differential pressure, 717
cabinet, 710
Jianu gastrostomy, 770
Ligature, pulmonary artery, 797
Mice, joint, 540
Middledorpf. Dislocation, shoulder, 106
Milk leg, 568
Milton's operation, 751
Miner's elbow, 20
Mintz. Bullets in pericardium, 727
Molecular adhesions, pleuræ, 709
Moles, arm, 255
pigment, 441
Molluscum fibrosum, 264
Momburg. Compression aorta, 686
Moore's bandage, fracture, clavicle, 31
Morbus coxæ, 514
senilis, 528
Morell-Lavell. Hernia, lung, 740
Morris. Dislocation, hip, 389, 394
Morison, R. Arthrectomy, hip, 694
Derangements, knee, 422
Excision, elbow, 329
Morphin, thoracic wounds, 725
Mortality, interscapulo-thoracic, amputation, 289
Morton's metatarsalgia, 609, 611, 618
Mosetig's bone wax, 485
plug, 699
Moskowicz. Gangrene, 562
Mosso. Acapnia, 706
Moynihan. Chest wounds, 726
Müller. Recurrence sarcoma, bone, 458
Tumor chest wall, 746
Murphy, J. B. Arthroplasty, hip, 694
knee, 700
Gonorrhœal arthritis, 509
Injection, knee, 337
Mediastinum, 746
Neurorrhaphy, 8
Treatment, gonorrhœal arthritis, 513
Murphy's injections, joints, 691, 698
Muscle, arm, diseases, 215
injuries, 20
culture, 632
examination of, in paralysis, 627
hernia of, 21
lengthening, 298
lower limb, injuries, 333
overstretched, 629
Muscle, rupture, 21
stretching of, 621
thigh, tumors, 449
training, after transplantation, 639
transference, 298
shoulder, 301
upper extremity, spasticity, 295
Muscular spasm, tuberculosis, hip, 517
Musculo-spiral nerve, fracture, elbow, 48
humerus, 61, 68
palsy, 621
paralysis, 13
Mycotic aneurism, arm, 247
Myositis, arm, 215
ischæmic, 22, 51, 224
ossificans, 210, 219
traumatic, 22
thigh, 450
Myotenotomy spasticity, 295, 297
Myotomy, adductors, thigh, 662
spasticity, upper extremity, 295, 297
Myxoma thigh, 449
Myxosarcoma, thigh, 449
thymus, 749

N

Nævi, pigmented, arm, 260
Nail, extension, fractures, 363
toe, ingrowing, 478
Necrosis bone, acute osteomyelitis, 481
Negative pressure cabinet, 709
Nelaton's line, 392, 479
Neoplasms, lower extremity, 439
of groin, 443
See also Tumors.
Nerve, anatomosis, spastic paralysis, 294
block, amputation, 323
bundles in nerve trunks, 679
circumflex, injuries, 12
grafting, 303, 678
injuries to, fracture, clavicle, 29
lesions, Colles', fracture, 86
lower limb, injuries, 341
median, injuries, 14
musculo-spiral fracture, elbow, 48
humerus, 61, 68
injuries, 13
phrenic blocking, 739
suture, 7
transference, 303
transplantation, 8

Nerve, tumors of, 441
arm, 265
ulnar, injuries, 15
upper extremity, traumata, 7
Neuber. Sequestrotomy, 484
Neugebauer. Transpleural operation, diaphragmatic hernia, 725
Neuralgia, brachial, 252
Neuritis, brachial, plexus, 11
traumatic, arm, 16
Neuroma, amputation, 442
plexiform arm, 265
stump, 682
Neuromata, lower limb, 442
Neuroplasty, 8
Neuropathic arthritis, arm, 208
Neurorraphy, 7
Nichols. Arthritis deformans, 203
Degenerative arthritis, 528
Tuberculosis, knee, 522
Non-union, fracture, clavicle, 30
Nurses' feet, 611
Nystrom. Empyema 757

O

Obliterative aneurismorrhaphy, 248
Obstetrical paralysis, 291, 295
Obturator, dislocation, hip, 390
Occupational changes, bones, 345
Œdema lungs, 772
Œhlecker. Phrenicotomy, 795
Œsophagus, carcinoma, 766
diverticula, 765
Œsophago-gastrostomy, 766
resection, 767
transpleural operation, 765
Oil, injection in pleura, 781
Old dislocation, hip, 398
Olecranon bursitis, 20, 214
fracture, 44, 48, 56
Ollier. Arthrectomy, shoulder, 324
Excision, wrist, 316, 330
Omi. Transplantation, vein, 565
Operation, acute osteomyelitis, 482
aneurism, 564
arm, 247
anterior mediastinum, 749
bone cysts, 454
bow-leg, 590
brachial paralysis, 11
chest, 740
Operation, claw-foot, 606
club hand, 309
coccygodynia, 580
congenital, club-foot, 595
dislocation, hip, 648
diplegia infants, 665
dislocation, elbow, 135
tendon, 338
echinococcus cyst, lung, 779
elephantiasis, 574
embolism, pulmonary artery, 752
exploratory empyema, 762
fixation, tendons, 678
for old empyema, 764
fracture, leg, 365
Freund's emphysema, 775, 800
hallux valgus, 617
hammer-toe, 617
infections, hand, 234
injury, semilunar cartilages, 432
joints, lower extremity, 691
Jones. Malum coxæ senilis, 696
knee-joint, 697
knock-knee, 585
local, sarcoma bone, 457
loose bodies, joints, 543
Lorenz, 649
lung, abscess, 775
Matas. Aneurism, 565
Arm, 248
mediastinum, 745
Milton's, 751
œsophagus, diverticula, 765
old dislocation, hip, 697
on lungs, 775
on pleura, 756
on shoulder joint, 324
on upper extremity, 319
paralysis, arm, 305
paralytic deformities, 635
talipes calcaneo cavus, 672
recurrent, dislocation, patella, 404
rupture, lung, 730
subastragaloid, dislocation, 417
spastic paraplegia, 662
spasticity, upper extremity, 297
subacromata, bursitis, 326
to dorsally flex foot, 633
transpleural diaphragmatic hernia, 725
on œsophagus, 765
Trendelenburg's, 752
tuberculosis, ankle, 526

Operation, tuberculosis, arthritis, arm 201
hip, 521
knee, 525
lungs, 780
varicose veins, 569
Volkmann's paralysis, 299
webbed fingers, 313
wounds, chest, 724
Operative treatment, dislocation, clavicle, 101
shoulder, 124
fractures, 358
clavicle, 31
humerus, 61
Orloff. Typhoid arthritis, 505
Ormsby. Blastomycosis, 156
Orthopedics, lower limb, 577
upper extremity, 291
Os calcis spur, 469
Osgood's disease, 486
Os magnum dislocation, 140, 142
fracture, 91
Ossification points, elbow, 46
Osteal felon, 232
Osteitis, arm, tuberculous, 172
fibrous, 182
Osteoarthritis, 345
lower limb, 528
Osteoarthropathies, 531
Osteochondritis, syphilis, 178
Osteoclasis, bow-leg, 590
Osteoid sarcoma, leg, 465
Osteoma, arm, 268
femur, 352
Osteomalacia, 486
Osteomyelitis, acute lower limb, 480
arm, 160
chronic, 485
finger, 232
near ankle, 494
Osteoplastic amputation, 682, 684
operation, chest, 743
Osteopsathyrosis, 486
Osteotomy, bow-leg, 597
Osteotomy, club-foot, 601
Colles' fracture, 89
femur, 585
fracture, elbow, 58
tibia, 587
Outdoor treatment, septic chest, 726
Ovarian cyst in groin, 444
Over-correction club-foot, 602
Oxygen, replacement during aspiration, 757

P

Pacci. Congenital dislocation, hip, 649
Paget's disease, bone, 456, 486
Pain after thoracotomy, 744
neuritis arm, 16
Paine. Infections from tonsils, 499
Pains in foot, 610
Palm, callosities, 475
Palmar abscess, 237
Palsies, birth, 12
wrist and hand, 303
Palsy, ischæmic, 291, 298
Klumpke's, 254
Papilloma, arm, 255
sole, 469
Paracentesis, pleura, 757
Paraffin dermatitis, 272
Paralysis, anesthesia, 12
brachial, 10
deltoid, 13, 291, 61
Drummer's, 25
Erbs', 10
infantile, nerve graft, 678
ischemic, 224
lower limb, 619
median nerve, 14
musculo-spiral, 13
peronæus profundus nerve, 679
serratus, 307
shoulder, 301
spastic, 657
upper extremity, 293
Tooth's, 604
traumatic upper extremity, 7
ulnar nerve, 15
upper extremity, 291
Volkmann's, 51, 291, 298
Paralytic deformity, hip, 630
knee, 630
talipes calcaneo varus, 672
Paraplegia, infants, 658
Parasitic bone cysts, 453
diseases, muscles, arm, 217
elephantiasis, 574
Paraverticular anæsthesia, 727
Parham. Tumors, chest wall, 746
Paronychia, 236

Patella, dislocation, 400, 587
floating, 492
fracture, 384
slipping, 587
tumors of, 459
Patellar bursitis, 341
Patton. Syphilis, knee, 503
Pauchet. Anæsthesia, lung wounds, 727
Payr. Ganglia, 468
Percostal, in amputation, 682, 683, 684
sutures, 736
Percy's tube, 721
Perforating ulcers, 343
Pericardium, bullet in, 727
Pericarditis, wounds, chest, 724
Periostitis, low limb, 480
Periphlebitis, 567
Peronei muscles, spasmodic flat-foot, 615
tendons, transplant, 641
Peroneus longus, 676
dislocation, 337
flail ankle, 678
Peronæus profundus nerve, paralysis, 679
Perthes' disease, 719
Pes cavus, 603
Phagedenic ulcer, 473
Phalanges. Amputations and disarticulations, 319
chondromata, 268
dislocation, 144, 147
fractures, 93
tuberculous, 316
Phelp's operation, club-foot, 602
Phlebitis, arm, 251
lower extremity, 567
Phlegmasia, alba dolens, 568
Phlegmon, lower extremity, 472
Phrenic nerve, block, 739
Phrenicotomy, 780, 794
Phthisis, pulmonary treatment, 779
Picqué. Chest wounds, 725
Picric acid in burns, 5
Pigmented nævi, arm, 260
nævus, 447
Pins, Wyeth's, 685
Pisiform, dislocation, 142
Plantar abscess, 472
Plantaris, rupture, 334
Plaster-of-Paris, hip, 521
Plastic closure, chest, 747
Plate, steel, for fractures, 370
Plating fracture, clavicle, 31
scapula, 34
Playfair suction drain, 761
Pleura, bullet in, 727
injuries, fracture, clavicle, 30
operations on, 756
wounds of, 722
Pleuræ, molecular adhesion, 709
Pleural injections, 756
Pleurotomy, chest wounds, 726
Plexiform neuroma, arm, 265
Plication caps, knee, 588
Pneumectomy, 798
Pneumococcic arthritis, 506
arthritis, hip, 487
Pneumonia, wounds, chest, 724 *et seq.*
Pneumolysis, 764
Pneumothorax, 707, 719, 722, 725, 726 *et seq.*
artificial, 780, 781
Polioencephalitis, 658
Poliomyelitis, 291
anterior acuta, 619
Polyserositis pleura, etc., 756
Poncet. Botryomycosis, 159
Popliteal abscess, 471
aneurism, 460, 562
nerve, externus, injuries, 341
space, tumors of, 460
Porter. X-ray carcinoma, 6
Position, Jones' elbow, 54
Positive pressure apparatus, 710
Post-pneumonic abscess, lung, 772
Posture, chest operation, 740
infantile paralysis, 626
tuberculosis, hip, 517
Pott's disease, spastic paralysis, 294
fracture, 370, 409, 412
traumatic flat-foot, 576
Poynton. Injection from tonsils, 499
Prepatellar bursitis, 341, 551
Pressure, differential, 709
intrathoracic, 705
Prevention, deformities, 577
Principles, deformities, lower limb, 577
exploratory thoracotomy, 730
operation, paralyses, arm, 305
tendon transplantation, 637
treatment, cerebral palsy, deformities, 658
club-foot, 602
foot paralysis, 629

Pringle. Fracture, dislocation, elbow, 40
transplantation, vein, 565
Prognosis Colles' fracture, 89
dislocation, knee, 407
erysipelas, arm, 152
fracture, clavicle, 30
elbow, 57
forearm, 42
scapula, 34
shoulder, 64.
gonorrhœal, arthritis, 513
infections, hip, 489
musculo-spiral paralysis, 75
nerve suture, 8
sarcoma, arm, 278
synovitis, knee, 493
syringomyelia, 539
tabetic arthropathy, 537
tuberculosis, ankle, 525
hip, 519
knee, 524
Projectiles in lungs, 727
Prolapse, lung, 740
Prophylactic treatment, paralytic deformities, 620
Prout. Brachial paralysis, 10
Prunus. Dislocation, shoulder, 113
Pulmonary. *See* Lung.
abscess, 772
artery, embolism, 752
ligation, 780, 795
emphysema, 774
œdema, 772
vessels, hemorrhage, 722
Pulsating tumors, bone, 458
Puncture, exploratory, lung abscess, 774
pneumothorax, 726

Q

Quadriceps tendon, rupture, 336

R

Rachitic curves, humerus, 308
Radical treatment, hip tuberculosis, 521
Radiculectomy, 667
Radium burns, 6
Radius, Colles' fracture, 78
congenital, absence, 309
dislocation, 125, 132, 133
fracture, 41
head and neck, fracture, 44, 50
Ransohoff. Old empyema, 764
Raynaud's disease, 250
Recamier bandage, fracture, clavicle, 31
Recovery, nerve muscle, cycle, 624
Recurrence, sarcomata bone, 458, 459
Recurrent dislocation, patella, 400, 404
Recurring dislocation, shoulder, 121
Reduction dislocation, hip, 394
knee, 407
patella, 402
old dislocation hip, 697
subastragaloid, dislocation, 417
Rehn. Epithelioma, lower limb, 463
Milton's operation, 751
Rehn, Jr. Œsophagectomy, 772
Splitting sternum, 749
Relapse after operation, club-foot, 603
Remarks on lung infections, 773
Report, British Fracture Committee, 359
Resection, bone cysts, 454
carcinoma cardia, 770
chest wall, 746
elbow, 328
knee, 525
œsophagus, 767
peronei tendons, 615
ribs, 759
shoulder, 324
vessels, 18
Respiration, physiology, 703
Respiratory center, 706
Results, neurorrhaphy, 8
suture musculo-spiral, 14
treatment, fractures, 359
Reversal circulation, leg, 559
Rheumatoid arthritis, 345
hip, 487
synovitis, 499
Ribs, fracture, 720
resection, 759
section of, 733
spreader, 732
trephining, 761
Rice bodies, tendon sheaths, 556
tuberculous, arthritis, 193
Rich. Silk tendons, 677
Rickets, arm, 308
dislocation, shoulder, 113
treatment, 577
Riders' bone, 450
Robinson. Bronchiectasis, 803
Drain through rib, 762

Robinson. Empyema, 764
Excision, lung, 801
Robinson's machine, artificial pneumothorax, 782
Roith. Vagus blocking, 765
Rose and Carless. Dislocation, knee, 405
Rosenbach. Erysipelas arm, 153
Rosenau. Infections, rheumatism, 499
Rosenow. Arthritis deformans, 203
Rosenthal. Sarcoma, tendon sheath, 467
Roser. Dislocation, elbow, 128
Rotter. Charcot's knee, 534
Roux. Dislocation, patella, 404
Rovsing. Arthritis, knee, 698
Dry arthritis, 691, 698
Rudolf. Wounds, lung, 724
Rupture, lung, 729
muscles, 21, 334
supraspinatus tendon, 326
tendons, 25
lower limb, 336
Rydigier. Sarcoma, articulation capsule, 466
Ryerson. Silk tendons, 677

S

Sabanejeff's amputation, 654
Sabre-cut, arthrotomy, shoulder, 326
Sacro-iliac, dislocation, 387
Salicylic acid treatment, callosities, 476
Sampson. Reduction, fractures, 349
Saphenous opening, abscess, 471
Sarcoma, amputation, hip, 688
ankle, 466
arm, 275
articulation capsule, 466
chest wall, 746
femur, 456
groin, 444
humerus excision, 325
knee, 460
leg, bones, 465
patella, 459
skin, lower limbs, 441
tendon sheaths, 467
thigh, 451
thymus, 749
Sauerbruch. Ligation, pulmonary artery, 780, 795
Plastic closure, chest, 747
Splitting sternum, 749
Sauerbruch. Thoracoplasty, 780, 784
Transpleural laparotomy, 738
Saw, Adam's, 586
Sayre's straps, fracture, calvicle, 31
Scalds, upper extremity, 5
Scaphoid, dislocation, 140
fracture, 90
Scapula alata, 307
deformities of, 308
fracture, 32
high, 305
Schede. Sequestrotomy, 484
Varicose veins, 570
Schedes's operation, 764
Schlatter's disease, 486
Schley. Drain empyema, 728
Schmerz. Trephining rib, 761
Schmidt. Oxygen replacement empyema, 728
Vaccines, gonorrhœal arthritis, 513
Sciatic dislocation, hip, 390
nerve, injuries, 343
Sclerotizing osteomyelitis, 485
Sculler's sprain, 24
Sebaceous cysts, lower limbs, 439
Section of ribs, 733
Seelig. Wounds, chest, 723
Semilunar, bone dislocation, 141
fracture, 91
cartilage, knee derangement, 421
Senile warts, 256
Senn. Decalcified bone chips, 485
Sensation after nerve suture, 8
Separation epiphysis, head femur, 377
lower epiphysis, humerus, 44, 46
upper epiphysis, humerus, 36, 59, 63
Septic wounds, chest, 726
Sequestrotomy, lower limb, 483
Serratus paralysis, 307
Sheaths, tendon sarcoma, 467
Sherren. Injury external popliteal nerve, 342
Shock, 715
chest operations, 742, 743
Shoe, after Potts' fracture, 578
club-foot, 598
errors in, 609
for flat-foot, 613
metatarsalgia, 618
Short, A. R. Acapnia, 706
Shoulder arthritis, 316
bursitis, 19, 317

Shoulder, disarticulation, 321
dislocation, 103
fractures, 35, 58
treatment, 61
habitual dislocation, 309
injuries, diagnosis, 60
-joint, operations on, 324
paralytic, 301
recurrent dislocation, 121
sabre-cut arthrotomy, 326
slipping, 309
tuberculosis, 315
Silk as tendon extensions, 676
Silver fork deformity, 79
Simon. Dislocation shoulder, 118
Singultus, injection, phrenic nerve, 739
Slack knee, 583
Slipping patella, 587
Smith, Nathan. Dislocation, hip, 394
Snapping finger, 24, 227, 313
Sodium citrate, blood, 721
Sole callosities, 475
wart of, 469
Solution, Dakin's, chest wounds, 726
Wright's, chest wounds, 727
Soutter. Silk tendons, 677
Space, dead, thorax, 705
Spannung's pneumothorax, 709, 729
Spasm, tuberculosis, hip, 517
Spasmodic flat-foot, 615
Spastic paralysis, infants, 657
upper extremity, 293
Spasticity, Forster's operation, 667
upper extremity, 295
wrist, 296
Spence. Disarticulation, shoulder, 322
Spina ventosa, 176, 316
Spinal paralysis, infants, deformities, 619
Spine, scapula, fracture, 34
Spitzy. Nerve grafting, 679
Splenectomy, transpleural, 738
Splint for injured semilunar cartilages, 431
Splints, hip, 520
Hoefftcke, 351, 365
knee, 524, 630
Thomas, 586
leg, 591
Spontaneous fracture, bone cysts, 454
Sporotrichosis, arm, 158
Sprain, elbow, 45
Sprains, lower limb, 338
upper extremity, 24
Spreader, rib, 732
Sprengel's deformity, 305
Spurs, calcaneal, 486
os calcis, 469
Sputum, lung infections, 773
Stabs, thorax, 722
Statistics, acute osteomyelitis, 480
musculo-spiral paralysis, 75
sarcoma, bone, 456
tuberculosis, knee, 522
Steinmann's nails, fractures, 363
Sternum, fracture, 720
Stiles. Tuberculosis osteitis, arm, 175
Stimson. Dislocation, clavicle, 102
hip, 394, 396
knee, 406
shoulder, 120
unciform, 141
Subglenoid dislocation, 112
Stimulants, chest wounds, 725
Stöffel. Nerve bundles, 679
Strains, tendons, 23
Sternum, splitting of, 749
Stretching of nerves, upper extremity, 9
Stuertz. Phrenicotomy, 780, 795
Stump, amputation, 682
neuroma, 682
Subacromial bursitis, 19
operation, 326
Subastragaloid dislocation, 414
Subclavian artery, abnormal, 751
ligation, gangrene, 16
preliminary ligation, 321
dislocation, 111
vessels, fracture, clavicle, 29
Subcutaneous rupture, muscle, 334
Subcoracoid dislocation, 108
Subdeltoid bursitis, 19, 212
Subglenoid dislocation, 112
Subluxation, sacro-iliac, 387
tuberculosis, knee, 523
Subungual angeiosarcoma, 469
spur, 469
Suction drain, chest, 737
empyema, 761
Supernumerary fingers, 311
Suppuration, hip, 481
Supracondylar fracture, elbow, 44, 46
Supraspinatus tendon, injuries, 325
Surgery, thoracic, 703
Surgical neck, humerus, fracture, 35, 58
Suture, arterial, 18

Suture, blood-vessels, 566
chest wounds, 744
nerves, arm, 7
lower limb, 343
of muscle, 335
percostal and pericostal, 736
of tendons, 25
lower limb, 336
thorax, 736
wounds, bronchi, 734
bronchus, 779
lung, 734
Swift, M. B. Finger injuries, 4
Syme's amputation, 681
Symptoms, acute osteomyelitis, 481
aneurism, lower extremity, 562
arteriosclerosis, lower extremity, 559
arthritis, ankle, 495
deformans, 205, 529
chest wounds, 725
derangements, cartilage, knee, 424
dislocation, clavicle, 97, 98, 99, 100, 101, 102
elbow, 126, 130
patella, 402
division, nerves, arm, 7
embolism and thrombosis, 560
erysipelas, arm, 152
floating bodies, joints, 541
gangrene, lower extremity, 561
gonorrhœal arthritis, 508
hemarthros, 544
infections, hip, 488
injuries, external popliteal nerve, 341
median nerve, 14
lymphangitis, 571
musculo-spiral paralysis, 13
posterior dislocation, hip, 390
pulmonary embolism, 752
sacro-iliac dislocation, 387
subastragaloid dislocation, 415
synovitis, knee, 492, 498
syphilis, hip, 502
tuberculosis, ankle, 525
arthritis, arm, 195
hip, 515
knee, 523
Volkmann's paralysis, 51
Synostosis, bones, forearm, 311
Synovitis, acute, 487
rheumatism, 499
chronic, ankle, 496
Synovitis, hip, 497
knee, 491, 497
tuberculosis, 522
Syphilitic lymphadenitis, 572
Syphilis, ankle, 504
arm, 154
arthritis, 501
arm, 201
hip, 502
knee, 460, 502
myositis, arm, 216
osteitis, 178
osteochondritis, 178
tendons and sheaths, 557
thoracic wall, 745
v. sarcoma bone, 456
ulcers, leg, 475
Syringomyelia, 208
joints, 538
Tabetic arthropathies, 531
foot, 537
Tailor's bursa, 554
Talipes calcaneo cavus paralysis, 672
calcaneus, 644
equinus, congenital, 593
paralytic, 629
Tangential shots, chest, 726
Tar cancer, 273
Tarsal bones, dislocation, 419
Tarso-metatarsal dislocation, 420
Tarsus, sarcoma, 467
tuberculosis, 527
Taylor. Brachial paralysis, 10
Telangiectasis, arm, 256
Tenalgia, 227
Tender callus, 579
Tendo Achillis, elongation, 663
rupture, 337
shortening, 676
spur, 469
strengthening of, 676
tenotomy, 597
transplant, 643
Tendons, as artificial ligaments, 677
arm, 23
biceps, dislocation, 61
dislocation, 337
fixation, 678
flail joints, 678
lengthening, 298
lower extremity, dislocation, 556
limb, injuries, 335

Tendons, over-stretched, 629
peronei resection, 615
rupture, lower limb, 336
rupture of, 25
sheaths, sarcoma, 467
solution of continuity, 25
supraspinatus injuries, 325
suture, 25
lower limb, 336
transference, 298
transplant, 624, 637
Tendovaginitis, 227
Tennis elbow, 24
leg, 335
Tenorrhaphy, 25
lower limb, 336
Tenosynovitis, 227
crepitans, 23
lower extremity, 556
Tenotomy, congenital club-foot, 596
talipes calcaneo cavus, 673
Tension pneumothorax, 709, 729
Test recovery, club-foot, 594
Thiersch's valvular drain, 761
Thigh, amputation, 684
tumors of, 449
Thomas' abduction frame, 662
Thomas. Brachial paralysis, 11
Thomas' frame, infantile paralysis, 625
prevention, deformities, 577
hip brace, 520
knee brace, 524
splint, 586
flexed knee, 630
shoe, club-foot, 601
walker caliper, 633
Thomas, Lynn. Forceps, 686
Thomas, Turner. Dislocation, shoulder, 122
Thoracic operations, 740
surgery, 703
wall infections, 745
wounds, treatment, 725
Thoracoplasty, 780
Thoracotomy, chest wounds, 725
empyema, 758
exploratory, 730
pain after, 744
Thorax, the, 703
compression causing ecchymosis, 719
suture of, 736
war surgery, 723
Thorax wounds, 720
Thrombosis, brachial artery, 17
lower extremity, 560
Thumb, disarticulation, 319
dislocation, 142
Thymus, tumors of, 748
Thyroid dislocation, hip, 390
Tibia, acute osteomyelitis, 483
exostoses, 453
fibula, congenital defect, 592
osteotomy, 587
tumors of, 465
Tibial tuberculosis, disease, 456
Tibialis anticus, flail ankle, 678
transplant, 642
posticus, dislocation, 337
Tiegel. Mediastinal emphysema, 738
Suture lung, 734
Tiegel's mask, 711
Tietse. Bone cysts, 453
Tilarius tendon fixation, 678
Toe, amputation, 681
hammer, 617
nail, ingrowing, 478
Toes, tuberculosis, 528
Tonsils, arthritis deformans, 203
rheumatic infections, 499
Tooth's paralysis, 604
Torek. Aspiration, pleura, 757
Resection, œsophagus, 767
Torek's incision, 733
Tourniquet, dangers, 9
Toxines, Coley's, sarcoma, bone, 459
Transference, muscles and tendons, 298
Transplantation, bone, humerus, 325
extensor proprius hallucis, 606
flexor longus hallucis, 676
ligamentum patellæ, 588
peroneus longus, 676
tendons, 624, 637
tibial tuberosity, 404
vein aneurism, 565
Transpleural drainage, liver and subphrenic abscess, 744
laparotomy, 738
operation, diaphragmatic hernia, 725
on œsophagus, 765
Trapezium and trapezoid, dislocation, 142
Traumata, chest, 719
lower extremity, 333
and sarcoma, 451
upper extremity, 1

Traumatic flat-foot, 612
myositis ossificans, 219
neuritis, arm, 16
paralysis, upper extremity, 291
tenosynovitis, 23
Treatment abscess, lung, 776
anchylosis, hip, 694
acute osteomyelitis, 482
aneurism, 564
arthritis, deformans, 530
arm, 191, 317
deformans, 207
arteriosclerosis, lower extremity, 559
arterio-venous aneurism, 558
boils, 150
bone cysts, 188, 454
bow-leg, 590
bronchiectasis, 802
burns, upper extremity, 5
bursitis, arm, 20
callosities, 476
Charcot's disease, 538
claw-foot, 604
club hand, 309
coccygodynia, 580
Colles' fracture, 88
congenital, club-foot, 595
dislocation, hip, 648
deltoid, paralysis, 301
diplegia, infants, 665
dislocation, ankle, 413
clavicle, 97, 98, 99, 100, 101, 102, 119
elbow, 127, 132
hip, 394
knee, 407
patella, 402
radius, 133, 134
tendon, 338
wrist, 137
Dupuytren's contracture, 314
early infantile paralysis, 625
elephantiasis, 574
empyema, 728
felons, 231
finger injuries, 4
flail ankle, 678
flat-foot, 612
floating bodies, joints, 543
foreign body in lung, 778
fractures, 358
clavicle, 31
dislocation, elbow, 41
Treatment, fractures, elbow, 56
forearm, 42
fingers, 96
metacarpal, 92
patella, 384
rib, 720
scaphoid, 91
scapula, 34
shoulder, 61
gangrene, 561
gonorrhœal arthritis, 513
hallux rigidus, 616
valgus, 616
hammer toe, 617
infections, hip, 490
knee, 494, 496, 498
ingrowing toe nail, 478
injuries, elbow, 53
median nerve, 15
nerves, 7
lower limb, 343
semilunar cartilage, 430
ulnar nerve, 15
knock-knee, 584
leg ulcers, 473
lymphangitis, 572
malum coxæ senilis, 696
muscle, rupture, 22
musculo-spiral paralysis, 14
myositis ossificans, 223
old dislocation, hip, 398
operation, paralysis, arm, 305
osteomyelitis, arm, 170
paralysis, calcaneo cavus, 673
phlebitis, 567
prophylactic infantile paralysis, 620
pulmonary emphysema, 775
recurrent dislocation, patella, 404
shoulder, 122
rupture, lung, 729
muscle, 335
tendon, 337
sarcomata, bone, 456, 457, 458
muscle, 451
sacro-iliac, dislocation, 388
snapping finger, 24
spasmodic flat-foot, 615
spastic paraplegia, 661
spasticity, upper extremity, 296
sprains, 24, 339
subastragaloid dislocation, 417
synovitis, hip, 497

Treatment, syringomyelia, 539
tenosynovitis, 23, 556
thoracic wounds, 725
traumatic neuritis, arm, 16
tuberculosis, abscess, 472
ankle, 525
arthritis, arm, 199
elbow, 315
hip, 519
knee, 524
lung, 779
osteitis, arm, 175
shoulder, 315
tarsus, 527
wrist, 316
tumors, knee, 460
ulnar, dislocation, 16
varicose veins, 569
Volkmann's contraction, 22
paralysis, 52, 226, 299
wounds, arm, 2
chest, 723
Trendelenburg's operation, 752
varicose veins, 569
Trephining rib, 761
Triangle, Bryant's, 392, 479
Trichinosis, arm, 217
Trigger finger, 227, 313
Trochanteric bursæ, 548
Tropical bubo, 573
Tubby. Neuroplasty, 8
Silk tendons, 677
Tuberculosis, abscess, lower limb, 472
ankle, 525
arthritis, 512, 514
arm, 192
cutaneous, arm, 155
elbow, 194, 196, 315
finger, 176
hand, 316
hip, 514
knee, 522
lung, collapse therapy, 779
Freund's operation, 799
lymphadenitis, 572
muscles, arm, 215
shoulder, 315
resection, 325
tarsus, 527
tenosynovitis, 238
lower extremity, 556
thoracic wall, 745
Tuberculosis, toes, 528
wrist, 195, 197, 315
Tuberculin, 199
Tuberculous osteitis, arm, 172
Tuberosities, humerus, fracture, 36, 38
Tuberosity, tibia, dislocation, 486
Tuffier. Fat compression, lung, 780, 791
Resection, lung, 799
Transplantation, vein, 565
Tumor, albus, 522
Tumors, ankle, 466
arm, 255
chest wall, 746
femur, 452
foot, 466
knee, 460
lower extremity, 439
lung, 775
mediastinum, 749
nerves, arm, 265
patella, 459
pleura, 756
popliteal space, 460
thymus, 748
of tibia, 465
Tyloma, 475
Tylosis, 475
Typhoid, arthritis, 505
hip, 487

U

Ulcers, leg, 472
Marjolin's, 461
perforating, 343
tuberculosis, arm, 155
X-ray, 6
Ulna, dislocation, 125
fractures, 40, 50
in Colles' fracture, 82
Ulnar nerve, injuries, 15
paralysis, 15
Unciform, dislocation, 141
Unilateral pneumothorax, 707
Union, fracture, clavicle, 30
elbow, 57
scapula, 34
shoulder, 64
Unterberger. Hemothorax, 727
Upper extremity, deformities, etc., 291
diseases, 149
fractures, 27

Upper extremity, operations, 319
traumata, 1

V

Vaccines, chest wounds, 727
gonorrhœal arthritis, 513
Vagus, blocking of, 765
Valvular drain, chest, 737
empyema, 761
Vanach. Sarcoma, patella, 459
Vanghetti. Amputations, 320
Varicose ulcers, 473
veins, 568
Vaseline injections, joints, 691
Vascular suture, 566
Veins, varicose, 568
Velpeau dressing, fracture, clavicle, 31
Venous implantation, aneurism, 565
thrombosis, 568
Verneuil. Hydroadenitis, 151
Verrucous tuberculosis, arm, 156
Vessels, arm, injuries, 16
ligation, gangrene, 16
lower extremities, disease, 557
Vital capacity, thorax, 705
Volkmann. Infective synovitis, 491
Marjolin's ulcer, 461
Volkmann's contracture, 22, 51, 224
paralysis, 43, 291, 298
Von Recklinghausen's disease, 265, 442

W

Waldren. Artificial pneumothorax, 781
Walker. Infection from tonsils, 499
Walton. Derangements, knee, 422
War surgery, chest, 723
Warts, arm, 255
sole, 469
Wassermann's reaction, diagnostic, bone disease, 457
Weak foot, 608
Webbed fingers, 312
Weir. Lipomata, knee, 460
White swelling, 522
Whitlow, 227
Wieting's operation, 559
Wegner. Syphilis, osteochondritis, 178
Williams' myositis ossificans, 210
Wilms's operation. Empyema, 765
Thoracoplasty, 780, 784
Wire, magnesium, suture, lung, 734
Wiring fractures, 372
Wolf. Intercostal diaphragm hernia, 725
Wolff's law, 584
Wölfler. Sarcoma, bone, 456
Wounds, arm, 1
local anæsthesia, 26
blood-vessels, 18
bronchi, 728
bronchus, suture, 779
bullet, arm, 17
gunshot, chest, 722
muscles, 21
lower limb, 333
sciatic nerve, 343
tendons, lower limb, 335
thorax, 720
treatment, 725
vessels, arm, 16
Wright's solution, chest wounds, 727
Wrist, amputation and disarticulation, 320
arthroplasty, 331
dislocation, 136
drop, 13, 72
dropped, 621
excision, 329
fracture, 78
palsies, 303
spasticity, 296
sprains, 24
tuberculosis, 195, 197, 315
Wyeth's amputation, hip, 687
pins, 685

X

X-ray burns, 6
carcinoma, 6
dermatitis and cancer, 274

Z

Zaaijer. Intrapharyngeal anæsthesia, 711
Œsophagus, diverticular, 766
Resection carcinoma cardia, 770
Zandler's apparatus, 299

NOV 8 1918

COLUMBIA UNIVERSITY LIBRARIES (hsl,stx)
RD 31 B51 C.1 v. 3
A treatise on regional surgery
2002104652

RD31 B51
3
Dinnie
Regional Surgery